

Case Report

An elderly 'kawara' craftsman with acute kidney injury and haemoptysis: a case of silica-induced autoimmunity

Satoshi Matsui, Hiroko Tsuji and Shinji Ono

Department of Nephrology and Hypertension, Mitsubishi Kyoto Hospital, Kyoto, Japan

Correspondence and offprint requests to: Satoshi Matsui; E-mail: smatsui-kob@umin.ac.jp

Abstract

A 62-year-old Japanese 'kawara' (ceramic roof tile) craftsman presented with acute kidney injury and haemoptysis. This case met the systemic lupus erythematosus and microscopic polyangiitis criteria, with high titres of myeloperoxidase–antineutrophil cytoplasmic antibody (570 EU). Results showed the presence of antinuclear antibody at a high titre (1:2560), but detection of rheumatoid factor, anti-dsDNA, anti-SSA and anti-SSB antibodies was not apparent. This serology was similar to drug-induced, silicon-induced or silica-induced autoimmunity. The patient had been exposed to silica for >40 years. The environmental aetiology of autoimmune diseases should be considered in cases that show atypical epidemiology and serology.

Keywords: adjuvant effect; p-ANCA; silica; SLE

Background

The association between silica exposure and autoimmune diseases has been well discussed [1–3]. A Japanese 'kawara' (ceramic roof tile) craftsman, who came to our hospital presenting with acute kidney injury and pulmonary haemorrhage, met the systemic lupus erythematosus (SLE) and microscopic polyangiitis (MPA) criteria with high titres of myeloperoxidase–antineutrophil cytoplasmic antibody (p-ANCA). He had been heavily exposed to silica included in 'kawara' for >40 years.

Case report

A 62-year-old male presented with a 2-week history of cough, fever, oliguria and haemoptysis. His medical history included hypertension, hyperuricaemia and odontogenic maxillary sinusitis for >20 years. He was administered amlodipine (5 mg/day), allopurinol (100 mg/day) and pravastatin (10 mg/day). He also had a 20-year history of cigarette smoking, and had worked until this admission as a Japanese 'kawara' craftsman for >40 years.

Upon physical examination, his body temperature was 38°C, SpO₂ 89% (room air) and BP 160/80 mmHg. Auscultation of the chest was significant for bilateral fine crackles, and oral ulcers were detected.

The estimated 24-h urinary protein excretion showed 6.0 g/g Cr. Berlin blue staining of his sputum was positive and showed phagocytosis of haemosiderin. The urinary sediment contained many deformed erythrocytes.

His serology results were strongly positive for antinuclear antibody (ANA) with a homogeneous immunofluorescence pattern at a titre of 1:2560. The patient also demonstrated decreased complement component 3 (C3; 54 mg/dL) and elevated platelet-associated IgG (27.1 ng/10⁷ cells), but was negative for the presence of anti-ssDNA, anti-dsDNA, anti-Sm, anti-GBM, c-ANCA, anti-SSA, anti-SSB and anti-cardiolipin antibodies, along with rheumatoid factor and lupus anticoagulant. His serum creatinine level was 6.79 mg/dL, and p-ANCA titre was elevated to 570 EU. His KL-6 was also elevated to 1200 IU/L. Laboratory tests included normal leucocyte counts (6900/μL) with slight lymphocytopenia (1242/μL), no eosinophilia, normal platelet counts (139 000/μL), depressed haemoglobin level (6.0 mg/dL) and elevated CRP (1.21 mg/dL).

Chest computed tomography (CT) scan showed bilateral pulmonary interstitial fibrosis with haemorrhage, emphysema, several small calcified nodules that are scattered in the upper lung fields, and some calcified hilar lymph nodes, which is not specific but suggestive of silicosis (Figure 1).

As his manifestation was strongly suggestive of MPA, we initiated induction therapy with three daily doses of methylprednisolone (12 mg/kg/day) followed by daily oral administration of prednisolone (1.0 mg/kg for the first month). Pulmonary interstitial fibrosis responded well to our therapy, but his renal function did not recover, and dialysis was required. After a month, p-ANCA titre had not declined to a satisfactory level; therefore, we administered cyclophosphamide (1 mg/kg/day) orally. However, because of pancytopenia caused by cyclophosphamide, we discontinued cyclophosphamide 17 days after prescribing it. Following his clinical improvement, we tapered off

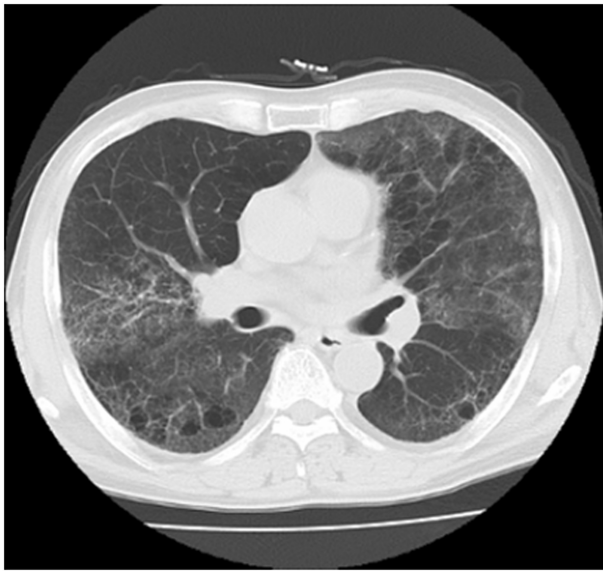

Fig. 1. Chest computed tomography showed bilateral pulmonary interstitial fibrosis, emphysema, several small calcified nodules that were scattered in the upper lung fields, and some calcified hilar lymph nodes.

oral prednisolone to a dose of 0.5 mg/kg/day and discharged the patient. His clinical course is described in Figure 2.

Discussion

An overview of the patient's clinical symptoms and laboratory data led us to believe this was a case of pulmonary–renal syndrome with haemorrhage. Wegener's granulomatosis was ruled out because of the poor manifestations of nasopharyngeal symptoms and negative c-ANCA. Goodpasture syndrome was also discounted because of a lack of anti-GBM antibody. Churg–Strauss syndrome was not considered due to lack of eosinophilia and a history of asthma. MPA was considered because his clinical manifes-

tations fit the definite (b) criteria (rapid progressive glomerulonephritis, pulmonary haemorrhage, fibrosis and p-ANCA) defined by the Japanese Ministry of Health, Labour and Welfare. SLE was our final diagnosis based on the American College of Rheumatology criteria, due to the presence of oral ulcers, proteinuria, lymphocytopenia and a high titre of ANA.

The patient was elderly and lacked the presence of other autoantibodies with the exception of the high ANA titre. This was rather suggestive of a drug-induced lupus than idiopathic, but any suspected drugs could not be detected in the patient.

Until this hospital admission, the patient had worked for >40 years as a Japanese 'kawara' craftsman in a very dusty factory during the manufacturing process, where there were no air conditioning or exhaust ports. Japanese 'kawara' tiles include silica.

Recently, Al-Mogairen *et al.* reported induction of autoimmunity in Brown Norway rats by oral and parenteral administration of sodium silicate [4]. The silica exposure group showed a high level of serum ANA compared with controls, but was negative for the presence of other autoantibodies. The adjuvant effect of silica has also been discussed [5].

The so-called 'adjuvant diseases' are multi-organ collagen or autoimmune diseases, including SLE, induced after 'silicon gel' implantation into the nose or breast for cosmetic purposes [6]. A review showed that prevalence of ANA was wide-ranging (7–68%) in patients with silicone implants, and the prevalence of other autoantibodies was discussed [7–9].

We considered that his pathophysiology was related to silica exposure. First, he had been heavily exposed to silica, and his chest CT findings were compatible with silicosis. Second, he was diagnosed as an elderly-onset lupus, but showed hypocomplementaemia and negative RF, anti-SSA and anti-SSB antibodies. Late-onset idiopathic SLE patients tend to manifest a higher rate of positive findings of RF, anti-SSA and anti-SSB antibodies, and a lower occurrence of hypocomplementaemia [10]. Third, silica ex-

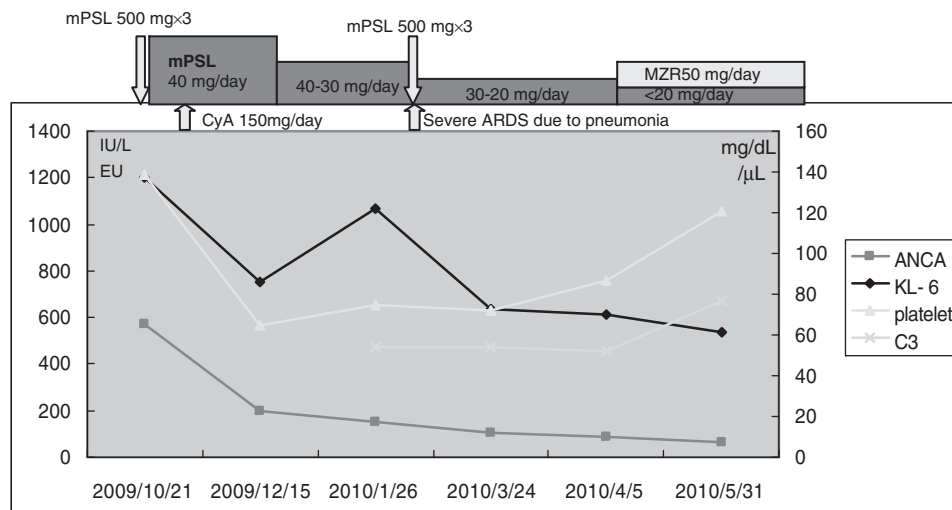


Fig. 2. Several serologic markers during his clinical course are shown. p-ANCA (EU), KL-6 (IU/L), platelet (μ L) and C3 (mg/dL).

posure rat model and adjuvant effect of a silica in humans have also been reported. Thus, we concluded that this case may be an example of a silica-induced autoimmunity caused by an adjuvant effect.

The environmental aetiology of autoimmune diseases should be considered in a case that shows atypical epidemiology and serology.

Acknowledgements. We are grateful to Dr Masahisa Kyogoku for discussions and helpful suggestion.

Conflict of interest statement. None declared.

References

1. Hogan SL, Cooper GS, Savitz DA *et al.* Association of silica exposure with anti-neutrophil cytoplasmic autoantibody small-vessel vasculitis: a population-based, case-control study. *Clin J Am Soc Nephrol* 2007; 2: 290–299
2. Bartůnková J, Pelclová D, Fenclová Z *et al.* Exposure to silica and risk of ANCA-associated vasculitis. *Am J Ind Med* 2006; 49: 569–576
3. Brown JM, Pfau JC, Pershouse MA *et al.* Silica, apoptosis, and autoimmunity. *J Immunotoxicol* 2005; 1: 177–187
4. Al-Mogairen SM, Al-Arfaj AS, Meo SA *et al.* Induction of autoimmunity in Brown Norway rats by oral and parenteral administration of sodium silicate. *Lupus* 2009; 18: 413–417
5. Mancino D, Bevilacqua N. Adjuvant effect of amorphous silica on the immune response to various antigens in guinea pigs. *Int Arch Allergy Appl Immunol* 1977; 53: 97–103
6. Yoshida SH, Chang CC, Teuber SS *et al.* Silicon and silicone: theoretical and clinical implications of breast implants. *Regul Toxicol Pharmacol* 1993; 17: 3–18
7. Bridges AJ. Autoantibodies in patients with silicone implants. *Semin Arthritis Rheum* 1994; 24: 54–60
8. Bridges AJ, Conley C, Wang G *et al.* A clinical and immunologic evaluation of women with silicone breast implants and symptoms of rheumatic disease. *Ann Intern Med* 1993; 118: 929–936
9. Cuéllar ML, Scopelitis E, Tenenbaum SA *et al.* Serum antinuclear antibodies in women with silicone breast implants. *J Rheumatol* 1995; 22: 236–240
10. Rovenský J, Tuchyňová A. Systemic lupus erythematosus in the elderly. *Autoimmun Rev* 2008; 7: 235–239

Received for publication: 13.9.10; Accepted in revised form: 28.9.10