



## Case report

# Hemoptysis in a patient with pulmonary aspergilloma and type 2 diabetes mellitus: A rare case in an Indonesian adult

Gilang Muhammad Setyo Nugroho, Laksmi Wulandari \*

Department of Pulmonology and Respiratory Medicine, Faculty of Medicine, Universitas Airlangga – Dr. Soetomo General Academic Hospital, Surabaya, Indonesia

## ARTICLE INFO

## Keywords:

Pulmonary aspergilloma  
Type 2 diabetes mellitus  
Hemoptysis  
Lobectomy

## ABSTRACT

**Background:** The success rate of surgery on aspergilloma is quite low since aspergilloma generally spreads throughout the lung cavity.

**Case presentation:** A 45-year-old woman with a past history of type 2 diabetes mellitus presented with chronic hemoptysis. Clinical presentation and work up revealed a left lung aspergilloma, with x-ray and CT-scan showing a mass in the upper lobe of left lung and FNAB showing *Aspergillus* sp. The patient underwent thoracotomy with left superior lobectomy. Histopathological examination of specimens showed hyphae with septa. The patient had postoperatively controlled pleural effusions.

**Discussion:** T2DM is a risk factor for *Aspergillus* sp infection because it is immunocompromised when hyperglycemia occurs. Pulmonary aspergilloma has a poor prognosis during surgery. Removing aspergilloma in the lung cavity and maintaining blood glucose levels can provide a good prognosis. Keeping the amount of fluid from increasing is the main focus of post-surgery.

**Conclusion:** Pulmonary aspergilloma that only occurs in one lung lobe has a good prognosis after surgery.

## 1. Introduction

Pulmonary aspergilloma is a fungus ball (mycetoma) that occurs due to cavity in the parenchyma from previous lung disease. This fungus ball can move within the cavity but does not invade the cavity wall and cause recurrent hemoptysis [1]. Pulmonary aspergilloma cases are reported in about 1/100,000 people in developing countries [2]. Pulmonary aspergilloma has a poor prognosis, in which the mortality rate in this case is reported to be 50–55%. Meanwhile, pulmonary aspergilloma with surgical treatment is reported to have 1–23% of good prognosis [1,3].

Type 2 diabetes mellitus (T2DM) results in a complex immunological inflammatory process, in which insulin resistance produces a series of immune responses that exacerbate the inflammatory state [4]. T2DM results in being immunocompromised which increases the risk for infection with microorganisms, such as *Aspergillus* sp [5]. Based on the description above, we were interested in reporting a case of pulmonary aspergilloma and T2DM in an Indonesian woman who underwent surgery and had a good prognosis. This case report used the Surgery Case Report (SCARE) 2020 Guideline [6].

## 2. Case presentation

A 45-year-old woman came to the hospital with complaint of coughing up blood since  $\pm 10$  months ago, left chest pain when coughing, decreased appetite, weight loss of  $\pm 6$  kg over the last 6 months, no fever and no night sweats. The patient had a history of TB treatment for 9 months  $\pm 8$  years ago, and was declared cured by the doctor. In addition, the patient had type-2 diabetes mellitus, with random blood glucose test of 256 mg/dL.

The examination found a respiration rate of 24/min, a pulse of 102/min. Thoracic examination showed lagged asymmetrical chest movements of left lung, and in the upper 1/3 of the left lung was found decreased fremitus, dull percussion, and decreased vesicular sound. X-rays and CT-scans showed a fungus ball in the left lung which is located between the superior and inferior lobes of the left lung (Fig. 1). Microbiological examination of KOH sputum found hyphae with septa, gram negative (+4), negative acid resistant bacteria, and negative *Mycobacterium tuberculosis*. Examination of fungal culture on the sputum obtained *Candida* sp. Fine needle aspiration biopsy (FNAB) was performed on the left lung, obtaining *Aspergillus* sp, due to suspicion of cell lung

\* Corresponding author at: Laksmi Wulandari, Department of Pulmonology and Respiratory Medicine, Faculty of Medicine, Universitas Airlangga – Dr. Soetomo General Academic Hospital, Jalan Mayjend Dr. Moestopo No. 6-8, Airlangga, Gubeng, Surabaya, East Java 60286, Indonesia.

E-mail address: [laksmi.wulandari@fk.unair.ac.id](mailto:laksmi.wulandari@fk.unair.ac.id) (L. Wulandari).

<https://doi.org/10.1016/j.ijscr.2021.106125>

Received 1 May 2021; Received in revised form 11 June 2021; Accepted 17 June 2021

Available online 18 June 2021

2210-2612/© 2021 The Authors. Published by Elsevier Ltd on behalf of IJS Publishing Group Ltd. This is an open access article under the CC BY-NC-ND license

(<http://creativecommons.org/licenses/by-nc-nd/4.0/>).

carcinoma. Other examination results obtained two hours postprandial glucose of 410 mg/dL and HBA1C of 12.5%. Based on the data above, the patient was diagnosed with pulmonary aspergilloma and T2DM.

The patient's initial management included administration of codeine 3x10mg, tranexamic acid 3 × 500 mg iv, novorapid 3 × 10 units, levemir 12 units (night), Fluconazole 1 × 400 mg (day 1) followed by 1 × 200 mg. Based on the results of X-ray and CT-scan, surgery was conducted using pulmonary wedge resection in the location of the aspergilloma in the left superior lobe. When a left superior lobe lobectomy was performed, there was a strong adhesion between the superior and inferior lobes (Fig. 2). The pathology anatomy results also revealed *Aspergillus sp* (Fig. 3). After surgery, the patient received micafungin therapy as much as 1 × 200 mg fluconazole, 3 × 12 units of novorapid, 12 units of levemir (night), and anti-tuberculosis drug category II. Fluconazole was still used because the results of laboratory tests showed sensitivity to *Aspergillus sp*. The patient had a good and stable prognosis which resulted in the patient having a controlled left cavity pleural effusion. The patient's spirometry results obtained FVC = 65%, FEV1 = 59%, and FEV1/FVC = 71.2%. Balloon blowing exercises were recommended for the patient to keep the amount of fluid in the empty cavity stable.

### 3. Discussion

Weight loss and T2DM are risk factors for pulmonary aspergilloma. Previous studies reported that as many as 66% of pulmonary aspergilloma patients experienced weight loss of 22 ± 3 lbs. with a reduction range of 3.3–43 lbs. In addition, it was reported that 34% of invasive aspergilloma patients had a history of T2DM. This condition was more than that of immunocompromised patients who had invasive aspergilloma as much as 21% [7]. Other studies also reported that T2DM patients are at high risk of being infected with fungi such as *Candida sp*, *Aspergillus sp*, etc. In addition, fluconazole resistance was found in this group of fungi [8]. T2DM increases the risk for several fungal infections including *Candida sp* (21.6%), *Cryptococcus sp* (17.1%), and *Aspergillus sp*. (12.6%) [9].

T2DM patients have insulin resistance or hyperglycemia which increases the production of Advanced Glycation End (AGE). The production of AGE leads to the formation of reactive oxygen species (ROS) that is used to reduce nicotinamide adenine dinucleotide phosphate (NADPH) by the Polyol Pathway, and reduces the overall levels of glutathione (GSH) and GSH-producing enzymes in T2DM patients. This mechanism causes immunocompromised, so that T2DM patients are susceptible to invasive *Aspergillus sp* [4,10]. This understanding of immunocompromised is useful for pulmonary aspergilloma and T2DM patients with the aim of controlling patient's blood glucose levels and

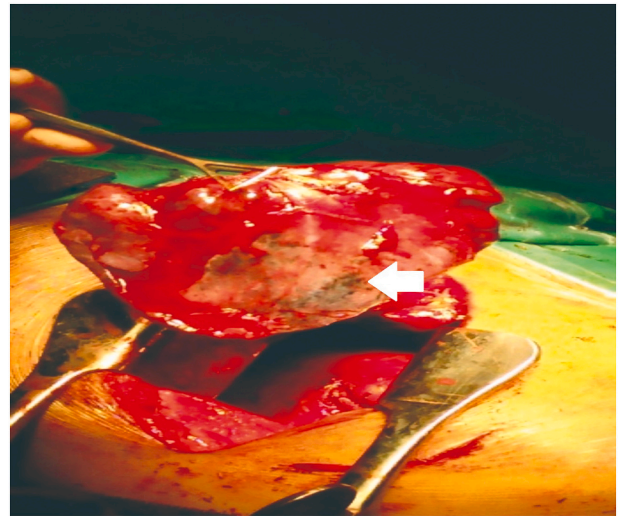


Fig. 2. Lung tissue of the superior lobe of the left lung infected with *Aspergillus sp*.

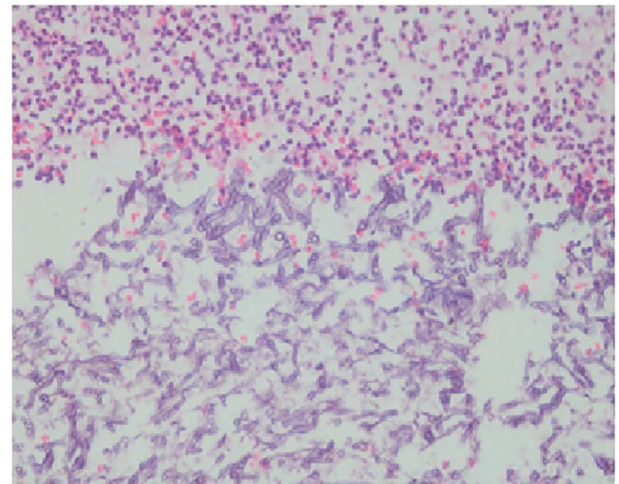


Fig. 3. The pathological anatomical microscopic structure of Aspergilloma with septic hyphal formation.

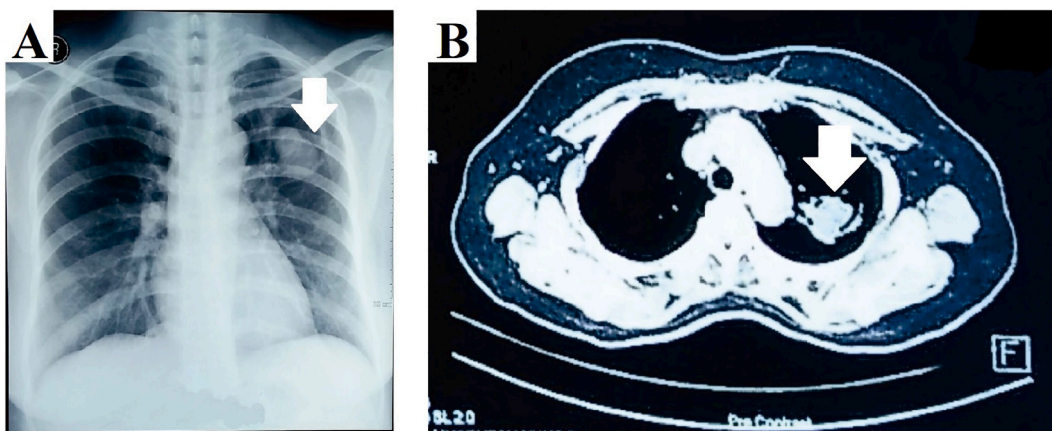


Fig. 1. A. A thin-walled cavity appeared with opacity in the shape of a well-defined oval. B. Fungus ball appeared in the apicoposterior segment of the superior lobe of the left lung.

HBA1C levels. Concomitant administration of insulin and antimycotic drugs has a good prognosis in our patient [4,11].

In terms of effectiveness of hemoptysis control, surgical therapy seems to be the first choice [12,13]. Surgery is performed to eliminate or stop the aspergilloma infection process in the superior lobe of the left lung which is located adjacent to the inferior lobe. Thus, thoracotomy surgery was chosen to facilitate surgery if the worst case would have to remove one lung [13,14]. This study considered to conduct surgery on the location of pulmonary aspergilloma in one left superior lobe. This surgery did have a side effect in the form of pleural effusion, in which the cavity should be filled with the lung cavity when it is empty. Body compensation of this void by filling with fluid, as we maintained it by encouraging the patient to blow a balloon frequently so that the lung expansion is consistent and pleural fluid does not increase [15]. Most pulmonary aspergilloma patients have a poor prognosis after surgery with 53% mortality rate [1,3,16].

#### 4. Conclusion

T2DM patients are at risk of being immunocompromised due to insulin resistance. This condition makes the patient susceptible to fungal infections such as *Aspergillus* sp. Pulmonary aspergilloma and T2DM patients need to maintain their blood glucose levels to improve their treatment prognosis. Localized pulmonary aspergilloma and lobectomy surgery on the left superior lobe have a good prognosis when followed with anti-microtics. There is controlled pleural fluid production in the removed superior lobe after surgery.

#### Funding

None.

#### Ethical approval

We have conducted an ethical approval base on Declaration of Helsinki at Ethical Committee in Dr. Soetomo General Academic Hospital, Surabaya, Indonesia.

#### Consent

Written informed consent was obtained from the patient for publication of this case report.

#### Research registration

Not applicable.

#### Guarantor

Laksmi Wulandari.

#### Provenance and peer review

Not commissioned, externally peer reviewed.

#### CRediT authorship contribution statement

Gilang Muhammad Setyo Nugroho: data curation, investigation, visualization, formal analysis, writing in draft; Laksmi Wulandari: supervision, methodology, editing & revising in draft.

#### Declaration of competing interest

The authors declare that they have no conflict of interest.

#### Acknowledgement

We would like to thank Fis Citra Ariyanto who helped us in the process of drafting, editing and proof.

#### References

- Passera E, Rizzi A, Robustellini M, Rossi G, Della Pona C, Massera F, Rocco G (2012) Pulmonary aspergilloma: clinical aspects and surgical treatment outcome. *Thorac. Surg. Clin.* 22 (3):345–361. doi:<https://doi.org/10.1016/j.thorsurg.2012.04.001>.
- D.W. Denning, A. Pleuvry, D.C. Cole, Global burden of chronic pulmonary aspergillosis as a sequel to pulmonary tuberculosis, *Bull. World Health Organ.* 89 (12) (2011) 864–872. <https://doi.org/10.2471/blt.11.089441>.
- Moodley L, Pillay J, Dheda K (2014) Aspergilloma and the surgeon. *J. Thorac. Dis.* 6 (3):202–209. doi:<https://doi.org/10.3978/j.issn.2072-1439.2013.12.40>.
- A. Berbudi, N. Rahmadika, A.I. Tjahjadi, R. Ruslami, Type 2 diabetes and its impact on the immune system, *Curr. Diabetes Rev.* 16 (5) (2020) 442–449. <https://doi.org/10.2174/1573399815666191024085838>.
- R.V. Leite-Filho, G. Fredo, C.G. Lupion, A. Spanemberg, G. Carvalho, L. Ferreira, D. Driemeier, S.P. Pavarini, L. Sonne, Chronic invasive pulmonary Aspergillosis in two cats with diabetes mellitus, *J. Comp. Pathol.* 155 (2–3) (2016) 141–144. <https://doi.org/10.1016/j.jcpa.2016.06.009>.
- R.A. Agha, T. Franchi, C. Sohrabi, G. Mathew, A. Kerwan, A. Thoma, A.J. Beamish, A. Noureldin, A. Rao, B. Vasudevan, B. Challacombe, B. Perakath, B. Kirshstein, B. Eksler, C.S. Pramesh, D.M. Laskin, D. Machado-Aranda, D. Miguel, D. Pagano, F. H. Millham, G. Roy, H. Kadioglu, L.J. Nixon, I. Mukhejee, J.A. McCaul, J. Chi-Yong Ngu, J. Albrecht, J.G. Rivas, K. Raveendran, L. Derbyshire, M.H. Ather, M. A. Thorat, M. Valmasoni, M. Bashashati, M. Chalkoo, N.Z. Teo, N. Reason, O. J. Muensterer, P.J. Bradley, P. Goel, P.S. Pai, R.Y. Afifi, R.D. Rosin, R. Coppola, R. Klappenbach, R. Wynn, R.L. De Wilde, S. Surani, S. Giordano, S. Massarut, S. G. Raja, S. Basu, S.A. Enam, T.G. Manning, T. Cross, V.K.L. Karanth, V. Kasivisvanathan, Z. Mei, The SCARE 2020 guideline: updating consensus surgical CAse REport (SCARE) guidelines, *Int. J. Surg.* 84 (2020) 226–230. <https://doi.org/10.1016/j.ijsu.2020.10.034>.
- Ghanaat F, Tayek JA (2017) Weight loss and diabetes are new risk factors for the development of invasive aspergillosis infection in non-immunocompromized humans. *Clin. Pract. (Lond. Engl.)* 14 (5 Spec Iss):296–301. doi:<https://doi.org/10.4172/clinical-practice.1000125>.
- C.F. Rodrigues, M.E. Rodrigues, M. Henriques, Candida sp. infections in patients with diabetes mellitus, *J. Clin. Med.* 8 (1) (2019). <https://doi.org/10.3390/jcm8010076>.
- M. Lao, C. Li, J. Li, D. Chen, M. Ding, Y. Gong, Opportunistic invasive fungal disease in patients with type 2 diabetes mellitus from southern China: clinical features and associated factors, *J. diabetes Investig.* 11 (3) (2020) 731–744. <https://doi.org/10.1111/jdi.13183>.
- S. Ferlita, A. Yegiazaryan, N. Noori, G. Lal, T. Nguyen, K. To, V. Venketaraman, Type 2 diabetes mellitus and altered immune system leading to susceptibility to pathogens, especially mycobacterium tuberculosis, *J. Clin. Med.* 8 (12) (2019). <https://doi.org/10.3390/jcm8122219>.
- . Raiesi O, Siavash M, Mohammadi F, Chabavizadeh J, Mahaki B, MaheroInaghsh M, Dehghan P (2017) Frequency of cutaneous fungal infections and azole resistance of the isolates in patients with diabetes mellitus. *Adv. Biomed. Res.* 6:71. doi:<https://doi.org/10.4103/2277-9175.191003>.
- . Denning DW, Cadranel J, Beigelman-Aubry C, Ader F, Chakrabarti A, Blot S, Ullmann AJ, Dimopoulos G, Lange C (2016) Chronic pulmonary aspergillosis: rationale and clinical guidelines for diagnosis and management. *Eur. Respir. J.* 47 (1):45–68. doi:<https://doi.org/10.1183/13993003.00583-2015>.
- . Alastruey-Izquierdo A, Cadranel J, Flick H, Godet C, Hennequin C, Hoenigl M, Kosmidis C, Lange C, Munteanu O, Page I, Salzer HJF (2018) Treatment of chronic pulmonary Aspergillosis: current standards and future perspectives. *Respir. Int. Rev. Thorac. Dis.* 96 (2):159–170. doi:<https://doi.org/10.1159/000489474>.
- . Kosan B, Steger V, Walker T, Friedel G, Aebert H (2010) Surgery of pulmonary aspergillomas in immunocompromised patients. *Thorac. Surg. Sci.* 7:Doc01. doi:<https://doi.org/10.3205/tss000020>.
- . Karkhanis VS, Joshi JM (2012) Pleural effusion: diagnosis, treatment, and management. *Open Access Emerg. Med. OAEM* 4:31–52. doi:<https://doi.org/10.2147/oaem.S29942>.
- L. Huang, N. Zhang, X. Huang, S. Xiong, Y. Feng, Y. Zhang, M. Li, Q. Zhan, Invasive pulmonary aspergillosis in patients with influenza infection: a retrospective study and review of the literature, *Clin. Respir. J.* 13 (4) (2019) 202–211. <https://doi.org/10.1111/crj.12995>.