

OPEN

Initial Experience With a New Intraoral Midface Distraction Device

Fernando Burstein, MD,* Magdalena Soldanska, MD,* Michael Granger, DMD,*
ChiChi Berhane, MD,[†] and Mark Schoemann, MD[‡]

Abstract: Maxillary hypoplasia that necessitates surgical advancement affects approximately 25% of patients born with cleft lip and palate. Syndromic conditions such as Crouzon may also be accompanied by significant maxillary hypoplasia. Severe maxillary hypoplasia can result in airway obstruction, malocclusion, proptosis, and facial disfigurement. For optimal stability, severe hypoplasia is best addressed with maxillary distraction osteogenesis. Twenty-two patients (15 boys, 7 girls, ages 6–16 years, mean age 10 years) with severe midface hypoplasia underwent midface distraction with new internal maxillary distraction (IMD) device at our institution. Total distraction distances ranged from 15 to 30 mm. There were no major complications, and all of them had improvement in functional and aesthetic parameters. There were 2 minor complications and 2 patients failed to distract the full distance because of converging vectors. Early maxillary distraction in patients with severe midface hypoplasia is a useful technique to provide interval correction of severe maxillary hypoplasia before skeletal maturity and definitive orthognathic surgery is contemplated, and it is a good tool to improve occlusion, aesthetics, and self-perception in younger patients.

Key Words: Cleft palate, Le Fort I, midface distraction, midface hypoplasia

(*J Craniofac Surg* 2015;26: 1224–1228)

Osseous distraction of the craniofacial skeleton has become ubiquitous during the last 2 decades. Distraction osteogenesis was initially described by Codivilla in 1905 and Ilizarov in 1951 for use in long bones.^{1–3} In the 1990s, McCarthy applied it to the mandible.⁴ Subsequently, it was applied to the maxilla and most recently to the skull. By gradually creating a gap, new bone is

formed in the distraction gap, while soft tissues slowly stretch. The advantages of distraction osteogenesis are less relapse, avoidance of bone grafts, and less soft tissue damage. In the craniofacial skeleton, distraction has been performed as an acute procedure to relieve airway obstruction or as part of staged reconstruction to correct facial asymmetry in cases such as craniofacial microsomia. Patients with syndromes such as Crouzon, as well as those with cleft lip and palate, who experience severe maxillary hypoplasia may be candidates for interval maxillary distraction years before definitive correction is possible.

Approximately 25% of all of the patients with cleft lip and palate will require surgical maxillary advancements, and many need advancements greater than are deemed stable by a traditional Le Fort I.^{5–10} Potential benefits of maxillary distraction can include decreasing obstructive sleep apnea, correction of severe class III malocclusion, and improvement in corneal exposure in syndromic patients, with minimal rates of relapse. External maxillary distraction devices have been successfully used for many years and continue to be the most common method of midface distraction in 83% of patients.^{10–13} These require a skilled orthodontist, frequent adjustments during the distraction period, and prolonged wearing of a bulky external device that is attached both to the maxilla and to the cranial vault. Parental and patient dissatisfaction can stem from the obvious external device, the prolonged time necessary for distraction and consolidation, and potential problems at the cranial level because fixation is often done in patients who may have had a previous craniotomy.

Traditionally, maxillary advancement is performed in patients once they reach skeletal maturity.^{5,11} A standard Le Fort I can achieve good results in patients who require a small advancement (4–9 mm); however, multiple studies have shown that advancement >10 mm, especially in patients with cleft lip and palate has a high relapse rate 20% to 60%, despite use of adjuvant stabilization measures such as plates and bone grafts.^{5,6,8–10,14,15} About a quarter of patients, who require major maxillary advancements (>10 mm), also undergo mandibular setback, despite having normal mandibular proportions, which may compromise facial esthetics and functional outcome by potentially worsening obstructive sleep apnea.^{10,11,16} Distraction at the mixed dentition stage can successfully be used as an interval procedure before definitive skeletal surgery at maturity, especially in patients in whom there are airway or ocular symptoms, or the ultimate advancement distance is too great for conventional techniques at skeletal maturity.

This study reports our experience with midface distraction using an internal maxillary distraction (IMD) device (KLS Group, Jacksonville, FL) placed through an intraoral incision. The IMD device was used as an interval measure in patients with severe midface hypoplasia and symptoms ranging from obstructive sleep apnea to corneal exposure. Our goal was to relieve the most severe symptoms and provide interval aesthetic and functional improvement of maxillary mandibular relations until definitive orthodontic intervention and orthognathic surgery at skeletal maturity.

From the *Children's Healthcare of Atlanta, the [†]Piedmont Hospital, Atlanta, GA, and the [‡]Virginia Tech Carilion School of Medicine, Roanoke, VA.

Received April 24, 2014.

Accepted for publication November 16, 2014.

Address correspondence and reprint requests to Magdalena Soldanska, MD, Scottish Rite Children's Healthcare of Atlanta, 975 Johnson Ferry Rd, NE, Suite 100, Atlanta, GA 30342; E-mail: msoldanska@atlplastic.com
FB is a consultant for KLS Martin Group, Jacksonville, FL.

The authors report no conflicts of interest.
Copyright © 2015 by Mutaz B. Habal, MD
ISSN: 1049-2275

DOI: 10.1097/SCS.0000000000001728

This is an open access article distributed under the terms of the Creative Commons Attribution-NonCommercial-NoDerivatives 4.0 License, where it is permissible to download and share the work provided it is properly cited. The work cannot be changed in any way or used commercially.

Copyright © 2015 by Mutaz B. Habal, MD
ISSN: 1049-2275

DOI: 10.1097/SCS.0000000000001728

MATERIALS AND METHODS

Twenty-two patients underwent midface distraction with the IMD device during a 3-year span from 2010 to 2013. There were 15 boys and 7 girls, ages 6 to 16 years, (mean age 10.24 years). All underwent maxillary osteotomies through an intraoral approach. There were 14 patients with a unilateral cleft, 6 patients with bilateral cleft, and 2 patients with Crouzon syndrome in this series. Indications for surgery included severe midface hypoplasia with class III malocclusion and a >12.0 mm discrepancy between the maxillary and mandibular dentition. All of the patients had symptoms of mild to severe obstructive sleep apnea and gross aesthetic deformities. The 2 patients with Crouzon syndrome also exhibited proptosis with symptoms consistent with corneal exposure including pain, excessive tearing, and inability to close the eyelids completely, despite a fronto-orbital advancement early in life. All of the patients had preoperative three-dimensional computed tomography scans with model reconstruction for planning purposes. They also had standard cephalometric and dental radiographs. All of the candidates for the IMD device were examined by the craniofacial surgeon, orthodontist, pediatric dentist, and speech pathologist preoperatively and postoperatively.

All of the patients underwent immediate intraoperative distraction of 5.0 mm with a 2-day latency period before a 2.0 mm/d distraction rate was implemented (1 mm twice a day). After distraction, 5 weeks of consolidation were allowed before the devices were removed on an outpatient basis in the operating room. Bone morphogenic protein (BMP) was placed in the osteotomy sites at the time of IMD device placement in all of the patients. All of the patients were placed on a soft diet for 5 weeks.

Technique

A standard Le Fort I approach was taken in all of the patients with cleft lips and palates; however, because most of the patients were in mixed dentition, the osteotomies were planned around the location of the unerupted teeth leaving 5 mm of bone between the teeth and the osteotomy site. This was made possible by careful study of the three-dimensional models (Medical Modeling Corporation, Golden, CO), which show the tooth buds exceptionally well. Important modifications for application of the IMD devices included bridging the right and left halves of the maxilla in unilateral clefts with a reconstruction plate and the premaxillary segment to the 2 halves of the maxilla in bilateral clefts with the same type of reconstruction plate. This was done to insure that the entire maxilla moved forward as a single structural unit even though all of the patients had previous alveolar bone grafting. All of the patients underwent submucous resection of any deviated septal, cartilaginous, or bony components, as well as turbinate reduction to insure a good postoperative airway. In the 2 patients with Crouzon syndrome undergoing advancement of the inferior orbit, the Le Fort I osteotomies were modified to include the lateral and inferior

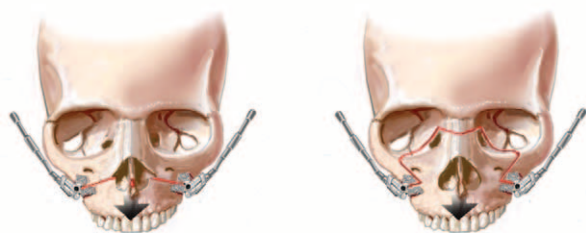


FIGURE 1. Traditional Le Fort osteotomy and modified osteotomy in patients with Crouzon syndrome, which include inferomedial orbital rims.

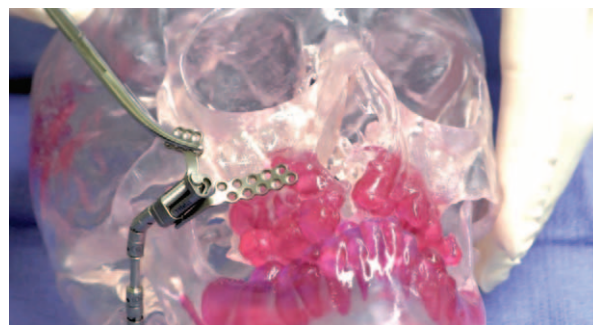

FIGURE 2. Device prebent on the three-dimensional model before application.

orbits, as shown in Figure 1. In these patients, midciliary incisions allowed access to the inferior orbital rims. After application of the transmaxillary plate to unite the maxilla into a single structural unit, the IMD devices were precisely bent to the contours of the maxilla on the sterile three-dimensional model (Fig. 2). This step included making sure that the proximal and distal plates were above the apices of the teeth and that the distraction vector would be parallel to the occlusal plane with as little convergence as possible.

After the osteotomy was completed, full mobilization was achieved. The segments were then returned to their original position. The devices were then applied using 3 proximal and 3 distal, with 2.0 × 7.0 mm screws. The path of the drive screw is delineated by gliding a tonsil clamp along the mandibular ramus just lateral to the coronoid to avoid damage to the parotid gland or the facial nerve, then making a stab incision just superior to the helical root. It is vital that the devices are placed parallel to each other and to the occlusal plane, otherwise vectors may erroneously converge or diverge (Fig. 3).

Once the IMD device was secured on both sides, the entire maxillary complex was distracted 15.0 mm to make sure there were no areas of bony interference. Often a small amount of bone

Correct
Distraction vector parallels zygomatic arch

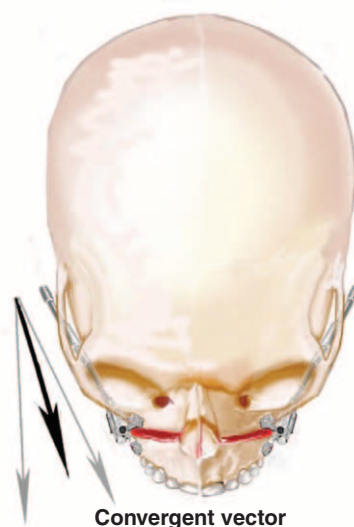

FIGURE 3. Correct distraction vector.

from the medial maxillary wall or lateral buttress needs trimming to insure that the maxillary distraction was not impinged upon as the maxilla came forward. Once unimpeded maxillary distraction was achieved, the IMD device was returned to a 5.0 mm distraction distance. The distraction osteotomies were then wrapped with BMP methylcellulose sponges, and the wounds were closed with resorbable sutures.

All of the patients were extubated immediately in the operating room upon completion of their procedure. All of the patients were observed in the intensive care unit overnight, and distraction was started at a rate of 2.0 mm/d split into 1.0 mm in A.M./1.0 mm in P.M. after a 48-hour latency period. Patients were allowed a soft diet. Distraction was termed complete when either a class I occlusal relation was reached or 30.0 mm of total distraction, which was the maximal distance of the device, was reached. All of the patients received 5 days of perioperative antibiotics and a steroid taper. After full distraction, a 5-week consolidation period was implemented. After this, the devices were removed in the operating room on an outpatient basis.

RESULTS

All of the 22 patients had successful placement of the intraoperative devices. Distraction distances were between 15.0 and 30.0 mm with a mean of 18.0 mm. Operating times were <2 hours for each patient. In 2 patients, hardware became exposed through the distraction process intraorally but did not affect the final outcome. In 2 patients, distraction was stopped at 15.0 mm because of converging vectors preventing further advancement. Four patients had significant velopharyngeal incompetence and required speech surgery at a later date. There were no clinically significant relapses after removal of the bone distraction devices. There were no mortalities, no infections, and no adverse effects from the use of BMP during the clinical period.

In the 2 patients with Crouzon syndrome, who underwent advancement of the inferior and medial orbital rims as part of the midface distraction, good correction of exophthalmos was achieved. Both were able to close their eyes after the surgery, and corneal irritation symptoms were improved (Fig. 4).

No disruption of normal tooth eruption patterns has been noted to date in patients who have undergone distraction. All of the patients have been followed for ≥1 year. Obstructive apnea symptoms and facial appearance improved in all of the patients. All of them went from concave midfacial patterns to more normal convex patterns (Fig. 5).

DISCUSSION

A quarter of patients with cleft lip and palate and many patients with craniofacial syndromes have maxillary hypoplasia requiring surgical correction.⁵⁻¹⁰ The severe angle class III occlusion results in compromised mastication, speech, and obstructive apnea in addition to severe psychologic implications.¹⁰ Over the years, distraction osteogenesis has been proven safe and effective in advancing the retruded maxilla with small relapse rates as compared with a single-step advancement.^{5,8,14} Distraction also eliminates the need for plates, bone grafts, intermaxillary fixation, and mandibular setback, and decreases operative time and need for blood transfusion.^{10,11,16,17}

The most commonly used device is the (rigid external distraction) RED device popularized by Figueroa and Polley.¹⁰⁻¹³ It is a bone and tooth-anchored external halo device that gradually pulls the osteotomized maxilla forward. Advantages of the RED include vector control, single surgery, and ability to use when there is insufficient or poor quality bone.^{10,12,13,17,18} These devices, however, are psychologically and socially burdensome and can cause scarring, scalp osteitis, intracranial pin migration, skull fractures,

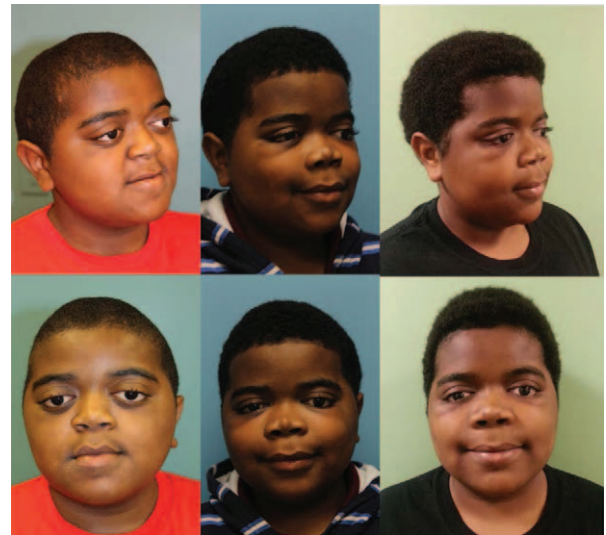

FIGURE 4. Patient with Crouzon syndrome before and after distraction, demonstrating stability 2 years postoperatively.

and loosening of device or tooth.^{8,11,16,18} Because they stay in place until consolidation occurs (6–12 weeks), they pose a significant burden on patients and families, and may not be well tolerated.

Several small studies have shown favorable results with internal bone-anchored devices.^{5,6,9,16,18-20} Internal devices tend to be better

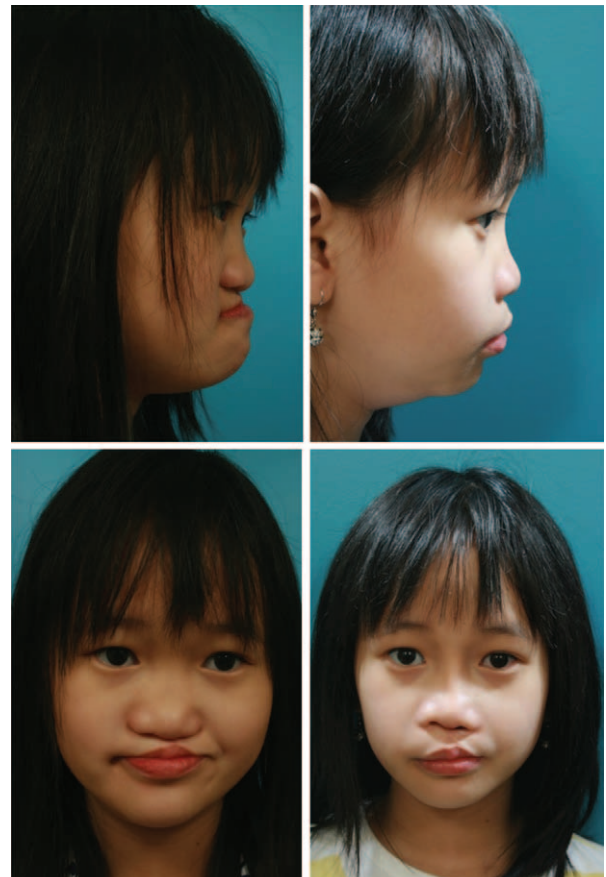


FIGURE 5. Patient with unilateral cleft lip and palate before and after 30 mm advancement.

tolerated and more inconspicuous; however, they are single vector thus requiring precise parallel placement, a second surgery to remove hardware, and sufficient bone stock to anchor, and may require a three-dimensional model for proper placement.^{5,6,8,14,18} In addition, many of the devices used have a limited distraction length. Chua and Hägg¹⁵ argue that internal distractors provide better long-term stability than external distractors because internal distractors transverse, and do not pull maxilla, which may decrease relapse rates. Both the methods had similarly low complication rates around 5%.^{11,14}

Our series of 22 patients had IMD device for severe midface hypoplasia because of a number of etiologies over a period of 36 months. Improvement in function and aesthetics were seen in all of the patients with minimal complications. Two patients did not have complete distraction because of converging vectors. This is a technical problem that occurs when the distraction devices are not placed parallel to each other and can be prevented by using intraoperative models to ensure parallel distraction. In the 2 patients who had exposed hardware, not enough of a buccal mucosal edge was left to allow tension-free coverage of the distractors.

The distance of ≥ 1.5 cm in all of the patients presents some of the greatest distraction distances achieved with internal distractors. Based on our experience with orthognathic surgery and distraction, we believe that the addition of BMP has greatly aided the rapid clinical bony consolidation achieved during our short 5-week consolidation period. Bone morphogenic protein, at the time of this writing, is used in 50% of patients with primary spinal fusion with good success and has been shown to induce mandibular bone formation amenable to implant placement and osseointegration as native bone; in addition, the formed bone does not significantly differ from the native bone.^{21–24} In all of the patients, bony callus was seen to be abundant in the osteotomy sites and the maxilla was clinically stable at IMD removal.

There is lack of consensus in the literature about the effect of distraction on velopharyngeal insufficiency.²⁵ Most studies show little if any increase in VPI in distracted patients, in which slow movements tend to stretch the soft tissues, whereas large single movements cause an increase in VPI.^{5,6,11,16,17} The general belief is that movements >10 mm in traditional Le Fort I, or 15 mm in distraction osteogenesis, will likely cause some increased nasal air escape. This was a problem that was experienced in 20% of patients, which is not unexpected given our great advancement distances. All of these cases resolved with a pharyngoplasty or pharyngeal flap 6 months after the distraction process.

The use of the IMD device as an intermediate step before orthognathic surgery represents a different approach than that used with most midface distraction halo devices. Indications include severe midface hypoplasia that would be extremely difficult to correct with orthognathic surgery alone, obstructive apnea, corneal exposure, significant psychosocial distress because of facial deformity, and its potential effect on speech or symptoms that can be corrected by early advancement. We are applying this to children as young as 6 years of age, in whom the tooth buds have descended to the point where modified high osteotomies can be made safely and effectively, especially with the aid of three-dimensional models that demonstrate the position of tooth buds.^{6,10,17,18} Eliminating rigid fixation also protects the tooth buds. This technique allows us to correct aesthetic as well as functional problems, such as sleep apnea, at an early age instead of waiting for definitive surgery when the patient is in the teens. This is particularly important in syndromic patients, who have been shown to benefit significantly from internal distraction with improvement in airway status that potentially avoids tracheostomy.²⁶ In the 2 patients with Crouzon syndrome, we were able to increase intraorbital volume and decrease the proptosis significantly with this approach. Both were able to close their eyes completely after the surgery, and both have had improvement in their corneal status.

Furthermore, we believe that early maxillary advancement will decrease the need for double jaw surgery when the patient is in his/her teens because the degree of maxillary advancement will be less pronounced. The psychologic benefit of early distraction when patients may be more vulnerable to peer and social pressures are significant. Chua et al²⁷ demonstrated that early distraction reduced social anxiety, social avoidance, and distress, and increased self-esteem and life satisfaction after completion of surgical correction.

In conclusion, the IMD device represents a new tool in armamentarium of the craniofacial surgeon. The IMD, as an intermediate step before definitive orthognathic surgery at skeletal maturity, allows for earlier aesthetic and functional correction in children with severe craniofacial deficiency. This may be applicable in children with severe midface hypoplasia and obstructive apnea, corneal exposure, or severe aesthetic deformities. The intraoral nature of this device makes it much more acceptable in many patient populations. Patients and parents should be prepared for the possible need for a definitive traditional orthognathic surgery at skeletal maturity.^{11,12,15–17,19}

REFERENCES

- Codivilla A. On the means of lengthening in the lower limbs, the muscles and tissues which are shortened through deformity. 1904. *Clin Orthop Relat Res* 1994;301:4–9
- Ilizarov GA. The tension-stress effect on the genesis and growth of tissues: Part I. The influence of stability of fixation and soft-tissue preservation. *Clin Orthop* 1989;238:249–281
- Ilizarov GA. The tension-stress effect on the genesis and growth of tissues: Part II. The influence of stability of fixation and soft-tissue preservation. *Clin Orthop* 1989;239:263–285
- McCarthy JG, Schreiber J, Karp N, et al. Lengthening the human mandible by gradual distraction. *Plast Reconstr Surg* 1992;89:1–8
- Kumar A, Gabbay JS, Nikjoo R, et al. Improved outcomes in cleft patients with severe maxillary deficiency after Le Fort I internal distraction. *Plast Reconstr Surg* 2006;117:1499–1509
- Wang XX, Wang X, Yi B, et al. Internal midface distraction in correction of severe maxillary hypoplasia secondary to cleft lip and palate. *Plast Reconstr Surg* 2005;116:51–60
- Wong GB, Padwa BL. LeFort I soft tissue distraction: a hybrid technique. *J Craniofac Surg* 2002;13:572–576
- Scolozzi P. Distraction osteogenesis in the management of severe maxillary hypoplasia in cleft lip and palate patients. *J Craniofac Surg* 2008;19:1199–1214
- Gateno J, Engel ER, Teichgraeber JF, et al. A new Le Fort I internal distraction device in the treatment of severe maxillary hypoplasia. *J Oral Maxillofac Surg* 2005;63:148–154
- Figuerola AA, Polley JW. Management of severe cleft maxillary deficiency with distraction osteogenesis: Procedure and results. *Am J Orthod Dentofacial Orthop* 1999;115:1–12
- Cheung LK, Chua HD. A meta-analysis of cleft maxillary osteotomy and distraction osteogenesis. *Int J Oral Maxillofac Surg* 2006;35:14–24
- Figuerola AA, Polley JW, Friede H, et al. Long-term skeletal stability after maxillary advancement with distraction osteogenesis using a rigid external distraction device in cleft maxillary deformities. *Plast Reconstr Surg* 2004;114:1382–1392
- Figuerola AA, Polley JW. Clinical controversies in oral and maxillofacial surgery: Part two. External versus internal distraction osteogenesis for the management of severe maxillary hypoplasia: external distraction. *J Oral Maxillofac Surg* 2008;66:2598–2604
- Cheung LK, Chua HD, Hägg MB. Cleft maxillary distraction versus orthognathic surgery: clinical morbidities and surgical relapse. *Plast Reconstr Surg* 2006;118:996–1008
- Chua HD, Hägg MB, Cheung LK. Cleft maxillary distraction versus orthognathic surgery: which one is more stable in 5 years? *Oral Surg Oral Med Oral Pathol Oral Radiol Endod* 2010;109:803–814
- Kahn DM, Broujerdi J, Schendel SA. Internal maxillary distraction with a new bimalar device. *J Oral Maxillofac Surg* 2008;66:675–683
- Doucet JC, Herlin C, Bigorre M, et al. Effects of growth on maxillary distraction osteogenesis in cleft lip and palate. *J Craniomaxillofac Surg* 2013;41:836–841

18. Sari E, Ucar C, Türk O, et al. Treatment of a patient with cleft lip and palate using an internal distraction device. *Cleft Palate Craniofac J* 2008;45:552–560
19. Rachmiel A, Aizenbud D, Peled M. Long-term results in maxillary deficiency using intraoral devices. *Int J Oral Maxillofac Surg* 2005;34:473–479
20. Mitsukawa N, Satoh K, Morishita T. Le Fort I distraction using internal devices for maxillary hypoplasia in patients with cleft lip, palate, and alveolus: complications and their prevention and management. *J Craniofac Surg* 2010;21:1428–1430
21. Herford AS, Tandon R, Stevens TW, et al. Immediate distraction osteogenesis: the sandwich technique in combination with rhBMP-2 for anterior maxillary and mandibular defects. *J Craniofac Surg* 2013;24:1383–1387
22. Cahill KS, Chi JH, Day A, et al. Prevalence, complications, and hospital charges associated with use of bone-morphogenetic proteins in spinal fusion procedures. *JAMA* 2009;302:58–66
23. Chin M, Ng T, Tom WK, et al. Repair of alveolar clefts with recombinant human bone morphogenetic protein (rhBMP-2) in patients with clefts. *J Craniofac Surg* 2005;16:778–789
24. Burstein FD, Maurice SM, Granger M, et al. Maxillary advancement in patients with severe maxillary hypoplasia: role of adjuvant stabilization techniques and materials. *J Craniofac Surg* 2012;23:812–816
25. Chua HD, Whitehill TL, Samman N, et al. Maxillary distraction versus orthognathic surgery in cleft lip and palate patients: effects on speech and velopharyngeal function. *Int J Oral Maxillofac Surg* 2010;39:633–640
26. Mitsukawa N, Kaneko T, Saiga A, et al. Early midfacial distraction for syndromic craniosynostotic patients with obstructive sleep apnoea. *J Plast Reconstr Aesthet Surg* 2013;66:1206–1211
27. Chua HD, Ho SM, Cheung LK. The comparison of psychological adjustment of patients with cleft lip and palate after maxillary distraction osteogenesis and conventional orthognathic surgery. *Oral Surg Oral Med Oral Pathol Oral Radiol* 2012;114(5 Suppl):S5–S10