

Dendritic fibromyxolipoma: A case report

HONGYUN LIU^{1*}, SHUMIN HEI^{2*}, JIGANG WANG³, QILIANG ZHANG⁴, XINJUAN YU⁵ and HUA CHEN^{1*}

¹Department of Pathology, Qingdao Municipal Hospital; ²Department of Pathology, School of Basic Medicine, Qingdao University, Qingdao, Shandong 266071; ³Department of Pathology, The Affiliated Hospital of Qingdao University, Qingdao, Shandong 266003; Departments of ⁴Sports Medicine and ⁵Central Laboratories, Qingdao Municipal Hospital, Qingdao, Shandong 266071, P.R. China

Received November 20, 2019; Accepted October 7, 2020

DOI: 10.3892/mco.2020.2169

Abstract. Dendritic fibromyxolipoma (DFML) is a rare variant of spindle cell lipoma. It is characterized by extensive myxoid change and the presence of stellate cells with dendritic processes. The present study reports three cases of DFML that arose from the limbs and thoracic cavity. Pathologically, the tumor was composed of mature adipocytes admixing with patch spindle cells in a myxoid stroma. The cell atypia was not apparent and mitotic figures were rare. Immunohistochemistry revealed that the spindle cells were strongly positive for CD34. The three patients demonstrated no significant issues during a two-year's follow-up without evidence of recurrence and metastasis. The current study additionally reviewed all reported DFML cases in the PubMed database and Chinese journals.

Introduction

Dendritic fibromyxolipoma (DFML) is a rare benign tumor that was first reported by Suster *et al* in 1998 (1). It consists of a mixture of small spindles to stellate cells and several mature fat cells. The stellate cells were embedded in an abundant myxoid stroma with strands of ropey collagen bundles. It shares similar morphologic features to other myxoid mesenchymal tumors, such as myxoid liposarcoma (MLS) and solitary fibrous tumor (SFT). In most reports, it is considered as a special variant of spindle cell lipoma (2). It is typically

present in the older age population with a male preponderance. Most of these tumors occurred in head and neck, chest wall, shoulder and back, and a few were located in limbs, including toes. They are often located in superficial fascia and occasionally in muscle (2). To the best of our knowledge, only 59 cases of DFML were reported and cited in PubMed and Chinese journals. In this study, we have described three DFML cases that were located in the limbs and thoracic cavity. Written informed consents have been obtained from these three patients.

Case presentation

Case 1. The patient was a 50-year-old male who presented with a painless right upper arm tumor mass for six years. In August 2012, he was admitted to Qingdao Municipal Hospital for the first time. Recently, the tumor was gradually growing. No other mass was found in other locations. The magnetic resonance imaging (MRI) showed a well-defined tumor mass measuring 79x46x100 mm in the right upper arm. It showed a mixed-signal intensity on both T1 and fat-suppression weighted imaging (Fig. 1A). The tumor was completely resected. Histopathologic evaluation showed that the tumor was composed of mature adipocytes with sparse slender spindle cells (Fig. 1B). The cellular atypia was not apparent. Strands of ropey collagen bundles within the myxoid background were noted (Fig. 1C). Immunohistochemical staining showed that the spindle cells were strongly positive for CD34 (Fig. 1D), but negative for CD99 and BCL-2. A diagnosis of DMFL was suggested. The patient was uneventful during a 12-month's follow-up without evidence of recurrence.

Case 2. The patient was a 33-year-old male. He was presented with a gradually growing right thigh mass for three years. In March 2014, he was admitted to Qingdao Municipal Hospital for the first time. It measured 3x3 cm, and it did not cause any local discomfort. The ultrasound revealed a subcutaneous well-defined hyperechoic mass, which suggested a lipoma (Fig. 2A). It was resected completely. Grossly, the tumor was lobulated with an intact capsule. The cut surface was yellowish and soft. Histopathologically, the tumor was composed of mature adipocytes and sparse spindle cells with a myxoid background (Fig. 2B and C). The tumor cells were positive for CD34 (Fig. 2D) and negative for CD99 and BCL-2.

Correspondence to: Dr Hua Chen, Department of Pathology, Qingdao Municipal Hospital, 5 Donghai Middle Road, Qingdao, Shandong 266071, P.R. China
E-mail: chenhua62@163.com

*Contributed equally

Abbreviations: DFML, dendritic fibromyxolipoma; MRI, magnetic resonance imaging; CT, computed tomography; FISH, fluorescence *in situ* hybridization; MLS, myxoid liposarcoma; MFS, myxofibrosarcoma; SFT, solitary fibrous tumor; LGFMS, low-grade fibrous myxoid sarcoma

Key words: dendritic fibromyxolipoma, spindle cell lipoma, immunohistochemistry

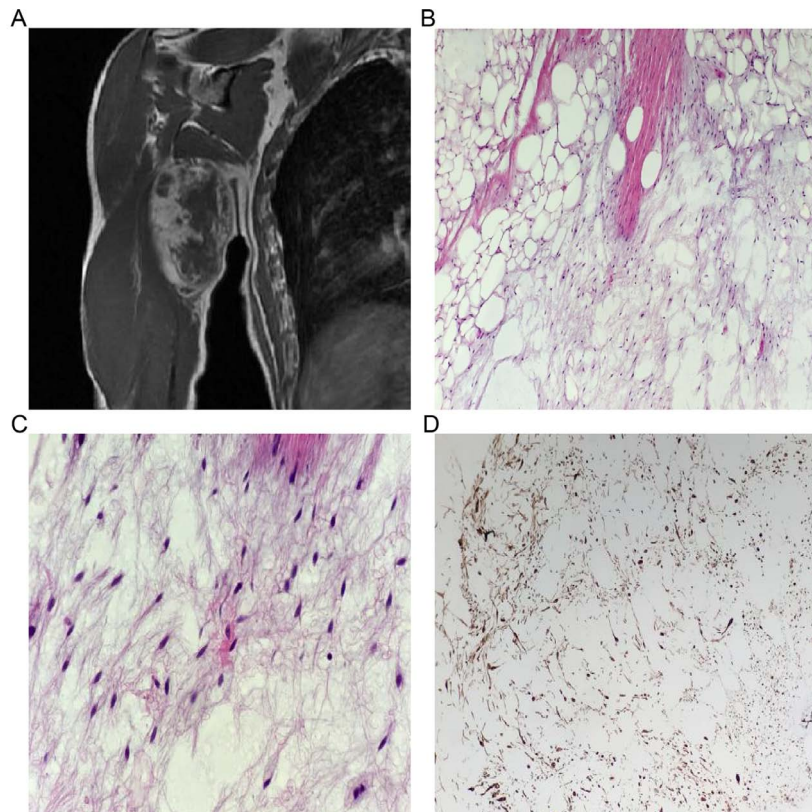


Figure 1. Case 1. (A) MRI revealing a homogeneous tumor mass in the right arm. (B) The tumor was composed of adipocytes and sparse slender spindle cells in a myxoid background (hematoxylin and eosin staining; magnification, x100). (C) Red collagen bundles were apparent under high power (hematoxylin and eosin staining; magnification, x400). (D) Immunohistochemistry staining revealed that the spindle cells were positive for CD34 (magnification, x100).

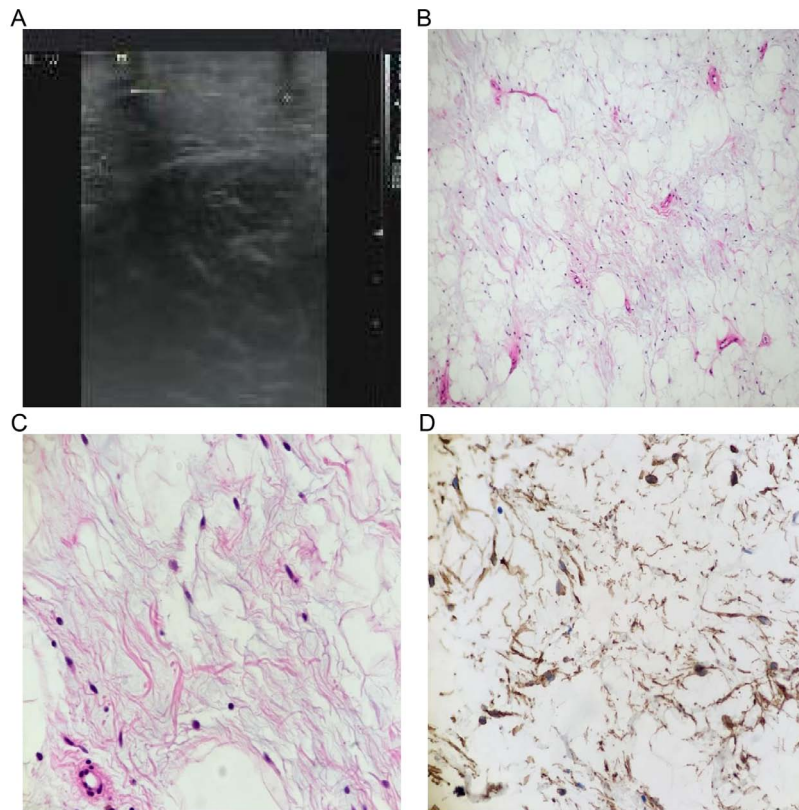


Figure 2. Case 2. (A) The tumor was composed of adipocytes in a myxoid background (hematoxylin and eosin staining; magnification, x100). (B) Slender spindle cells and red collagen bundles were observed under high power (hematoxylin and eosin staining; magnification, x400). (C) Red collagen bundles were apparent under high power (hematoxylin and eosin staining; magnification, x400). (D) Immunohistochemistry staining revealed that the spindle cells were positive for CD34 (magnification, x100).

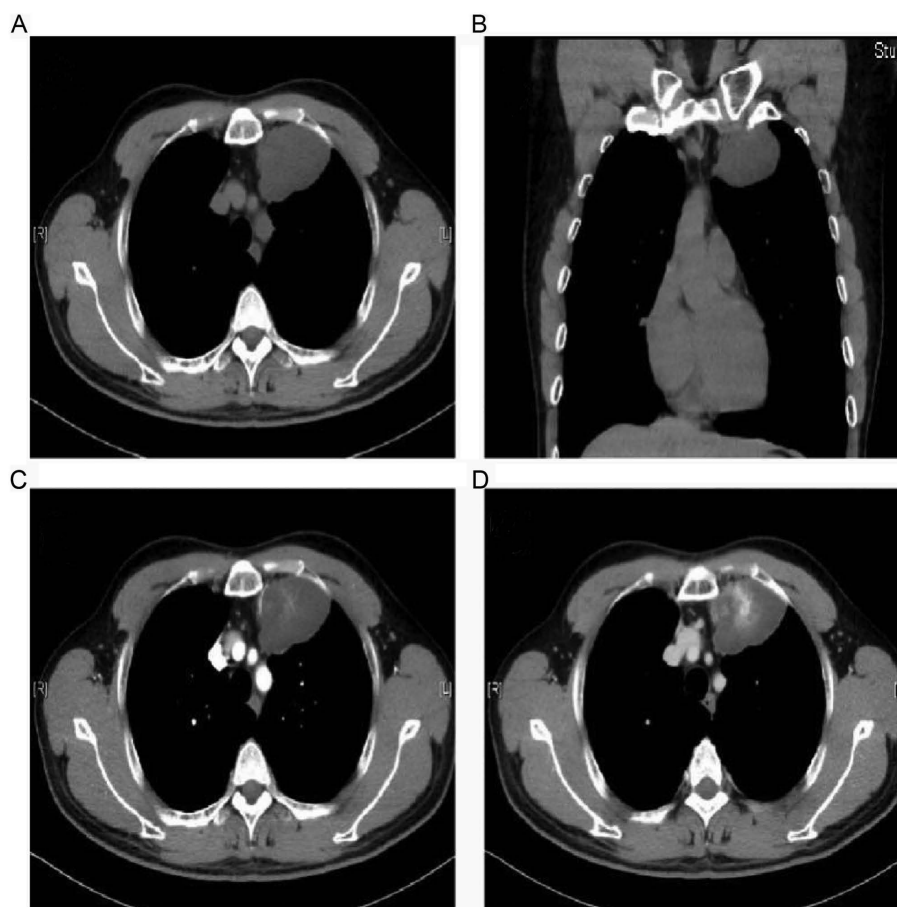


Figure 3. Case 3. (A and B) Radiological features of thoracic dendritic fibromyxolipoma on CT imaging. CT demonstrated a homogenous low-density shadow in the left thoracic cavity attaching to the anterior chest wall. It measured 43x60x36 mm with a well-defined boundary and was heterogeneously enhanced. The tumor center was enhanced more markedly in the (D) venous phase than the (C) arterial phase.

Case 3. The patient was a 48-year-old male who presented with a left thoracic tumor mass. He appeared asymptomatic, and the medical history was unremarkable. In July 2015, he was admitted to Qingdao Municipal Hospital for the first time. The tumor was incidentally observed during a routine physical examination. No other mass was found in other locations. The computed tomography (CT) showed a homogenous low-density mass in the left thoracic cavity beside the mediastinum. It measured 43x60x36 mm and had a well-defined boundary (Fig. 3A and B). The tumor center was heterogeneously enhanced, indicating the presence of blood vessels. The tumor center was enhanced more obviously in the venous phase (Fig. 3D) than the arterial phase (Fig. 3C). Considering the tumor location, a pleural SFT was suggested. In addition, a fine needle biopsy was performed, but as no adipocytes were observed, a pathologic diagnosis of myxoid subtype of SFT was made. The tumor was completely resected by video-assisted thoracic surgery. Histopathologic evaluation showed that the tumor predominantly comprised slender spindle cells embedded in an abundant myxoid stroma with strands of ropey collagen bundles (Fig. 4A and B). The cellular atypia was not apparent. Red collagen bundles were apparent under high power (Fig. 4C). Immunohistochemical staining showed that the spindle cells were strongly positive for vimentin and CD34 (Fig. 4D), but negative for BCL-2 (Fig. 4E), CD99, STAT6, S100, SMA and Desmin. The Ki-67 index was <1%.

Focal mature adipocytes were present within the myxoid background. In addition, a prominent delicate, arborizing vascular pattern was observed in some areas, which was similar to a MLS. However, the fluorescence *in situ* hybridization (FISH) analysis with the *DDIT3* break apart probe (ZytoLight; cat. no. Z-2100-200) showed negative *DDIT3* rearrangement (Fig. 4F). Therefore, a pathologic diagnosis of DFML was rendered. The patient was uneventful during a follow-up of 15 months without evidence of recurrence and metastasis.

Discussion

A literature search was performed in Pubmed, CNKI and Wanfang database to identify eligible studies published prior to October 9, 2019. Search terms were 'dendritic fibromyxolipoma' or 'DFML'. The inclusion criteria was: case report or case series on patients with DFML. The exclusion criteria was: articles that were reviews, comments, news, letters and that did not meet the inclusion criteria were excluded. Articles not in the English or Chinese language were also excluded. 20 studies were eligible involving 59 patients with DFML, including 48 males and 11 females (Table I).

DFML is an uncommon benign tumor that was initially described by Suster *et al* in 1998. A total of 12 cases were introduced in their report (1). Since then, a total of 47 additional cases have been reported and cited in PubMed and Chinese

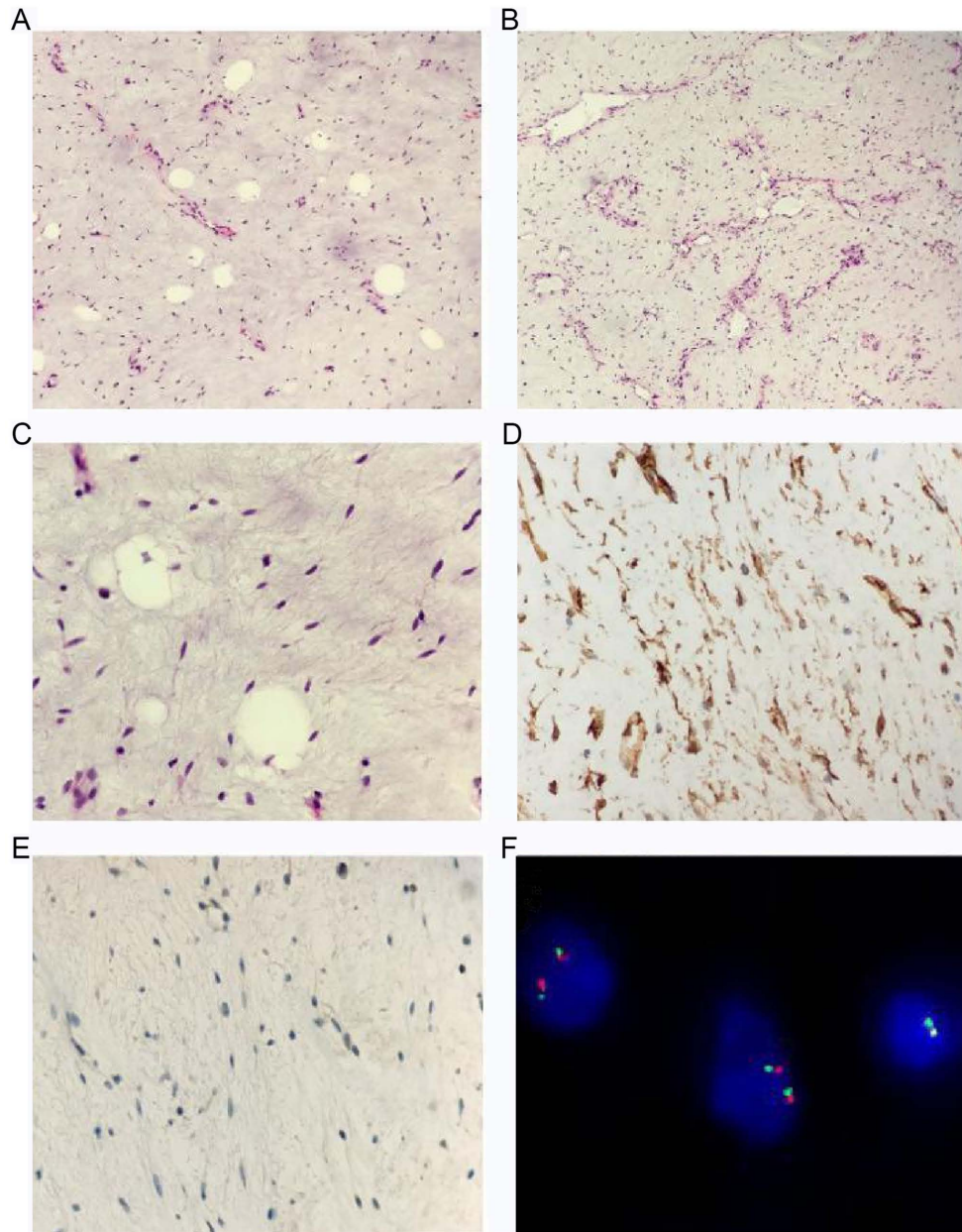


Figure 4. Case 3. Pathological features of thoracic dendritic fibromyxolipoma. (A and B) The tumor was composed of sparse spindle cells in a myxoid background. (A) Focal adipocytes and (B) delicate, arborizing blood vessels were abundant in some areas (hematoxylin and eosin staining; magnification, x100). (C) Red collagen bundles were apparent under high power (hematoxylin and eosin staining; magnification, x400). Immunohistochemistry staining revealed that spindle cells were (D) positive for CD34 (magnification, x100), but (E) negative for BCL-2 (magnification, x100). (F) Fluorescence *in situ* hybridization detection for DNA damage-inducible transcript 3 break apart was negative.

journals (Table I) (1-20). Although its incidence is relatively low, DFML can occur in almost all parts of the body, including the left inguinal region (15), hypopharynx (16), infraclavicular region (19), and other uncommon parts. The tumor develops primarily in the sub-cutis or muscular fascia. Among the 62 reported cases (including the current three cases), the age of patients ranges from 24 to 81 years with a male/female ratio of 51/11. The tumor size ranges from 1 to 24 cm, with an average of 8.2 cm. Gradually growing up mass without symptoms is the most common clinical manifestation. The medical history ranged from 1 month to 13 years. When the tumor is superficial, it often manifests as a painless tumor mass for several years. To the best of our knowledge, no more than 10 cases of DFML of extremities have been reported. The clinical presentations

and imaging features are rather non-specific, and the definite diagnosis relies on the histopathology. The differential diagnosis includes other myxoid mesenchymal tumors, for instance, MLS and SFT. When the blood vessels are abundant, and 'chicken-wire' like, or the fat component is not apparent, a diagnosis is rather difficult.

It has been reported that the 13q14.3 deletion, the hall marker of spindle cell lipoma, was detected in DFML. Thus, DFML is considered as a myxoid variant of spindle cell lipoma (2). It is mainly composed of mild spindle cells and unequal amounts of mature adipocytes. The spindle cells are small and deeply stained, without obvious atypia. The cytoplasm has long and narrow protrusions, which are dendritic. The mitotic figures are rare. According to a report, the bland spindle cells were

Table I. Clinical findings of 61 reported cases of dendritic fibromyxolipoma.

Author, year	Age, years	Sex	Presentations	Location	Size (cm)	Follow-up	(Refs.)
Suste <i>et al.</i> , 1998	33-81 (mean, 64)	11 Males; 1 Female	-	Head and neck region or the chest and back.	3-11	Seven cases with 2-13 years' follow-up	(1)
Tan and Wen, 2003	45-75 (mean, 65)	8 Males	-	Head and neck region, shoulder, back, calf and foot	2-9.5	Five cases with 0.5-3 years' follow-up	(3)
Karim <i>et al.</i> , 2003	73	Male	A painless mass	Right shoulder	13x8x5.5	-	(4)
Al-Maskery <i>et al.</i> , 2011	36	Female	A progressive painless swelling	Lower lip	2x1.6x2	2 years	(5)
Dahlin and Ljungberg, 2012	65	Female	Hypertension	Left volar forearm	2x3.2x1	3 years	(6)
Qiao <i>et al.</i> , 2012	39-67 (mean, 54)	9 Males; 1 Female	Painless subcutaneous nodules	Neck region, back and shoulder	1-6	13-27 months	(7)
Zhang <i>et al.</i> , 2013	32	Female	A painless subcutaneous mass for 3 years	Right inguinal and perineum	24x10.5x5	9 months	(8)
Wong <i>et al.</i> , 2014	67	Male	A gradually enlarging, painless left shoulder swelling for 1 year	Left shoulder	7	-	(2)
Han <i>et al.</i> , 2014	69	Male	A skin-colored lesion for 4 years	Nasal tip	1	-	(9)
Yuan <i>et al.</i> , 2014	33-81 (mean, 64)	3 Males	Gradually growing mass without symptoms	Neck region, back, and shoulder	3.7-8.6	2-16 months	(10)
Xu <i>et al.</i> , 2015	24	Male	A painless, slowly growing mass for 2 years	Left shoulder	14x8.5x8	4 years	(11)
Liu <i>et al.</i> , 2015	53	Male	A mass for 1 month	Right back	2x1.5x1.5	1 year	(12)
Guo <i>et al.</i> , 2015	45-80 (mean, 59)	3 Males	Local mass and pressure symptoms	Neck region, back, and shoulder	3-8	6-18 months	(13)
Song <i>et al.</i> , 2016	34	Female	A recurrent jaw tumor mass	Jaw	4x3x3	-	(14)
Ciloglu <i>et al.</i> , 2016	59	Female	A painless subcutaneous mass for 10 years	Left inguinal region	17x13x10	3 years	(15)
AlAbdulrahim and Arafah, 2016	38	Male	A progressive dysphagia for 1 year	Hypopharynx	3.4x3.4x2.8	-	(16)
Xiao <i>et al.</i> , 2017	38, 53	1 Male; 1 Female	A pain mass	Abdominal cavity	7 cm, 16	6-18 months	(17)
Li <i>et al.</i> , 2017	27-73 (mean, 50)	4 Males; 2 Females	A painless slowly growing mass	Shoulder, waist, back, thigh, iliac fossa and mesentery	2.5-18.5	Several months-several years	(18)
Ruiz Molina <i>et al.</i> , 2018	69	Male	A painless soft tissue mass for 8 years	Infralavicular region	5x1.7	2 years	(19)
Fu <i>et al.</i> , 2018	Mean 50	2 Males; 1 Female	-	Upper arm, shoulder and oral cavity	4-5.5	-	(20)

positive for CD34, vimentin and BCL-2. However, BCL-2 was not invariably positive in the present three cases, which had also been observed for two previous cases (6,11).

The tumor may be confused with other myxoid mesenchymal tumors. i) MLS and DFML: they may share a distinct myxoid background and mature adipocytes. They are easy to be confused, especially when the lesions occur in non-superficial sites (such as case 3). However, they can be distinguished from each other by histology, immunohistochemistry and molecular genetics (3,21,22). DFML is mostly located in the superficial tissues. Morphologically, DFML consists of abundant delicate, arborizing blood vessels and bland spindle or stellate-shaped cells in a myxoid with a collagenous matrix. The adipocytes were scattered, and definite lipoblasts were not identified. The short spindle cells were sparse and lacked atypia and mitosis. Thus, it may be somewhat difficult to make a definite diagnosis. In contrast, MLS occurs mostly in the deep soft tissues of the lower extremities. The tumor is mainly composed of three components: Adipocytes with different degrees of differentiation, myxoid stroma, and plexiform capillaries. In immunohistochemistry, CD34, BCL-2, and vimentin were expressed in DFML, but S-100 and Desmin were negative, while in MLS, the opposite result was found. In molecular genetics, 13q14.3 deletion exists in DFML, while *FUS-DDIT3* (>90%) or *EWSR1-DDIT3* (<5%) gene fusion exists in MLS (23). In case 3, the FISH detection for *FUS-DDIT3* was negative, and the immunohistochemistry for NY-ESO-1 (a specific immunomarker for MLS) was also negative. These results can rule out an MLS. Since 13q14.3 detection is an important biomarker for spindle cell lipoma (2), the lack of its detection is a limitation of this study. And the tissues obtained from the 3 patients were for the purposes of diagnosis only, not for testing novel biomarkers. The clinical history, histological morphology and immunohistochemistry were mainly used to identify these two diseases. ii) Myxofibrosarcoma (MFS) and DFML: in case 3, a possible diagnosis of MFS invading the pre-existing adipose tissues should be ruled out. The diagnosis of MFS mostly depends on the morphology, and immunohistochemistry may be not very helpful. MFS is a kind of malignant soft tissue tumor. The histologic features of MFS included the following: a commonly nodular growth pattern; a myxoid matrix containing elongated, curvilinear capillaries; and fusiform, round or stellate tumor cells with indistinct cell margins, slightly eosinophilic cytoplasm and hyperchromatic atypical nuclei. For the present case, it was well defined and had a clear boundary without involving the surrounding tissues. In addition, the adipocytes were evenly distributed and rather scattered. Thus, we believe the adipocytes were tumor components. Furthermore, the flow-up result also favors the diagnosis of a benign tumor. iii) Low-grade fibrous myxoid sarcoma (LGFMS) and DFML: The morphology of LGFMS is a vortex structure composed of fusiform fibroblast-like cells, and alternating collagen-like and myxoid regions are observed. In addition, arch vessels and perivascular hyalinosis can be seen. (4) Lipoblastoma and DFML: likewise, in addition to mucin-like interstitial and branched blood vessels, there are also fat vacuoles stellate and fusiform stromal cells. However, 90% of lipoblastomas occur in infants under three years of age, while DFML often occurs in middle-aged and older adults, and spindle cells are positive for CD34. (5) SFT: It can

undergo extensive myxoid degeneration, and the spindle cells are positive for STAT-6, CD99, CD34 and BCL-2. However, the mature fat component is absent.

DFML is a special subtype of spindle cell lipoma. Complete resection is the best treatment choice. A diagnostic pitfall is other myxoid mesenchymal tumors, such as LMS and LGFMS, which may lead to 'overtreatment.' The postoperative recurrence and metastasis are rare after complete resection. Only one recurrent case was reported until now (14).

Acknowledgements

Not applicable.

Funding

No funding was received.

Availability of data and materials

The datasets used and/or data analyzed during the present study are available from the corresponding author on reasonable request.

Authors' contributions

HL, SH and HC conceived the present study. JW, QZ, XY and HC performed the experiments. HL, SH, JW, QZ and XY wrote the manuscript. XY and HC critically reviewed the manuscript. All authors read and approved the final version of the manuscript.

Ethics approval and consent to participate

The present study was approved by the Ethics Committee of the Qingdao Municipal Hospital (approval no. 2020-049). All patients provided their written informed consent.

Patient consent for publication

All patients provided their consent for the publication of their data and associated images.

Competing interests

The authors declare that they have no competing interests.

References

1. Suster S, Fisher C and Moran CA: Dendritic fibromyxolipoma: Clinicopathologic study of a distinctive benign soft tissue lesion that may be mistaken for a sarcoma. *Ann Diagn Pathol* 2: 111-120, 1998.
2. Wong YP, Chia WK, Low SF, Mohamed-Hafiah NH and Sharifah NA: Dendritic fibromyxolipoma: A variant of spindle cell lipoma with extensive myxoid change, with cytogenetic evidence. *Pathol Int* 64: 346-351, 2014.
3. Tan GM and Wen P: Clinicopathologic features of dendritic fibromyxolipoma. *Zhonghua Bing Li Xue Za Zhi* 32: 404-408, 2003 (In Chinese).
4. Karim RZ, McCarthy SW, Palmer AA, Bonar SF and Scolyer RA: Intramuscular dendritic fibromyxolipoma: Myxoid variant of spindle cell lipoma? *Pathol Int* 53: 252-258, 2003.

5. Al-Maskery AY, Al-Sidairy SM and Al-Hamadani AS: Dendritic myxofibrolipoma: Often misdiagnosed as sarcoma. *Craniomaxillofac Trauma Reconstr* 4: 171-174, 2011.
6. Dahlin LB and Ljungberg O: Dendritic fibromyxolipoma adherent to the median nerve in the forearm. *J Plast Surg Hand Surg* 46: 120-123, 2012.
7. Qiao HG, Zhang C, Zhuang YL and Wang J: Dendritic fibromyxolipoma: A clinicopathological analysis of 10 cases. *J Clin Exp Pathol* 28: 1332-1335, 2012.
8. Zhang XJ, Zhou S, Nie K, Chen DF, Kui GJ and Zhang XH: Dendritic fibromyxolipoma in the right inguinal and perineum regions: A case report and review of the literature. *Diagn Pathol* 8: 157, 2013.
9. Han XC, Zheng LQ and Shang XL: Dendritic fibromyxolipoma on the nasal tip in an old patient. *Int J Clin Exp Pathol* 7: 7064-7067, 2014.
10. Yuan XX, Yuan JP, Yang YH, Yin YB and Luo B: Clinicopathological characteristics of dendritic fibromyxolipoma in muscle: An analysis of 3 cases. *J Diagn Pathol* 21: 1, 2014.
11. Xu X, Xiong W, Zheng L and Yu J: Intramuscular dendritic fibromyxolipoma in a 24-year-old male: A case report and review of the literature. *Oncol Lett* 9: 583-586, 2015.
12. Liu S, Wang X, Lei B, Ma H, Li J, Guo D and Xu S: Dendritic fibromyxolipoma in the latissimus dorsi: A case report and review of the literature. *Int J Clin Exp Pathol* 8: 8650-8654, 2015.
13. Guo WW, Huang WQ, Kong QN and Han ZL: Clinicopathologic analysis of dendritic fibromyxolipoma. *J Clin Pathol Res* 35: 622-626, 2015.
14. Song L, Wang Z, Xu JW and Qin YJ: Dendritic fibromyxolipoma of jaw: Report of a case. *Zhonghua Bing Li Xue Za Zhi* 45: 276-277, 2016 (In Chinese).
15. Ciloglu S, Duran A, Keskin E and Yigit A: Dendritic fibromyxolipoma of left inguinal region. *Indian J Pathol Microbiol* 59: 250-251, 2016.
16. AlAbdulsalam A and Arafah M: Dendritic fibromyxolipoma of the pyriform sinus: A case report and review of the literature. *Case Rep Pathol* 2016: 7289017, 2016.
17. Xiao XW, Zhang LF, Li WS and Liu Y: Clinicopathological characteristics of dendritic fibromyxolipoma in abdominal cavity: An analysis of two cases. *Diagn Pathol* 24: 7, 2017.
18. Li YQ, Ma Q, Chen Y, Tang Y and Qian ZH: Dendritic fibromyxolipoma: A clinicopathologic analysis of 6 cases and review of the literature. *J Clin Pathol Res* 37: 527-530, 2017.
19. Ruiz Molina I, Solis Garcia E and Civico Amat V: Dendritic infraclavicular fibromyxolipoma: At the boundary between spindle cell lipoma and solitary fibrous tumour. *Rev Esp Patol* 51: 44-48, 2018 (In Spanish).
20. Fu WL, Tang XF and Guo QN: A Clinicopathologic study of dendritic fibromyxolipoma. *Med J West China* 30: 503-506, 2018.
21. Abaricia S and Hirbe AC: Diagnosis and treatment of myxoid liposarcomas: Histology matters. *Curr Treat Options Oncol* 19: 64, 2018.
22. Hei SM, Wei HJ, Chen H and Wang JG: Pathological significance of NY-ESO-1 expression in the diagnosis of myxoid liposarcoma. *Zhonghua Bing Li Xue Za Zhi* 48: 225-230, 2019 (In Chinese).
23. Yu JS, Colborne S, Hughes CS, Morin GB and Nielsen TO: The FUS-DDIT3 interactome in myxoid liposarcoma. *Neoplasia* 21: 740-751, 2019.



This work is licensed under a Creative Commons Attribution-NonCommercial-NoDerivatives 4.0 International (CC BY-NC-ND 4.0) License.