

Histopathological Change of Oral Malignant Tumour and Epithelial Dysplasia Subjected to Photodynamic Therapy

Masataka Uehara¹, Hisazumi Ikeda¹, Mihoko Nonaka¹, Izumi Asahina¹

¹Department of Regenerative Oral Surgery, Unit of Translational Medicine, Graduate School of Biomedical Sciences, Nagasaki University, Nagasaki, Japan.

Corresponding Author:

Masataka Uehara
1-7-1 Sakamoto, 852-8588, Nagasaki
Japan
Phone: +81-95-819-7704
Fax: +81-95-819-7705
E-mail: uehara@nagasaki-u.ac.jp

ABSTRACT

Objectives: The purpose of this study is to analyze the morphological change of cell nuclei and the change of proliferating activity of oral malignancy and epithelial dysplasia between before and after photodynamic therapy in order to predict recurrence.

Material and Methods: We experienced 14 cases of oral squamous cell carcinoma, one case of verrucous carcinoma and seven cases of epithelial dysplasia treated by photodynamic therapy (PDT). The mean nuclear area (NA) and coefficient of variation of the nuclear area (NACV) of 100 nuclei per slide were calculated using computer-assisted image analysis in hematoxylin and eosin stained biopsy specimens before and after PDT. Additionally, proliferating cell nuclear antigen (PCNA) immunohistochemistry was carried out in each specimen.

Results: The mean NA after PDT was significantly lower than that before PDT in the nonrecurrent group. However, there was no significant difference in mean NA before and after PDT in the recurrent group. There were no significant differences in NACV before and after PDT in either the nonrecurrent or recurrent group. Furthermore, the PCNA labelling indices of the specimens after PDT was significantly lower than that before PDT in both the nonrecurrent and the recurrent group.

Conclusions: Mean nuclear area in the biopsy specimen after photodynamic therapy is likely to be a predictive marker for the recurrence of oral squamous cell carcinoma or epithelial dysplasia subjected to photodynamic therapy, while coefficient of variation of the nuclear area and proliferating cell nuclear antigen labelling indices are less helpful in predicting the recurrence of such lesions.

Keywords: photodynamic therapy; squamous cell carcinoma; epithelial cells; carcinoma, verrucous; cell nucleus; proliferating cell nuclear antigen.

Accepted for publication: 16 July 2010

To cite this article:

Uehara M, Ikeda H, Nonaka M, Asahina I. Histopathological Change of Oral Malignant Tumour and Epithelial Dysplasia Subjected to Photodynamic Therapy.

J Oral Maxillofac Res 2010 (Jul-Sep);1(3):e5

URL: <http://www.ejomr.org/JOMR/archives/2010/3/e5/e5ht.pdf>

doi: [10.5037/jomr.2010.1305](https://doi.org/10.5037/jomr.2010.1305)

INTRODUCTION

Photodynamic therapy (PDT) consists of the administration of a photosensitizer that localizes in malignant or premalignant lesions because of its relative selectivity, followed by light irradiation. PDT uses the localized delivery of light to activate the photosensitizer [1,2]. As PDT is a useful therapy for oral lesions because of the accessibility of light to the lesions, it has been applied to oral malignant and premalignant lesions [3-6]. However, the recurrence of tumours after PDT despite a good initial response remains problematic [7-9]. In a previous study, we pointed out the heterogeneous susceptibility of mouse tumours to PDT anti-tumour effects [10]. Furthermore, we also found that the nuclear area (NA) and coefficient of variation of the nuclear area (NACV) as well as proliferating cell nuclear antigen (PCNA) of tumour cells are useful indicators in assessing the effect on tumour of PDT [11,12].

We present here 14 cases of oral squamous cell carcinoma (SCC), one case of verrucous carcinoma and 7 cases of oral epithelial dysplasia (ED), which were clinically diagnosed as leukoplakia, treated by PDT. No biopsy, taken from 4 to 9 weeks after PDT, produced evidence of residual tumour. However, 5 cases of SCC and one case of ED recurred 4 to 30 months after PDT. The biopsy specimens before and after PDT were investigated using morphological analyses of the tumour and ED cell nuclei as well as PCNA immunohistochemistry in order to clarify the correlation between the histopathological changes of lesions after PDT and during recurrence.

MATERIAL AND METHODS

Patients and PDT

Twenty patients were diagnosed with 22 lesions having one or more histologically proven SCC, verrucous carcinoma or ED of the oral cavity (Table 1). All lesions were diagnosed as stage I or II (T1 or T2 N0M0) SCC, verrucous carcinoma or ED, and no deep extension to underlying muscle or bone was identified by the clinical, histological or radiological findings. None of the patients had received prior treatment. Informed consent and ethical committee of Nagasaki University approval was obtained in each case.

Photofrin® (Axcan Pharma, Birmingham, AL, USA) at a dose of 2 mg/kg [3,5] was given by intravenous infusion 48 hours prior to surface laser irradiation. An excimer dye laser was used to deliver monochromatic red light at 630 nm. An optical fiber was applied to

irradiate the targeted oral lesions. A light dose of 100 - 200 J/cm² was delivered to each area. The patients were counselled to avoid direct sunlight for six weeks following sensitization. Treated areas were biopsied to confirm the effects of PDT 2 to 9 weeks after laser irradiation.

A complete response was defined as the disappearance of all known disease at least 4 weeks after PDT.

Computer-assisted image analysis of cell nuclei

The cell nuclei of lesions were examined with computer-assisted image analysis (Macintosh Image 1.62 on a Power Book G4, Apple Computer, Cupertino, CA, USA) for quantitative measurement of the nuclear areas. Three fields of randomly sampled hematoxylin and eosin stained biopsy specimens were photographed using a Coolpix 4500 digital camera (Nikon, Tokyo, Japan) at 65x magnification. After saving the captured image in a personal computer, 100 nuclei per slide were measured and the nuclear area was calculated (Figure 1). The mean nuclear area (NA) and standard deviation (SD) of NA were calculated. The NA and SD of each specimen were aggregated. The coefficient of variation of the nuclear area (NACV) was calculated as the objective parameter of anisonucleosis by the following formula: $NACV (\%) = (SD \text{ of } NA) / (\text{mean } NA) \times 100$ [13].

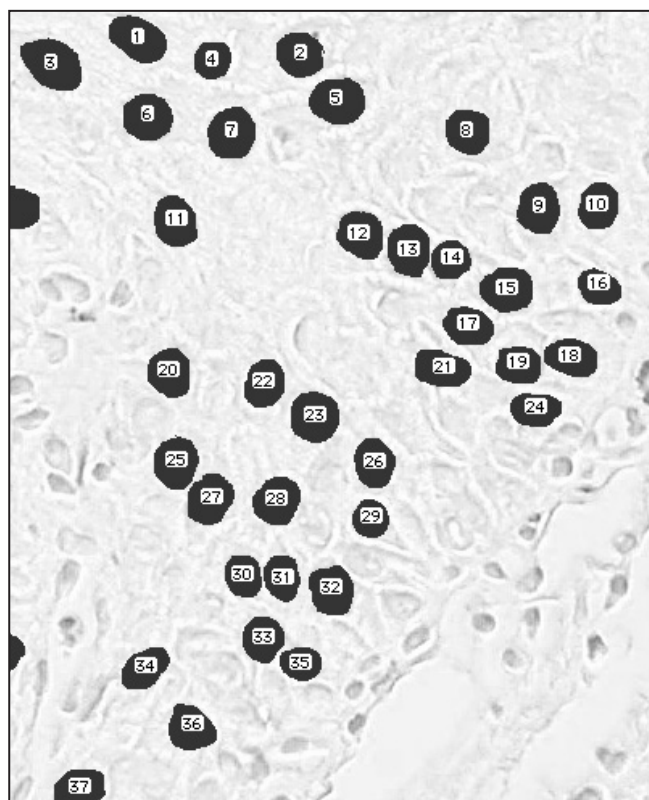


Figure 1. Computer-assisted image analysis of lesion cell nuclei (hematoxylin and eosin stain, original magnification x65).

PCNA immunohistochemistry

Four μm sections were prepared for each specimen, mounted on poly L-lysine-coated glass slides, and dried overnight on a hot plate at 37 °C to promote adhesion. Endogenous peroxidase was inhibited by treatment with 0.3% H_2O_2 in methanol for 30 min. After three washes in phosphate-buffered saline (PBS), the sections were incubated with diluted normal blocking serum for 30 min. Anti-PCNA monoclonal mouse antibody (PC10, 1 : 100 diluted, DAKO M0897, Denmark) was applied for 30 min at room temperature, followed by diluted biotinylated secondary antibody for 30 min, and ABC reagent for 30 min using a Vectastain Elite ABC Kit (Vector Laboratories, Burlingame, CA, USA). PBS was used instead of anti-PCNA antibody as a negative control.

The PCNA labelling index (LI) of the lesion cells was determined. Both the labelled and unlabelled lesion cells were counted with the aid of a squared eyepiece graticule (Nikon, Tokyo, Japan) in square fields (0.0625 mm^2) at a magnification of 400x. The PCNA LI of the lesion cells was defined as the percentage of PCNA-positive cells in 1000 lesion cells counted from four randomly selected fields.

Statistical analysis

Statistical analysis was performed using the Mann-Whitney U-test for the NA of biopsy specimens between before and after PDT in each case. Paired t-test was also used for statistical comparison of the mean NA and NACV in biopsy specimens before and after PDT in both the nonrecurrent and recurrent group. Differences between values before and after PDT were considered statistically significant if P values were less than or equal to 0.05.

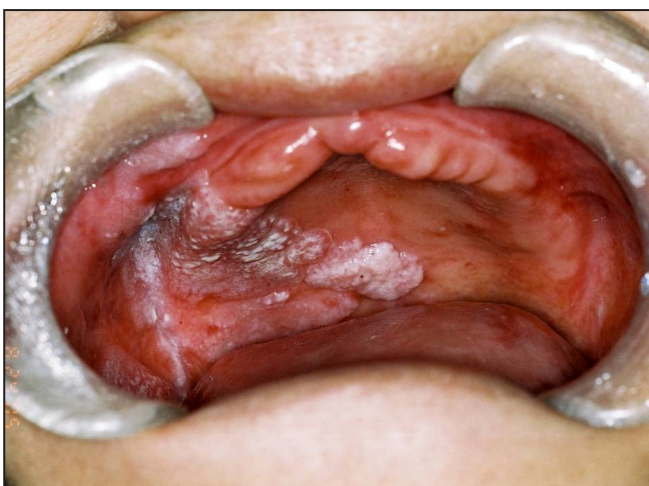


Figure 2. Case 16 before PDT.

RESULTS

A complete response was achieved in all cases (Figures 2 and 3). Stomatitis was observed for one or two weeks after PDT in all cases. However, other severe adverse side effects were not observed in all cases. Furthermore, no evidence of residual tumour was found in biopsy specimen 4 to 9 weeks after PDT in cases 1 to 13. Case 1, 2, 3-i, 4, 5 and case 17 developed recurrent lesions at the treatment site 4 to 30 months after PDT. These were treated with surgical excision or repeat PDT. The histological diagnosis of each case is shown in Table 1. The mean NAs before PDT were from 54.1 to 158.8 μm^2 (median = 91.4 μm^2 , SD = 23.0 μm^2), and those after PDT were from 24.6 to 106.8 μm^2 (median = 66.5 μm^2 , SD = 21.7 μm^2). Furthermore, medians of mean NAs before PDT were 92.4 μm^2 (SD = 23.5 μm^2) and 88.5 μm^2 (SD = 23.2 μm^2) in nonrecurrent group and recurrent group, respectively. In cases 1 and 3-i, the mean NAs after PDT were significantly larger than those before PDT. In cases 2, 3-ii, 3-iii, 7 and 19, there was no significant difference in mean NA before and after PDT. In cases 4, 5, 6, 8-18 and 20, the mean NAs after PDT were significantly smaller than those before PDT (Table 1). In the nonrecurrent group, the mean NA after PDT was significantly lower than that before PDT (Figure 4A; $P = 0.026$), although there was no significant difference in mean NA before and after PDT in the recurrent group (Figure 4B; $P = 0.5938$).

The mean NACV before PDT was 36.4% (from 15.8 to 58.1%, SD = 9.6%), and that after PDT was 31.3% (from 19.5 to 54.3%, SD = 9.7%) in the nonrecurrent group (Figure 5A), while that before PDT was 32.0% (from 19.9 to 38.6%, SD = 7.0%) and that after PDT was 28.6% (from 22.8 to 34.8%, SD = 4.2%) in the recurrent group (Figure 5B).

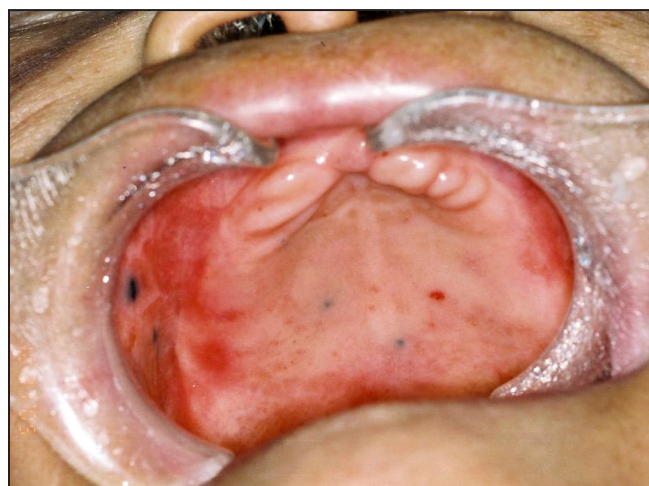

Figure 3. Case 16, 6 weeks after PDT. Tattoos show margin of tumour.

Table 1. Nuclear changes of oral lesions epithelial cells before and after photodynamic therapy

Case (Age, Sex)	Site of lesions (TNM classification)	Histological diagnosis (pre-PDT/post-PDT)	Mean of NA (μm^2 ; pre-PDT/post-PDT)	NACV (%; pre-PDT/post-PDT)	PCNA LI (%; pre-PDT/post-PDT)	Follow-up or recurrent term	Recurrence
1 (56, F)	tongue (T2N0M0)	SCC/ED, moderate	57.7/82.2 ^a	28.4/27.0	20.5/20.0	30 months	+
2 (90, F)	buccal mucosa (T2N0M0)	SCC/ED, moderate	105.2/106.8	19.9/27.4	17.2/16.7	15 months	+
3 (69, F)	i) lt. buccal mucosa (T1N0M0)	SCC/ED, severe	60.4/97.0 ^a	32.5/22.8	36.3/20.7	11 months	+
	ii) rt. lower gingiva (T1N0M0)	SCC/gingivitis	93.7/96.5	36.2/54.3	27.3/25.1	37 months	-
	iii) rt. buccal mucosa (T1N0M0)	SCC/ED	90.2/85.4	44.6/26.6	22.7/7.7	37 months	-
4 (83, M)	hard palate (T2N0M0)	SCC/stomatitis	108.8/84.3 ^a	38.6/27.4	44.0/21.1	15 months	+
5 (70, M)	oral floor (T2N0M0)	SCC/stomatitis	95.2/65.8 ^a	37.3/32.1	22.5/10.8	4 months	+
6 (63, F)	tongue (T2N0M0)	SCC/ED, moderate	87.8/40.2 ^a	32.1/36.7	19.8/16.6	44 months	-
7 (80, F)	hard palate (T1N0M0)	SCC/stomatitis with moderate ED	66.0/64.6	43.7/19.5	41.9/18.8	24 months	-
8 (85, F)	upper gingival (T2N0M0)	SCC/gingivitis	95.6/63.1 ^a	34.2/25.8	52.7/17.0	22 months	-
9 (75, M)	buccal mucosa (T1N0M0)	SCC/sialadenitis	127.2/24.6 ^a	43.9/43.6	16.0/21.0	20 months	-
10 (74, F)	lower gingival (T1N0M0)	SCC/gingivitis	82.3/53.8 ^a	32.1/29.9	12.5/3.8	15 months	-
11 (78, F)	lower gingival (T1N0M0)	SCC/gingivitis	97.8/59.7 ^a	58.1/40.4	19.6/11.9	18 months	-
12 (76, M)	Tongue (T2N0M0)	SCC/glossitis	96.0/81.1 ^b	39.7/27.5	25.0/5.3	18 months	-
13 (66, M)	lower gingival (T3N0M0)	verrucous carcinoma/ED, severe	158.8/35.0 ^a	41.6/35.3	26.7/16.4	10 months	-
14 (72, M)	tongue	ED, moderate/ED, mild	54.1/41.6 ^a	35.9/32.0	49.9/41.7	19 months	-
15 (29, F)	tongue	ED, mild/glossitis	87.1/71.2 ^a	27.2/39.3	17.1/22.0	19 months	-
16 (79, F)	hard palate	ED, mild /ED, mild	81.9/51.7 ^a	15.8/21.0	25.3/17.9	30 months	-
17 (65, F)	tongue	ED, severe/glossitis	103.5/43.7 ^a	35.6/34.8	19.1/13.7	30 months	+
18 (61, M)	soft palate	ED/stomatitis with mild ED	82.6/59.7 ^a	39.6/23.9	43.5/37.5	33 months	-
19 (70, F)	buccal mucosa	ED, moderate/ED, mild	82.2/80.2	26.2/22.2	35.4/37.1	16 months	-
20 (67, M)	tongue	ED, mild/glossitis	95.6/74.0 ^a	31.7/22.5	35.0/47.0	7 months	-

^aExistence of statistically significant differences, $P < 0.0001$.

^bExistence of statistically significant differences, $P < 0.0243$.

F = female; M = male; SCC = squamous cell carcinoma; ED = epithelial dysplasia; NA = nuclear area; NACV = coefficient of variation of the nuclear area; PCNA LI = proliferating cell nuclear antigen labelling index; PDT = photodynamic therapy.

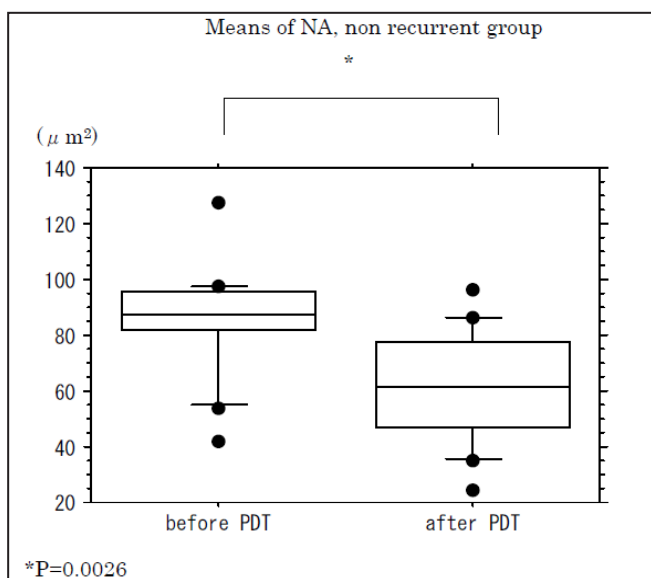


Figure 4A. Mean nuclear area (NA) in nonrecurrent group. There was significant difference in mean NA before and after PDT ($P = 0.0026$).

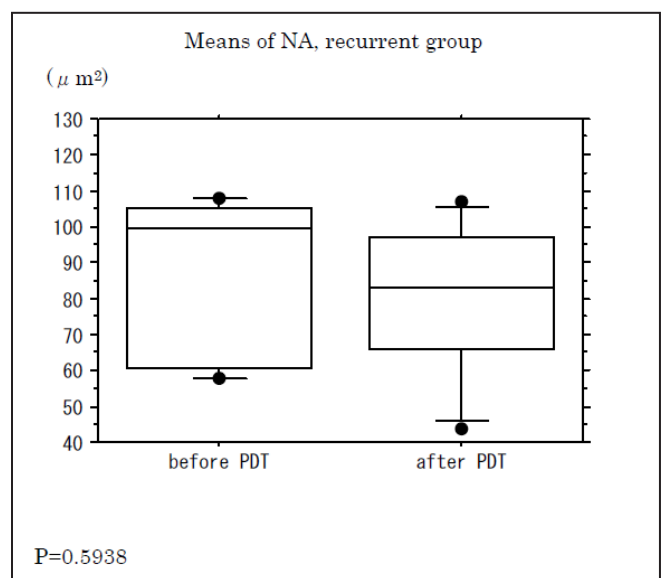


Figure 4B. Mean nuclear area (NA) in recurrent group. There was no significant difference in mean NA before and after PDT ($P = 0.5983$).

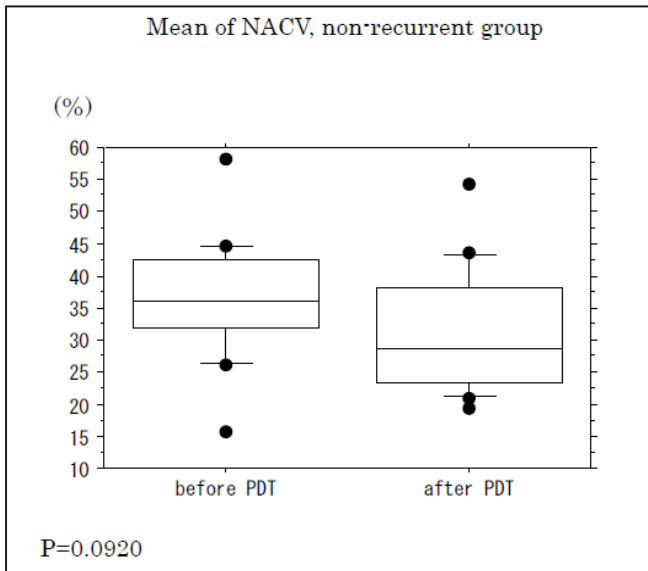


Figure 5A. Mean coefficient of variation of the nuclear area (NACV) in nonrecurrent group. There was no significant difference in mean NACV before and after PDT ($P = 0.0920$).

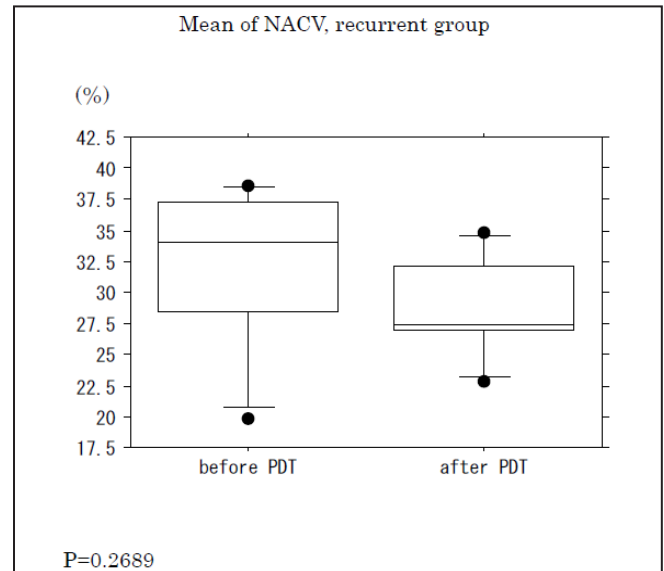


Figure 5B. Mean coefficient of variation of the nuclear area (NACV) in recurrent group. There was no significant difference in mean NACV before and after PDT ($P = 0.2689$).

The mean NACV after PDT tended to be lower than that before PDT in the nonrecurrent group, although the difference was not significant ($P = 0.0920$).

PCNA-positive cells were distinguished as the brown-stained nuclei in immunohistochemical staining. The mean PCNA LI before PDT was 30.3% (from 12.5 to 52.7%, $SD = 12.3\%$), and that after PDT was 22.5% (from 3.8 to 47.0%, $SD = 13.0\%$) in the nonrecurrent group (Figure 6A), while that before PDT was 24.3% (from 17.2 to 44.0%, $SD = 10.9\%$) and that after PDT was 15.0% (from 10.8 to 21.1%, $SD = 4.2\%$) in the recurrent group (Figure 6B). There were significant differences in PCNA LI values before and after PDT

in the both the nonrecurrent and the recurrent group ($P = 0.0188$ in nonrecurrent group, $P = 0.0496$ in recurrent group).

DISCUSSION

Morphological change in the nuclei is a useful marker for assessing the effects of radiotherapy [14] and chemotherapy [15,16]. With regard to specific PDT effects, plasma membranes are the most important targets [17,18], and mitochondria are also critical targets [19,20]. In our previous study, we also clarified

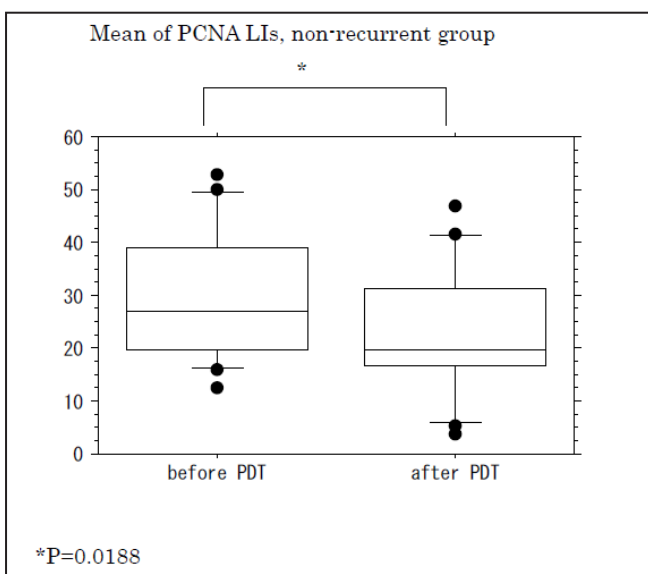


Figure 6A. Mean proliferating cell nuclear antigen (PCNA) labeling indices (LIs) in nonrecurrent group. There was a significant difference in mean PCNA LIs before and after PDT ($P = 0.0188$).

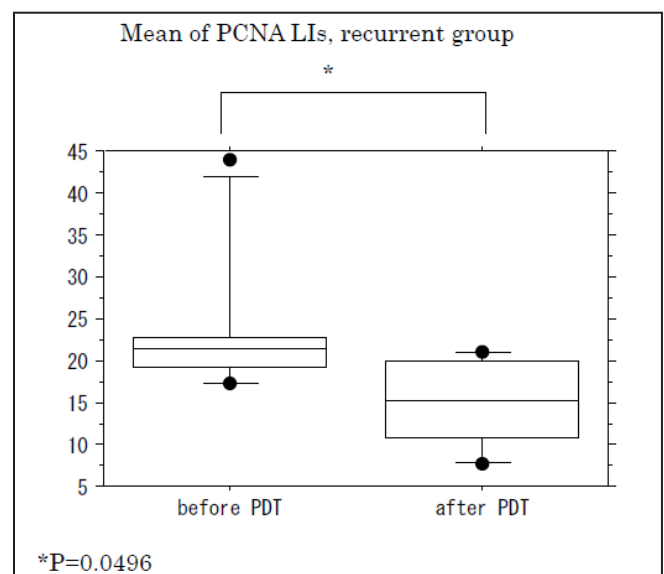


Figure 6B. Mean proliferating cell nuclear antigen (PCNA) labeling indices (LIs) in recurrent group. There was a significant difference in mean PCNA LIs before and after PDT ($P = 0.0496$).

that the morphological change of mouse tumour cell nuclei subjected to PDT was available to assess the anti-tumour effects of PDT [11]. In the present human study, the mean NA after PDT significantly decreased compared to that before PDT in the nonrecurrent group while this difference was not significant in the recurrent group. PDT induces DNA fragmentation in some cell lines [21], and may induce the reduction of cell nuclei after PDT. Accordingly, it was speculated that when PDT targets cells whose nuclei are barely susceptible to PDT, there is a risk of recurrence. NACV is also useful for objectively evaluating nuclear pleomorphism [13,22]. The significant reductions of NACV reflect the morphologic alterations of tumour nuclei with narrow dispersion of their size, and the value increases with the malignant potential of the lesion [13]. In a previous study, we experimentally demonstrated that the reduction of NACV reflects the anti-tumour effects of PDT to some extent [11]. However, in this study there was no significant difference in mean NACV before and after PDT in either group, although NACV after PDT was lower than that before PDT in the nonrecurrent group ($P = 0.0920$). On the other hand, the mean PCNA LI after PDT was significantly lower than that before PDT in the both the nonrecurrent and recurrent group. PCNA synthesis occurs in the latter part of G1 and throughout the S-phase, predominantly increasing in the S-phase [23], while the photosensitivity of cells increases during the G1 to mid-S-phase [1]. Accordingly, the significant decrease of PCNA LI after PDT may have resulted from susceptibility to PDT in the PCNA-positive tumour cells. These results are likely to be indicative

that NACV and PCNA LI are not predictive markers for tumour recurrence after PDT.

The primary advantage of PDT is that minimal damage is caused to healthy tissue, and PDT can be applied repeatedly at the same site because the laser used in PDT is nonthermal. However, targets are generally superficial or early-stage lesions [24]. In order to apply PDT to advanced lesions, or to have a better prognosis, fractionated laser irradiation [25,26] and adjuvant chemotherapies [26,27] should be made available. Furthermore, secondary PDT is likely to be indicated in cases which have no significantly reduced mean NA in the biopsy specimen after PDT, even if there is no evidence of residual tumour.

CONCLUSIONS

The non-reduction of nuclear area after photodynamic therapy may predict a possibility of recurrence of oral malignancy and epithelial dysplasia, although further investigations on more examples will be required to precisely predict the recurrence of oral malignancy and epithelial dysplasia.

ACKNOWLEDGMENTS AND DISCLOSURE STATEMENTS

The authors report no conflicts of interest related to this study.

REFERENCES

1. Moan J, Pettersen EO, Christensen T. The mechanism of photodynamic inactivation of human cells in vitro in the presence of haematoporphyrin. *Br J Cancer*. 1979 Apr;39(4):398-407. [Medline: [220998](#)] [[FREE Full Text](#)]
2. Dougherty TJ, Gomer CJ, Weishaupt KR. Energetics and efficiency of photoinactivation of murine tumor cells containing hematoporphyrin. *Cancer Res*. 1976 Jul;36(7 PT 1):2330-3. [Medline: [1277138](#)]
3. Hopper C. Photodynamic therapy: a clinical reality in the treatment of cancer. *Lancet Oncol*. 2000 Dec;1:212-9. Review. [Medline: [11905638](#)] [doi: [10.1016/S1470-2045\(00\)00166-2](#)]
4. Hopper C, Kübler A, Lewis H, Tan IB, Putnam G. mTHPC-mediated photodynamic therapy for early oral squamous cell carcinoma. *Int J Cancer*. 2004 Aug 10;111(1):138-46. [Medline: [15185355](#)] [doi: [10.1002/ijc.20209](#)]
5. Schweitzer VG, Somers ML. PHOTOFRIN-mediated photodynamic therapy for treatment of early stage (Tis-T2N0M0) SqCCa of oral cavity and oropharynx. *Lasers Surg Med*. 2010 Jan;42(1):1-8. [Medline: [20077493](#)] [doi: [10.1002/lsm.20881](#)]
6. Rigual NR, Thankappan K, Cooper M, Sullivan MA, Dougherty T, Popat SR, Loree TR, Biel MA, Henderson B. Photodynamic therapy for head and neck dysplasia and cancer. *Arch Otolaryngol Head Neck Surg*. 2009 Aug;135(8):784-8. [Medline: [19687399](#)] [[FREE Full Text](#)]
7. Wile AG, Novotny J, Mason GR, Passy V, Berns MW. Photoradiation therapy of head and neck cancer. *Am J Clin Oncol*. 1984 Feb;7(1):39-43. [Medline: [6695852](#)] [doi: [10.1097/00000421-198402000-00005](#)]
8. Schuller DE, McCaughan JS Jr, Rock RP. Photodynamic therapy in head and neck cancer. *Arch Otolaryngol*. 1985 Jun;111(6):351-5. [Medline: [4004631](#)]

9. Grossweiner LI, Hill JH, Lobraico RV. Photodynamic therapy of head and neck squamous cell carcinoma: optical dosimetry and clinical trial. *Photochem Photobiol.* 1987 Nov;46(5):911-7. [Medline: [3327063](#)] [doi: [10.1111/j.1751-1097.1987.tb04868.x](#)]
10. Uehara M, Inokuchi T, Sano K, Pe MB. The anti-tumor effect of photodynamic therapy evaluated by bromodeoxyuridine immunohistochemistry. *Int J Oral Maxillofac Surg.* 1998 Jun;27(3):204-8. [Medline: [9662014](#)] [doi: [10.1016/S0901-5027\(98\)80011-8](#)]
11. Uehara M, Sekine J, Wang Z, Inokuchi T. Morphometric analysis of mouse tumor nuclei subjected to photodynamic therapy. *J Oral Maxillofac Surg.* 2005 Feb;63(2):244-6. [Medline: [15690295](#)] [doi: [10.1016/j.joms.2004.04.031](#)]
12. Uehara M, Inokuchi T, Sano K, Sekine J, Ikeda H. Cell kinetics of mouse tumour subjected to photodynamic therapy--evaluation by proliferating cell nuclear antigen immunohistochemistry. *Oral Oncol.* 1999 Jan;35(1):93-7. [Medline: [10211316](#)] [doi: [10.1016/S1368-8375\(98\)00073-6](#)]
13. Nagashima T, Suzuki M, Oshida M, Hashimoto H, Yagata H, Shishikura T, Koda K, Nakajima N. Morphometry in the cytologic evaluation of thyroid follicular lesions. *Cancer.* 1998 Apr 25;84(2):115-8. [Medline: [9570215](#)] [doi: [10.1002/\(SICI\)1097-0142\(19980425\)84:2<115::AID-CNCR8>3.3.CO;2-I](#)]
14. Francisco J, Pauwels O, Simon S, Gasperin P, Van Houtte P, Pasteels JL, Kiss R. Computer-assisted morphonuclear characterization of radiotherapy-induced effects in MXT mouse mammary adenocarcinomas surviving earlier radiotherapy. *Int J Radiat Oncol Biol Phys.* 1995 May 15;32(2):409-19. [Medline: [7751183](#)] [doi: [10.1016/0360-3016\(95\)00529-8](#)]
15. McCluggage WG, Lyness RW, Atkinson RJ, Dobbs SP, Harley I, McClelland HR, Price JH. Morphological effects of chemotherapy on ovarian carcinoma. *J Clin Pathol.* 2002 Jan;55(1):27-31. [Medline: [11825920](#)] [[FREE Full Text](#)]
16. McKelvie PA, Daniell M. Impression cytology following mitomycin C therapy for ocular surface squamous neoplasia. *Br J Ophthalmol.* 2001 Sep;85(9):1115-9. [Medline: [11520767](#)] [doi: [10.1136/bjo.85.9.1115](#)] [[FREE Full Text](#)]
17. Denstman SC, Dillehay LE, Williams JR. Enhanced susceptibility to HPD-sensitized phototoxicity and correlated resistance to trypsin detachment in SV40 transformed IMR-90 cells. *Photochem Photobiol.* 1986 Feb;43(2):145-7. [Medline: [3010344](#)] [doi: [10.1111/j.1751-1097.1986.tb09506.x](#)]
18. Kessel D. Sites of photosensitization by derivatives of hematoporphyrin. *Photochem Photobiol.* 1986 Oct;44(4):489-93. [Medline: [2947252](#)] [doi: [10.1111/j.1751-1097.1986.tb04697.x](#)]
19. Hotta S, Kashimura H, Hirai S, Nakahara A, Fukutomi H, Osuga T, Uchiyama Y. Immediate changes in subcellular structures of transplanted tumors following photodynamic and laser hyperthermic therapy. *Lasers Surg Med.* 1995;16(3):262-71. [Medline: [7791500](#)] [doi: [10.1002/lsm.1900160308](#)]
20. Hilf R, Murant RS, Narayanan U, Gibson SL. Relationship of mitochondrial function and cellular adenosine triphosphate levels to hematoporphyrin derivative-induced photosensitization in R3230AC mammary tumors. *Cancer Res.* 1986 Jan;46(1):211-7. [Medline: [3940191](#)] [[FREE Full Text](#)]
21. Agarwal ML, Clay ME, Harvey EJ, Evans HH, Antunez AR, Oleinick NL. Photodynamic therapy induces rapid cell death by apoptosis in L5178Y mouse lymphoma cells. *Cancer Res.* 1991 Nov 1;51(21):5993-6. [Medline: [1933862](#)] [[FREE Full Text](#)]
22. Nagashima T, Suzuki M, Yagata H, Hashimoto H, Shishikura T, Imanaka N, Nakajima N. Cytomorphometric differentiation of intraductal proliferative breast lesions. *Breast Cancer.* 2000 Jan;7(1):43-7. [Medline: [11029770](#)] [doi: [10.1007/BF02967187](#)]
23. Morris GF, Mathews MB. Regulation of proliferating cell nuclear antigen during the cell cycle. *J Biol Chem.* 1989 Aug 15;264(23):13856-64. [Medline: [2569465](#)] [[FREE Full Text](#)]
24. Biel MA. Photodynamic therapy in head and neck cancer. *Curr Oncol Rep.* 2002 Jan;4(1):87-96. Review. [Medline: [11734119](#)] [doi: [10.1007/s11912-002-0053-8](#)]
25. Uehara M, Inokuchi T, Sano K, ZuoLin W. Expression of vascular endothelial growth factor in mouse tumours subjected to photodynamic therapy. *Eur J Cancer.* 2001 Nov;37(16):2111-5. [Medline: [11597392](#)] [doi: [10.1016/S0959-8049\(01\)00243-X](#)]
26. Uehara M, Inokuchi T, Ikeda H. Enhanced susceptibility of mouse squamous cell carcinoma to photodynamic therapy combined with low-dose administration of cisplatin. *J Oral Maxillofac Surg.* 2006 Mar;64(3):390-6. [Medline: [16487799](#)] [doi: [10.1016/j.joms.2005.11.011](#)]
27. Uehara M, Sano K, Wang ZL, Sekine J, Ikeda H, Inokuchi T. Enhancement of the photodynamic antitumor effect by streptococcal preparation OK-432 in the mouse carcinoma. *Cancer Immunol Immunother.* 2000 Oct;49(8):401-9. [Medline: [11043846](#)] [doi: [10.1007/s002620000134](#)]

To cite this article:

Uehara M, Ikeda H, Nonaka M, Asahina I. Histopathological Change of Oral Malignant Tumour and Epithelial Dysplasia Subjected to Photodynamic Therapy.

J Oral Maxillofac Res 2010 (Jul-Sep);1(3):e5

URL: <http://www.ejomr.org/JOMR/archives/2010/3/e5/e5ht.pdf>

doi: [10.5037/jomr.2010.1305](https://doi.org/10.5037/jomr.2010.1305)

Copyright © Uehara M, Ikeda H, Nonaka M, Asahina I. Accepted for publication in the JOURNAL OF ORAL & MAXILLOFACIAL RESEARCH (<http://www.ejomr.org>), 16 July 2010.

This is an open-access article, first published in the JOURNAL OF ORAL & MAXILLOFACIAL RESEARCH, distributed under the terms of the [Creative Commons Attribution-Noncommercial-No Derivative Works 3.0 Unported License](https://creativecommons.org/licenses/by-nc-nd/3.0/), which permits unrestricted non-commercial use, distribution, and reproduction in any medium, provided the original work and is properly cited. The copyright, license information and link to the original publication on (<http://www.ejomr.org>) must be included.