

## Case Report

# Lemierre's Syndrome Due to Malignant Otitis Externa: Imaging Studies Revealed Its Systemic Dissemination

Manabu Ogi, Kuniyuki Takahashi, Yuka Morita, Arata Horii

Department of Otolaryngology, Head and Neck Surgery, Niigata University Graduate School of Medical and Dental Sciences, Niigata, Japan

ORCID iDs of the authors: M.O. 0000-0001-7956-6397; K.T. 0000-0001-7577-7728; Y.M. 0000-0002-0306-0530; A.H. 0000-0002-6036-0492

Cite this article as: Ogi M, Takahashi K, Morita Y, Horii A. Lemierre's syndrome due to malignant otitis externa: imaging studies revealed its systemic dissemination. *J Int Adv Otol.* 2021; 17(5): 461-464.

Lemierre's syndrome is characterized by internal jugular vein thrombosis and systemic septic embolism; it is a fatal complication of upper respiratory tract infections. To date, it has not been demonstrated how the upper respiratory tract inflammation spreads from the primary infection site to internal jugular vein and systemic thrombosis. We report a very rare case of Lemierre's syndrome derived from malignant otitis externa in which the spread of infection and thrombosis process were identified by imaging. A 61-year-old man with severe diabetes mellitus visited our hospital with consciousness disturbance and right posterior neck pain. He complained of right ear pain and otorrhea several days prior to the neck pain. Contrast-enhanced computed tomography demonstrated thrombosis in internal jugular vein and multiple lung abscesses. Temporal bone images revealed continuous lesions from skull base osteomyelitis to suboccipital abscess and sigmoid sinus thrombosis. We diagnosed the patient as having Lemierre's syndrome secondary to skull base osteomyelitis following malignant otitis externa. The patient clinically recovered with a combination of drainage of suboccipital abscess and long-term administration of antibiotics, which is the standard treatment of malignant otitis externa. Considering the details of imaging and bacterial examination is very useful for understanding the pathophysiology and determining appropriate treatment in Lemierre's syndrome pathophysiology and determining appropriate treatment in Lemierre's syndrome.

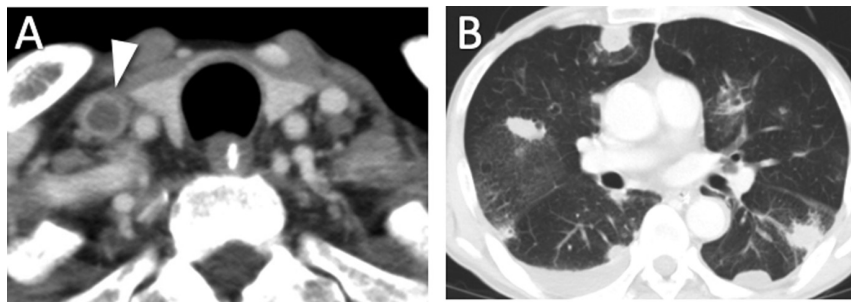
**KEYWORDS:** Lemierre's syndrome, malignant otitis externa, skull base osteomyelitis, *Klebsiella pneumoniae*

## INTRODUCTION

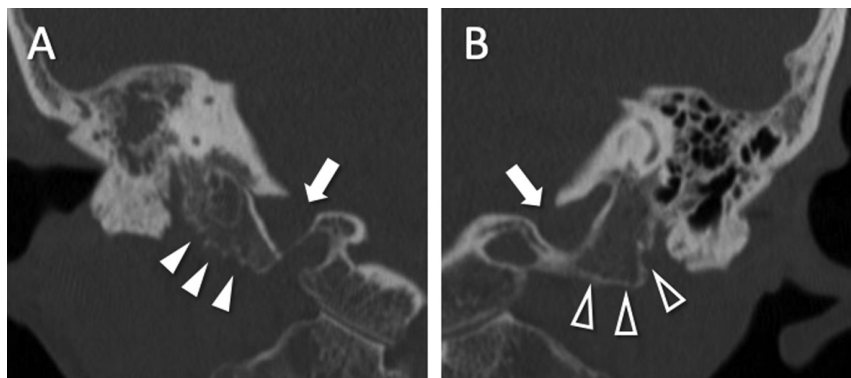
Lemierre's syndrome is a rare complication of head and neck infection which leads to septic thrombophlebitis in the internal jugular vein (IJV) with distant septic emboli.<sup>1</sup> The development of septic emboli may be life-threatening.<sup>2</sup> Pharyngitis is the most suspected infectious source of Lemierre's syndrome, as patients with this condition usually had a history of upper respiratory tract symptoms. To date, there have been no reports that identified the route of primary infection site to IJV and systemic thrombosis. We report a case of Lemierre's syndrome secondary to malignant otitis externa (MOE), in which the thrombosis process could be precisely demonstrated by imaging studies. Bacteriological findings, that is, detection of the same bacteria from local (otorrhea) and systemic (blood culture) specimens, also supported the same pathophysiology of local and systemic diseases.

## CASE PRESENTATION

A 61-year-old man with type 2 diabetes mellitus visited an emergency room of our hospital with complaints of loss of consciousness and right posterior neck pain. He had right ear pain and otorrhea several days prior to the neck pain. His body temperature was 40.8°C and his respiratory rate was 22/min. Laboratory data revealed high-grade inflammation (white blood cell count: 14 800/ $\mu$ L, C-reactive protein level: 30.35 mg/dL), marked thrombocytopenia (platelet count: 10 000/ $\mu$ L), disseminated intravascular coagulation state (prothrombin time-international normalized ratio: 1.41, activated partial thromboplastin time: 36.6 seconds (control: 27.6 seconds), fibrin level: 557 mg/dL, fibrinogen degradation product level: 16.8  $\mu$ g/mL, D-dimer level: 6.0  $\mu$ g/mL), and severe diabetes mellitus (hemoglobin A1C: 12.2%). Contrast-enhanced computed tomography (CT) demonstrated a thrombosis in the right IJV (Figure 1A) and multiple lung abscesses (Figure 1B). The emergency physician diagnosed him as having Lemierre's syndrome,



**Figure 1.** Contrast-enhanced CT of the neck (A) and the chest (B). Thrombus in the right IJV (arrowhead) (A) and multiple lung abscesses (B) were demonstrated. CT, computed tomography; IJV, internal jugular vein.

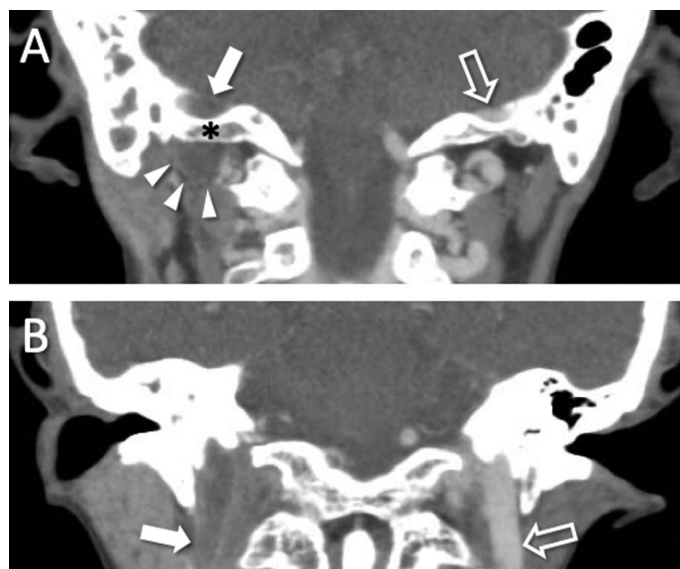


**Figure 2.** Coronal plane of thin-slice CT at the level of jugular foramen. (A) Coronal planes of CT showed that there was a disruption of cortical bone continuity (closed arrowhead) in the skull base just adjacent to jugular foramen (arrow) on the right side. This is the specific finding of osteomyelitis. (B) On the normal side (left), the cortical bone continuity is maintained (open arrowhead). CT, computed tomography.

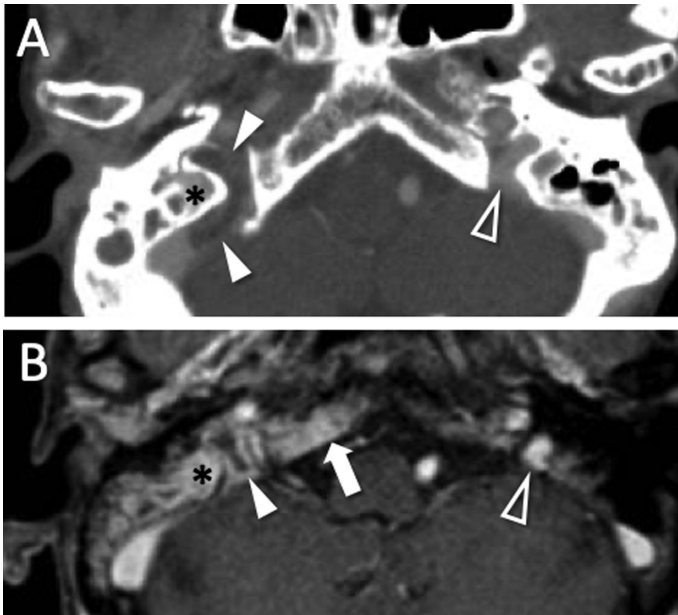
but the primary infection site could not be identified. Antibiotics (meropenem 3 g/day, clindamycin 1.8 g/day, and micafungin 150 mg/day), immunoglobulins, and anticoagulants (antithrombin III 1500 IU/day, heparin sodium 12 000 IU/day) were intravenously administered to the patient as empirical therapy.

Because the patient's right neck gradually became swollen despite empirical therapy, he was referred to the Otolaryngology Department. Otoscopy revealed an erosion in the right external auditory canal with otorrhea and effusion in the tympanic cavity. There was no post-auricular redness and auricular protrusion, which was characteristic of acute mastoiditis; moreover, there were no significant findings in the pharynx, larynx, and oral cavity. Temporal bone CT demonstrated soft tissue density in the right middle ear cavity and bone erosion in the skull base just adjacent to the jugular foramen (Figure 2). Coronal planes of contrast-enhanced CT images showed that there was an abscess immediately under the skull base, which is 5 mm posterior to the eroded portion in Figure 2, and a sigmoid sinus thrombus immediately over it (Figure 3A). The thrombus continued to IVJ, which was completely occluded (Figure 3B). Axial plane of contrast-enhanced CT demonstrated that the thrombus continued from sigmoid sinus to the IJV, which surrounded the skull base bone just above the abscess (Figure 4A). Magnetic resonance imaging (MRI) revealed a low-intensity area, which indicated the thrombus, and a well-enhanced lesion by gadolinium in the same skull base bone and the right half of the clivus (Figure 4B). These well-enhanced bone findings suggested that there was skull base osteomyelitis secondary to MOE. This series of CT and MRI images suggested that skull base osteomyelitis caused the thrombus in the sigmoid sinus and continuously led to the suboccipital abscess, which finally developed IJV thrombosis and multiple

lung abscess, commonly known as Lemierre's syndrome. *Klebsiella pneumoniae* was detected by the bacterial test of both otorrhea and blood culture.

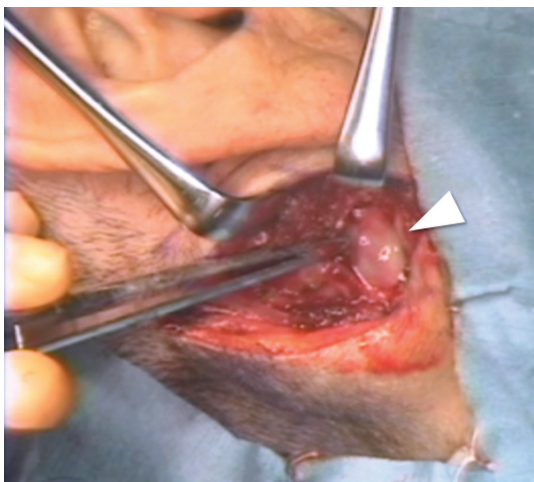


**Figure 3.** Coronal plane of contrast-enhanced CT. (A) Coronal planes of contrast-enhanced CT showed that there was an abscess (arrowhead) immediately under the skull base (asterisk) and sigmoid sinus thrombus immediately over it (arrow) on the right side. On the opposite normal side, the sigmoid sinus was homogeneously enhanced (open arrow). (B) The left IVJ (open arrow) was well enhanced, but the right IVJ (closed arrow) was not enhanced, which indicates complete occlusion. CT, computed tomography; IVJ, internal jugular vein.



**Figure 4.** Axial plane of contrast-enhanced CT and MRI. (A) The thrombus continued from sigmoid sinus to the IJV (closed arrowhead), which surrounded the skull base bone (asterisk) immediately above the abscess. Asterisk indicates the same part in Figure 3. The opposite normal side was homogeneously enhanced (open arrowhead). (B) MRI revealed a low-intensity area (closed arrowhead), which indicates the thrombus in the right IJV, and a well-enhanced lesion by gadolinium in the same skull base bone (asterisk) and the right half of the clivus (arrow). These well-enhanced bone findings suggested that there was skull base osteomyelitis. Open arrowhead on the left side indicates the normal IJV, which was well enhanced by contrast material. CT, computed tomography; IJV, internal jugular vein; MRI, magnetic resonance imaging.

We performed exploratory antrotomy and suboccipital abscess drainage. Though there was only serous exudate in the antrum, of which the bacterial culture was negative, copious pus discharged from the abscess (Figure 5). Bacterial test of the pus from the suboccipital abscess revealed the presence of *K. pneumoniae* as same as from the otorrhea and blood culture. Surgical drainage was quite effective, and the patient's general condition improved quickly. After the causative bacteria was found, the antibiotics were de-escalated to ceftriaxone 2 g/day, and the patient was discharged from the hospital



**Figure 5.** Intraoperative photograph of right cervical abscess drainage. Pus was found in the cavity under the occipital bone (arrowhead).

6 weeks after surgery. After discharge, oral levofloxacin 500 mg/day was subsequently administered to prevent MOE relapse for 13 weeks. An oral anticoagulant (warfarin 3 mg/day at initial dose, which was adjusted based on the coagulation status) was also administered during the same period. He is clinically recovered 8 months after the discharge.

## DISCUSSION

Lemierre's syndrome was first described by Courmont and Cade in 1900 and was further characterized by Lemierre in 1936.<sup>1,3</sup> Though Lemierre's syndrome was referred to as the "forgotten disease" after the emergence of antibiotics, a recent report has described an increasing incidence.<sup>4</sup> The mortality rate of patients with Lemierre's syndrome is improving, but it is still approximately 10%.<sup>2,4,5</sup> Therefore, prompt diagnosis and appropriate treatment including surgical intervention and administration of antibiotics and anticoagulant are essential to improve the mortality rate.

In previous reports, the etiology of Lemierre's syndrome is neither so conclusive nor definitive. There is a report showing that the main infection source in patients with Lemierre's syndrome was tonsil infection (37%), pharyngeal and upper respiratory tract infection (30%), chest and lower respiratory tract infection (25%), and middle ear and mastoid infection (2%).<sup>4</sup> However, these incidences were estimated from only a history of regional symptoms of each patient.<sup>6</sup> The temporal bone area is a rare infection source, and there are a few reports that MOE was suspected to be the cause of Lemierre's syndrome.<sup>7-10</sup> It had been formerly reported that MOE occurs by *Pseudomonas aeruginosa* in elderly diabetic patients. However, it is now considered that MOE is necrotizing otitis externa which is an opportunistic infection in immunosuppressive patients.<sup>11</sup> There are many reports of MOE causing cranial nerve palsy,<sup>12-14</sup> but only a few reports of vascular complications.<sup>15,16</sup> The pathophysiology of the intravenous thrombi formation caused by infection remains unclear; however, phlebitis due to direct contact with the infection source may be essential. The walls of the vein are composed of 3 main layers. The outer layer is connective tissue called tunica adventitia, the middle layer of smooth muscle is called the tunica media, and the inner layer lined with endothelial cells is called the tunica intima. Veins have a thinner tunica media than arteries, especially in the intracranial sinuses, they lack a tunica media. Therefore, once the inflammation affects the vein, it immediately spreads to the vascular endothelium. Damage to the vascular endothelium activates a coagulation cascade intravenously which leads to intravenous thrombosis.<sup>17</sup> In our case, it was considered that MOE spreads to the skull base bone followed by the suboccipital abscess and the sigmoid sinus phlebitis, which finally lead to the intravenous thrombosis and Lemierre's syndrome. The infection spread was clearly demonstrated by CT and MRI images.

Regarding the bacterial testing, *K. pneumoniae* was detected from not only systemic samples such as blood culture but also from local samples such as otorrhea and abscess; this confirms that the local ear disease (MOE) was causally related to the systemic disease (Lemierre's syndrome). The most common causative pathogen of Lemierre's syndrome is *Fusobacterium* species, followed by anaerobic streptococci and other miscellaneous gram-negative anaerobes.<sup>14</sup> In contrast, MOE is usually caused by *Pseudomonas aeruginosa*.<sup>11,18</sup> The occurrence of *K. pneumoniae* is not common in both Lemierre's syndrome

and MOE. It is frequently seen in infections of compromised host such as patients having diabetes, who are alcoholics and/or immunodeficient.<sup>19</sup> We believe that *K. pneumoniae*, present in the external auditory canal of the compromised host with non-treated severe diabetes,<sup>20</sup> caused Lemierre's syndrome.

## CONCLUSION

This is the first report of Lemierre's syndrome derived from MOE in which the spread of infection and thrombosis process were identified by imaging and bacterial studies. Since MOE was identified as the causative disease, the patient was cured by combination therapy of surgical drainage and long-term administration of antibiotics. Considering not only the patient's medical history and symptoms but also the details of imaging and bacterial examination is very useful for understanding the pathophysiology and determining appropriate treatment in Lemierre's syndrome.

**Informed Consent:** Informed consent was obtained from the patient who participated in this study.

**Peer Review:** Externally peer-reviewed.

**Author Contributions:** Concept – M.O., K.T.; Design – M.O., K.T.; Supervision – A.H.; Data Collection and/or Processing – M.O., K.T., Y.M.; Analysis and/or Interpretation – M.O., K.T., Y.M.; Literature Search – M.O.; Writing – M.O., K.T.; Critical Reviews – A.H.

**Conflict of Interest:** The authors have no conflict of interest to declare.

**Financial Disclosure:** The authors declared that this study has received no financial support.

## REFERENCES

1. Lemierre A. On certain septicemias due to anaerobic organisms. *Lancet*. 1936;227(5874):701-703.
2. Syed MI, Baring D, Addidle M, Murray C, Adams C. Lemierre syndrome: two cases and a review. *Laryngoscope*. 2007;117(9):1605-1610.
3. Courmont P, Cade A. Septico-pyemia simulating human plague caused by a bacillus anaerobic streptococci. *Arch Med Exp Anat Pathol*. 1900;12:393-418.
4. Karkos PD, Asrani S, Karkos CD, et al. Lemierre's syndrome: a systematic review. *Laryngoscope*. 2009;119(8):1552-1559.
5. Schubert AD, Hotz MA, Caversaccio MD, Arnold A. Septic thrombosis of the internal jugular vein: Lemierre's syndrome revisited. *Laryngoscope*. 2015;125(4):863-868.
6. Golpe R, Marín B, Alonso M. Lemierre's syndrome (necrobacillosis). *Postgrad Med J*. 1999;75(881):141-144.
7. Davidoss N, Ha JF, Anderson JR, Rodrigues S. Lemierre's syndrome: an unusual complication of otitis externa in a young, healthy female. *J Laryngol Otol*. 2015;129(suppl 1):S60-S62.
8. Lee SJ, Weon YC, Cha HJ, et al. A case of atypical skull base osteomyelitis with septic pulmonary embolism. *J Korean Med Sci*. 2011;26(7):962-965.
9. Hile LM, Gibbons MD, Hile DC. Lemierre syndrome complicating otitis externa: case report and literature review. *J Emerg Med*. 2012;42(4):e77-e80.
10. He J, Lam JC, Adlan T. Clival osteomyelitis and hypoglossal nerve palsy—rare complications of Lemierre's syndrome. *BMJ Case Rep*. 2015;2015.
11. Chandler JR. Malignant external otitis. *Laryngoscope*. 1968;78(8):1257-1294.
12. Damiani JM, Damiani KK, Kinney SE. Malignant external otitis with multiple cranial nerve involvement. *Am J Otol*. 1979;1(2):115-120.
13. Mani N, Sudhoff H, Rajagopal S, Moffat D, Axon PR. Cranial nerve involvement in malignant external otitis: implications for clinical outcome. *Laryngoscope*. 2007;117(5):907-910.
14. Chen CN, Chen YS, Yeh TH, Hsu CJ, Tseng FY. Outcomes of malignant external otitis: survival vs mortality. *Acta Otolaryngol*. 2010;130(1):89-94.
15. Baker A, Rizk H, Carroll W, Lambert P. Cervical internal carotid artery pseudoaneurysm complicating malignant otitis externa: first case report. *Laryngoscope*. 2015;125(3):733-735.
16. Miyabe H, Uno A, Nakajima T, et al. A case of skull base osteomyelitis with multiple cerebral infarction. *Case Rep Otolaryngol*. 2016;2016:9252361.
17. Takahashi K, Yamamoto Y, Ogi M, et al. A case of lateral sinus insufficiency with acute otitis media: early surgical intervention for prevention of lateral sinus thrombosis. *Auris Nasus Larynx*. 2015;42(6):492-495.
18. Hollis S, Evans K. Management of malignant (necrotizing) otitis externa. *J Laryngol Otol*. 2011;125(12):1212-1217.
19. Feldman C, Smith C, Levy H, et al. Klebsiella pneumoniae bacteraemia at an urban general hospital. *J Infect*. 1990;20(1):21-31.
20. Yang TH, Kuo ST, Young YH. Necrotizing external otitis in a patient caused by Klebsiella pneumoniae. *Eur Arch Otorhinolaryngol*. 2006;263(4):344-346.