



ELSEVIER

Contents lists available at [ScienceDirect](https://www.sciencedirect.com)

Trauma Case Reports

journal homepage: www.elsevier.com/locate/tcr

Case Report

Endoscopic management gunshot wound at the face: Fact or fiction?

Seyed Mojtaba Mirzadeh ^{*}

Department of Otolaryngology- Head and Neck Surgery, Otorhinolaryngology Research Center, Shahid Sadoughi University Of Medical Sciences, Yazd, Iran

ARTICLE INFO

Keywords:

Face injury
Shrapnel
Bullet
Surgery method
Wounds

ABSTRACT

Shrapnel or gunshot injuries in Maxillofacial Region are highly considered to be challenging which leads to death in most cases, and even in the case of no mortality, they will cause morbidity and appearance impairment due to complex injuries to bone and soft tissue. Herein, in a particular case, the patient was a person injured by a gunshot of a Kalashnikov's bullet in his face; the bullet was located at the end of the medial wall of the maxillary sinus and was removed through the functional endoscopy of the nose and sinuses. The bullet was removed without causing any additional incisions on the face and further damage through endoscopic ligation of severe bleeding from the sphenopalatine artery. The clinical approach to patients with penetrating trauma from a bullet to head and face demands prompt action. Functional endoscopic nasal and sinus surgery can maintain the patient's face cosmetic appearance.

Introduction

Head and face injuries are very significant regarding cosmetic appearance as well as functional issues. Due to the complex and sensitive structure of soft tissue as well as the facial skeleton, the damage to this area is different from other parts of the body [1]. In this regard, the impact of a bullet is one of the most important penetrating traumas. The actual estimate of bullet wounds to the face remains unclear. A retrospective study reported that for about 4100 bullet injuries cases, 6% of which involved the face and almost 80% of them were men, 11% of them died within the first 24 h [2].

A person with a penetrating trauma from a bullet to his/her head and face is expected to experience morbidity or mortality. Therefore, the clinical approach to such patients is sensitive and requires appropriate action. The extent of the effects caused by bullet injury depends on the type of weapon, its distance from the person, mass, and velocity of the bullet [3]. All of these factors cause varying degrees of skin and soft tissue defects, facial bone fractures, and damages to blood vessels and nerves.

Bullet wounds and damages can be divided into two types: low-velocity and high-velocity [2]. The hallmark for high-velocity bullet damages includes extensive tissue defects and complex fractures of the facial bones, cavities in the mouth, and severe vascular and nerve damage. But in the cases of low-velocity bullet damage, the severity of complications is less. However, in some cases, shrapnel from the bullet may hit the face, which in these cases, facial damage is inevitable.

^{*} Otolaryngology, Head and Neck Specialist, Floor one, Otorhinolaryngology Research Center, Shahid Sadoughi University, Shahid Bahonar Square, Yazd 8916978477, Iran.

E-mail address: mirmoji@yahoo.com.

<https://doi.org/10.1016/j.tcr.2021.100497>

Accepted 14 June 2021

Available online 25 June 2021

2352-6440/© 2021 Published by Elsevier Ltd. This is an open access article under the CC BY-NC-ND license

(<http://creativecommons.org/licenses/by-nc-nd/4.0/>).

Case presentation

The patient was a 50-year-old man who was brought to the emergency room after being hit by shrapnel from a Kalashnikov rifle in the lateral area of his right nose and cheek. The patient's level of consciousness was low (Glasgow coma scale score of 12/15). Skin and soft tissue defects and facial bones were evident. The shooting site was bleeding profusely. At the time of the patient's admission to the emergency room, the patient's airway was examined; his mouth and throat were full of blood, saliva, and soil, which were cleared immediately. The patient's oxygen level was equal to 88% at the time of admission.

Due to heavy bleeding and the patient's restlessness, and for preventing blood aspiration and loss of O₂ saturation, and ensuring a protected airway, the patient was intubated under the supervision of an emergency medicine specialist and anesthesiologist. Then, defected site was packed with sterile gauze, inside the nasal cavity was filled by a tampon, and bleeding was controlled. At the same time, two large blood vessels were taken from the patient by gray angiocath in the femoral region, and Ringer's serum was administered for the patient, while an emergency complete blood cell count test was done for the patient. A blood iso-group and iso-Rh reservation were also made.

When the general condition and vital signs of the patient were stabilized, a facial computed tomography (CT) scan without contrast was performed to further investigate the location of the bullet and estimate the severity of injury to the facial skeleton. CT scans showed bullet shrapnel in the medial wall of maxillary sinus near the sphenopalatine artery, as well as damage to the anterior maxillary sinus plate and right lacrimal bone (Fig. 1).

The patient was transferred to the operating room for definitive treatment and removal of the bullet. First, packed dressing on the wound was removed and a soft-tissue defect of the face was examined, and what was evident in the initial assessment was a 2*2 defect in the right facial area. Then, the initial nasal tampon was removed, and for controlling the patient's bleeding, a tampon impregnated with phenylephrine drop 5% was placed in the nasal cavity for 10 min.

Due to the great depth of the bullet inside the face and its location at the end of the medial wall of maxillary sinus regarding sphenopalatine artery damage, it was decided to use functional endoscopy of the nose and sinuses instead of making an incision by a scalpel to prevent further damage to the face and better control over bleeding. Phenylephrine tampon was removed from the nose after 10 min and the bullet was found through the endoscopic method and it was removed by Blakesley upturned (Fig. 2).

As expected, the sphenopalatine artery was damaged, and as soon as the bullet was removed blood jet was observed from the artery (Fig. 3). A phenylephrine-impregnated tampon was immediately repositioned into the nasal cavity, the bleeding site was packed and the bleeding was controlled. The tampon was removed after 10 min, the bleeding site was cauterized and it was completely controlled. Also, on endoscopic examination, the patient's septum was perforated, and the right middle turbine was damaged, all of which were repaired. The soft tissue defect of the patient was repaired with a delay and in two stages, using the bilobed flap. With the termination of anesthesia, the patient was extubated as a result of stability of vital signs and being ensured of the open airway, he regained his full consciousness and his oxygen saturation level was equal to 97%.

Discussion

Penetrating trauma to the face following a bullet wound occurs as a result of several causes including suicide, military actions, ethnic, and tribal-related accidents, or street fighting. Emergency services are rarely provided to this type of patient because most of the injured do not survive [4]. Both mass and velocity of the bullet have impacts on the amount of tissue damage. According to the following formula: $KE = \frac{1}{2} \text{mass} * \text{velocity}^2$, the effect of bullet velocity is much greater than mass, which means that increasing velocity doubles the damage, and increasing mass by the same amount causes damage. Also, the quality of viscoelastic tissue of the face

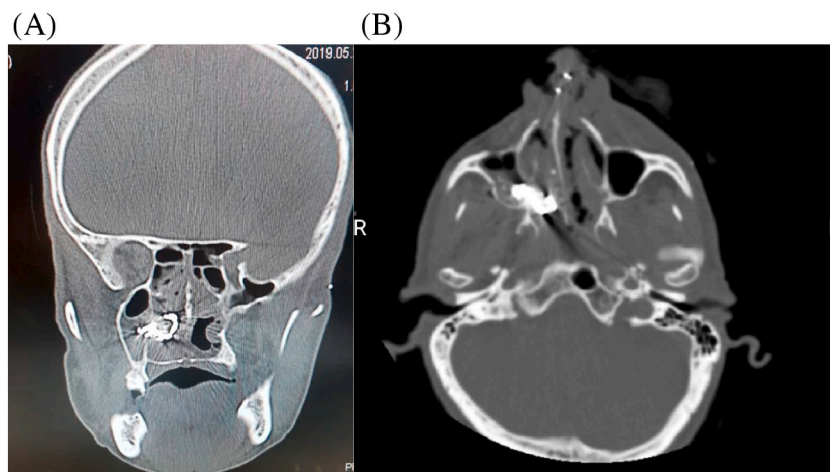


Fig. 1. CT scans show the bullet shrapnel in medial wall of maxillary sinus near the sphenopalatine artery, as well as damage to anterior maxillary sinus plate and right lacrimal bone. (A) Coronal view, (B) Axial view.

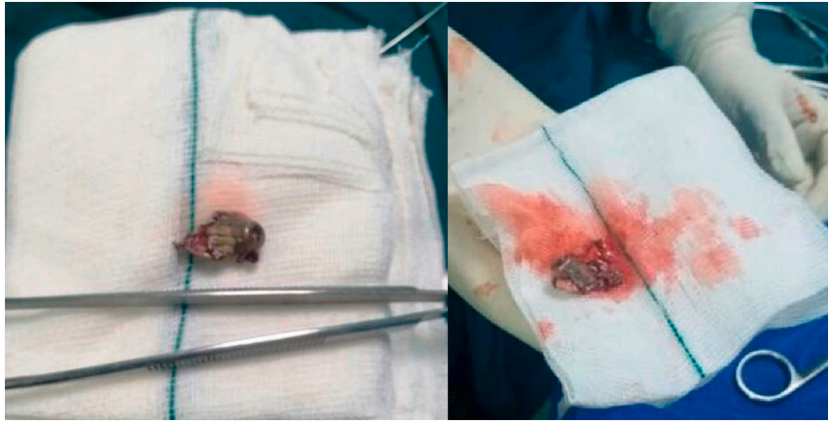


Fig. 2. Removal of the bullet and shrapnel from maxillary sinus and lacrimal bone.

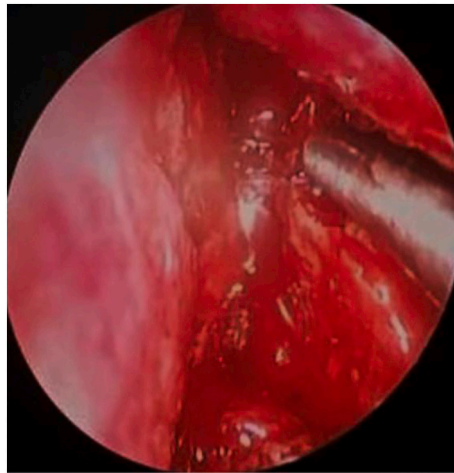


Fig. 3. The bullet was removed and blood jet was observed from the artery in endoscopic view.

has a significant effect on the injury in such a way that facial bone is fragmented due to its rigid structure, while the elasticity of the muscular and soft tissue is more compatible than the bone [2]. A cavity is created inside due to the impact of the bullet or shrapnel on the facial area, given special anatomy of which, it often enters the mouth or nasal cavity or sinuses, which turns it into a dirty wound [5].

Initial treatment of such patients in the emergency room is important. For these cases, the algorithmic advanced trauma life support (ATLS) protocol should be followed. There are four basic steps in managing the patients with bullet trauma into the face including 1- Airway control, 2- Bleeding control, 3- Finding other injuries, and 4- Repairing the defects. The function time threshold of the resuscitation team should be low for intubation and even tracheostomy. Owing to the density of blood vessels and the presence of important blood vessels, bleeding is high in these cases and action should be taken as soon as possible to control bleeding. Given the special structure and heavy bleeding, it is not possible to take a specific area by hand and squeezing it; thus, other measures such as packing the bleeding site inside the nose or cavity created by the bullet, and even angiography for embolization of bleeding vessel by a radiologist should be considered [6].

CT scan without contrast is the gold standard imaging method to determine the severity of the bullet damage and possibly the location of the shrapnel. The distance between the cuts should be one millimeter from the upper skull to the lower jaw. Both axial and coronal views are required. However, it should be noted that examination of dental and root canal injuries requires panoramic imaging. Surgery is performed when the patient's general condition is stabilized. At this time, the desired treatment is performed by the surgeon depending on the severity of the injury [2]. In our presented particular case, since the bullet was located inside the nasal cavity in the medial wall of the maxillary sinus and due to the possibility of bleeding after removal of the bullet, the surgeon decided to perform functional endoscopic nasal and sinus surgery to remove the bullet. Moreover, additional damage to the face due to incision and maxillectomy can be prevented by this method, and also if bleeding occurs inside the sinuses and cavities, it can be easily controlled.

Conclusion

Penetrating trauma from a bullet to head and face is expected to be associated with morbidity or mortality. Therefore, clinical approach to such patients is sensitive and demands prompt action.

In addition the cosmesis of the patient's face must be preserved. Functional endoscopic nasal and sinus surgery can prevent additional damage to the face due to incision and maxillectomy.

Funding acknowledgment

This study has not been government-sponsored. There are no Grants and Foundation Support.

Ethical approval

The study is exempt from ethical approval.

Consent

The patient's consent was obtained.

Declaration of competing interest

There is no conflict of interest.

Acknowledgment

The author would like to appreciate the contribution of all members of the team for managing and treatment of the patient.

References

- [1] V.S. Doctor, D.G. Farwell, Gunshot wounds to the head and neck, *urr. Opin. Otolaryngol. Head Neck Surg.* 15 (4) (2007) 213–218.
- [2] L. Hollier, E.P. Grantcharova, M. Kattash, Facial gunshot wounds: a 4-year experience, *J. Oral Maxillofac. Surg.* 59 (3) (2001) 277–282.
- [3] M. Peled, et al., Treatment protocol for high velocity/high energy gunshot injuries to the face, *Craniomaxillofac. Trauma Reconstr.* 5 (1) (2012) 31–40.
- [4] Y. Kaufman, P. Cole, L.H. Hollier, Facial gunshot wounds: trends in management, *Craniomaxillofac. Trauma Reconstr.* 2 (2) (2009) 85–90.
- [5] S.T. Shuker, Emergency treatment of blast, shell fragment and bullet injuries to the central midface complex, *J. Maxillofac. Oral Surg.* 18 (1) (2019) 124–130.
- [6] Y. Guruprasad, G. Giraddi, Unusual case of gunshot injury to the face, *J. Clin. Imaging Sci.* 1 (2011).