

## Case report

## A curious case of Lyme carditis in an urban hospital



Shantel Brissett<sup>a</sup>, Khaing T. Myint<sup>b</sup>, Yanira Lopez<sup>c</sup>, Farbod Raiszadeh<sup>d</sup>, Vel Sivapalan<sup>b</sup>, Damian Kurian<sup>d,\*</sup>

<sup>a</sup> Department of Internal Medicine, NYC Health & Hospitals | Harlem, New York, NY, United States

<sup>b</sup> Division of Infectious Diseases, NYC Health & Hospitals | Harlem, New York, NY, United States

<sup>c</sup> Department of Emergency Medicine, NYC Health & Hospitals | Harlem, New York, NY, United States

<sup>d</sup> Division of Cardiology, NYC Health & Hospitals | Harlem, New York, NY, United States

## ARTICLE INFO

## Article history:

Received 5 January 2021

Received in revised form 5 May 2021

Accepted 9 June 2021

## Keywords:

Lyme carditis

High-grade AV block

Transvenous pacemaker

Cardiology

Infectious diseases

## ABSTRACT

Lyme carditis (LC), a manifestation of early disseminated Lyme disease, most commonly presents with cardiac conduction abnormalities. It is a transient condition with good prognosis but in extremely rare cases may be life-threatening. We describe a 42-year-old man who presented with progressively worsening generalized weakness, presyncope and dyspnea on exertion for 2 weeks after sustaining a tick bite. He subsequently developed a 'bull's eye rash' on his flank 2 days before his presentation. He was found to have symptomatic third-degree AV conduction blockade with a ventricular escape rhythm resulting in a brief cardiac arrest. Intravenous (IV) ceftriaxone was commenced empirically and a temporary transvenous pacemaker was placed. In a few days he showed dramatic, rapid improvement; the pacemaker was removed, and the patient was discharged on oral doxycycline to complete a 24-day course. This case is unique due to its occurrence in an urban hospital where such cases are uncommon. Cardiac arrest, although brief in this case, is a rare occurrence. Lyme carditis was a surprise diagnosis in our hospital due to the patient's geographical dislocation during the COVID-19 pandemic.

© 2021 Published by Elsevier Ltd. This is an open access article under the CC BY-NC-ND license (<http://creativecommons.org/licenses/by-nc-nd/4.0/>).

## Background

Lyme diseases (LD) is a commonly reported vector-borne illness in the United States caused by the Gram-negative spirochete *Borrelia burgdorferi* which is transmitted by the deer tick *Ixodes scapularis*. It is a multiplex disease that is categorized into three stages based on clinical signs and symptoms: early localized stage, early disseminated stage, and late stage [1]. LC is an uncommon manifestation, occurring in up to 1% of all patients with LD [2]. An AV conduction abnormality is the most common presentation, with a third-degree heart block as the most severe and fatal form.

## Case presentation

A 42-year-old Caucasian male with no prior medical history presented to our emergency department in June with progressively worsening generalized weakness, presyncope and dyspnea on exertion for 2 weeks. The patient recalled a tick bite two weeks

prior in upstate NY where had been quarantining from the New York City COVID-19 pandemic. He noted an erythematous rash with central pallor on his left flank that appeared 2 days prior to presentation.

In the emergency department, the patient was diaphoretic and appeared anxious. He was afebrile, but had marked bradycardia at 30 beats per minute and hypotension. A 'bull's eye rash' was noted on his back extending to his left flank. An electrocardiogram (ECG) revealed a third-degree AV block with ventricular escape rhythm (Fig. 1). Asystole was also noted on telemetry leading to a transient loss of consciousness. Cardiopulmonary resuscitation followed by transcutaneous pacing led to restoration of hemodynamic stability. Empiric IV ceftriaxone was commenced and patient was transferred to the cardiac care unit where a transvenous pacemaker was immediately placed. Post procedure EKG showed 100 % ventricular capture (Fig. 2).

Troponin I was unremarkable. Enzyme-linked immunosorbent assay (ELISA) with antibody titer positive of 11.50 to *B. burgdorferi* followed by Western blot showed presence of both IgG and IgM Lyme bands (Tables 1 and 2). He was also tested for COVID-19 PCR that was negative. An ECG the next day showed transition to a first-degree heart block (P-R interval of 330 ms), heart rate of 78 beats per minute with narrow-complex QRS and diffuse ST-T wave abnormalities, likely due to cardiac memory (Fig. 3). The

Abbreviations: LC, Lyme carditis; LD, Lyme disease; AV, atrioventricular; ECG, electrocardiogram; IV, intravenous; MS, millisecond.

\* Corresponding author at: Harlem Hospital Center, MLK Room 15-102, 506 Lenox Avenue, New York, NY, 10037, United States.

E-mail address: [Damian.Kurian@nychhc.org](mailto:Damian.Kurian@nychhc.org) (D. Kurian).

<http://dx.doi.org/10.1016/j.idcr.2021.e01179>

2214-2509/© 2021 Published by Elsevier Ltd. This is an open access article under the CC BY-NC-ND license (<http://creativecommons.org/licenses/by-nc-nd/4.0/>).

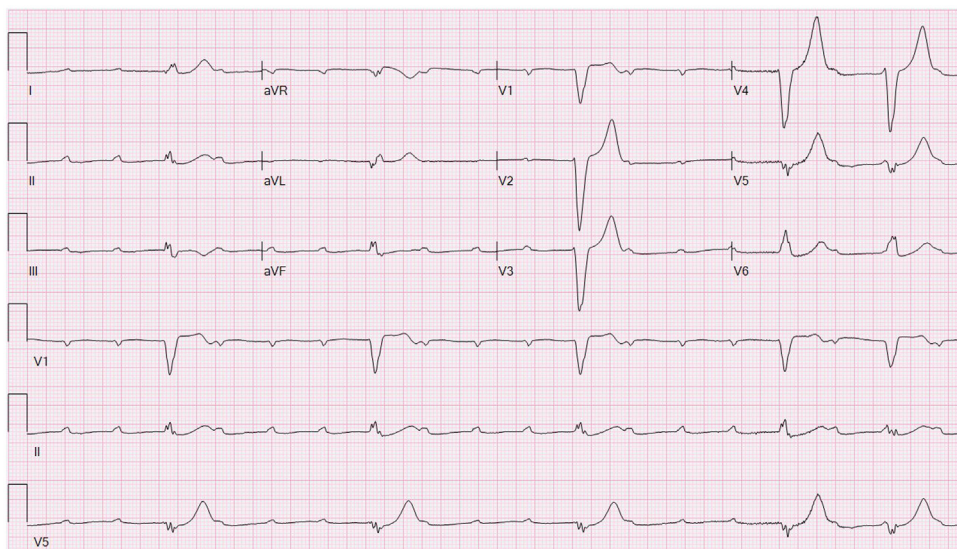


Fig. 1. ECG on presentation showing third degree AVB with ventricular escape rhythm.

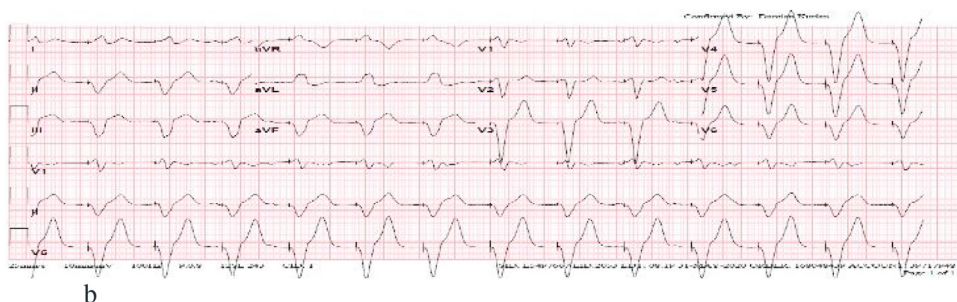


Fig. 2. ECG post transvenous pacemaker placement.

Table 1  
Lyme IgM serology results.

Lyme IgM band 41	Present
Lyme IgM band 39	Present
Lyme IgM band 23	Present
Lyme Western Blot IgM	Positive

Table 2  
Lyme IgG serology results.

Lyme IgG Band 93	Present
Lyme IgG band 66	Present
Lyme IgG band 58	Present
Lyme IgG band 45	Present
Lyme IgG band 41	Present
Lyme IgG band 39	Present
Lyme IgG band 31	Absent
Lyme IgG band 30	Absent
Lyme IgG band 28	Absent
Lyme IgG band 18	Absent
Lyme Western Blot IgG	Positive

transvenous pacemaker was removed on day 3 after complete resolution of the AV block and an intrinsic sinus rate of 80/min. On day 4, the P-R interval shortened to 240 ms (Fig. 4); IV ceftriaxone was switched to oral doxycycline, and patient was discharged home to complete the remaining course for a total of 24 days. He

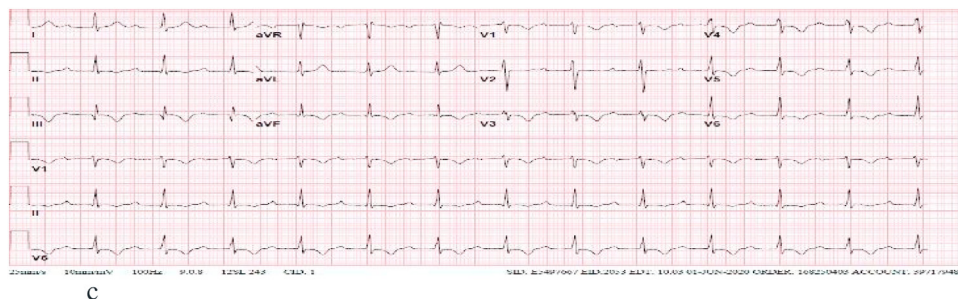
followed up in cardiology and infectious diseases clinics post-discharge.

Discussion

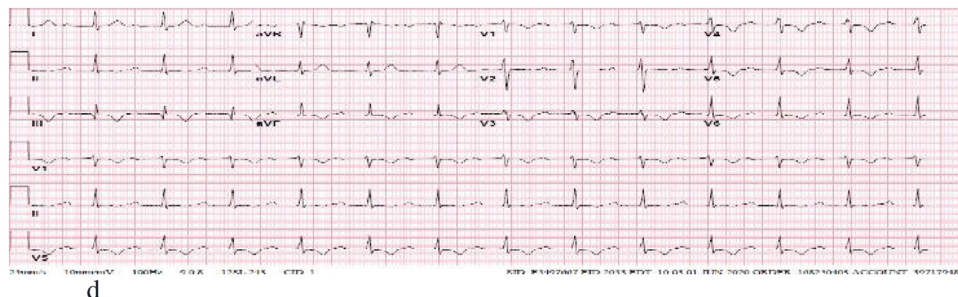
An estimated 300,000 people are diagnosed with LD each year in the United States [1,6] with most cases frequently occurring in New England and the Atlantic states [4,6]. The highest prevalence is during the Spring and Summer months, when the deer and ticks are most active.

Early disseminated LD can present as LC and can typically occurs 1–2 months after the onset of infection. Diagnosis is mainly by clinical features and epidemiological findings. [1] The Suspicious Index in Lyme carditis (SILC) score or COSTAR mnemonic was developed to help determine the likelihood that a patient’s AV block is due to LC [3]. Patients receive points for the presence of constitutional symptoms, engaging in outdoor activity or being in an endemic area, male (sex) gender, tick bite, age <50 years old and presence of erythema migrans (rash) [3]. Patients receiving a score of 0–2 is considered a low risk; 3–6 is an intermediate; and 7–12 is highly suspicious for LC [3]. Our patient had all these features and received a maximum score of 12 points.

Furthermore, two traditional serological tests, ELISA followed by Western immunoblot test are helpful in supporting LD diagnosis in the appropriate setting. The sensitivity and specificity of IgM blot is 32 % and 100 % respectively, while IgG blot is 83 % and 95 % [5]. The IgM Western blot is considered positive if two of three common particular Lyme bands are detected (24, 39, 41) [5]. The IgG Western



**Fig. 3.** ECG on Day 3 showing transition to first degree AVB with P-R interval 330 msec.



**Fig. 4.** ECG on Day 4 showing first degree heart block with P-R interval <290 msec.

blot is considered positive if five of 10 common particular Lyme bands are detected (18, 23, 28, 30, 39, 41, 45, 58, 66, 93) [5]. In our patient both of these tests were positive. It is imperative to note that serology may be negative in the first 6–8 weeks of illness and treatment should not be delayed while awaiting results of serological testing [1]. Therefore, the diagnosis of LD still remains a clinical one.

Patients with symptoms suggestive of LC, including those with marked first- (>300 ms), second-, third-degree AV block should be hospitalized for IV antibiotic therapy [1]. Temporary pacemaker placement is indicated in the treatment of high-degree AV block. However, the AV conduction blockade due to Lyme disease is transient, and will resolve with early initiation of appropriate antibiotics that are effective against *Borrelia* spirochete [1]. IV antibiotics can be switched to oral when high-degree AV block has resolved and P-R interval is <300 ms [1,4]. In previous reports, the time for resolution of complete heart block after treatment can be as early as 6 days with a median of 1 day to 7 weeks [2]. Our patient rapidly improved with IV ceftriaxone and by day 2 had full resolution of the complete heart block with transition to first-degree heart block. By the following day, the P-R interval shortened to <300 ms and he was transitioned to oral doxycycline. No permanent pacemaker placement was required. He has remained asymptomatic on follow-up with a return of his exercise tolerance to prior levels.

LC is a reversible condition with a good prognosis. Early treatment is important and emergent intervention may rarely be needed, as was in this case. Cardiac arrest is rare, and mortality extremely uncommon [7]. Of the rare case fatalities reported, delay in recognition was the main factor leading to a poor outcome. Our case highlights the rapidly progressive nature of the illness and the rapid rate of recovery when timely intervention is instituted. Our patient had severe symptomatic high-grade third-degree AV block and became hemodynamically unstable within seconds that progressed to a brief cardiac arrest. With appropriate use of antibiotic and temporary pacemaker placement, our patient had resolution of his symptoms and had a remarkable recovery.

## Conclusion

The aim of this case report is to highlight the unique Lyme carditis presentation in an urban hospital during COVID-19 pandemic. The need for prompt treatment with high clinical suspicion, and emergent intervention may be necessary in its rare presentation as cardiac arrest.

## Sources of funding

The authors declare that they did not receive any funding for this case report.

## Ethical approval

This case report did not require ethical approval.

## Consent

Written consent from this patient was obtained for the publication of this case report and any accompanying images.

## Authors' contributors

Shantel Brissett: conceptualization, resources, writing-original draft, review & editing, visualization, project administration.

Khaing Myint: conceptualization, resources, writing-original draft, review & editing, visualization, project administration.

Yanira Lopez: supervision.

Farbod Raiszadeh: conceptualization, writing-review & editing, supervision, project administration.

Vel Sivapalan: conceptualization, writing-review & editing, supervision, project administration.

Damian Kurian: conceptualization, writing-review & editing, supervision, project administration.

### Declaration of Competing Interest

The authors declare that they have no known competing financial interests or personal relationships that could have appeared to influence the work reported in this paper.

### References

- [1] Muhammad S, Simonelli R. Lyme carditis: a case report and review of management. *Hosp Pharm* 2018;53(4):263–5.
- [2] Chaudhry MA, Satti SD, Friedlander IR. Lyme carditis with complete heart block: management with an external pacemaker. *Clin Case Rep* 2017;5(6):915–8.
- [3] Yeung C, Baranchuk A. Systematic approach to the diagnosis and treatment of Lyme carditis and high-degree atrioventricular block. *Healthcare (Basel)* 2018;6(4):119.
- [4] Murray T, Shapiro E. Lyme disease. *Clin Lab Med* 2010;30(1):311–28.
- [5] Dressler F, Whalen J, Reinhardt B, Steere A. Western blotting in the serodiagnosis of Lyme disease. *J Infect Dis* 1993;167(2):392–400.
- [6] Kannagara DW, Sidra S, Pritiben P. First case report of inducible heart block in Lyme disease and an update of Lyme carditis. *BMC Infect Dis* 2019;19:428.
- [7] Yeung C, Baranchuk A. Diagnosis and treatment of Lyme carditis. *J Am Coll Cardiol* 2019;73:717–26.