

Received: 2012.12.06
Accepted: 2012.12.13

The comparison of efficacy of different imaging techniques (conventional radiography, ultrasonography, magnetic resonance) in assessment of wrist joints and metacarpophalangeal joints in patients with psoriatic arthritis

Artur Jacek Sankowski¹, Urszula Maria Łebkowska², Jarosław Ćwikła¹, Irena Walecka¹, Jerzy Walecki¹

¹ Department of Radiology, Medical Centre for Postgraduate Education, Warsaw, Poland

² Department of Radiology, Medical University of Białystok, Białystok, Poland

Author's address: Artur Jacek Sankowski, Department of Radiology, Medical Centre for Postgraduate Education, Warsaw, Poland, e-mail: art.san@gazeta.pl

Summary

Background:

Psoriatic arthritis (PsA) is a chronic inflammatory joint disease which develops in patients with psoriasis. The rheumatoid factor is characteristically absent in the serum of PsA patients. Etiology of the disease is still unclear but a number of genetic associations have been identified. Inheritance of the disease is multilevel and the role of environmental factors is emphasized. Immunology of PsA is also quite complex. Inflammation is caused by immunological reactions leading to a release of kinins. Destructive changes in bones usually appear after a few months from the onset of clinical symptoms.

Material/Methods:

PsA typically involves joints of the axial skeleton with an asymmetrical pattern. The spectrum of symptoms includes inflammatory changes in attachments of articular capsules, tendons, and ligaments to bone surface. The disease can have a diverse clinical course but usually manifests as oligoarthritis.

Results:

Imaging plays an important role in the diagnosis of PsA. Classical radiography has been used for this purpose for over a hundred years. It allows to identify late stages of the disease, when bone tissue is affected. In the last 20 years however many new imaging modalities, such as ultrasonography (US), computed tomography (CT) and magnetic resonance (MR), have been developed and became important diagnostic tools for evaluating rheumatoid diseases. They enable the assessment and monitoring of early inflammatory changes.

Conclusions:

As a result, patients have earlier access to modern treatment and thus formation of destructive changes in joints can be markedly delayed or even avoided.

Key words:

psoriatic arthritis • plain radiography • ultrasonography • magnetic resonance • exudate • synovial membrane hyperplasia • erosions

PDF file:

<http://www.polradiol.com/fulltxt.php?ICID=883764>

Background

Lesions observed in the course of psoriatic arthritis (PsA) lead to joint destruction. The disease is chronic and progressive. The lesions gradually progress resulting in permanent

damage and joint destruction and, as a consequence, leads to disability. According to the referenced publications, the crucial factor influencing the effectiveness of therapy is early diagnosis preceding the occurrence of destructive lesions. Modern treatment strategies using new biological

therapy drugs at an early stage of the disease can reduce inflammatory processes and prevent joint destruction.

In view of these data our attempt to determine the diagnostic utility of imaging techniques most commonly used in inflammatory joint diseases seems to be useful. Conventional radiography allows for visualization of destructive lesions after many months or years of the disease. There are reports in the literature that indicate higher sensitivity of ultrasonography and magnetic resonance imaging over conventional radiography. These reports consider MRI as slightly superior to ultrasonography in detecting inflammatory lesions. The economic aspect is also an important issue. It is crucial to answer the following questions: whether on ultrasound examination, which according to literature is more sensitive than X-ray, should become the first-line diagnostic test in the initial phase of arthritis? (this examination is a cheaper and more available than MRI) and whether performing US examinations in ambulatory practice (rheumatology out-patient clinics) will make the diagnosis of early inflammatory lesions in the course of PsA quicker and more accurate?

The aim of this study was to compare the diagnostic efficacy of imaging modalities (X-ray, ultrasound and MRI) in patients diagnosed with PsA in light of evaluation wrist joint and metacarpophalangeal joint.

Material and Methods

Material

The study group comprised of 50 patients diagnosed with psoriatic arthritis, treated at the Department of Dermatology at the Central Clinical Hospital Ministry of Internal Affairs and Administration in Warsaw. X-ray and ultrasound examinations of the wrist joints and metacarpophalangeal joints were performed in all patients. MRI of the aforementioned joints was performed in 16 patients.

Patients aged 20 to 70 years, with the mean age of 45.98 years. The study group included 26 men and 24 women.

The group was divided into two subgroups according to the age at onset:

1. Patients with type 1 psoriasis (onset of joint manifestation under the age of 40):
39 patients (78% of the study group): 15 women (38.5%) and 24 men (61.5%), mean age of 40.5 years.
2. Patients with type 2 psoriasis (onset of symptoms over the age of 40):
11 patients (22% of the study group): 9 women (81.8%) and 2 men (18.2%), mean age 58.9 years.

Psoriasis was diagnosed based on characteristic location and morphology of skin lesions. Mycological and histopathological examination were performed for differential diagnosis in uncertain cases. Patients were treated and diagnosed by experienced dermatologists and rheumatologists (cases with joint involvement).

The serum level of rheumatoid factor was analyzed and found to be negative in all patients.

Methods

Radiographic examinations of wrist joints and metacarpophalangeal joints-MCP (X-ray images in PA projection) were performed in all patients using the Optimus Philips.

The assessment included the joint space width (in millimeters), the presence or absence of erosive lesions (usually seen as a round brightening of bone structure with the cortical bone discontinuity), periarticular calcifications and periosteal reactions. Tendon attachments were assessed for the presence or absence of bone destruction.

Ultrasound examinations were performed using the Hitachi EUB 8500 scanner and a broadband linear transducer with high resolution in the frequency range of 7–13 MHz. The musculoskeletal, or superficial imaging options were applied. In order to confirm the inflammatory process activity within the synovial membrane and entheses Doppler ultrasound (color Doppler [CD] and power Doppler [PD]) were also performed. In addition to the aforementioned features of X-ray examinations the assessment also included synovial hyperplasia. Synovium was considered as hypertrophic (in accordance with the literature) when the synovial fold thickness on the dorsal surface of the wrist was over two millimeters. In metacarpophalangeal joints the synovial fold thickness had to be over 1 millimeter. Another parameter evaluated by ultrasound was the presence of joint effusion.

The MRI of wrist and MCP joints was performed using 1,5T Picker Eclipse scanner with a used knee coil. The protocol included the following sequences:

1. fat saturation sequences (STIR, FATSAT);
2. gradient echo sequences (T2-weighted);
3. FSE sequence (fast spin echo) (T1- and T2-weighted images);
4. PD (proton density).

The examination was performed in 16 patients evaluating the same parameters as in ultrasonography.

Statistical analysis was performed using Statistica software ver. 7.0 (Statsoft, OK., USA).

Results

Wrist joints were assessed by measuring their joint space width. The results of three different methods were taken into consideration: X-ray, ultrasound and MRI. In conventional radiography the mean joint space width was 1.86 millimeters (range 0.5–2.5 mm). The mean value of joint space width measured by ultrasound was 2.02 millimeters (range 0.7–3.8 mm). The mean value of the joint space width was 1.84 millimeters (range 1.2–2.5 mm) in MRI studies. Figure 1 is a graphic presentation of the results. The statistical analysis of wrist joints showed no statistically significant difference between the measurements of joint space width obtained using X-ray, ultrasound or MRI ($P > 0.05$, Wilcoxon Matched Pairs Test). Further analysis showed no statistically significant difference between the types of psoriasis, (type I vs. type II) and between men and women ($P > 0.05$, Mann-Whitney U-test).

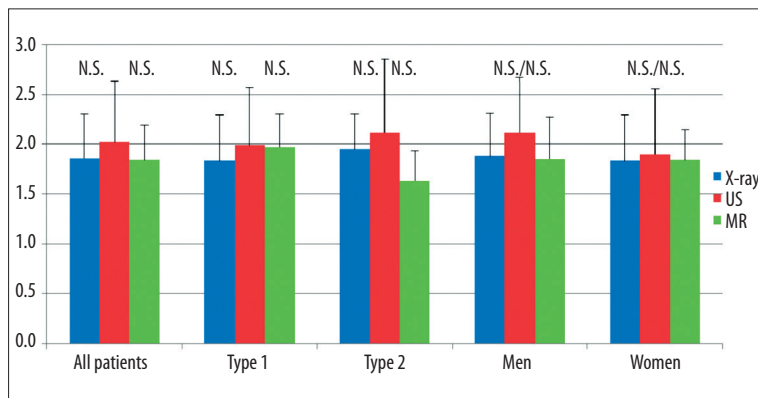


Figure 1. Results of measurements of the width of joint gap in joints of the wrist using three methods: X-ray, US, and MR; average values and SD (mm) were presented in the Figure for all patients and for patients with regard to the type of psoriasis and sex. N.S. – no statistically significant differences between individual methods, for all patients and in particular groups of patient (paired Wilcoxon test $P > 0.05$)

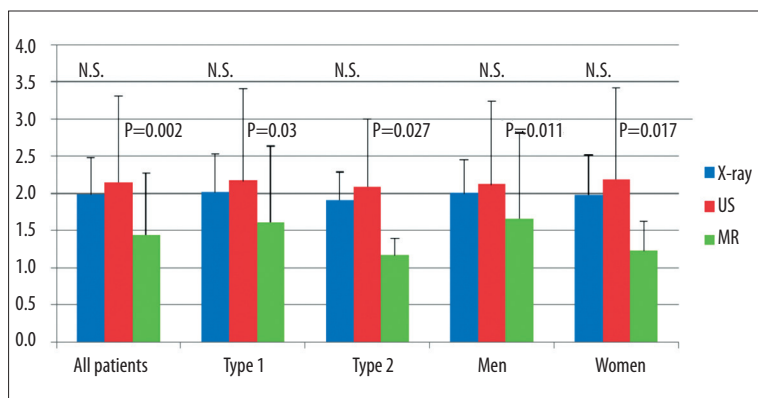


Figure 2. Graphic presentation of measurements of the width of joint gap in metacarpophalangeal joints using three diagnostic methods: X-ray, US, and MR. Average value and SD (mm) were shown for all patients and for patients with regard to the type of psoriasis and sex (N.S. – no significant differences between particular methods, and P value in groups with statistically significant differences between US and MR (paired Wilcoxon test $P < 0.05$).

The joint space width of metacarpophalangeal joints was subsequently assessed using three imaging techniques (X-ray, ultrasound and MR). The X-ray results ranged from 1 millimeter to 4 millimeters. The mean width value of the joint space obtained by conventional radiography was 1.99 millimeters. The results of ultrasound examination ranged from 1 millimeter to 6.7 millimeters, with the mean value of 2.15 millimeters. The MRI results varied from 1 millimeter to 4.5 millimeters, with a mean value of was 1.44 millimeters. All results are graphically presented in Figure 2.

The statistical analysis performed for metacarpophalangeal joints found no statistically significant difference between the values measured by X-ray and ultrasound examinations ($P > 0.05$; Wilcoxon Matched Pairs Test). Statistically significant differences were found between conventional radiography and MRI ($P = 0.005$) and between ultrasound and MRI ($P = 0.002$). In addition, statistically significant differences were found in measured values of joint space width in the metacarpophalangeal joints were found between ultrasound and MRI in type 1 psoriasis ($P = 0.03$), and similarly between X-ray and MRI ($P = 0.041$).

In type 2 psoriasis there were differences between X-ray and MRI measurements ($P = 0.045$) as well as between ultrasonography and MRI ($P = 0.027$). In male and female groups there were no significant differences between the X-ray and ultrasonography studies. There were, however, significant differences between X-ray and MRI values in the female ($P = 0.02$), and male group ($P = 0.042$). In addition, statistical analysis of the results obtained by ultrasound examination vs. MRI revealed significant differences in the

female group ($P = 0.017$), and in the male group ($P = 0.011$) (Wilcoxon Matched Pairs Test).

Further statistical analysis found a significant positive correlation the joint space widths of wrist joints between the measurements obtained by conventional radiography and ultrasound examination (Kendall tau coefficient 0.54, $P < 0.05$), a positive correlation between the width of the joint spaces measured by X-ray and MRI (Kendall tau coefficient 0.36, $P < 0.05$), and between MRI and ultrasound (Kendall tau coefficient 0.47, $P < 0.05$).

The assessment of synovial hypertrophy in wrist joints and metacarpophalangeal joints was assessed using ultrasound and magnetic resonance imaging. The results were presented as mean values, ranges and standard deviations. All patient data for each group of joints are shown in Table 1.

The statistical analysis in the group of 16 patients who underwent ultrasound examination and MRI found no statistical difference between values of synovial fold thickness within the wrist joints and the metacarpophalangeal joints obtained by these two methods (Wilcoxon Matched Pairs Test; $P > 0.05$).

Further statistical analysis compared the measurements of synovial fold thickness between male and female patients. There was a significant difference between these two groups in the obtained values of this parameter for elbow joints ($P = 0.006$ for US and $P = 0.02$ for MRI, Mann-Whitney U test). There were no statistically significant differences between these groups regarding other parameters ($P > 0.05$, Mann-Whitney U test). Synovial membrane thickness measurements using MRI and ultrasound are shown

Table 1. Measurements of synovial membrane fold thickness (in millimeters) using US and MRI in the joints of the wrist and metacarpo-phalangeal joints.

	US (N=50); synovial fold thickness in mm (range and SD)	US (N=16) synovial fold thickness in mm (range and SD)	MRI (N=16) synovial fold thickness in mm (range and SD)
Wrist joints	2.45; (1.4–4.6); 0.68	2.91; (2–4.6); 0.76	2.98; (2.0–5.3); 0.35
Metacarpophalangeal joints	2.14; (1–5.7); 0.78	2.68; (1.7–5.7); 0.99	2.83; (1.8–3.5); 0.48

Table 2. Measurement of synovial fold thickness (in millimeters) in the joint of the wrist, using US and MRI taking into account the type of psoriasis and sex.

	Type 1 Mean value, (range), SD	Type 2 mean value, (range), SD	Male, mean value, (range), SD	Female mean value, (range), SD
MRI	3.29; (2.3–5.3); 1.03	2.45; (2.0–3.1); 0.42	2.86; (2.0–4.6); 0.84	3.09; (2.0–5.3); 1.07
US	3.17; (2.0–4.6); 0.86	2.47; (2.1–3.0); 0.29	2.85; (2.0–4.2); 0.78	2.96; (2.3–4.6); 0.8

Table 3. Measurement of synovial fold thickness (in millimeters) of the MCP joints, using US and MRI taking into account the type of psoriasis and sex.

	Type I mean value, (range), SD	Type II mean value,, (range), SD	Male mean value, (range), SD	Female mean value, (range), SD
MRI	2.94; (1.8–6.0); 1.2	2.65; (2.0–3.4); 0.45	3.05; (1.8–6.0); 1.32	2.61; (1.8–3.4); 0.43
US	2.7; (1.7–5.7); 1.17	2.67; (1.7–3.8); 0.72	2.72; (1.7–5.7); 1.35	2.65; (2.0–3.8); 0.54

Table 4. Assessment of the frequency of erosions, periosteal reactions, and calcifications in the joints of wrist using X-ray, US and MR.

	Erosions N (%)	Periosteal reactions N (%)	Calcifications N (%)
X-rays (N=50)	11 (22)	10 (20)	7 (14)
US (N=50)	20 (40)	28 (56)	24 (48)
MRI (N=16)	11 (68.8)	8 (50)	3 (19)
US (N=16)	9 (56.3)	11 (68.8)	11 (68.8)

in Table 2 (wrist joints) and Table 3 (metacarpophalangeal joints) for all subgroups.

The study compared different methods of imaging (X-ray, ultrasonography and MRI) in the evaluation of calcifications, periosteal reactions and the presence of erosions in each group of joints. Analysis of the wrist joints lead to the conclusions that in all of the patients there was a significant difference between X-ray and ultrasound in detection of calcifications ($P < 0.001$; Wilcoxon Matched Pairs Test), erosions ($P = 0.04$) and evident periosteal reactions ($P < 0.01$).

The directional assessment of patients in MRI and ultrasound (N=16) revealed a significant difference in detection of calcifications in favor of ultrasound ($P = 0.003$). No other differences between ultrasound and MRI were found in relation to other parameters ($P > 0.05$).

The results relating to the detection of erosions, calcifications and periosteal reactions in the wrist joints are summarized in Table 4.

There was no significant difference in detection of erosions ($P = 0.003$) and in MCP joints calcifications ($P = 0.02$) between the X-ray and ultrasound examinations (Wilcoxon Matched Pairs Test). This analysis also revealed no significant difference in detection of periosteal reactions between the aforementioned methods ($P > 0.05$).

The analysis of 16 patients found no significant differences between ultrasound and MRI in detection of erosions, calcifications and periosteal reactions in this group ($P > 0.05$, Wilcoxon Matched Pairs Test).

The directional comparison of ultrasonography vs. magnetic resonance imaging (N=16) in detection of joint destruction features in PsA, the authors found no significant differences between the analyzed imaging methods in detection of erosions, periosteal reactions and the number of calcifications ($P > 0.05$, Wilcoxon Matched Pairs Test). The collected data on features joint damage in MCP joints are shown in Table 5.

The statistical analysis of joint effusion assessment using ultrasonography, revealed a significant difference

Table 5. Assessment of the frequency of erosions, periosteal reactions and calcifications in the MCP joints in the investigations of X-ray, US and MR.

	Erosions N (%)	Periosteal reactions N (%)	Calcifications N (%)
X-rays (N=50)	7 (14)	8 (14)	7 (14)
US (N=50)	18 (36)	8 (16)	14 (28)
MRI (N=16)	11 (68.8)	3 (18.8)	6 (37.5)
US (N=16)	9 (56.3)	3 (18.8)	4 (25)

Table 6. Assessment of the frequency of occurrence of exudates in the joints of the wrist and metacarpophalangeal joints.

	Wrist joints N (%)	Metacarpophalangeal joints N (%)
US (N=50)	27 (54)	19 (38)
MRI (N=16)	8 (50)	8 (50)
US (N=16)	11 (68.8)	9 (56.3)

between the wrist joints and MCP joints regarding the increased amount of fluid (54% vs. 38%, respectively) ($P=0.04$, Wilcoxon Matched Pairs Test). Table 6 summarizes the prevalence of effusion in wrist joints and metacarpophalangeal joints.

Discussion

Psoriatic arthritis is one of the spondyloarthropathies [1]. The disease is characterized by the coexistence of arthritis with typical psoriatic skin lesions [2]. Rheumatoid factor (RF) is not found in psoriatic arthritis which differentiates PsA from rheumatoid arthritis (RA).

About 20 years ago the evaluation of arthritis prevalence among patients with psoriatic skin lesions was based mainly on physical examination and conventional radiography. For this reason, earlier publications reported a lower prevalence of arthritis in patients with psoriatic lesions. Conventional radiographs revealed inflammatory changes in peripheral joints usually approximately 6 months from the onset of clinical symptoms. In the last 20 years modern imaging techniques such as ultrasonography and magnetic resonance imaging have been introduced as a part of the diagnostic procedure. These methods enable to visualize inflammatory lesions in joints and periarticular regions soon after the onset of clinical symptoms. The above mentioned techniques show macroscopic inflammatory lesions of joints and allow the assessment of soft tissues before of the bone structures appear which can be revealed by conventional radiography. As the new imaging techniques developed data indicates a higher prevalence rate of PsA in the population than previously thought [3–7]. Currently, the prevalence of PsA in the world population is estimated at 0.02–0.2%. [8].

The available literature confirms similar efficacy of ultrasonography and magnetic resonance imaging in the diagnosis of PsA. These diagnostic techniques allow for early identification of joint lesions before destructive changes, such

as erosion, appear [9–11]. Early implementation of new biologically active medications which prevents the occurrence of joint destruction or substantially delays the formation of destructive lesions is now possible. Destructive joint lesions lead to a significant deterioration in the patients quality of life and often result in permanent disability and, as a consequence, may cause social exclusion [12].

Difficulty in assessing destructive lesions of bone surface in narrow joint spaces (particularly in smaller joints of the hand) is the main disadvantage of ultrasound examination. Both methods provide the possibility to detect early signs of inflammation, such as joint effusion, synovial hypertrophy, hyperaemia, enthesitis, bone edema as well as a number of other features of acute, chronic or persistent inflammatory process. Its important to note that the above mentioned findings are precursors to further destructive lesions in the course of the disease [12] (Figure 3).

The results presented here are of the MR and US examinations on patients with early lesions, before destructive lesions would be appreciated. MRI was performed in 16 patients in order to assess the wrist joints and metacarpophalangeal joints. Patients suffering from severe pain and periarticular edema were enrolled in the study.

Thickening and inflammatory edema of tendons and ligaments, both in the elbow joints, wrist joints and metacarpophalangeal joints were found on examinations. As the aforementioned lesions were undetectable by conventional radiography, US and MRI examinations were used as a verifying method. MRI verification criterion arises from the fact that this method is reproducible and complementary in opposition to the subjective assessment in ultrasonography. The examinations of all patients in this study were performed according to a specific standard by the same investigator, using the same equipment, which made the results comparable. A thorough analysis of images and correlation with X-ray and MR imaging was performed in a systematic way in order to avoid measurement errors. Subjectivity was minimized by uniform conditions of examination performance, i.e. the use of the same equipment and the engagement of the same investigating physician (Figure 4).

An important parameter in the assessment of lesions in joint diseases is the evaluation of joint space width. The comparative study presented here found no significant differences between three different imaging methods assessing the wrist joints and elbow joints. Statistically significant differences were found in comparing MRI to ultrasonography and conventional radiography of the metacarpophalangeal joints. These differences occur in the whole

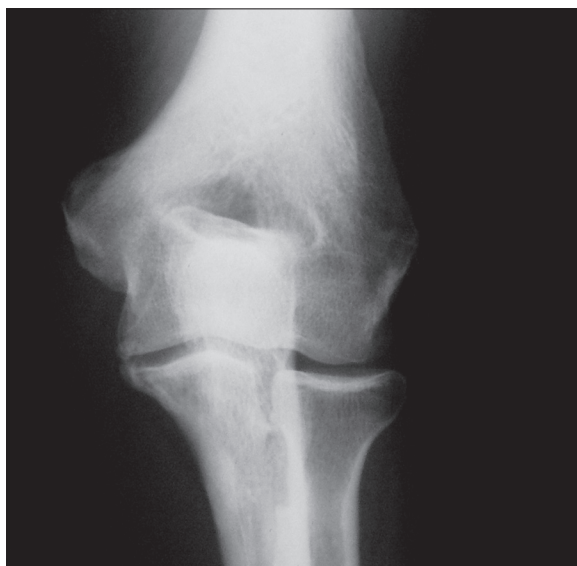

Figure 3A. X-ray of cubital joint in a 56-year-old man with a 21-year history of psoriatic arthritis. Destructive changes are visible in the lateral epicondyle of the humeral bone in attachment of the extensors of the forearm.

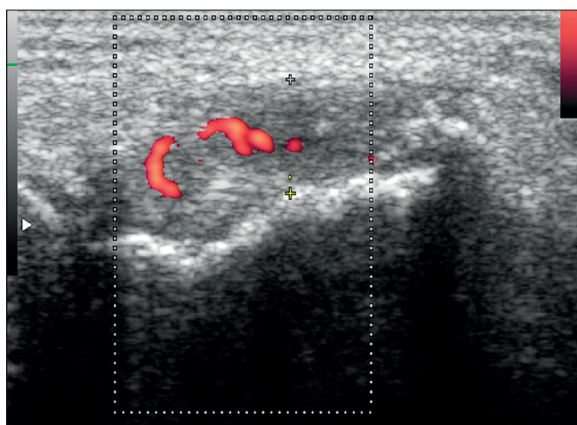


Figure 3B. Ultrasound with Power Doppler (PD) of the lateral epicondyle of the humeral bone in the same patient. Features of enthesis in the form of thickening of enthesis with heterogeneous echogenicity. Hyperaemia in PD indicating the activity of the process. Osseous destruction.

group (for ultrasound $P=0.02$, for X-ray $P=0.005$), as well as in each subgroup regarding gender and type of psoriasis. There were no statistically significant differences between the measurements obtained by X-ray and ultrasound examinations ($P>0.05$). MRI values were lower compared to conventional radiography and ultrasonography. A positive correlation between the values of joint space width in all three diagnostic methods was found. These results indicate an accurate assessment of joint space width in all three methods. However, it is not possible to compare the values obtained with different techniques, particularly the MRI. X-ray and ultrasound measurements are very similar.

Despite the introduction of modern diagnostic methods such as high-resolution ultrasonography and magnetic resonance imaging, the conventional radiography is still considered a valuable and sensitive method for assessing

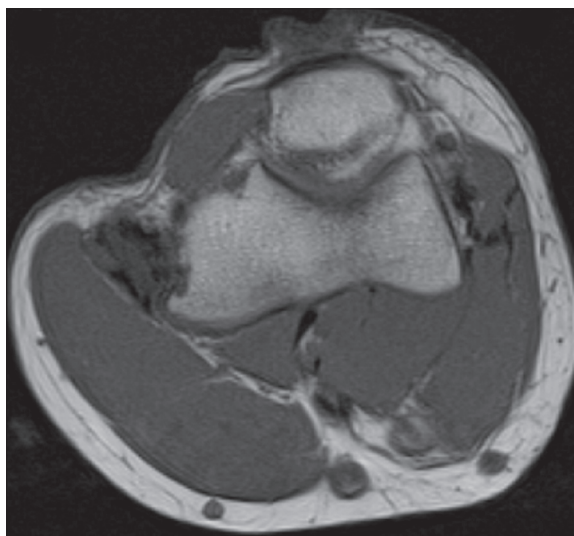


Figure 3C. MR of the cubital joint; FSE sequence, T1-weighted image in axial plane in the same patient. Thickened enthesis with heterogeneous signal. Features of osseous destruction.

joint width. Analysis of X-ray results showed no significant differences compared to ultrasonography and, in some of the assessed joints, MRI [13]. Normal joint space width is equivalent to the thickness of hyaline cartilage covering both articular surfaces. The thickness of the fluid layer in normal joint does not affect the measurement.

Some authors believe that the X-ray examination shows slightly wider joint spaces than ultrasound [14]. It is caused by the fact that in ultrasound studies the deepest layer of hyaline cartilage containing substantial amounts of calcium salts may be viewed as beginning of bone. Our study found no such differences, showing similar measures in both modalities of diagnostic imaging. The mean value of joint space width measured on radiographs was 1.86 millimeters in wrist joints and 1.99 millimeters in metacarpophalangeal joints.

In ultrasound evaluation the following results were obtained: mean value of joint space width in wrist joints was 2.02 mm and in metacarpophalangeal joints – 2.15 mm. The mean width of joint space in metacarpophalangeal joints on MRI was 1.44 mm. This value was lower than obtained by X-ray and ultrasound examinations. The differences reported sporadically by other authors (Reichman et al. [13] and Moller et al. [14]) can be associated with a specific selection of patients who had apparent degenerative lesions with calcifications within cartilages. These calcifications could reflect the ultrasound beam preventing deeper penetration. The majority of patients enrolled in this study were under the age of 40 years. In this age group degenerative lesions are not fully developed yet.

There was no significant difference in joint space width between : male and female groups, types of psoriasis , and type of modality with the exception of MCP evaluated by MRI. The mean width of joint spaces in metacarpophalangeal joints were: X-ray – 2.0 mm, US – 2.12 mm and MRI – 1.66 mm. In women, mean joint space widths were

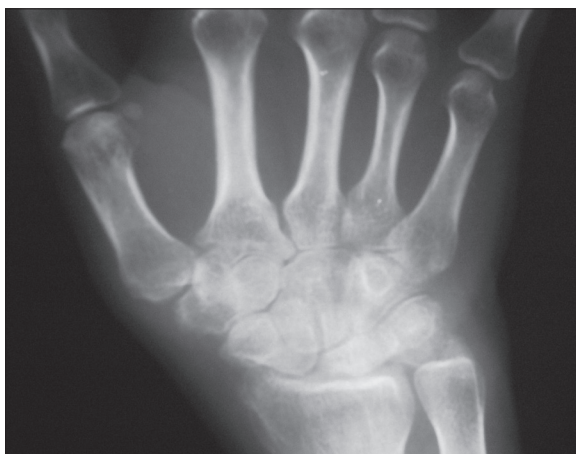


Figure 4A. 36-year-old female with a 3 month history of inflammation of the wrist. X-ray of the wrist. Periarticular osteoporosis. Soft tissue thickenings.

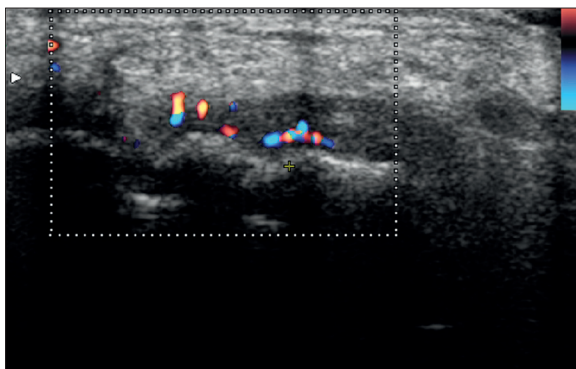


Figure 4B. US Doppler of the wrist. Hypertrophy of the synovial membrane with hyperaemia. US indicating an active inflammatory process of the joints of the wrist. The same patient as in Figure 4A.

measured as 1.98 mm in X-ray, 2.19 mm in ultrasound examination and 1.23 mm in MRI. With the exception of MRI results, all other joint space widths in male and female groups were similar.

Some authors report wider joint spaces in men as compared to women [15,16]. This study does not confirm such differences and the joint space width was similar in both groups as evaluated in all imaging methods. At the same time, several authors describe a slow thickness reduction of the articular cartilage and subsequent, age-related narrowing of the joint space. This negative correlation between age and joint space width was also evident in our study.

Width of joint spaces is a common parameter in the assessment of arthritis. New imaging techniques have made no significant improvement in the evaluation of joint space width, hence, it seems that conventional radiography is still an effective tool in measuring the joint space width [17]. Joint space width should always be assessed using the same method to avoid the influence of various factors characteristic for particular imaging techniques. Joint space widths in PsA remain unchanged until late in the disease. Narrowing of joint spaces appears in the late stages of the disease with large lesions of articular cartilage.

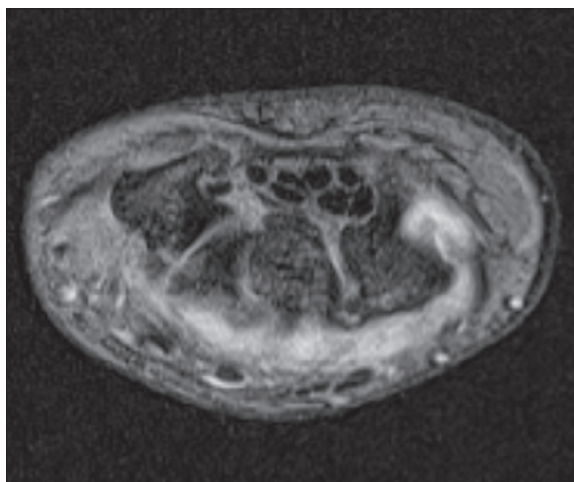


Figure 4C. MR of the wrist with fat saturation. Hypertrophy of the synovial membrane. The same patient as in Figure 1A, 1B.

Hypertrophy in synovitis and synovial production of inflammatory cytokines leads to bone destruction and cartilage damage [3,18–20]. Erosions at the joint margins typical for inflammatory diseases appear as result of advanced inflammatory changes in joints. Growing erosions destroy the articular surfaces of the affected joints and often lead to their total destruction, which frequently occurs in patients with the destructive form of PsA. Differential diagnosis of synovitis includes psoriatic arthritis, RA and other inflammatory joint diseases. Differentiation is difficult, particularly in the destructive form and polyarthritis that resembles RA [21]. Similar synovial changes appear in both entities. Differential diagnosing can be based on the presence of lesions characteristic for PsA, i.e. periosteal reactions with bone proliferation, osteopenia (rarely), pencil-in-cup deformities of phalanges, enthesitis and joint ankylosis in the late stage of the disease.

X-ray examination does not reveal synovial hypertrophy. Some features of radiographs may suggest this pathology, i.e. soft tissue edema surrounding the joint. Ultrasound and MRI can directly visualize inflammatory process of the synovial membrane [9,10].

The authors found no significant differences in the assessment of synovial hypertrophy of the wrist joints and metacarpophalangeal joints ($P < 0.05$) between magnetic resonance and ultrasound imaging.

Ultrasound is a valuable method of assessing the inflammatory changes of synovial membrane. The measurements of synovial fold thickness, particularly in the wrist joints and interphalangeal joints, is equivalent to synovial volume measurements performed in MRI studies. These parameters allow the evaluation of treatment efficacy, especially using recently introduced biologically active medications. The implementation of power Doppler (PD) provides additional possibilities to, for example assess the activity of pannus. Perfusion alterations detected by PD examination provide data to evaluate the activity of synovial membrane during therapeutic treatment [22–25].

Backhaus et al. compared different types of inflammatory lesions. They observed a statistically significant advantage

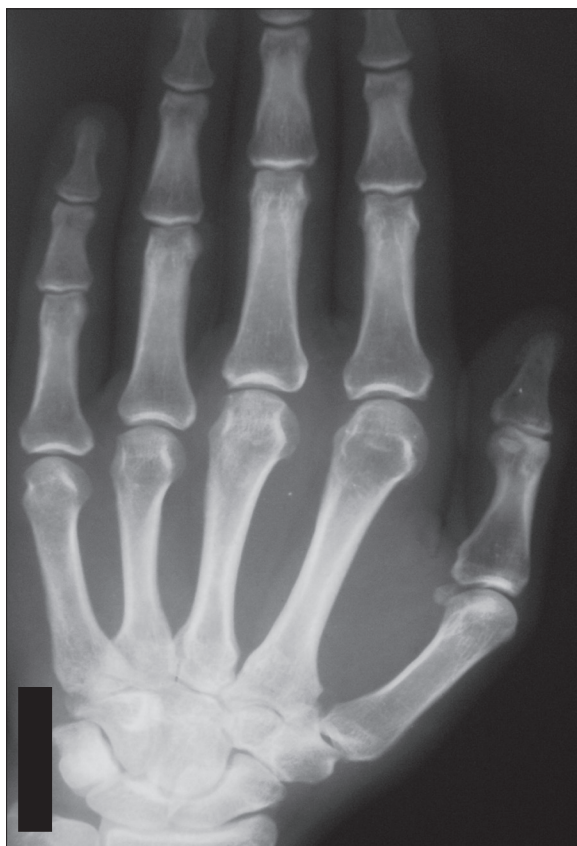

Figure 5A. X-ray of a 36-old-male with a 4 month history of pain and soft tissue swelling in the neighbourhood of the 2nd and 3rd MCP joint. The patient has a twelve years history of psoriasis with no joint problem until now. The X-ray shows no other abnormalities, other than soft tissue edema.

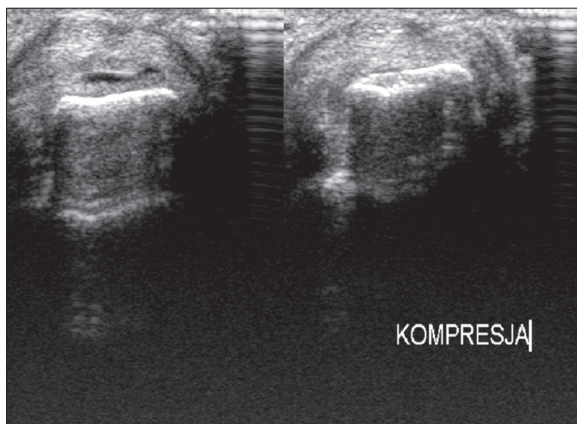


Figure 5B. US of MCP joint II in this same patient. Hypertrophy of the synovial membrane and exudation confirmed by the compression test (pressure with a probe). Features of osseous destruction.

of ultrasound, MRI and scintigraphy in the evaluation of inflammatory lesions of joints as compared to X-ray examination. The same study also compared ultrasound examination to MRI. Basing on their results, authors found a significant advantage of ultrasound in the assessment of synovitis [9,26]. In our study, the results were different from

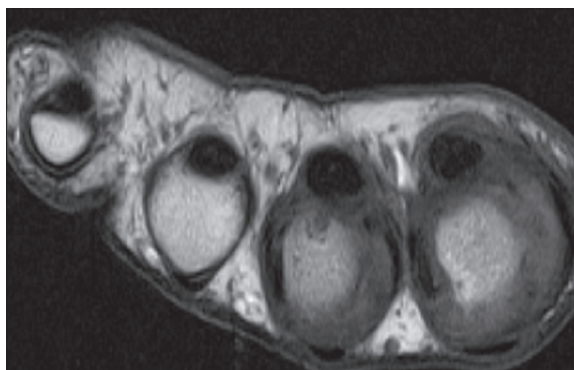


Figure 5C. MR FSE T1-weighted image of metacarpophalangeal joints in the same patient. Synovium hypertrophy involving the II and III metacarpophalangeal joint and tendinous sheaths of flexor digitorum. A small erosion can be seen in the III metacarpal bone.

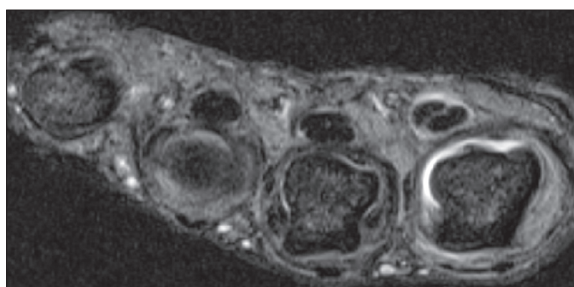


Figure 5D. MR STIR image of metacarpophalangeal joints in the same patient. Joint effusion present in II metacarpophalangeal joint and flexor digitorum tendinous sheaths of II and III finger can be seen apart from findings depicted in Figure 5C.

the above-cited publication as they demonstrate that both methods show similar efficacy in the assessment of synovial hyperplasia.

Dohne et al. showed the important role of ultrasonography and magnetic resonance in the assessment of synovial hypertrophy. They found high effectiveness of both methods in detection of synovial hypertrophy in inflammatory joint diseases. It's possible to analyze the size of lesions during therapy showing progression or good response to treatment. At the same time the authors found a high-resolution CT to be considerably useful (surpassing MRI and ultrasonography) in the evaluation of bone destruction (erosions). The author's opinion on the value of modern imaging techniques in detection of synovial hypertrophy is congruent with the evaluation presented in this study [27].

Another study by Backhaus et al. (2002) [26] also appreciates the high value of MRI and ultrasonography, surpassing conventional radiography capabilities of detecting synovial hypertrophy. The authors evaluated a group of 49 patients with inflammatory joint diseases (RA, PsA). The study investigated the metacarpophalangeal joints as well as proximal and distal interphalangeal joints. The authors revealed inflammatory lesions of synovial membrane in 55% of the patients undergoing ultrasonography and in 42% undergoing MRI. In our study higher percentage of synovial hypertrophy using ultrasound imaging was found as compared to the above-cited publication. Inflammatory

synovial lesions of metacarpophalangeal joints were found 48% of the time with US (the group of 16 patients who underwent MRI, the percentage of synovial inflammation assessed by ultrasound was 75%, whereas MRI revealed these type of lesions in 68.9% of patients). The difference between the results of the ultrasonography and MRI was small, in favor of ultrasound, however it did not reach statistical significance (Figure 5).

In another publication by Horikoshi et al. MRI and ultrasonography in the diagnosis of arthritis were assessed leading to different conclusions. The authors have demonstrated ultrasound superiority over magnetic resonance in detection of synovial hypertrophy. 156 joints were assessed using ultrasonography inflammatory lesions of synovial membrane were found in 74 joints, whereas the MRI revealed these changes in only 38 joints. In our study, such an advantage was not that evident. In our opinion such results were found due to a low-field MRI scanner used in the above-mentioned study. Our study used a high-field scanner with magnetic field of 1.5 T. In our study both methods are nearly equivalent [28].

Similarly, Haavardsholm et al. described the usefulness of US and MRI in the assessment of synovial hypertrophy. In their opinion, these methods surpass the capabilities of conventional radiography and physical examination in arthritis. However, the authors strongly emphasized the superiority of MRI over ultrasonography [29]. Additionally, the authors draw attention to the possibility of effective treatment monitoring based on new drugs of biological therapy using modern imaging techniques.

Similar conclusions were reported by Weiner et al. recognizing the superiority of MRI and ultrasound over conventional radiography [30]. Sensitivity of these methods in the assessment of joint inflammation was established at 72% in MRI, 71% in US and 32% in X-ray. The highest sensitivity was shown in scintigraphic examination – 82%. In the assessment of synovial hypertrophy the superiority of MRI over ultrasonography was reported. Insignificant differences between ultrasound and MRI depend mostly on the anatomy of the evaluated joint. Similar conclusions were published by Wiell et al., Haavardsholm et al. They confirmed the effectiveness of MRI and ultrasonography in the assessment of joint inflammation and their superiority over conventional radiography [29,31]. According to these authors, magnetic resonance imaging is an effective method of assessing discrete (as well as subclinical) signs of synovitis [32].

Erosion occurring in PsA are the result of the destructive activity of inflammatory process in bone structure. It is one of the main manifestations of the disease. These lesions lead to impaired functioning of the joint. Hence, early detection of erosions is an important issue of PsA diagnosis. Dhir et al. estimate the prevalence of erosions at 50% of patients with PsA after 10 years of the disease [33]. Other authors report lower rates pointing that erosions may occur in up to 33% of the patients [34]. In our study wrist joint erosions were found in 40% of the patients, whereas in metacarpophalangeal joints in 36% of the patients as revealed by ultrasonography. The median of PsA duration in our patients was 4 years.

The results of our study support a statistically significant relation between detection of erosions in X-ray examination and the detection of erosions in ultrasonography (showing higher efficacy of US) in wrist joints ($P=0.04$) and metacarpophalangeal joints ($P=0.003$).

No statistical significance was found then comparing the usage of MRI and US for the detection of erosions in all investigated joints ($P>0.05$). This indicates a similar efficacy of these methods. Significant differences were found in the assessment of joints between gender (male vs. female) and psoriasis type subgroups (type 1 vs. type 2)

Our study showed higher efficacy of MRI and US in detection of erosions as compared to X-ray examination. Similar conclusions were reported by several authors. Conventional radiography reveals lesions at late stages of the disease. In psoriatic arthritis it usually means many years of disease progression. MRI and ultrasonography allow early detection of joint lesions [35]. X-ray examination is a considerably useful to monitor advanced erosions at the later stage of the disease [36]. This is a reproducible and objective examination. Moreover, the availability of this examination and relatively low cost play an important role. X-ray examination can complement the physical examination [37].

Wiell et al. evaluated the inflammatory lesions in joints of the hand using conventional radiography, ultrasonography and magnetic resonance imaging and subsequently compared the effectiveness of these methods to physical examination [31]. Imaging studies were found more sensitive compared to physical examination. In addition, the number of detected erosions pointed to a higher effectiveness of ultrasound and MRI comparing to X-ray examination. Erosions were found in 18% of joints on ultrasound examination, in 23% of joints on MRI and 12% of joints on radiographs. MRI is slightly more sensitive than ultrasound. Our result also show the domination of MRI and ultrasonography over conventional radiography. X-ray examinations reveal wrist joint erosions in 22% of patients, ultrasound examination in 40% (in group of 16 people who underwent MRI the rate was 56.3%). MRI revealed wrist joint erosions in 68.8% of patients.

Weiner et al. came to a different conclusion, stating that the diagnostic value of ultrasound and X-ray in detection of erosions and periosteal reactions is higher than in MRI [30].

Numerous reports emphasize the dominant role of MRI in the diagnosis of arthritis, particularly in the evaluation of synovial inflammation, effusion and erosions [38,39]. However, the role of ultrasound is always noticeable. The authors of these reports believe that ultrasonography is slightly inferior to MRI in the assessment of erosive lesions. Only one study found a significant superiority of MRI in the detection of destructive lesions over US and X-ray examination [40]. According to these authors MRI is a reference standard as the X-ray and ultrasonography detected erosions in only 50% of the cases revealed by MRI. Our results, as well as the majority of publications on this issue, are not congruent with these findings [41,42].

In our opinion, the most sensitive test detecting erosive lesions is MRI, which remains slightly superior to

ultrasonography. However, both techniques (ultrasound and magnetic resonance) are sensitive enough to be useful methods in detecting erosive lesions and monitoring their evolution in different therapies. Uncertain cases should be verified by MRI.

Periosteal reactions are a typical manifestation of PsA. These reactions are an important component of the so-called sausage-digit morphology, which is a characteristic symptom of PsA [43]. MRI is a particularly sensitive method for detecting these lesions. The results of our study revealed a statistically significant difference in the detection of periosteal reactions in wrist joints between ultrasonography and classic radiography ($P < 0.001$). The sensitivity of ultrasound and MRI was significantly higher than the sensitivity of X-ray studies. The statistical analysis of wrist joint examinations showed similar results regardless of gender and type of psoriasis. In other investigated joints our results showed no statistically significant differences in the detection of periosteal reactions ($P > 0.05$).

Most publications reported a significantly higher sensitivity of MRI compared to other imaging techniques [43,44]. In our opinion ultrasound and MRI have a similar diagnostic value and surpass conventional radiography in detection of periosteal reactions. Although the metacarpophalangeal joint investigation showed no statistical significance, MR imaging revealed more lesions than X-ray examinations (in wrist joints 50% vs. 20%). In addition, our results showed a high rate of periosteal reactions in US examinations (56% for wrist joints). The publication by Tan et al. presented an opinion of X-ray examination superiority over ultrasound and MR imaging in the detection of periosteal reactions [45]. Such an opinion is not shared by the majority of authors.

The study by Kane et al. found significant diagnostic capabilities of ultrasound in the assessment of periosteal reactions [46]. Ultrasound imaging correlated with radiographic findings. The above-cited study is consistent with our observations particularly pertaining to the assessment of elbow joints and metacarpophalangeal joints. Ultrasound examination plays an important role in the imaging of periosteal reactions and edema of bone structures in the vicinity.

Ultrasound examinations and MR imaging provide a thorough diagnostic evaluation of periosteal reactions. Its importance is role of these new methods is the ability to monitor the lesions after treatment implementation. Harty et al. believe that periosteal reactions are responsible for the discomfort persists despite treatment implementation and withdrawal of clinical symptoms such as swelling and tenderness [47]. These lesions are clearly visible in MRI and ultrasound.

In our opinion, all methods of imaging may play an important role in the evaluation of periosteal reactions, however, MRI and ultrasound capabilities outweigh conventional radiography.

Soft tissue calcifications observed in the area of joint inflammation are the result of regressive changes caused

by ongoing inflammatory processes. Calcium deposits are usually visible in tendon attachments, joint capsules as well as tendon sheaths.

In our study, periarticular calcifications were mostly found in wrist joints (ultrasonography – 48%, X-ray – 14%, and MRI – 19% of patients). In metacarpophalangeal joints this type of lesion was detected by ultrasound in 28% of the patients, by radiography in 14% and in MRI in 37.5% of the cases. Moreover, we found a statistically significant correlation between ultrasound and X-ray examination in all investigated joints, indicating the superiority of ultrasonography in the detection of periarticular calcification (wrist joint ($P = 0.000$); metacarpophalangeal joints ($P = 0.02$)).

A statistically significant correlation was also observed between US and MRI efficacy in the detection of wrist joint calcifications ($P = 0.003$). These results indicate the superiority of ultrasound over conventional radiography and magnetic resonance imaging in detecting periarticular calcifications. MRI results varied in different joints, probably due to the usually small, variable amount of free protons in calcium deposits that can affect the MR signal within these lesions. This seems to be a limitation of MRI in detecting these structures [48]. In most publications, however, MRI had a high diagnostic efficacy.

Vinson et al. assessed and compared the efficacy of calcium deposit detection using conventional radiography and magnetic resonance imaging evaluating metacarpophalangeal joints. The authors found a good correlation between these methods. Concluding, that MRI capabilities outweigh conventional radiography, as it was able to visualize lesions of surrounding soft tissues [49]. The visualization of lesions around calcium deposits provided the possibility to assess the activity of the process in a particular case.

In another study Elhai et al. evaluated the wrist joints and other joints of the hand in patients with systemic sclerosis and inflammatory joint diseases [50]. The ultrasound studies revealed calcifications in 40% of the patients, whereas X-ray examination found these lesions in 36% of patients. The authors evaluated the two methods to be equivalent. They concluded that both methods revealed the characteristic symptoms for both groups of diseases. In another study, lesions in the peripheral joints in the course of SpA have been evaluated [51]. Authors of this study considered ultrasound a highly effective in the detection of calcifications in and around joints. Calcifications were found in 33.7% of the patients. These observations are similar to the results obtained in our study, indicating the high value of ultrasonography.

Similarly, a high diagnostic effectiveness of ultrasound in detection of calcifications was noted in other studies in which the assessment of calcification and calcium deposits was part of the diagnostic procedure [50,52].

There is a variety of opinions in the literature on detection of intraarticular calcifications. The great value of conventional radiography is noted, but the leading role of ultrasound and MRI is frequently stressed. Our study showed significantly higher detection capabilities of ultrasound

in the assessment of calcifications. MRI and conventional radiography appear to be less accurate. The ultrasound examination was more efficient particularly in the detection of small lesions. Limitations of MRI efficacy in this regard is described above.

Joint inflammation is often associated with joint effusions produced by the inflamed synovium. In our study, the presence of intraarticular effusions was found in patients (16 individuals) examined by ultrasound and MRI. The wrist joints effusions were detected by ultrasound in 68.8% of the patients and metacarpophalangeal joints effusions in 56.3% of the patients. MRI revealed wrist joint effusions in 50% of the patients and metacarpophalangeal joints effusion in 50% of the patients.

There was a significant statistical correlation in wrist effusion detection between US and MRI ($P=0,04$) in favor of US. Additionally, the results showed higher prevalence of wrist joint effusions in women as compared to the male group ($P=0.046$). Moreover, the wrist joint effusions were more frequently found in patients with type II psoriasis (73%) compared to type I (49%).

No statistically significant differences were found between the diagnostic capabilities of ultrasound and MR in other groups of joints ($P>0.05$).

Modern imaging methods (US and MRI) are important in detecting joint effusions. The high diagnostic efficacy of both methods outweigh the physical examination [53,54]. Conaghan et al. found a high effectiveness of ultrasonography in the evaluation of intra-articular effusions [55]. Inflammatory processes in joints were assessed over a three-year follow-up. In addition, the authors presented an opinion that the evaluation of articular effusion is a prognostic factor of disease.

References:

1. Wright V: Seronegative polyarthritis: a unified concept. *Arthritis Rheumatica*, 1978; 21(6): 619-33
2. Moll JMH, Wright V: Psoriatic arthritis, (In:) *Seminars in Arthritis and Rheumatism*, 1973; 3(1): 55-78
3. Mease PJ: Tumour necrosis factor (TNF) in psoriatic arthritis: pathophysiology and treatment with TNF inhibitors. *Ann Rheum Dis*, 2002; 61: 298-304
4. Salvarani C, Lo Scocco G, Macchioni P et al: Prevalence of Psoriatic Arthritis in Italian Psoriatic Patients. *J Rheumatol*, 1995; 22(8): 1499-503
5. Zachariae H: Prevalence of joint disease in patients with psoriasis: implications for therapy. *Am J Clin Dermatol*, 2003; 4(7): 441-47
6. Green L, Meyers OL, Gordon W et al: Arthritis in Psoriasis. *Ann Reum Dis*, 1981; 40(4): 366-69
7. McQueen FM: MRI in Psoriatic Arthritis. *Ann Reum Dis*, 2007; 66(Suppl.2): 19
8. Zochling J, Smith EU: Seronegative spondyloarthritis. *Best Pract Res Clin Rheumatol*, 2010; 24(6): 747-56
9. Backhaus M, Kamradt T, Sandrock D et al: Bollow. Arthritis of the finger joints: a comprehensive approach comparing conventional radiography, scintigraphy, ultrasound, and contrast-enhanced magnetic resonance imaging. *Arthritis Rheum*, 1999; 42: 1232-45
10. Ciechomska A, Andrysiak R, Serafin-Król M et al: Ocena przydatności ultrasonografii i rezonansu magnetycznego w diagnostyce zapalenia stawów rąk. *Polski Merkuriusz Lekarski*, 2001; 62: 144-47 [in Polish]
11. Schoellnast H, Deutschmann H, Hermann J et al: Psoriatic arthritis and rheumatoid arthritis: Findings in contrast-enhanced MRI. *Am J Roentgenol*, 2006; 187: 351-57
12. Hau M, Kneitz C, Tony H-P et al: High resolution ultrasound detects a decrease in pannus vascularisation of small finger joint in patients with rheumatoid arthritis receiving treatment with soluble tumour necrosis factor alpha receptor (etanercept). *Ann Rheum Dis*, 2002; 61: 55-58
13. Reichmann WM, Maillefert JF, Hunter DJ et al: Responsiveness to change and reliability of measurement of radiographic joint space width in osteoarthritis of the knee: a systematic review. *Osteoarthritis Cartilage*, 2011; 19(5): 550-56
14. Moller B, Bonel H, Rotzetter M et al: Measuring finger joint cartilage by ultrasound as a promising alternative to conventional radiographs imaging. *Arthritis Rheum*, 2009; 61(4): 435-41
15. Beattie KA, Duryea J, Pui M et al: Minimum joint space width and tibial cartilage morphology in the knees of healthy individuals: A cross-sectional study. *BMC Musculoskeletal Disorders*, 2008; 8(9): 119
16. Spannow AH, Pfeiffer-Jensen M, Andersen NT et al: Ultrasonographic measurements of joint cartilage thickness in healthy children: age- and sex-related standard reference values. *J Rheumatol*, 2010; 37(12): 2595-601
17. A Keat: ABC of Rheumatology: Spondyloarthropathies. *BMJ*, 1995; 310: 1321-24
18. Olek-Hrab K, Kaczorowska I, Żaba R et al: Polimorfizm genu dla TNF-alfa u chorych na łuszczycę i łuszczycowe zapalenie stawów. *Przegląd Dermatologiczny*, 2004; 91: 291-96 [in Polish]

19. Mease P: TNF- α therapy in psoriatic arthritis and psoriasis. *Ann Rheum Dis*, 2004; 63: 755–58
20. McGonagle D, Gibbon W, Emery P: Classification of inflammatory arthritis by enthesitis. *Lancet*, 1998; 352: 1137–40
21. Hau M, Kneitz C, Tony H-P et al: High resolution ultrasound detects a decrease in pannus vascularisation of small finger joint in patients with rheumatoid arthritis receiving treatment with soluble tumour necrosis factor alpha receptor (etanercept). *Ann Rheum Dis*, 2002; 61: 55–58
22. Newman JS, Laing TJ, McCarthy CJ et al: Power Doppler Sonography of Synovitis: Assessment of Therapeutic Response – Preliminary Observations. *Radiology*, 1996; 198: 582–84
23. Ribbens C, Andre B, Marcellis S et al: Rheumatoid hand joint synovitis: Grey-scale and Power Doppler US quantifications following anti-tumor necrosis factor-alpha treatment: Pilot study. *Radiology*, 2003; 229: 562–69
24. Stone M, Bergin D, Whelan B et al: Power Doppler ultrasound assessment of rheumatoid hand synovitis. *J Rheumatol*, 2001; 28: 1979–82
25. Szkudlarek M, Court-Payen M, Standberg C et al: Power Doppler ultrasonography for assessment of synovitis in the metacarpophalangeal joints of patients with rheumatoid arthritis: a comparison with dynamic magnetic resonance imaging. *Arthritis Rheum*, 2001; 44: 2018–23
26. Backhaus M, Burmester GR, Sandrock D et al: Prospective two year follow up study comparing novel and conventional imaging procedures in patients with arthritic finger joints. *Ann Rheum Dis*, 2002; 61: 895–904
27. Dohn UM, Ejbjerg B, Boonen A et al: No overall progression and occasional repair of erosions despite persistent inflammation in adalimumab-treated rheumatoid arthritis patients: results from a longitudinal comparative MRI, ultrasonography, CT and radiography study. *Ann Rheum Dis*, 2011; 70: 252–58
28. Horikoshi M, Suzuki T, Sugihara M et al: Comparison of low-field dedicated extremity magnetic resonance imaging with articular ultrasonography in patients with rheumatoid arthritis. *Mod Rheumatol*, 2010; 20(6): 556–60
29. Hvardsholm EA, Ostergaard M, Hammer HB et al: Monitoring anti-TNF α treatment in rheumatoid arthritis: responsiveness of magnetic resonance imaging and ultrasonography of the dominant wrist joint compared with conventional measures of disease activity and structural damage. *Ann Rheum Dis*, 2009; 68(10): 1572–79
30. Weiner SM, Jurenz S, Uhl M et al: Ultrasonography in the assessment of peripheral joint involvement in psoriatic arthritis: a comparison with radiography, MRI and scintigraphy. *Clin Rheumatol*, 2008; 27(8): 983–89
31. Wiell C, Szkudlarek M, Hasselquist M et al: Ultrasonography, magnetic resonance imaging, radiography and clinical assessment of inflammatory and destructive changes in fingers and toes of patients with psoriatic arthritis. *Arthritis Res Ther*, 2007; 9(6): R119
32. Conaghan PG, McQueen FM, Bird P et al: Update on research and future directions of the OMERACT MRI inflammatory arthritis group. *J Rheumatol*, 2011; 38(9): 2031–33
33. Dhir V, Aggarwal A: Psoriatic arthritis: a critical review. *Clin Rev Allergy Immunol*, 2012 [Epub ahead of print]
34. Zisman D, Eder L, Elias M et al: Clinical and demographic characteristics of patients with psoriatic arthritis in northern Israel. *Rheumatol Int*, 2012; 32(3): 595–600
35. Barozzi L, Olivieri I, De Matteis M et al: Seronegative spondyloarthropathies: imaging of spondylitis, enthesitis and dactylitis. *Eur J Radiol*, 1998; 27(Suppl.1): S12–17
36. Wassenberg S, Fischer-Kahle V, Herborn G et al: A method to score radiographic change in psoriatic arthritis. *Z Rheumatol*, 2001; 60(3): 156–66
37. Siannis F, Farewell VT, Cook RJ et al: Clinical and radiological damage in psoriatic arthritis. *Ann Rheum Dis*, 2006; 65(4): 478–81
38. McQueen F, Lassere M, Duer-Jensen A et al: Testing an OMERACT MRI scoring system for peripheral psoriatic arthritis in cross-sectional and longitudinal settings. *J Rheumatol*, 2009; 36(8): 1811–15
39. Cimmino MA, Parodi M, Zampogna G et al: Magnetic resonance imaging of the hand in psoriatic arthritis. *J Rheumatol Supplement*, 2009; 83: 39–41
40. Malattia C, Damasio MB, Magnaguagno F et al: Magnetic resonance imaging, ultrasonography, and conventional radiography in the assessment of bone erosions in juvenile idiopathic arthritis. *Arthritis Rheum*, 2008; 59(12): 1764–72
41. Haugen IK, Boyesen P: Imaging modalities in hand osteoarthritis – status and perspectives of conventional radiology, magnetic resonance imaging, and ultrasonography. *Arthritis Res Ther*, 2011; 13(6): 248
42. Szkudlarek M, Klarlund M, Narvestad E et al: Ultrasonography of the metacarpophalangeal and proximal interphalangeal joints in rheumatoid arthritis: a comparison with magnetic resonance imaging, conventional radiography and clinical examination. *Arthritis Res Ther*, 2006; 8(2): R52
43. Spira D, Kotter I, Henes J et al: MRI findings in psoriatic arthritis of the hand. *Am J Roentgenol*, 2010; 195(5): 1187–93
44. Ory PA, Gladman DD, Mease PJ: Psoriatic arthritis and imaging. *Ann Rheum Dis*, 2005; 65: ii55–57
45. Tan AL, McGonagle D: Psoriatic arthritis: correlation between imaging and pathology. *Joint Bone Spine*, 2010; 77(3): 206–11
46. Kane D, Greaney T, Brenishan B et al: Ultrasonography in the diagnosis and management of psoriatic dactylitis. *J Rheumatol*, 1999; 26(8): 1746–51
47. Harty LC, Ng CT, Fearon C et al: Joint tenderness and swelling in biologic-treated inflammatory arthritis patients – a tricky trade off? *Int J Clin Pract*, 2012; 66(2): 128–31
48. Abreu M, Johnson K, Chung CB et al: Calcification in calcium pyrophosphate, dehydrate (CPPD) crystalline deposits in the knee: anatomic, radiographic, MR imaging, and histologic study in cadavers. *Skeletal Radiology*, 2004; 33(7): 392–98
49. Vinson EN, Desai SV, Reddy S et al: Periarticular calcifications in two patients with acute hand pain. *Am J Roentgenol*, 2010; 195(6) Suppl.: 576–79
50. Elhai M, Guerini H, Bazeli RJ et al: Ultrasonographic hand features in systemic sclerosis and correlates with clinical, biological and radiographic findings. *Arthritis Care Res*, 2012; 64(8): 1244–49
51. Spadaro A, Iagnocco A, Perrotta FM et al: Clinical and ultrasonography assessment of peripheral enthesitis in ankylosing spondylitis. *Rheumatology*, 2011; 50(11): 2080–86
52. Ciapetti A, Filippucci E, Gutierrez M et al: Calcium pyrophosphate dehydrate crystal deposition disease: sonographic findings. *Clinical Rheumatol*, 2009; 28(3): 271–76
53. Wittoek R, Lans L, Lambrecht V et al: Reliability and construct validity of ultrasonography of soft tissue and destructive changes in erosive osteoarthritis of the interphalangeal finger joints: a comparison with MRI. *Ann Rheum Dis*, 2011; 70(2): 278–83
54. Wakefield RJ, Kong KO, Conaghan PG et al: The role of ultrasonography and magnetic resonance imaging in early rheumatoid arthritis. *Clin Exp Rheumatol*, 2003; 21(5 Suppl.31): S42–49
55. Conaghan PG, D'Agostino MA, Le Bars M et al: Clinical and ultrasonographic predictors of joint replacement for knee osteoarthritis: results from a large, 3-year, prospective ELUAR study. *Ann Rheum Dis*, 2010; 69(4): 644–47
56. Tarhan S, Unlu Z: Magnetic resonance imaging and ultrasonographic evaluation of the patients with knee osteoarthritis: a comparative study. *Clin Rheumatol*, 2003; 22(3): 181–88
57. Ostergaard M, Court-Payen M, Gideon P et al: Ultrasonography in arthritis of the knee. A comparison with MRI imaging. *Acta Radiol*, 1995; 36(1): 19–26