

Received: 2014.06.08  
Accepted: 2014.06.28  
Published: 2014.10.03

ISSN 1941-5923  
© Am J Case Rep, 2014; 15: 426-430  
DOI: 10.12659/AJCR.891150

## Five-Year Follow-Up of a Patient with Bilateral Carotid Body Tumors after Unilateral Surgical Resection

Authors' Contribution:  
Study Design A  
Data Collection B  
Statistical Analysis C  
Data Interpretation D  
Manuscript Preparation E  
Literature Search F  
Funds Collection G

AEG 1 **Tolga Demir**  
BCDF 2 **Ibrahim Uyar**  
BEF 3 **Hale Bolgi Demir**  
F 1 **Mazlum Sahin**  
BE 4 **Gokcen Gundogdu**

1 Department of Cardiovascular Surgery, Beylikdüzü Kolan Hospital, Istanbul, Turkey  
2 Department of Cardiovascular Surgery, Acute Cardiovascular Hospital, Izmir, Turkey  
3 Department of Cardiovascular Surgery, Medicana International Hospital, Istanbul, Turkey  
4 Department of Pathology, Istanbul University, Istanbul Medical Faculty, Istanbul, Turkey

**Corresponding Author:** Tolga Demir, e-mail: [dr.tolgademir@gmail.com](mailto:dr.tolgademir@gmail.com)  
**Conflict of interest:** None declared

**Patient:** Female, 34  
**Final Diagnosis:** Carotid body tumor  
**Symptoms:** Dysphagia • hoarseness • non-tender neck swelling  
**Medication:** —  
**Clinical Procedure:** —  
**Specialty:** Surgery

**Objective:** Rare disease





**Background:** Carotid body tumors are rare, highly vascularized neoplasms that arise from the paraganglia located at the carotid bifurcation. Surgery is the only curative treatment. However, treatment of bilateral carotid body tumors represents a special challenge due to potential neurovascular complications.

**Case Report:** We present the therapeutic management of a 34-year-old woman with bilateral carotid body tumors. The patient underwent surgical resection of the largest tumor. It was not possible to resect the tumor without sacrificing the ipsilateral vagal nerve. Due to unilateral vagal palsy, we decide to withhold all invasive therapy and to observe contralateral tumor growth with serial imaging studies. The patient is free of disease progression 5 years later.

**Conclusions:** Treatment of bilateral CBTs should focus on preservation of the quality of life rather than on cure of the disease. In patients with previous contralateral vagal palsies, the choice between surgery and watchful waiting is a balance between the natural potential morbidity and the predictable surgical morbidity. Therefore, to avoid bilateral cranial nerve deficits, these patients may be observed until tumor growth is determined, and, if needed, treated by radiation therapy.

**MeSH Keywords:** Carotid Body Tumor • Vagus Nerve Injuries • Vocal Cord Paralysis

**Full-text PDF:** <http://www.amjcaserep.com/abstract/index/idArt/891150>

 1493  —  5  17



## Background

Carotid body tumors (CBTs), also known as carotid paragangliomas, are rare neoplasms localized in the bifurcation of the common carotid artery. They have a reported incidence between 0.06 and 3.33 per 100 000 patients. Familial occurrence is likely to occur in 10% of patients with an autosomal dominant inheritance. Approximately 30% of familial CBTs are bilateral, compared 3–4% of the sporadic tumors [1]. The best choice of treatment is complete surgical resection [2]. Patients with bilateral CBTs represent a special challenge. One-step surgery is not recommended since it carries the risk of bilateral cranial nerve palsies and cerebrovascular complications resulting in severe disabilities [3]. In the present study, we present a case of bilateral CBTs in a 34-year-old female patient.

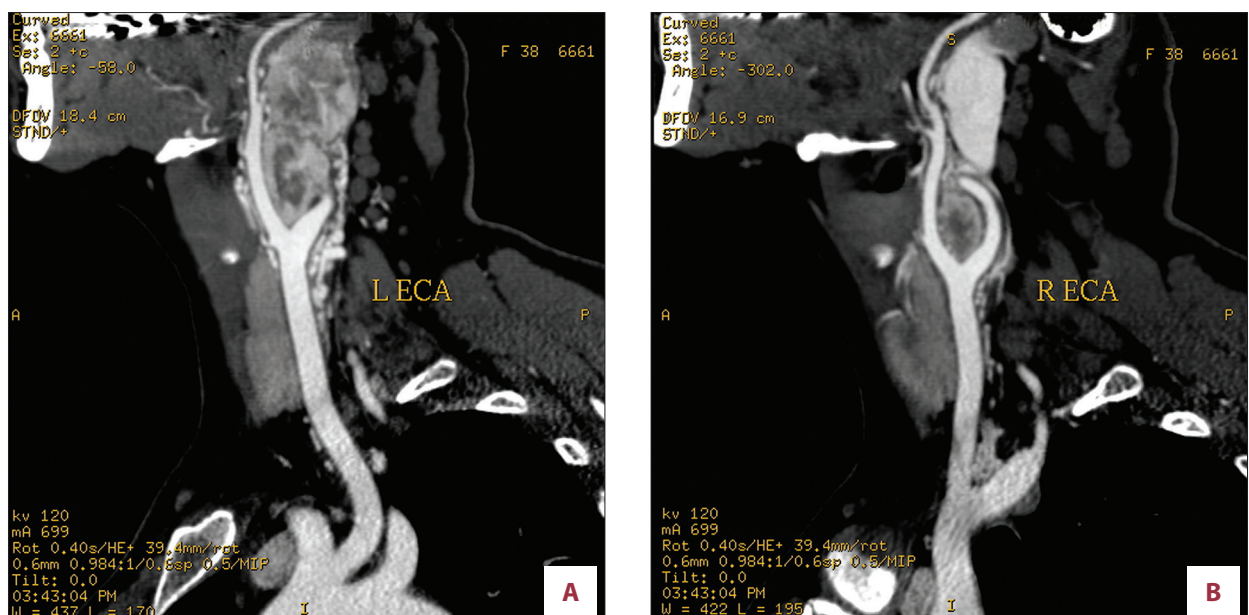
## Case Report

A 34-year-old woman referred to our department with a history of non-tender swellings on both sides of the neck. It was associated with dysphagia to solids, occasional breathing difficulty, and hoarseness of voice. The only physical finding of importance was restricted to the neck, where, on the left, a 5.0×3.0 cm non-tender, rubbery mass could easily be palpated over the carotid bifurcation. This was freely moveable horizontally but not vertically (Fontaine sign). Examination of the right neck revealed a somewhat smaller mass at the carotid bifurcation, which measured approximately 3.0×3.0 cm and

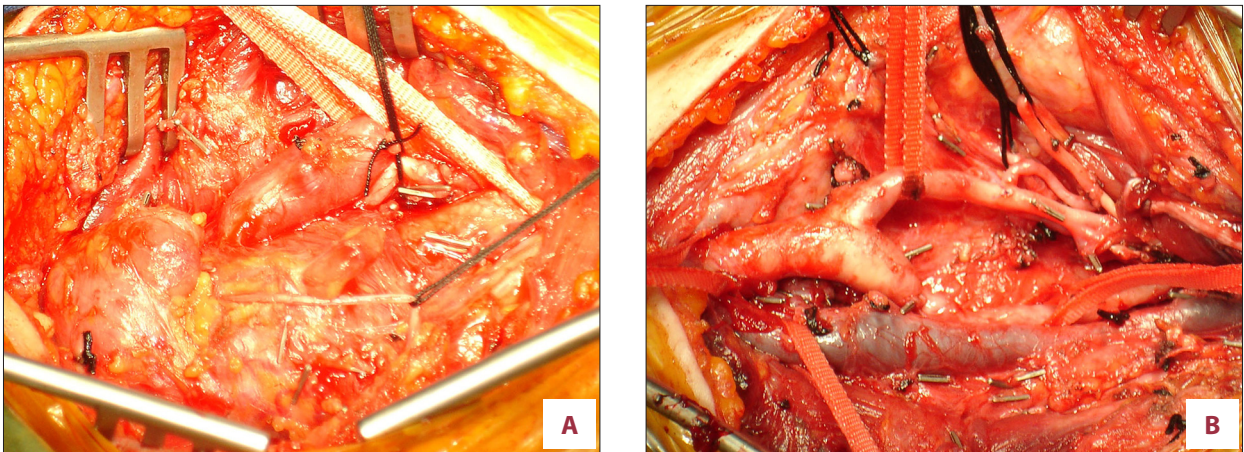
presented all the characteristics of the lesion noted on the left. Cranial nerve examinations were intact. Past medical history and family history were unremarkable.

On imaging evaluation, computer tomography (CT) and CT angiography showed a 6.9×3.4×2.0 cm lobular contoured, hypervascularized mass on the bifurcation of the left common carotid artery (Figure 1A) and also revealed a similar tumor with a maximal diameter of 2.2 cm (4.5×1.8×2.2 cm) on the right-side carotid bifurcation, which caused splaying of external and internal carotid arteries (Figure 1B). This finding was consistent with bilateral CBTs.

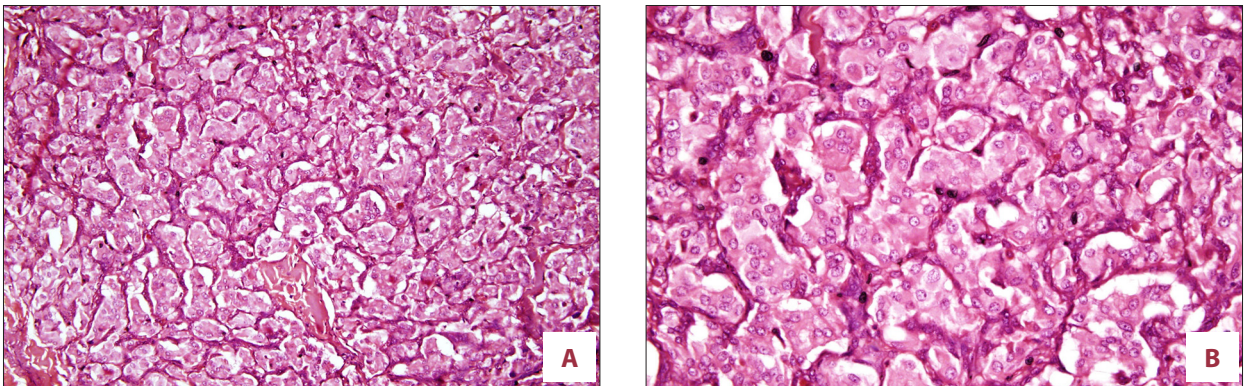
Based on our review of the literature and clinical experiences in the treatment of bilateral CBTs, we recommend resecting the largest tumor first. Therefore, the patient underwent surgical resection of the left-side tumor. Under general anesthesia, a lateral cervical incision was made parallel to the anterior border of sternocleidomastoid muscle, followed by careful dissection to expose the carotid vessels characteristically splayed by the tumor (Figure 2A). Proximal and distal control of the internal carotid artery, external carotid artery, and common carotid artery were performed before tumor resection. The dissection was difficult because the tumor was tightly attached to the carotid bifurcation and internal carotid artery. The vagus was identified at both the superior and inferior poles of the mass. The attempt to preserve it failed because the nerve was grossly infiltrated and no plane for dissection existed between it and the tumor. All feeding vessels were ligated. The tumor was completely removed (Figure 2B).



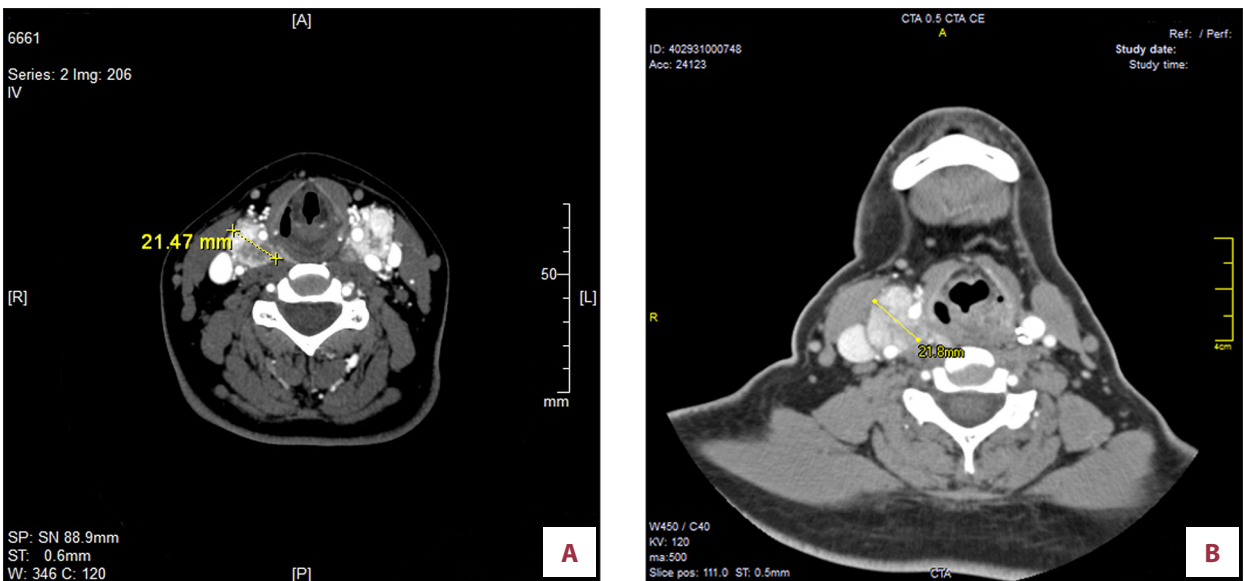
**Figure 1.** Sagittal reformation from a multislice spiral CT angiography of a 34-year-old woman. (A) A huge, lobular, contoured, highly vascularized carotid body tumor located at the left carotid artery bifurcation and extending through the skull base. Cranio-caudal axis diameter is about 7 cm. (B) Smaller tumor on the right side of the neck causing typical widening of the carotid bifurcation.



**Figure 2.** Intraoperative view of the left-sided carotid body tumor. (A) Huge hypervascular, lobular, contoured mass tightly attached to the left carotid bifurcation, external carotid artery, and internal carotid artery. (B) Undisturbed carotid arteries after tumor excision.



**Figure 3.** Tumor cells with typical organoid pattern and fibrovascular stroma around the nests. (A) HE  $\times 200$ , (B) HE  $\times 400$ .



**Figure 4.** Axial contrast-enhanced CT images showing the maximal diameter of the right-sided carotid body tumor. (A) The preoperative image. (B) Postoperative scan performed 5 years later. Notice that the maximal diameter of the contralateral side tumor shows no difference compared with the preoperative scan.

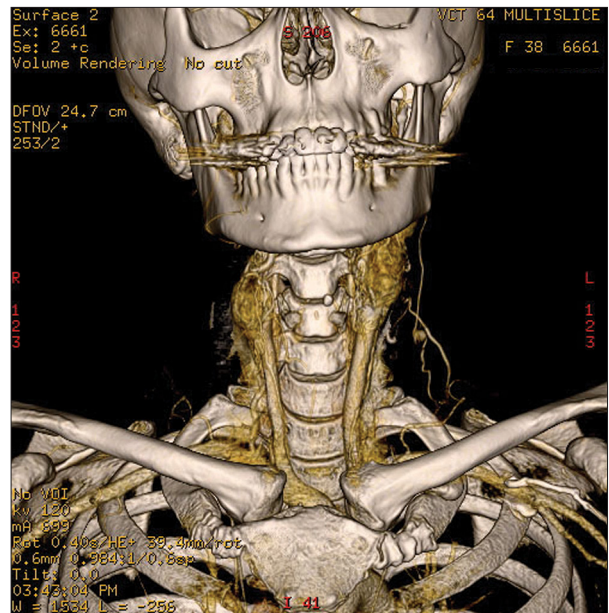
Histopathologically, the tumor was composed of small nests of neuroendocrine cells separated by fibrovascular structures and surrounded by sustentacular cells. Immunohistochemically, the tumor cells were positive for chromogranin and negative for low molecular weight cytokeratin. These findings confirmed the preoperative diagnosis of CBT (Figure 3A, 3B). Lymph node examination results were negative for metastasis.

In the early postoperative period, swallowing difficulty developed and hoarseness worsened due to vagal palsy. Four months after the operation, she could swallow without aspiration. We considered a “wait and scan” policy for the remaining contralateral CBT. Five years after the operation, the patient was completely free from her previous symptoms, and follow-up CT showed no growth of the right-side tumor (Figure 4A, 4B).

## Discussion

CBTs are rare, highly vascular, neuroendocrine tumors originating from the paraganglionic cells of the carotid bifurcation. They have an incidence of approximately 1:30 000 in the general population and are benign in the majority of the cases [3–5]. Malignant degeneration is rare and cannot be diagnosed histologically. Therefore, metastasis to a non-neuroendocrine tissue is regarded as the only true sign of malignancy [6]. These tumors are mostly sporadic (90%), but they can also be familial (10%). In some patients, mainly in the familial form, multiple CBTs can develop [2]. In our case, the possibility of a familial syndrome was excluded by the family history. Diagnosis is commonly established by duplex ultrasound, CT, and MRI. Therapeutic options for the treatment of CBTs include surgical resection, conventional radiotherapy, and permanent embolization. Because they are usually slow-growing tumors, a “wait and scan” policy might be justified in certain cases [3,7]. Today, complete surgical resection is considered the treatment of choice for the vast majority of cases, with the goal of treating or preventing local advancement of the tumor [8]. However, surgery is very challenging in patients with bilateral CBTs [9]. In these patients, the recommended procedure is staged, not simultaneous, excision because it carries the risk of bilateral cranial nerve palsies resulting in severe disabilities [10]. Depending on the postoperative cranial nerve status, therapy of the remaining tumor may be individually planned [3].

In 1971, Shamblin introduced a classification system of CBTs based on the tumor size and involvement of carotid vessels [11]. Shamblin Group 1 tumors are small and do not involve the surrounding vessels. Group 2 are adherent or partially surround and compress the carotid vessels, but are not problematic for surgical resection with a careful subadventitial dissection. Group 3 tumors have an intimate adherent relationship to the entire circumference of the carotid bifurcation, requiring



**Figure 5.** Multislice spiral CT angiography with 3-D volume-rendering reconstruction showing bilateral carotid body tumors.

partial or complete vessel resection and reconstruction. In our case, the left-side tumor was classified as Shamblin Group 2. The dissection was difficult because the tumor was partly adherent to the carotid bifurcation and the entire length of the internal carotid artery (Figure 5).

The major morbidity associated with surgery is related to postoperative cranial nerve dysfunction. The risk of cranial nerve palsy as a complication of CBT surgery has been reported to range from 10% to 40% [5]. The hypoglossal nerve and vagus nerve appeared to be most vulnerable to injury from the sacrifice or retraction. O’ Neil et al. reported that cranial nerve injury was more likely following the removal of larger tumors (average size of 3.95 cm) [2]. There has been controversy concerning the usefulness of preoperative embolization in larger tumors. Some authors prefer routine preoperative embolization, which has been reported to decrease tumor size by up to 25%. Others disagree on embolization due to post-embolization morbidity, such as stroke incidence as high as 10% [12,13]. The risk of complications from embolization always has to be weighed against the advantages.

Patients with bilateral CBTs are a somewhat special issue because bilateral lower cranial nerve palsies represent a severe life-threatening situation [14]. Velegrakis et al. recommended always resecting the largest tumor first. Depending on the postoperative cranial nerve status, therapy for the remaining tumor may be individually planned [15]. Unilateral vagal palsy may produce speech and swallowing difficulties in the immediate postoperative period. Most of the patients often

compensate these deficits by 4 to 6 months with speech and swallowing rehabilitation [16].

The potential morbidity of the surgery makes the management of contralateral CBT extremely difficult [17]. Patients with bilateral CBTs who present with a previous palsy of the vagus nerve are not good candidates for surgical resection. Bilateral vagal palsies would render them unable to speak or swallow, and in need of a tracheotomy and percutaneous gastrostomy.

In our patient, it was not possible to resect the tumor without sacrificing the left vagal nerve. Therefore, we decide to withhold all invasive therapy and to observe contralateral tumor growth with serial imaging studies. Five years after the operation, maximum diameter of the remaining lesion on the contralateral side showed no difference compared with the preoperative CT scan. Clinical follow-up is paramount to identify any evidence of tumor recurrence or growth of the contralateral CBT. Forest et al. recommend yearly follow-up within the first 5 years after the therapy [3]. Thereafter, the follow-ups may be once every 2–4 years.

In summary, the management of bilateral CBTs remains difficult. The recommended procedure is staged, not simultaneous, excision, since it carries the risk of bilateral cranial nerve

palsies resulting in severe disabilities. We always recommend resection of the largest tumor first. Therapeutic options for the remaining tumor may be individually planned. In patients with previous contralateral vagal palsies, the choice between surgery and watchful waiting is a balance between the natural potential morbidity and the predictable surgical morbidity. Therefore, to avoid bilateral cranial nerve deficits, these patients may be observed until tumor growth is determined, and treated by radiation therapy if needed.

## Conclusions

The treatment of bilateral CBTs should focus on preservation of the quality of life rather than on cure of the disease. Further studies are needed to critically assess the growth pattern or rate, determine the natural history of untreated CBTs, and to better define the role of radiation therapy.

## Acknowledgements

The authors would like to thank to Dr. Omer Isik for general support of the manuscript. No potential conflict of interest relevant to this article was reported. There were no external funding sources for this study.

## References:

1. Fennessy BG, Kozakewich HP, Silvera M et al: The presentation and management of multiple paraganglioma in head and neck. *Ir J Med Sci*, 2011; 180: 757–60
2. O'Neill S, O'Donnell M, Harkin D et al: A 22-year Northern Irish experience of carotid body tumours. *Ulster Med J*, 2011; 80: 133–40
3. Boedeker CC: Paragangliomas and paraganglioma syndromes. *GMS Curr Top Otorhinolaryngol Head Neck Surg*, 2011; 10: Doc03
4. Del Guercio L, Narese D, Ferrara D et al: Carotid and vagal body paragangliomas. *Transl Med UniSa*, 2013; 6: 11–15
5. Kollert M, Minovi AA, Drafi W, Bockmühl U: Cervical paragangliomas-tumor control and long-term functional results after surgery. *Skull Base*, 2006; 16: 185–91
6. Warshawski SJ, de Souza FM: The carotid body tumor. *J Otolaryngol*, 1989; 18: 306–10
7. Westerband A, Hunter GC, Cintora I et al: Current trends in the detection and management of carotid body tumors. *J Vasc Surg*, 1998; 28: 84–92
8. Paridaans MP, van der Bogt KE, Jansen JC et al: Results from craniocaudal carotid body tumor resection: should it be the standard surgical approach? *Eur J Vasc Endovasc Surg*, 2013; 46: 624–29
9. Marangos N, Schumacher M: Management of large bilateral glomus jugulare tumors. *HNO*, 1999; 47: 816–20
10. Kaman L, Singh R, Aggarwal R et al: Diagnostic and therapeutic approaches to carotid body tumours: report of three cases and review of the literature. *Aust N Z J Surg*, 1999; 69: 852–55
11. Shamblin WR, ReMine WH, Sheps SG, Harrison EG Jr: Carotid body tumor (chemodectoma). clinicopathologic analysis of ninety cases. *Am J Surg*, 1971; 122: 732–39
12. Muhm M, Polterauer P, Gstöttner W et al: Diagnostic and therapeutic approaches to carotid body tumors. review of 24 patients. *Arch Surg*, 1997; 132: 279–84
13. Little VR, Reilly LM, Ramos TK: Preoperative embolization of carotid body tumors: when is it appropriate? *Ann Vasc Surg*, 1996; 10: 464–68
14. Kataria T, Bisht SS, Mitra S et al: Synchronous malignant vagal paraganglioma with contralateral carotid body paraganglioma treated by radiation therapy. *Rare Tumors*, 2010; 30: e21
15. Velegrakis G, Kalikakis G, Karampekios S et al: Bilateral paraganglioma of the vagus nerve. *HNO*, 2001; 49: 471–75
16. Netteville JL, Jackson CG, Miller FR et al: Vagal paraganglioma: a review of 46 patients treated during a 20-year period. *Arch Otolaryngol Head Neck Surg*, 1998; 124: 1133–40
17. Obholzer RJ, Hornigold R, Connor S, Gleeson MJ: Classification and management of cervical paragangliomas. *Ann R Coll Surg Engl*, 2011; 93: 596–602