

Overlapping Stents with Coil Sandwich for Ruptured Blood-blister Aneurysm in a Patient with Ipsilateral Persistent Primitive Trigeminal Artery: A Case Report and Review of Literature

Abstract

Ruptured blood-blister aneurysms (RBBA) of the intracranial internal carotid artery (ICA) are associated with high morbidity and mortality. RBBA has been treated with trapping with high-flow bypass avoiding manipulation of RBBA. In case of the presence of persistent primitive trigeminal artery (PPTA), it is necessary to preserve the antegrade blood flow of PPTA because avoiding ischemic complications. Here, we present a case of RBBA concomitant with ipsilateral PPTA successfully treated with multistaged overlapping braided stents maintaining PPTA flow. A 30-year-old woman suffered from headache and was diagnosed RBBA of the intracranial ICA concomitant with ipsilateral PPTA. A reconstructive endovascular treatment using low-profile visualized intraluminal support (LVIS) stent was performed. However, it has recurred, and RBBA has finally been occluded after overlapping LVIS stents with coil sandwich that is not yet reported in the literature. We report the first case of overlapping LVIS stents with coil sandwich for RBBA.

Keywords: Coil sandwich, overlapping stent, ruptured blood-blister aneurysm

Introduction

Ruptured blood-blister aneurysms (RBBA) of the intracranial internal carotid artery (ICA) are rare, comprising 0.9%–6.5% of all ruptured intracranial cerebral aneurysms and high morbidity and mortality rates.^[1] RBBA are initially treated by trapping using high-flow bypass avoiding manipulation of RBBA. In contrast, persistent primitive trigeminal artery (PPTA) occurs with an incidence of 0.1%–0.6% in cerebral angiography.^[2] In patients with RBBA of the intracranial ICA, accompanied by an ipsilateral PPTA, antegrade blood flow in the PPTA (via the ICA) must be preserved. Here, we report the first case of overlapping LVIS stents with coil sandwich for RBBA.

Case Report

A 30-year-old woman presented with headache and vomiting. Magnetic resonance imaging on admission showed subarachnoid hemorrhage (SAH) with diffuse clotting in the basal cistern [Figure 1a]; however, magnetic resonance angiography (MRA) and digital subtraction

angiography (DSA) showed no evidence of aneurysm [Figure 1b-d]. Concomitantly, a right PPTA, originated from the proximal cavernous portion of the right ICA, was detected with severe hypoplasia of the lower basilar artery; the portion proximal to anastomosis with the vertebral artery was very faint [Figure 1b, c, e and f]. Based on angiographic analysis, the patient was diagnosed with SAH of unknown origin; thus, conservative treatment was initially implemented. Follow-up MRA on day 7 after onset showed *de novo* aneurysm that was <2 mm in maximum depth on the anterior wall of the supraclinoid segment of the right ICA; thus, the patient was diagnosed with RBBA [Figure 2a and b]. Reconstructive endovascular treatment (EVT) was chosen. Dual antiplatelet therapy with aspirin and clopidogrel was initiated before the procedure with a 300 mg bolus of aspirin and a 300 mg bolus of clopidogrel; these were followed by postoperative administration of aspirin at 100 mg/day and clopidogrel at 75 mg/day. Under general anesthesia, a 7-Fr Roadmaster 90-cm guiding catheter (Goodman, Aichi, Japan) was positioned at the petrous segment of the right ICA through the

This is an open access journal, and articles are distributed under the terms of the Creative Commons Attribution-NonCommercial-ShareAlike 4.0 License, which allows others to remix, tweak, and build upon the work non-commercially, as long as appropriate credit is given and the new creations are licensed under the identical terms.

For reprints contact: reprints@medknow.com

**Ryosuke Maeoka,
Ichiro Nakagawa¹,
Hiroyuki Ohnishi,
Hiroyuki Nakase¹**

Department of Neurosurgery,
Ohnishi Neurological Center,
Hyogo, ¹Department of
Neurosurgery, Nara Medical
University, Nara, Japan

Address for correspondence:
Dr. Ichiro Nakagawa,
840 Shijo-cho, Kashihara,
Nara 634-8522, Japan.
E-mail: nakagawa@naramed-u.
ac.jp

Access this article online

Website: www.asianjns.org

DOI: 10.4103/ajns.AJNS_177_19

Quick Response Code:



How to cite this article: Maeoka R, Nakagawa I, Ohnishi H, Nakase H. Overlapping stents with coil sandwich for ruptured blood-blister aneurysm in a patient with ipsilateral persistent primitive trigeminal artery: A case report and review of literature. Asian J Neurosurg 2019;14:1236-9.

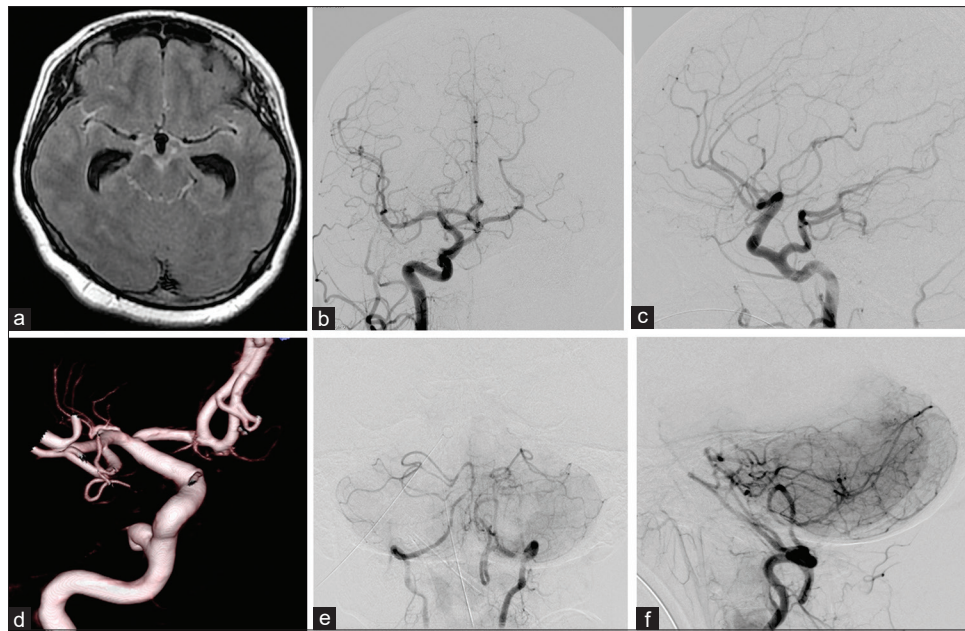


Figure 1: (a) Magnetic resonance imaging shows diffuse subarachnoid hemorrhage. (b-d) Digital subtraction angiography shows no evidence of aneurysm. (e and f) Concomitantly, ipsilateral persistent primitive trigeminal artery is shown with severe hypoplasia of the basilar artery. The section that is proximal to anastomosis with the vertebral artery is very faint

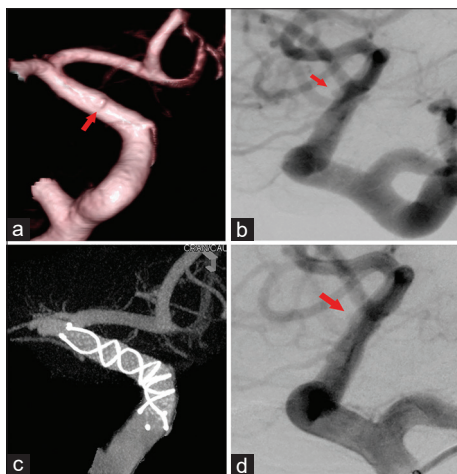


Figure 2: (a) Three-dimensional digital subtraction angiography on day 7 after onset shows *de novo* appearance of a blood-blister aneurysm (arrow) on the anterior wall of the supraclinoid segment of the right internal carotid artery. (b) A *de novo* blood-blister aneurysm (arrow) is present at the working angle on digital subtraction angiography. (c) Cone-beam computed tomography shows that the low-profile visualized intraluminal support stent has been deployed. (d) The blood-blister aneurysm has obliterated on postoperative digital subtraction angiography

right common femoral artery access. A 4-Fr Cerulean G 125-cm catheter (Medikit, Tokyo, Japan) was positioned at the cavernous segment. A Headway 21 microcatheter (MicroVention-Terumo, Tustin, CA, USA) was placed across the blood-blister aneurysm (BBA) neck, and a 4.5 mm × 23 mm low-profile visualized intraluminal support (LVIS) stent was deployed [Figure 2c]. The BBA did not depict after deployment of the LVIS stent [Figure 2d]; however, follow-up DSA on day 14 after onset showed a recurrence of the BBA [Figure 3a]. A second

treatment was performed using a stent-in-stent technique with a 4.5 mm × 18 mm LVIS stent [Figure 3b], and the BBA was almost occluded [Figure 3c]. The postoperative course was good; the patient exhibited a Glasgow Outcome Scale (GOS) score of 5 at discharge. Aspirin and clopidogrel were administered as postprocedural maintenance therapy. Follow-up DSA at 3 months after onset showed BBA regrowth [Figure 4a and b]. A third treatment was performed, comprising an overlapping LVIS stent (4.5 mm × 18 mm) with coil sandwich between the stents with HyperSoft three-dimensional coil (1 mm × 2 cm; MicroVention-Terumo), using the semi-jailing technique intended for reduction of porosity, by sandwiching the coil near the BBA neck. Finally, the BBA obliterated, and patency of the anterior choroidal artery was confirmed [Figure 4c-e].

The postoperative course was good. Follow-up DSA at 1 year after onset showed complete occlusion of the BBA, and the patient exhibited a GOS score of 5. Clopidogrel was eliminated after 1 year of treatment, whereas aspirin is planned to be administered as lifelong postprocedural maintenance therapy.

Discussion

RBBA is a rare but clinically important because of its high morbidity and mortality. Several treatment strategies for RBBA have been reported, including open surgery and EVT. However, optimal treatment for BBA remains uncertain.^[1,3,4] RBBA is fragile and can easily re-rupture at its neck during surgery. Trapping parent artery with high-flow bypass is often used for the treatment of RBBA because neck clipping is difficult and cerebral vasospasm

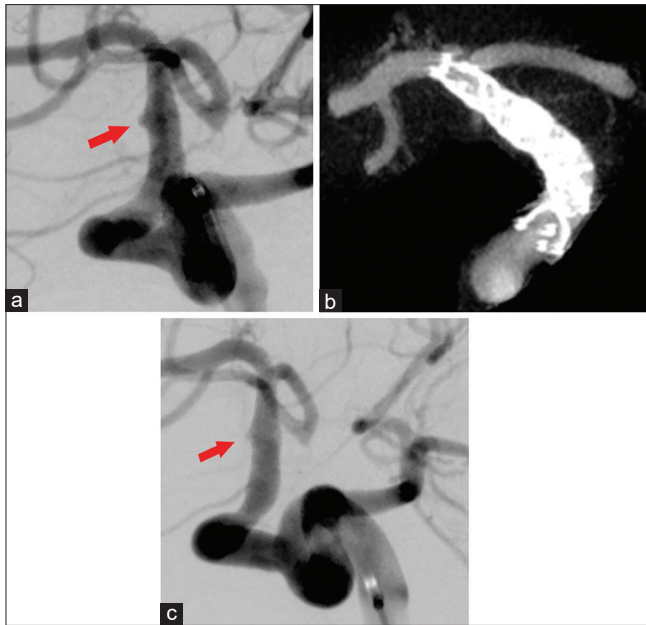


Figure 3: (a) Digital subtraction angiography on day 14 after onset shows residual blood-blister aneurysm. (b) Cone-beam computed tomography shows that the stent-in-stent technique obviously decreases porosity. (c) Postoperative digital subtraction angiography shows that the stent-in-stent technique decreases flow volume to the blood-blister aneurysm

results in ischemic complications in the ipsilateral hemisphere. However, RBBA in a patient with an ipsilateral PPTA cannot undergo trapping with a high-flow bypass because ischemic complications would likely arise in the area perfused by the PPTA. Conversely, EVT has been reported as potentially useful for patients with BBAs recently.^[1,4] In the present case, the preservation of PPTA antegrade flow was needed to preserve normal hemodynamics; therefore, reconstructive EVT was selected.

Reconstructive EVT for BBA of the ICA is effective for the preservation of antegrade flow. However, stent-assisted or balloon-assisted coil embolization for RBBA involves a high level of risk because the BBA is morphologically small, shallow, wide-necked, and fragile; moreover, the height of the BBA neck is generally less than twice the maximal dome height.^[5] Many studies have reported the LVIS stent to be safe and effective for the treatment of ruptured intracranial saccular aneurysms.^[6-9] Because the LVIS stent is braided with a single nickel–titanium (nitinol) wire, this type of stent is visible through fluoroscopy. This characteristic facilitates confirmation of complete stent opening and stent wall apposition.^[8] In the present case, therefore, single LVIS stent deployment was selected as initial treatment; additional LVIS stent placement through the stent-in-stent technique was chosen as the second treatment. In the third treatment for intractable BBA, an overlapping stent with coil sandwich was placed using a semi-jailing technique; this approach aimed to reduce porosity by sandwiching

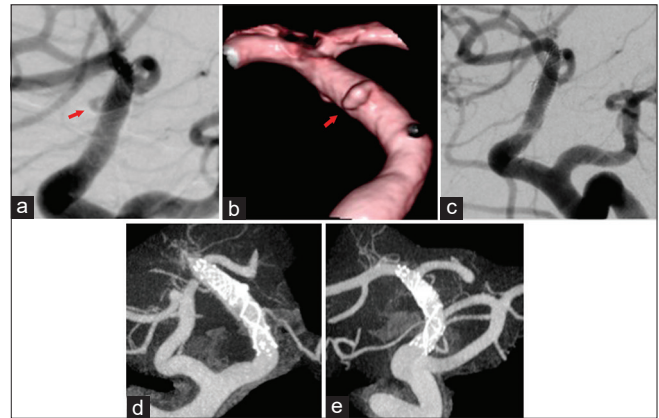


Figure 4: (a) Digital subtraction angiography in the 3rd month after onset shows blood-blister aneurysm regrowth and enlargement (arrow). (b) Three-dimensional digital subtraction angiography in the 3rd month after onset shows the blood-blister aneurysm. (c) Overlapping stents with coil sandwich finally result in obliteration of the blood-blister aneurysm. (d and e) Cone-beam computed tomography shows that stent-in-stent and stent-assisted coil embolization decrease porosity

the coil near the BBA neck. Fortunately, one loop of the coil was embolized within the BBA dome; this accelerated aneurysm thrombosis and healing.

Reconstructive EVT with a flow diverter has been shown to achieve a higher rate of complete occlusion and a lower rate of retreatment than the corresponding EVT without a flow diverter; furthermore, perioperative morbidity and mortality rates, as well as mid- and long-term clinical outcomes, are statistically similar between flow diverter and nonflow diverter groups.^[4] Notably, the use of multiple overlapping stents is a safe and effective strategy for correcting BBA remodeling in the supraclinoid ICA, although the number of stents required for effective treatment is currently unclear.^[10-13] Kim *et al.* described three patients in which successful obliteration of BBAs was performed in the supraclinoid ICA after placement of two or three overlapping nonbraided stents.^[14] Conversely, Gaughen *et al.* showed that three of six patients with BBAs required retreatment after initial treatment with overlapping nonbraided stents.^[11] Multiple overlapping braided LVIS stents may be more effective because LVIS stents effectively permit a greater reduction in wall shear stress, compared with overlapping nonbraided stents or single pipeline stents.^[15-17]

Conclusion

Here, we have reported the efficacy of EVT for RBBA in a patient who exhibited an ipsilateral PPTA. Overlapping LVIS stents with coil sandwich for RBBA may provide an effective treatment option, especially when antegrade flow is required.

Declaration of patient consent

The authors certify that they have obtained all appropriate patient consent forms. In the form the patient(s) has/have given his/her/their consent for his/her/their images and

other clinical information to be reported in the journal. The patients understand that their names and initials will not be published and due efforts will be made to conceal their identity, but anonymity cannot be guaranteed.

Financial support and sponsorship

Nil.

Conflicts of interest

There are no conflicts of interest.

References

- Shah SS, Gersey ZC, Nuh M, Ghonim HT, Elhammady MS, Peterson EC. Microsurgical versus endovascular interventions for blood-blister aneurysms of the internal carotid artery: Systematic review of literature and meta-analysis on safety and efficacy. *J Neurosurg* 2017;127:1361-73.
- Ishikawa T, Yamaguchi K, Anami H, Sumi M, Ishikawa T, Kawamata T. Treatment of large or giant cavernous aneurysm associated with persistent trigeminal artery: Case report and review of literature. *World Neurosurg* 2017;108:996.
- Gonzalez AM, Narata AP, Yilmaz H, Bijlenga P, Radovanovic I, Schaller K, *et al.* Blood blister-like aneurysms: Single center experience and systematic literature review. *Eur J Radiol* 2014;83:197-205.
- Rouchaud A, Brinjikji W, Cloft HJ, Kallmes DF. Endovascular treatment of ruptured blister-like aneurysms: A systematic review and meta-analysis with focus on deconstructive versus reconstructive and flow-diverter treatments. *AJNR Am J Neuroradiol* 2015;36:2331-9.
- Meckel S, Singh TP, Undrén P, Ramgren B, Nilsson OG, Phatouros C, *et al.* Endovascular treatment using predominantly stent-assisted coil embolization and antiplatelet and anticoagulation management of ruptured blood blister-like aneurysms. *AJNR Am J Neuroradiol* 2011;32:764-71.
- Iosif C, Piotin M, Saleme S, Barreau X, Sedat J, Chau Y, *et al.* Safety and effectiveness of the low profile visualized intraluminal support (LVIS and LVIS Jr) devices in the endovascular treatment of intracranial aneurysms: Results of the TRAIL multicenter observational study. *J Neurointerv Surg* 2018;10:675-81.
- Poncyłjusz W, Biliński P, Safranow K, Baron J, Zbroszczyk M, Jaworski M, *et al.* The LVIS/LVIS Jr. stents in the treatment of wide-neck intracranial aneurysms: Multicentre registry. *J Neurointerv Surg* 2015;7:524-9.
- Shankar JJ, Quateen A, Weill A, Tampieri D, Del Pilar Cortes M, Fahed R, *et al.* Canadian registry of LVIS Jr for treatment of intracranial aneurysms (CaRLA). *J Neurointerv Surg* 2017;9:849-53.
- Zhang X, Zhong J, Gao H, Xu F, Bambakidis NC. Endovascular treatment of intracranial aneurysms with the LVIS device: A systematic review. *J Neurointerv Surg* 2017;9:553-7.
- Fiorella D, Albuquerque FC, Deshmukh VR, Woo HH, Rasmussen PA, Masaryk TJ, *et al.* Endovascular reconstruction with the neuroform stent as monotherapy for the treatment of uncoilable intradural pseudoaneurysms. *Neurosurgery* 2006;59:291-300.
- Gaughen JR Jr., Hasan D, Dumont AS, Jensen ME, McKenzie J, Evans AJ. The efficacy of endovascular stenting in the treatment of supraclinoid internal carotid artery blister aneurysms using a stent-in-stent technique. *AJNR Am J Neuroradiol* 2010;31:1132-8.
- Kim BM, Chung EC, Park SI, Choi CS, Won YS. Treatment of blood blister-like aneurysm of the internal carotid artery with stent-assisted coil embolization followed by stent-within-a-stent technique. Case report. *J Neurosurg* 2007;107:1211-3.
- Walsh KM, Moskowitz SI, Hui FK, Spiotta AM. Multiple overlapping stents as monotherapy in the treatment of “blister” pseudoaneurysms arising from the supraclinoid internal carotid artery: A single institution series and review of the literature. *J Neurointerv Surg* 2014;6:184-94.
- Kim YW, Park IS, Baik MW, Jo KW. Endovascular treatment of blood blister-like aneurysms using multiple self-expanding stents. *J Korean Neurosurg Soc* 2011;49:116-9.
- Wang C, Tian Z, Liu J, Jing L, Paliwal N, Wang S, *et al.* Flow diverter effect of LVIS stent on cerebral aneurysm hemodynamics: A comparison with enterprise stents and the pipeline device. *J Transl Med* 2016;14:199.
- Mokin M, Chinea A, Primiani CT, Ren Z, Kan P, Srinivasan VM, *et al.* Treatment of blood blister aneurysms of the internal carotid artery with flow diversion. *J Neurointerv Surg* 2018;10:1074-8.
- Zhu D, Yan Y, Zhao P, Duan G, Zhao R, Liu J, *et al.* Safety and efficacy of flow diverter treatment for blood blister-like aneurysm: A systematic review and meta-analysis. *World Neurosurg* 2018;118:e79-86.