

# Conventional four field radiotherapy versus computed tomography-based treatment planning in cancer cervix: A dosimetric study

Abhishek Gulia, Firuza Patel, Bhavana Rai, Anshuma Bansal, Suresh C. Sharma

## Abstract

**Background:** With advancements in imaging, wide variations in pelvic anatomy have been observed, thus raising doubts about adequate target volume coverage by conventional external radiotherapy fields based on bony landmarks. The present study evaluates the need for integrating computed tomography (CT)-based planning in the treatment of carcinoma cervix. **Aims:** To estimate inadequacies in target volume coverage when using conventional planning based on bony landmarks. **Materials and Methods:** The study consisted of 50 patients. Target volume delineation was done on planning CT scans, according to the guidelines given in literature. The volume of target receiving 95% of prescribed dose (V95) was calculated after superimposing a conventional four field box on digitally reconstructed radiograph. The geographic miss with conventional four field box technique was compared with the CT-based target volume delineation. **Results:** In 48 out of 50 patients, the conventional four field box failed to encompass the target volume. The areas of miss were at the superior and lateral borders of the anterior-posterior fields, and the anterior border of the lateral fields. The median V95 for conventional fields marked with bony landmarks was only 89.4% as compared to 93% for target delineation based on CT contouring. **Conclusions:** Our study shows inadequate target volume coverage with conventional four field box technique. We recommend routine use of CT-based planning for treatment with radiotherapy in carcinoma cervix.

**Key words:** Four field technique, carcinoma cervix, geographic miss

## Introduction

External beam radiotherapy (EBRT) plays an important role in the management of patients with carcinoma cervix. EBRT treats the whole pelvis, including clinically and radiologically apparent tumor, uterine corpus, upper part of vagina, parametrium, and the draining lymph nodes. The central disease (cervix, vagina, and medial parametria) is further boosted by intracavitary brachytherapy. Conventionally, EBRT planning is based on standard bony landmarks using X-rays and can be delivered by anterior–posterior and posterior–anterior (AP-PA) parallel opposed fields or the four field box technique. Although the AP-PA field technique provides good coverage to the target volume, its main disadvantages are inferior dose distribution in the region of parametrium and increased dose to bladder, rectum, and subcutaneous tissue. The conventional four field box technique with parallel opposed AP-PA fields and two lateral opposed fields achieves better dose distribution than the parallel opposed AP-PA field technique in terms

of tumor coverage and a relatively reduced dose to the normal tissues. With the use of sectional imaging, wide variations have been reported in the pelvic anatomy of individual patients. Variations include different levels of aortic bifurcation, altered sacral curvature, and varying course of pelvic vessels.<sup>[1-3]</sup> These have raised concerns over the adequate coverage of the target volume with conventional two-dimensional fields based on standard bony landmarks.

Three-dimensional conformal radiotherapy and intensity-modulated radiotherapy are now increasingly being used in the developed countries. These newer techniques have reported decrease in normal tissue toxicity, along with decrease in the chances of geographic miss. However, whether they are superior in terms of local control and survival also is yet to be demonstrated in larger trials.

By contrast, many centers in developing countries still prefer to use conventional X-ray-based planning using the standard bony landmarks. This is because in developing countries, where patient load is high, X-ray-based planning is simple, less time consuming, and cost-effective as compared to three-dimensional CT-based planning.

However, randomized studies comparing volumetric planning versus conventional planning in carcinoma cervix are lacking. At our center also, before the inception of this study, volumetric planning was done only in selected patients due to logistical constraints. Thus, before integrating volumetric planning in our routine practice, the present study was designed to compare conventional four field planning based on standard bony landmarks versus volumetric planning in patients of carcinoma cervix undergoing radiotherapy.

Department of Radiotherapy, Post Graduate Institute of Medical Education and Research, Chandigarh, India

**Correspondence to:** Dr. Abhishek Gulia,

E-mail: drabhishekgulia@gmail.com

### Access this article online

Quick Response Code:



**Website:**

www.sajc.org

**DOI:**

10.4103/2278-330X.114116

## Materials and Methods

Fifty previously untreated biopsy-proven patients of locally advanced uterine cervix cancer stage II-III registered at our institute were included. Their ages ranged from 32 to 75 years (median 55 years). Thirty-two patients (64%) belonged to Stage IIB and 18 (36%) to Stage IIIB. All patients were planned for radical radiation of 46Gy delivered in 23 fractions over 4.5 weeks and 78% patients received concomitant chemotherapy with weekly cisplatin at a dose of 40 mg/m<sup>2</sup>. After EBRT, all patients received two sessions of high-dose rate (HDR) intracavitary brachytherapy, 1 week apart, with a dose of 9 Gy per fraction. In all patients, the treatment was completed within 56 days of starting external radiation.

A thorough clinical examination along with a baseline work up was carried out for all patients.

CT simulation was done after oral, rectal, and IV contrast for proper delineation of target volume. Slices were taken from T12-L1 level up to the lesser trochanter level of the femur, with the slice thickness of 3.75 mm. Patients were excluded if they had positive paraaortic nodes (nodes enlarged >1 cm).

The clinically and the radiologically visualized primary tumor, along with the whole uterine corpus, cervix, upper third of the vagina, and parametrium, was included in the clinical target volume (CTV Tumor) of the tumor. At the time of inception of this study, a literature review identified two guidelines, one by Taylor *et al.*, and the other by Small *et al.*, regarding the delineation of pelvic nodal CTV.<sup>[4,5]</sup> The nodal CTV included the presacral, obturator, external and internal iliac, and common iliac lymph nodal groups (CTV Nodal). Nodal CTV was delineated from the bifurcation of aorta in accordance with the atlas by Taylor *et al.*, as an aid for target volume definition of the pelvic nodal regions.<sup>[4]</sup> Although we found that the aortic bifurcation often occurred higher than the L4-L5, the upper border of the field was kept at L4-L5 junction. The decision for modifying this was taken in accordance with the guidelines given by Small *et al.*, who advocated that the nodal CTV for common iliac vessels should be restricted to 7 mm below the L4-L5 intervertebral space.<sup>[6]</sup> Because modifying superior field border would have resulted in a sharp increase in the irradiated volume, especially with the use of concurrent chemoradiation, to limit the potential increase in normal tissue toxicity and the resultant reduction in treatment tolerance, the superior border was kept at the L4-L5 interface and nodal CTV extending above the L4-L5 interspace was excluded from the treatment field. Unlike Taylor's guidelines,<sup>[4]</sup> we did not extend the contour around external iliac vessels anterolaterally along the iliopsoas muscle by an additional 10 mm. This was in accordance with RTOG guidelines by Small *et al.*<sup>[5]</sup>

The organs at risk, including bladder, rectum, and small bowel, were delineated as per their extent. Target volume was defined as CTV total (CTV tumor + CTV nodal). As the uterus is a highly mobile organ, a margin for its movements was separately defined as internal target volume (ITV uterus).<sup>[6]</sup> Planning target volume (PTV) included margin to

the total CTV and ITV uterus. Planning was done on the Eclipse treatment planning system (Varian Medical Systems, Palo Alto, CA, USA). Patients were treated using this plan.

To quantify the extent to which the target volume was being missed with standard four field plans, a four field box plan was generated using the standard bony landmarks. For AP-PA fields, the superior border was taken at the L4-L5 intervertebral space and the inferior border was taken at the lower border of the obturator foramen. The lateral borders were taken 2 cm on either side of the widest part of the pelvic brim. For the lateral fields, the superior and inferior borders were the same as defined for the AP-PA fields. The posterior border covered the sacral hollow. The anterior border was taken at the anterior edge of pubic symphysis while ensuring at least a 2.5-cm margin from the anterior aspect of the L5 vertebral body.

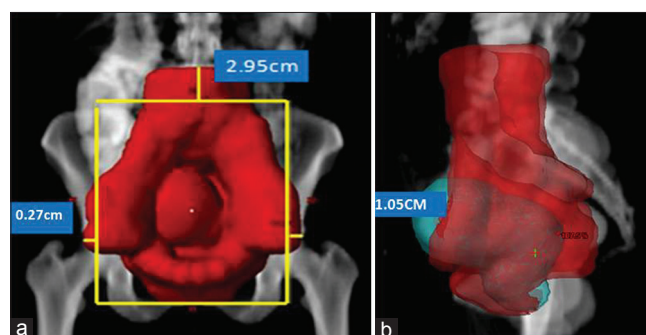
The target volume delineated was then projected onto the digitally reconstructed radiograph (DRR) and the distance of the target volume from the edges of the field was measured using the Beam's Eye View [Figure 1a and 1b]. The volume of the target receiving at least 95% of the prescribed dose was calculated (V95). V95 was subtracted from the total target volume to calculate the volume that would have been missed in conventional planning based on bony landmarks. In addition, uterine version was noted and categorized into three: Anteverted, straight, and retroverted. The distance of the uterine fundus from the sacral promontory was calculated as a measure of the bulk and version of uterine corpus. For this, a vertical tangent was drawn at the anteriormost extent of uterine fundus and the distance was measured from sacral promontory to the point of intersection of this tangent with the line joining sacral promontory with the symphysis pubis [Figure 2].

## Statistical analysis

Descriptive statistics including mean, median, and 95% confidence intervals of the mean were derived for parameters related to the miss and the same were correlated against disease-related parameters.

## Results

In only two patients (4%) out of 50 was the whole of the target volume encompassed by the standard four field box



**Figure 1:** Measurement of extent of miss of target volume at various borders (a) superior and lateral border in anterior field; and (b) anterior border in lateral field

marked on bony landmarks. The mean and median V95 for 2-D plans based on bony landmarks were 88.95% and 89.4%, respectively (95% confidence intervals of means 87.25-90.66%). The median miss at superior border of the fields from aortic bifurcation to L4-L5 junction was 2.95 cm, and the maximum was up to 7.27 cm.

The lateral borders of the anterior fields failed to encompass the target in 54% ( $n = 23$ ) patients. The median miss at the lateral borders was 0.27 cm, and the maximum was 2.62 cm. In all cases the miss at the lateral borders of the anterior fields was due to extension of the external iliac lymph node contours beyond the conventional bony landmarks for lateral fields.

For the lateral fields, the target volume extended beyond the anterior borders of the fields in 41 patients (82%). The median miss from anterior border was 1.05 cm and maximum was 4.91 cm [Table 1]. In majority of the

patients, the miss at the anterior borders of the lateral fields was due to delineation of the outlying group of the external iliac nodal volume; however, in 10 (24.39%) out of 41 patients the miss was due to bulky anteverted uterus.

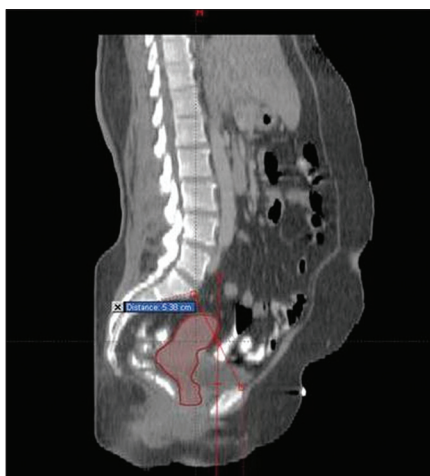
The median distance of the uterine fundus from the sacral promontory in patients with anteverted uterus ( $n = 36$ ) was 6.33 cm. Patients with increased anteversion had a bulkier uterus with associated hydro pyometra.

On comparing the mean irradiated volume receiving 95% and 50% of the prescribed dose by the four field technique using bony landmarks and the CT-based plan, it was found that there was a statistically significant increase in the volume of tissue irradiated while using the CT-based 3-D plans [Table 2]. In addition, the mean dose to the bowel and bone marrow was increased significantly in the CT-based plan when compared with the standard four field plan [Table 2].

## Discussion

In the treatment of cancer cervix with radiotherapy, the traditional four field technique has been used for decades with fairly good locoregional control (LRC) and acceptable toxicity.<sup>[7-9]</sup> With the advancement in imaging techniques, radiotherapy planning has also witnessed drastic changes from 2-D planning to 3-D planning. In the quest for better LRC and lower normal tissue toxicity, clinicians are shifting from conventional to conformal planning. While the target volume is more or less agreed upon, precise localization of structures for target delineation and their anatomic boundaries remains controversial.<sup>[8]</sup> Although conformal plans have been found to be superior to conventional 2-D plans in a majority of anatomical sites, many centers still continue to use conventional 2-D planning based on conventional bony landmarks for target delineation in cancer cervix. This is especially true in developing countries where increased patient load and lack of facilities have hampered the use of CT-based planning, which is both time consuming and expensive as compared to conventional 2-D planning. Moreover, there is paucity of data comparing conventional 2-D planning with 3-D CT-based planning in cancer cervix. Because there is lack of clear-cut clinical data showing the comparative efficacy of 3-D planning and dose delivery over conventional techniques, our department carried out a comparative study of the two.

A study by Russel *et al.*,<sup>[10]</sup> reported the value of pelvic magnetic resonance imaging (MRI) in the design of



**Figure 2:** Measurement of distance of the uterine fundus from the sacral promontory

**Table 1: Pattern of target volume missed with conventional four field box technique**

Radiation fields	No of patients with TV extending outside (% of total cases)	Length of TV outside the border (cm)	
		Median	Range
AP-PA fields			
Superior border	48 (96)	2.95	0-7.27
Lateral border	27 (54)	0.27	0-2.62
Lateral fields			
Anterior border	41 (82)	1.05	0-4.91

AP-PA=Anterior-posterior and posterior-anterior

**Table 2: Comparison of few dosimetric parameters between the two plans**

Dose-Volume parameters	Mean		95% confidence interval		P value (t-test)
	Four field	CT-based field	Four field	CT-based field	
Vol. receiving 95% of prescribed dose (cu cm)	2851.41	3155.66	2732.11 to 2971.71	3046.03 to 3215.28	<0.001
Vol. receiving 50% of prescribed dose (cu cm)	7505.36	7771.09	7145.58 to 7865.14	7426.55 to 8115.64	<0.001
D mean bowel (% of prescribed dose)	51.38	55.74	46.80 to 55.98	51.23 to 60.25	<0.001
D mean bone marrow (% of prescribed dose)	91.02	91.87	90.06 to 91.99	90.84 to 92.89	<0.001

CT=Computed tomography

pelvic fields of the box technique. In 25 patients with FIGO clinical Stages 1B-1VA, MRI was used primarily to define the treatment volume required to encompass the primary disease and its direct regional extensions, and only secondarily to assess the presence or absence of lymph node metastases. The sagittal scans revealed that use of “conventional” or “standard” lateral radiation portals resulted in a failure to encompass all gross cancer extensions (marginal miss) in 24% patients. The use of conventional lateral portals resulted in an incomplete coverage (62.5%) of the uterine fundus, of whom three had gross cancer extension involving either the uterine cavity or the myometrium of the lower uterine segment. The authors concluded that conventional lateral portal design, as in standard radiation oncology texts, may be suboptimal for a significant percentage of patients with locally advanced or bulky cervical cancer, and could be a contributing cause of failure to control pelvic disease.

With the increasing use of 3-D planning, interfraction, and intrafraction organ motion is being studied extensively in order to adequately cover the target volume. Taylor *et al.*,<sup>[6]</sup> performed an MRI in 33 patients with gynecological cancer on 2 consecutive days to study the interfraction movement of the uterus and cervix. They observed that large movements of uterus occurred in the superior–inferior and anterior–posterior directions, although cervical displacement was less marked and recommended asymmetrical margin with CTV–PTV expansion of the uterus, cervix, and upper vagina of 15 mm AP, 15 mm SI, and 7 mm laterally. Our study also used an ITV margin in accordance with Taylor *et al.* As a result, in 82% of patients, the standard four field based on bony landmarks failed to encompass the target volume defined by CT as compared with previous studies discussed earlier.

Conventionally, the upper border of the anterior field in a four field box technique has been the L4-L5 junction as this is thought to represent the aortic bifurcation. However, this is not always true as a wide anatomic variation of the same has been reported in various studies. In one of the earlier studies by Zunino *et al.*,<sup>[1]</sup> in 1999, the authors performed lymphangiography in some patients and anatomic studies on a few cadavers to localize the pelvic lymph nodes within the borders of the standard four field radiotherapy technique. In 49% of the patients, the posterior border of the lateral field failed to encompass the posterior extension of the tumor. They observed that besides tumor volume and position of the uterine body there could be important variations in the position of pelvic lymph node drainage chains. In our study, in 48 out of 50 patients as well the level of bifurcation was above the L4-L5 level. However, at the time of our study, we were skeptical about deviating from the conventional standard recommendations and thus kept the upper border of the anterior field at the L4-L5 junction. Moreover, the guidelines by RTOG also define the superior border of the field based on bony anatomy. Furthermore, the

disadvantage of delineating based on guidelines proposed by Taylor *et al.*, lies in the excessive volume of the small bowel and bone marrow that can potentially get irradiated [Table 2].

In our study, the external iliac lymph nodes contouring was done in accordance with both RTOG<sup>[5]</sup> where we did not give an extra 10-mm margin for lateral expansion of CTV. A similar recommendation has been made by Toita *et al.*,<sup>[11]</sup> who also do not advocate an extra margin for the anterolateral group of external iliac lymph nodes. Moreover, there is a lack of any evidence for isolated failures at the lateral external iliac group of lymph nodes in the literature. Sakuragi *et al.*<sup>[12]</sup> analyzed the distribution of patterns of metastatic nodes in 208 patients who underwent radical hysterectomy and pelvic lymph node dissection and reported an incidence of only 3.8% metastasis in the external iliac lymph nodes. Had we attempted to cover the entire target volume, at both the superior and lateral aspect of the anterior posterior field, the irradiated volume would have been grossly increased. As these patients receive concurrent chemoradiation, tolerance to such extended fields was also an issue. Thus, this decision was taken, anticipating the excessive acute toxicity mainly due to increased volume of small bowel and bone marrow irradiation, and also unplanned treatment breaks, which could be detrimental for tumor control. Our study indicates the need for target volume delineation using CT-based planning while using conventional four field box technique, in patients with locally advanced uterine cervix carcinoma. However, one of the major difficulties lies in the definition of the CTV components. While there is general agreement on what constitutes the CTV, defining these different components for delineation is problematic and may vary from institute to institute.

The present study shows only dosimetric data of the target volume coverage of the treatment plans. We recommend CT-based treatment planning for locally advanced cases of uterine cervix carcinoma based on our observation of target volume miss in 48 out of 50 cases. The clinical significance of geographic miss of target volume in the common iliac nodal region is to be ascertained, and a longer follow-up of the study cohort is required.

## References

1. Zunino S, Rosato O, Lucino S, Jauregui E, Rossi L, Venencia D. Anatomic study of the pelvis in carcinoma of uterine cervix as related to the box technique. *Int J Radiat Oncol Biol Phys* 1999;44:53-9.
2. Justino PB, Baroni R, Blasbalg R, Carvalho Hde A. Clinical tumor dimensions may be useful to prevent geographical miss in conventional radiotherapy of uterine cervix cancer: A Magnetic Resonance Imaging- Based study. *Int J Radiat Oncol Biol Phys* 2009;74:503-10.
3. Greer BE, Koh WJ, Figge DC, Russell AH, Cain JM, Tamimi HK. Gynecologic radiotherapy fields defined by intraoperative measurements. *Gynecol Oncol* 1990;38:421-4.
4. Taylor A, Rockall AG, Powell ME. An atlas of the pelvic lymph node regions to aid radiotherapy target volume definition. *Clin Oncol* 2007;19:542-50.
5. Small W, Mell LK, Anderson P, Creutzberg C, De Los Santos, Gaffney D, *et al.* Consensus guidelines for delineation of clinical

- target volume for intensity-modulated pelvic radiotherapy in postoperative treatment of endometrial and cervical cancer. *Int J Radiat Oncol Biol Phys* 2008;71:428-34.
6. Taylor A, Powell ME. An assessment of interfraction uterine and cervical motion: Implications for radiotherapy target volume definition in gynaecological cancer. *Radiotherapy and Oncology* 2008;88:250-57.
  7. Saibishkumar EP, Patel FD, Sharma SC. Results of radiotherapy alone in the treatment of carcinoma of uterine cervix: A retrospective analysis of 1069 patients. *Int J Gynaecol Cancer* 2005;15:890-7.
  8. Saibishkumar EP, Patel FD, Sharma SC. Evaluation of late toxicities of patients with carcinoma of cervix treated with radical radiotherapy: An audit from India. *Clin Oncol* 2006;18:30-7.
  9. Lanciano RM, Pajak TF, Martz K, Hanks GE. The influence of treatment time on outcome for squamous cell cancer of the uterine cervix treated with radiation: A patterns-of-care study. *Int J Radiat Oncol Biol Phys* 1993;25:391-7.
  10. Russel AH, Walter JP, Anderson MW, Zukowski CL. Saggital magnetic resonance imaging in the design of lateral radiation treatment portals for patients with locally advanced squamous cell carcinoma of the cervix. *Int J Radiat Oncol Biol Phys* 1992;23:445-9.
  11. Toita T, Ohno T, Kaneyasu Y, Uno T, Yoshimura R, Kodaira T, *et al.* A Consensus-based Guideline Defining the Clinical Target Volume for Pelvic Lymph Nodes in External Beam Radiotherapy for Uterine Cervical Cancer. *Jpn J Clin Oncol* 2010;40:456-463.
  12. Sakuragi N, Satoh C, Takeda N, Hareyama H, Takeda M, Yamamoto R, *et al.* Incidence and distribution pattern of pelvic and paraaortic lymph node metastasis in patients with Stages IB, IIA, and IIB cervical carcinoma treated with radical hysterectomy. *Cancer* 1999;85:1547-54.

**How to cite this article:** Gulia A, Patel F, Rai B, Bansal A, Sharma SC. Conventional four field radiotherapy versus computed tomography-based treatment planning in cancer cervix: A dosimetric study. *South Asian J Cancer* 2013;2:132-5.

**Source of Support:** Nil. **Conflict of Interest:** None declared.