


Case Report

Nonmetastatic castration-resistant prostate cancer treated with salvage focal brachytherapy after external beam radiotherapy

Soichiro Yoshida,¹ Yoh Matsuoka,¹ Kazuma Toda,² Sho Uehara,¹ Hajime Tanaka,¹  Minato Yokoyama,¹ Kazutaka Saito,¹ Ryoichi Yoshimura² and Yasuhisa Fujii¹

Departments of ¹Urology, and ² Radiation Therapeutics and Oncology, Tokyo Medical and Dental University, Tokyo, Japan

Abbreviations & Acronyms

ADT = androgen deprivation therapy
 CRPC = castration-resistant prostate cancer
 CT = computed tomography
 EBRT = external beam radiotherapy
 GI = gastrointestinal
 GU = genitourinary
 HIFU = high-intensity focused ultrasound
 LDR = low-dose rate
 MRI = magnetic resonance imaging
 PSA = prostate-specific antigen
 RP = radical prostatectomy
 SBRT = stereotactic body radiotherapy

Introduction: The efficacy of salvage local therapy after external beam radiotherapy has recently gained attention. However, a challenge with these therapies is the risk of significant genitourinary and gastrointestinal toxicity. Focal brachytherapy may be a treatment option because of its potential to reduce side effects.

Case presentation: A patient with castration-resistant prostate cancer was found to be free of metastases on whole-body magnetic resonance imaging following external beam radiotherapy, and prostate biopsy revealed a localized recurrence in the ventral prostate. The patient underwent salvage focal brachytherapy and had a prostate-specific antigen progression-free survival of 23 months. No adverse effects were observed following salvage brachytherapy.

Conclusion: Our case suggests that salvage focal brachytherapy may be an effective local treatment option for nonmetastatic castration-resistant prostate cancer that has relapsed after external beam radiotherapy, wherein the lesion is confined to a small area within the prostate.

Key words: brachytherapy, hemi-gland focal therapy, prostatic neoplasms, castration-resistant, radiotherapy, salvage therapy.

Correspondence: Soichiro Yoshida M.D., Ph.D., Department of Urology, Tokyo Medical and Dental University Graduate School, 1-5-45 Yushima, Bunkyo-Ku, Tokyo 113–8510, Japan.
 Email: s-yoshida.uro@tmd.ac.jp

How to cite this article: Yoshida S, Matsuoka Y, Toda K *et al.* Nonmetastatic castration-resistant prostate cancer treated with salvage focal brachytherapy after external beam radiotherapy. *IJU Case Rep.* 2021; **4**: 228–230.

This is an open access article under the terms of the Creative Commons Attribution-NonCommercial-NoDerivs License, which permits use and distribution in any medium, provided the original work is properly cited, the use is non-commercial and no modifications or adaptations are made.

Received 22 January 2021; accepted 6 April 2021.

Online publication 3 May 2021

Keynote message

Local therapy can be a treatment option for nonmetastatic castration-resistant prostate cancer. The challenge with salvage therapy for recurrence after external beam radiotherapy is the risk of significant genitourinary and gastrointestinal toxicity. Salvage focal brachytherapy may be an effective local treatment option for nonmetastatic castration-resistant prostate cancer that has recurred after external beam radiotherapy, wherein the disease is confined to a small area within the prostate.

Introduction

A large phase III study has shown the life-prolonging benefit of enzalutamide, apalutamide, and darolutamide in the setting of nonmetastatic CRPC.¹ Data showing the oncologic benefit of local treatment for nonmetastatic CRPC are limited, and there are no comparative clinical trials.² The optimal management of hormone-naïve, recurrent prostate cancer after radiotherapy is also unknown due to the lack of large prospective trials. RP, brachytherapy, cryotherapy, HIFU, and SBRT are options for salvage treatment; however, for any of these therapies, the risk of GU and GI toxicity associated with local salvage is an important issue.³ Focal brachytherapy may be an option as salvage treatment for recurrent prostate cancer after radiotherapy because of its ability to precisely define the treatment area and its potential to reduce side effects. A small prospective study evaluating local salvage high-dose rate brachytherapy for patients with local recurrence after EBRT reported that the anticancer efficacy was comparable to a series of whole-gland salvage brachytherapy and that the incidence of urologic adverse events of grade 3 or greater was 1 in 15 patients.⁴

Here, we report a case of nonmetastatic CRPC that underwent salvage focal prostate brachytherapy after EBRT, wherein the lesion was confined to a small area within the prostate and achieved a PSA progression-free survival of 23 months.

Case presentation

A 64-year-old man receiving immunosuppressive therapy for myasthenia gravis was referred to our department because of high PSA levels. His serum PSA concentration had increased to 20.2 ng/mL. The prostate was stony hard on rectal examination, and a prostate biopsy revealed adenocarcinoma with a Gleason score of 9. CT and bone scintigraphy showed no findings suggestive of prostate cancer metastasis, and the patient was diagnosed with prostate cancer, clinical stage T2cN0M0. The patient was treated with neoadjuvant ADT and EBRT. During the neoadjuvant ADT of gonadotropin-releasing hormone agonist (goserelin), the PSA level began to increase after a nadir value of 0.81 ng/mL and bicalutamide was added. After EBRT (total dose: 70 Gy, 2 Gy/fraction, 5 fractions/week), the PSA decreased to an undetectable level (<0.02 ng/mL). The patient continued to receive ADT throughout the treatment, and his serum testosterone level was maintained below 50 ng/dL. Twenty-eight months after initiating ADT, PSA levels began to rise again. Bicalutamide was replaced by flutamide; however, the effect on the increasing PSA was very limited. Fifty-two months after initiating ADT, when the PSA was 1.42 ng/mL, whole-body MRI and prostate MRI revealed a 13-mm tumor in the ventral prostate with no metastases (Fig. 1). Prostate re-biopsy was performed for pathological confirmation, in which cancer was detected in the ventral prostate by MRI-targeted sampling. No malignant findings were identified in the other regions on either 18-core systematic biopsy or MRI. Under the diagnosis of prostate cancer recurrence confined to the ventral prostate, the patient underwent salvage focal LDR brachytherapy at a PSA of 3.18 ng/mL, 68 months after ADT. Under the approval of the ethics committee of our university (approval number: M2000-1871), iodine-125 loose seeds were implanted to deliver a prescribed dose of 110 Gy to the intraprostatic recurrent site using Spot Pro[®] (Nucletron, Veenendaal, Netherlands, Fig. 2). After 11 months of salvage brachytherapy, the PSA level decreased to 0.04 ng/mL; however, it increased to 0.837 ng/mL after 23 months (Fig. 3). The PSA doubling time was 2.2 months. Whole-body MRI did not identify prostate cancer recurrence or metastasis. No side effects, including GU or GI, occurred due to salvage brachytherapy. Apalutamide was introduced to this focal brachytherapy-resistant cancer and showed a good reduction in PSA levels.

Discussion

Herein, we describe a case that suggests the use of salvage focal brachytherapy as a treatment option for nonmetastatic CRPC that has relapsed after EBRT. Next-generation imaging modalities such as Gallium-68–prostate-specific membrane antigen positron emission tomography/CT and whole-body MRI have recently made it possible to detect metastases more accurately, and the efficacy of metastasis-directed therapy in oligometastatic CRPC has been reported in retrospective studies.^{5–7} Local therapy aimed to delay the introduction of new hormonal agents, reduce toxicity, and maintain patient quality of life may be an effective treatment in nonmetastatic CRPC. Furthermore, local treatment may reduce metastasis and

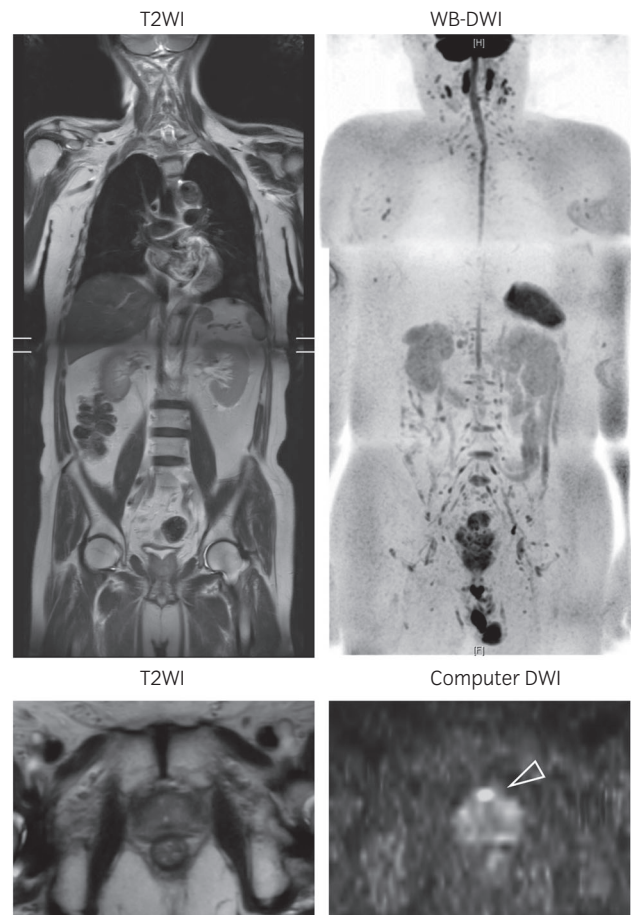


Fig. 1 Whole-body diffusion-weighted magnetic resonance imaging (WB-DWI) showed no findings suggestive of prostate cancer metastasis. The external beam radiotherapy-resistant prostate cancer was identified as a hyperintense area on computed DWI with a b -value of 1500 s/mm² in the ventral prostate (arrowhead).

progression from nonmetastatic CRPC to metastatic CRPC. Several retrospective studies have reported local treatment for nonmetastatic CRPC. Botticella et al. examined the curative role of 78 Gy EBRT on the prostate in a retrospective study including 42 patients with nonmetastatic CRPC and reported a 60% survival rate without distant metastasis and a 65% cancer-specific survival rate at 5 years.⁸ Hosogoe et al. reported a case

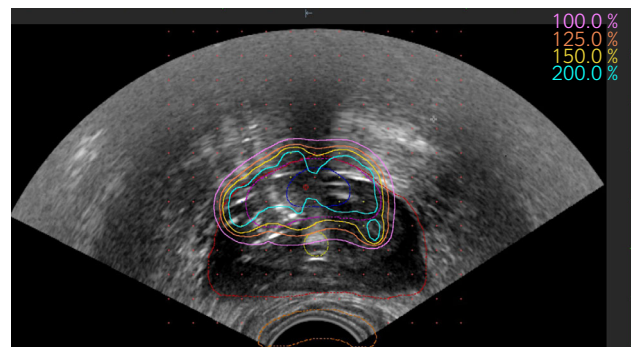


Fig. 2 Post-implant dosimetry of salvage focal brachytherapy on transrectal ultrasound. The 100% isodose corresponds to 110 Gy. The entire prostate is contoured in red.

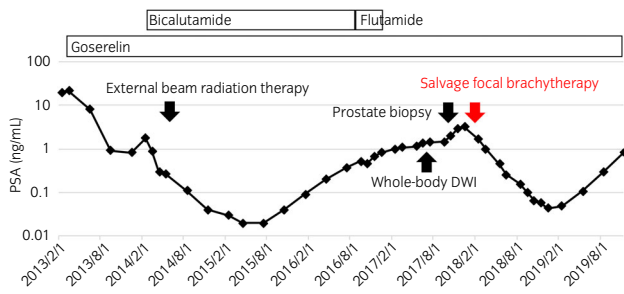


Fig. 3 Treatment course and trends in serum prostate-specific antigen.

in which salvage whole-gland brachytherapy (145 Gy) was performed for EBRT-resistant local recurrence of CRPC, and PSA levels rapidly decreased within 6 months.⁹

Of the salvage treatment options for recurrent cancer after radiotherapy, salvage RP has the highest likelihood of achieving local control.^{10,11} On the other hand, the risk of postoperative complications must be taken into consideration when selecting local salvage therapy. In a meta-analysis of salvage therapy for recurrent prostate cancer after radiotherapy, severe GU toxicity exceeded 21% for HIFU and RP but ranged from 4.2% to 8.1% for re-irradiation.³ The rate of severe GU toxicity was significantly lower for re-irradiation with high-dose rate brachytherapy, LDR brachytherapy, or SBRT than RP. Severe GI toxicity was less than 2% for all treatments.³ Although the evidence for re-irradiation in nonmetastatic CRPC recurrent after EBRT is limited, in this case, focal LDR brachytherapy did not result in either GU or GI side effect. Focal therapy of the prostate in patients with low- and some intermediate-risk cancer characteristics is intended to limit damage to adjacent structures leading to functional preservation without compensating for cancer control as a primary treatment.¹² Even when salvage therapy is needed after EBRT, focal therapy may eliminate recurrent cancer and minimize treatment-related toxicity in patients who are carefully assessed using biopsy and imaging.^{13,14} In this case, with nonmetastatic CRPC recurrent after radiotherapy, focal LDR brachytherapy showed a good therapeutic effect in terms of PSA reduction, and no adverse effects were observed. Long-term follow-up studies in many patients are needed in future.

In conclusion, focal brachytherapy may be a feasible option to reduce GU and GI side effects because of salvage therapy for recurrent cancer after radiotherapy with limited spread within the prostate.

Editorial Comment

Editorial Comment to Nonmetastatic castration-resistant prostate cancer treated with salvage focal brachytherapy after external beam radiotherapy

This is an open access article under the terms of the Creative Commons Attribution License, which permits use, distribution and reproduction in any medium, provided the original work is properly cited.

Conflict of interest

The authors declare no conflict of interest.

References

- Smith MR. Progress in nonmetastatic prostate cancer. *N. Engl. J. Med.* 2018; **378**: 2531–2.
- Beauval J-B, Loriot Y, Hennequin C *et al.* Loco-regional treatment for castration-resistant prostate cancer: Is there any rationale? A critical review from the AFU-GETUG. *Crit. Rev. Oncol. Hematol.* 2018; **122**: 144–9.
- Valle LF, Lehrer EJ, Markovic D *et al.* A systematic review and meta-analysis of local salvage therapies after radiotherapy for prostate cancer (MASTER). *Eur. Urol.* 2020; in press. <https://doi.org/10.1016/j.euro.2020.11.010>
- Murgic J, Morton G, Loblaw A *et al.* Focal salvage high dose-rate brachytherapy for locally recurrent prostate cancer after primary radiation therapy failure: results from a prospective clinical trial. *Int. J. Radiat. Oncol. Biol. Phys.* 2018; **102**: 561–7.
- Deek MP, Taparra K, Phillips R *et al.* Metastasis-directed therapy prolongs efficacy of systemic therapy and improves clinical outcomes in oligoprogressive castration-resistant prostate cancer. *Eur. Urol. Oncol.* 2020; in press. <https://doi.org/10.1016/j.euo.2020.05.004>
- Gillessen S, Attard G, Beer TM *et al.* Management of patients with advanced prostate cancer: report of the advanced prostate cancer consensus conference 2019. *Eur. Urol.* 2020; **77**: 508–47.
- Yoshida S, Takahara T, Arita Y *et al.* Progressive site-directed therapy for castration-resistant prostate cancer: localization of the progressive site as a prognostic factor. *Int. J. Radiat. Oncol. Biol. Phys.* 2019; **105**: 376–81.
- Botticella A, Guarneri A, Filippi AR *et al.* May non-metastatic clinically localized castration-resistant prostate cancer after primary androgen ablation benefit from salvage prostate radiotherapy? *J. Cancer Res. Clin. Oncol.* 2013; **139**: 1955–60.
- Hosogoe S, Soma O, Matsumoto T *et al.* Salvage brachytherapy for castration-resistant and external beam radiotherapy-resistant local recurrence 17 years after radical prostatectomy. *Case Rep. Urol.* 2015; **2015**: 839738.
- Pisters LL, Leibovici D, Blute M *et al.* Locally recurrent prostate cancer after initial radiation therapy: a comparison of salvage radical prostatectomy versus cryotherapy. *J. Urol.* 2009; **182**: 517–27.
- Chade DC, Eastham J, Graefen M *et al.* Cancer control and functional outcomes of salvage radical prostatectomy for radiation-recurrent prostate cancer: a systematic review of the literature. *Eur. Urol.* 2012; **61**: 961–71.
- Eggner S, Salomon G, Scardino PT, De la Rosette J, Polascik TJ, Brewster S. Focal therapy for prostate cancer: possibilities and limitations. *Eur. Urol.* 2010; **58**: 57–64.
- Matsuoka Y, Numao N, Saito K *et al.* Candidate selection for quadrant-based focal ablation through a combination of diffusion-weighted magnetic resonance imaging and prostate biopsy. *BJU Int.* 2016; **117**: 94–101.
- Matsuoka Y, Numao N, Saito K *et al.* Combination of diffusion-weighted magnetic resonance imaging and extended prostate biopsy predicts lobes without significant cancer: application in patient selection for hemiablativ focal therapy. *Eur. Urol.* 2014; **65**: 186–92.