

Comparison Study of Anterior Capsule Contraction of Hydrophilic and Hydrophobic Intraocular Lenses Under the Same Size Capsulotomy

Yuyan Wang¹, Wei Wang¹, Yanan Zhu¹, Jia Xu¹, Chenqi Luo¹, and Ke Yao¹

¹ Eye Center of the Second Affiliated Hospital, School of Medicine, Zhejiang University, Hangzhou, Zhejiang Province, China

Correspondence: Ke Yao, Eye Center of the Second Affiliated Hospital, School of Medicine, Zhejiang University, Eye Institute of Zhejiang University, 310009, Hangzhou, Zhejiang Province, China. e-mail: xlren@zju.edu.cn

Received: June 6, 2021

Accepted: December 14, 2021

Published: January 18, 2022

Keywords: anterior capsule contraction; femtosecond laser-assisted cataract surgery; intraocular lenses

Citation: Wang Y, Wang W, Zhu Y, Xu J, Luo C, Yao K. Comparison study of anterior capsule contraction of hydrophilic and hydrophobic intraocular lenses under the same size capsulotomy. *Transl Vis Sci Technol.* 2022;11(1):24. <https://doi.org/10.1167/tvst.11.1.24>

Purpose: To compare anterior capsule contraction of two kinds of hydrophilic and hydrophobic acrylic intraocular lenses (IOLs) under the same size capsulotomy with femtosecond laser-assisted cataract surgery (FLACS).

Methods: A total of 320 eyes in 320 patients who underwent FLACS were included. The patients were scheduled to have hydrophilic acrylic IOLs (MI60, 509M) and hydrophobic acrylic IOLs (iSert250, ZCB00) implanted. Visual acuity and anterior segment photography using a slit lamp microscope were performed at postoperative one week, one month, three months, and one year.

Results: The contraction of the anterior capsule opening area (mm²) and circumference (mm) in the hydrophilic group were larger than that of the hydrophobic group from postoperative one week to one year ($P < 0.001$, $P < 0.001$, respectively). The postoperative contraction of the capsule opening area in MI60 was larger than in 509M ($P < 0.001$) and larger in 509M than in iSert250 and ZCB00 ($P = 0.008$, $P = 0.019$, respectively), but no difference was observed between iSert250 and ZCB00 ($P = 0.867$). During postoperative one to three months, all groups had the maximum capsule contraction ($P < 0.001$).

Conclusions: Under the same size capsulotomy with FLACS, the postoperative anterior capsule contraction induced by hydrophobic IOLs was less than that induced by hydrophilic IOLs. Among the four IOLs, the capsule contraction was largest in MI60, followed by 509M, and least in iSert250 and ZCB00, which was time-dependent.

Translational Relevance: Our findings implied that patients with a high risk of ACC should choose hydrophobic IOLs, as well as nonsteroidal anti-inflammatory drugs may be used for a longer period in patients with high risk of capsule contraction syndrome.

Introduction

Cataract surgery is one of the most successful operations in the world.^{1,2} Femtosecond laser-assisted cataract surgery (FLACS) can achieve more precise capsulotomy sizing and centering than manual continuous curvilinear capsulorrhexis (CCC),³ resulting in better postoperative refractive and visual outcomes.⁴ Progressive contraction of the anterior capsule opening remains a significant mid-to-late complication of cataract surgery.^{5,6} Anterior capsule contraction (ACC) is closely related to the material of the intraocular lens (IOL).⁷

Previous studies have compared the anterior capsule opening area after phacoemulsification surgery with implantation of polymethyl methacrylate (PMMA), silicone, and acrylic IOLs. The percentage of the anterior capsule opening area contraction of silicone IOLs is significantly greater than that of acrylic IOL. However, there is no significant difference between different acrylic IOLs. IOL optical materials have the greatest influence on ACC.⁷ The contact between the acrylate and the capsule bag is tighter than in PMMA and silicone, which might lead to more support and adhesion. The reduction of proliferation and fibrosis of lens epithelial cells (LECs) could reduce the contraction of the anterior capsule opening.⁸ In addition, in

a retrospective study that compared the incidence of capsule contraction syndrome (CCS) 6 months after phacoemulsification cataract surgery with a hydrophobic acrylic IOL (Acrysof-SN60AT) and 2 hydrophilic acrylic IOLs (Quatrix and ACR6D), the incidence of CCS in the hydrophobic IOL was significantly lower than that in the hydrophilic IOLs. No significant statistical difference was observed between the two hydrophilic IOLs.⁹

Traditional phacoemulsification cataract surgery was the primary method used in the previous studies. When the capsulorrhexis was too small or too large, it would increase postoperative ACC.¹⁰ On the one hand, some researchers tried to fix the size of the capsulorrhexis, which might actually lead to large deviations with CCC.¹¹ On the other hand, some studies did not fix the size of the capsulorrhexis.¹² Their results could be better convinced if they can make the capsulorrhexis fixed. Therefore this study aimed to compare the impact of the implantation of four different IOLs—two hydrophobic IOLs and two hydrophilic IOLs—on ACC under the same size capsulotomy with FLACS, which has not been reported to date to our knowledge. To be more accurate, AutoCAD software was used to precisely calculate the area and circumference of the anterior capsule opening.

Methods

Patients

This prospective consecutive nonrandomized comparative cohort study was conducted from August 2016 to December 2017 at the Eye Center, Second Affiliated Hospital of the School of Medicine, Zhejiang University, Hangzhou, China. This study enrolled 345 patients (one eye per patient) who required FLACS, and included 320 patients (one eye per patient) in the final data. The study was approved by the Human Research Ethics Committee of the Second Affiliated Hospital of Zhejiang University. It was registered with the Chinese Clinical Trial Registry (ChiCTR-ONN-17010319). All methods were carried out in accordance with the relevant guidelines and regulations of the Second Affiliated Hospital of Zhejiang University. The study adhered to the Declaration of Helsinki, and written informed consent was obtained from each patient. Patients who (1) had FLACS performed by the same experienced surgeon (Yao Ke); (2) were undergoing their first cataract surgery; (3) had an axial length within the normal range (22.5–26 mm); (4) had a normal pupil size, a clear anterior segment photo, and the diameter of the dilated pupil

was larger than 5 mm; and (5) had normal cornea and fundus were included in the study. Patients with narrow eyelid fissures, corneal scars, keratoconus and pterygium, glaucoma or ocular hypertension, macular degeneration, retinal disease, optic neuritis, high myopia, diabetes, pseudoexfoliation syndrome, myotonic dystrophy, uveitis, diabetic retinopathy, or retinitis pigmentosa were excluded from the study.^{13–17}

Surgery and Intraocular Lenses

All patients in this study underwent FLACS (LenSx; Alcon Laboratories, Elkridge, MD, USA) with IOL implantation. The operation followed the standard procedure of our hospital and was performed by the same experienced surgeon (Yao Ke). Uncorrected and corrected distance visual acuity (CDVA), anterior segment photography using a slit lamp microscope, and optical coherence tomography were evaluated and performed at postoperative 1 week, 1 month, 3 months, and 1 year. Each preoperative and postoperative examination was performed by an experienced fixed technician, who did not know the type of IOL the patient had before the examination.

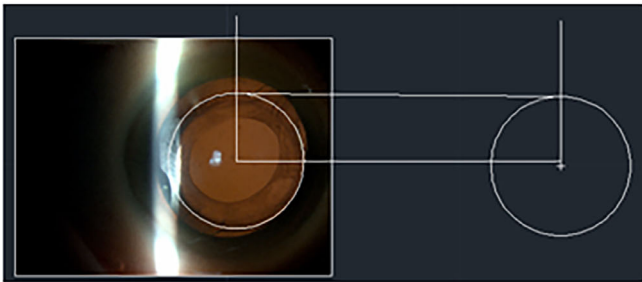
The implanted IOLs were as follows: Akreos MI60 (Bausch & Lomb, Rochester, NY, USA), which is hydrophilic; CT ASPHINA 509M (Zeiss, Oberkochen, Germany), which is hydrophilic with a hydrophobic surface modification; and iSert250 (HOYA Surgical Optics, Singapore) and TECNIS ZCB00 (Precision Lens, Bloomington, MN, USA), which are both hydrophobic. All four IOLs are foldable, biconvex aspheric, single-piece lenses (Table 1).

Evaluation of Anterior Capsule Area and Circumference


AutoCAD2014 software was used to calculate the area and circumference of ACC at postoperative one week, one month, three months, and one year. All pictures were evaluated by the same person and repeated twice to determine the average. The specific evaluation steps were (1) draw the IOL circle on the anterior segment photo, (2) draw a standard circle with a radius of 3 mm, (3) adjust the IOL circle on the anterior segment photo to the standardized circle with a 3 mm radius (Fig. 1A), (4) draw the anterior capsule opening in multiple arcs, and (5) calculate the area and circumference of ACC (Fig. 1B).

Table 1. Characteristics of Four Different IOLs

	Akreos MICS MI60L	CT ASPHINA 509MP	HOYA Model 250	TECNIS ZCB00
Material-Optic and haptic	Hydrophilic acrylic with UV absorber	Hydrophilic acrylate(25%) with hydrophobic surface and UV absorber	Hydrophobic acrylic with UV absorber and PMMA(haptic)	Hydrophobic acrylic with UV absorber
Optic configuration	Biconvex aspheric	Biconvex aspheric	Biconvex aspheric	Biconvex aspheric
Water content	26%	25%	26%	26%
Incision size	2.0 mm	2.0 mm	2.0 mm	2.0 mm
Optic diameter	6.0 mm	6.0 mm	6.0 mm	6.0 mm
Overall diameter	11.0 mm (+0 to +15 D) 10.7 mm (+15.5 to +22 D) 10.5 mm (+22.5 to +30 D)	11.0 mm	12.5 mm	13.0 mm
Haptic configuration	4 plate loop	2 plate loop	2 Modified-C loop	2 Modified-C loop, PROTEC 360°Square posterior edge



A



B

Figure 1. Evaluation of anterior capsular area and circumference using AutoCAD.

Statistical Analysis

All analyses were performed using SPSS 22.0 software. All continuous data were presented as mean ± standard deviation. The Shapiro-Wilk test was used to verify the normality of the quantitative variables as appropriate. The χ^2 test was used to compare categorical data. An unpaired *t* test and the Mann-Whitney U test were used to compare outcomes between the two groups. The Mauchly sphericity test, analysis of variance (ANOVA), and the Friedman test were used to compare outcomes at different timepoints within the same group. One-way ANOVA and the Kruskal-Wallis test were used to compare the four groups. If there were significant statistical differences between the groups, a least significant difference (LSD) post-hoc test was used for pairwise comparison. A *P* value <0.05 was considered statistically significant.

Results

A total of 320 patients (one eye per patient) were included. No adverse events occurred during the surgeries and no postoperative complications were observed. Seventy-five, 89, 85, and 71 eyes were included in the MI60, 509M, iSert250, and ZCB00 IOL groups, respectively. There was no statistically significant difference in the rate lost to follow-up. There was no statistically significant difference in age,

Table 2. Characteristics of Eyes With FLACS Using Four Different IOLs

Characteristics	MI60	509M	iSert	ZCB00	P Value
Eyes (n)	75	89	85	71	—
Mean age (y)	59.29 ± 8.26	62.00 ± 10.92	62.36 ± 9.29	61.96 ± 12.15	0.220*
Male/Female	36/39	42/47	40/45	34/37	0.999†
Male/Female (%)	48.0/52.0	47.2/52.8	47.0/53.0	47.9/52.1	—
OD/OS	38/37	47/42	43/42	37/34	0.989†
OD/OS (%)	50.7/49.3	52.8/47.2	50.6/49.4	52.1/47.9	—
Axial length(mm)	23.53 ± 0.42	23.69 ± 0.64	23.68 ± 0.59	23.67 ± 0.54	0.234*
Diopter(D)	19.65 ± 1.10	19.49 ± 1.09	20.02 ± 1.72	19.62 ± 1.29	0.061*

Data are presented as mean ± standard deviation or n (%).

*One-way ANOVA

† χ^2 test.

Table 3. The Area (mm²) and Circumference (mm) of Anterior Capsule Opening in Hydrophobic and Hydrophilic Group

	Hydrophobic (n = 156)	Hydrophilic (n = 164)	t Value	P Value*
1 week				
Area	20.82 ± 0.79	20.84 ± 0.71	-0.287	0.774
Circumference	16.18 ± 0.39	16.16 ± 0.36	0.575	0.565
1 month				
Area	20.21 ± 0.94	19.58 ± 1.69	4.179	<0.001
Circumference	15.89 ± 0.42	15.62 ± 0.73	3.996	<0.001
3 months				
Area	19.38 ± 1.16	18.22 ± 2.26	5.821	<0.001
Circumference	15.55 ± 0.50	15.07 ± 1.04	5.221	<0.001
1 year				
Area	18.96 ± 1.20	17.64 ± 2.26	6.570	<0.001
Circumference	15.35 ± 0.53	14.76 ± 1.09	6.120	<0.001

Data are presented as mean ± standard deviation.

*Unpaired T test.

male-to-female ratio, left-to-right eye ratio, axis length, or IOL diopter between the groups ($P > 0.05$; Table 2).

There was no statistically significant difference in the anterior capsule opening area and circumference between the hydrophobic and hydrophilic group at postoperative one week ($P = 0.774$, $P = 0.565$, respectively; Table 3). The anterior capsule opening area and circumference of the hydrophobic group were greater than that of the hydrophilic group at postoperative one month, three months, and one year (for all time points $P < 0.001$, $P < 0.001$, respectively; Table 3).

Compared with postoperative one week, the contraction of the anterior capsule opening area in the hydrophilic group was more than that in the hydrophobic group at postoperative one month, three months, and one year, respectively (Fig. 2A).

Compared with postoperative one week, the contraction of the anterior capsule opening circumference in the hydrophilic group was also more than that in the hydrophobic group at postoperative one month, three months, and one year, respectively (Fig. 2B).

There were no statistically significant differences in the anterior capsule opening area and circumference among the MI60, 509M, iSert250, and ZCB00 groups at postoperative 1 week ($P = 0.981$, $P = 0.492$), but there were statistically significant differences at postoperative one month, three months, and one year ($P < 0.001$; Table 4).

Compared with postoperative one week, the contraction of the anterior capsule opening area in MI60 was larger than in 509M at postoperative one month, three months, and one year ($P < 0.05$) and

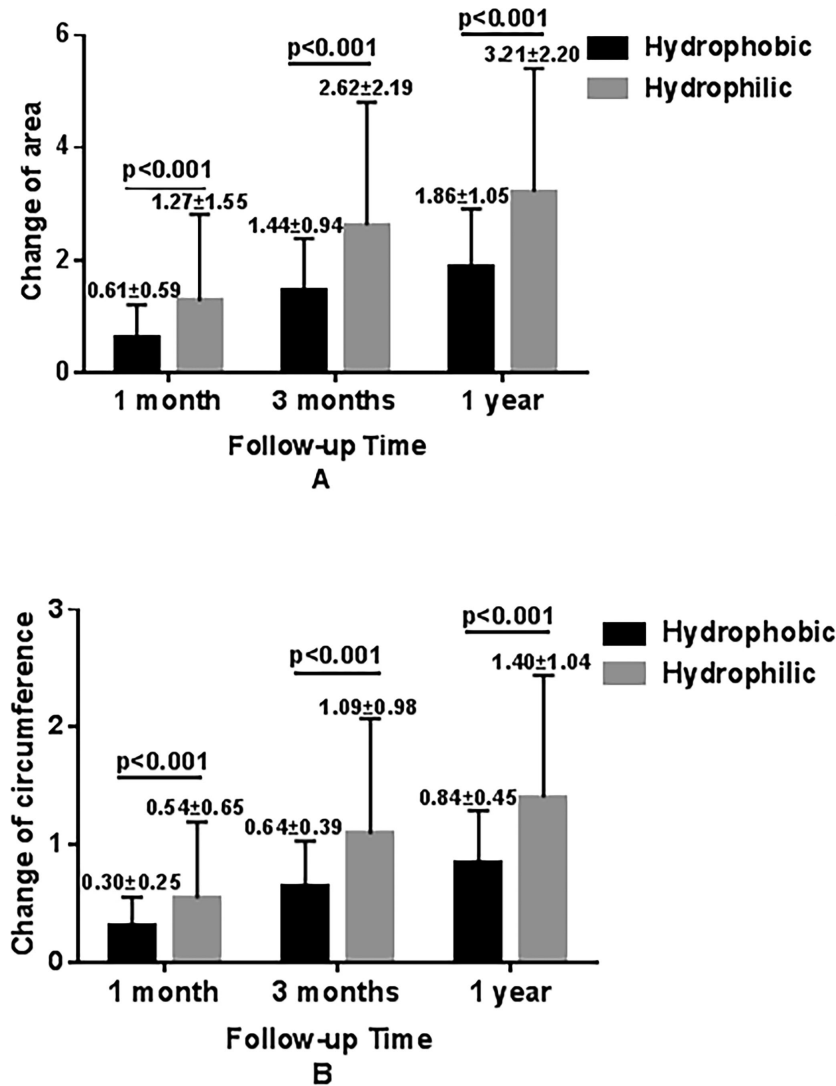


Figure 2. Changes in the area (A) and circumference (B) of the anterior capsule opening in hydrophobic (n = 156) and hydrophilic (n = 164) group.

larger in 509M than in iSert250 and ZCB00 at the same checkpoints ($P < 0.05$), but between iSert250 and ZCB00, no statistical differences were observed ($P > 0.05$; Fig. 3A). As same as the area of the anterior capsule opening, the contraction of the circumference was most obvious in MI60, followed by 509M, and the smallest changes were observed in iSert250 and ZCB00 at postoperative one month ($P < .05$); however, no differences were observed in iSert250 and ZCB00 at postoperative one month, three months, and one year ($P > 0.05$; Fig. 3B). The changes of circumference between 509M and the two hydrophobic lenses, iSert250 and ZCB00, were not statistically different at postoperative three months ($P = 0.118$, $P = 0.096$, respectively), and between 509M and iSert250, there was no difference at postoperative one year ($P = 0.113$),

although there was a trend of shorter circumference in 509M (Fig. 3B).

The contraction of the anterior capsule opening area (Fig. 4A) and circumference (Fig. 4B) in the hydrophilic group were more than that in the hydrophobic group from postoperative one week to one month ($P < 0.001$), from one month to three months ($P < 0.001$), and from three months to one year ($P < .001$; Fig. 4A).

As Tables 5 and 6 and Figure 4 show, with the increase of postoperative time, the anterior capsule opening area and circumference of both the hydrophobic hydrophilic groups became gradually reduced. In the hydrophobic group, the anterior capsule opening area decreased the most from postoperative one month to three months, and decreased the least from

Table 4. The area (mm²) and Circumference (mm) of Anterior Capsule Opening in Four Groups

	MI60 (n = 75)	509M (n = 89)	iSert250 (n = 85)	ZCB00 (n = 71)	P Value*
1 week					
Area	20.85 ± 0.74	20.84 ± 0.69	20.84 ± 0.64	20.80 ± 0.94	0.981
Circumference	16.13 ± 0.33	16.19 ± 0.37	16.21 ± 0.37	16.15 ± 0.40	0.492
1 month					
Area	19.34 ± 1.84	19.77 ± 1.54	20.23 ± 0.83	20.19 ± 1.07	<0.001
Circumference	15.50 ± 0.79	15.72 ± 0.66	15.91 ± 0.38	15.86 ± 0.46	<0.001
3 months					
Area	17.50 ± 2.65	18.83 ± 1.66	19.43 ± 1.09	19.32 ± 1.23	<0.001
Circumference	14.71 ± 1.24	15.37 ± 0.71	15.57 ± 0.49	15.53 ± 0.51	<0.001
1 year					
Area	16.81 ± 2.56	18.33 ± 1.69	18.99 ± 1.15	18.91 ± 1.27	<0.001
Circumference	14.30 ± 1.27	15.14 ± 0.72	15.34 ± 0.54	15.35 ± 0.52	<0.001

Data are presented as mean ± standard deviation.

†One-way ANOVA.

Table 5. The Change of Area (mm²) of Anterior Capsule Opening in Hydrophobic and Hydrophilic Group

	1 Week	1 Month		3 Months		1 Year	
	Area	Area	Change From 1 Week	Area	Change From 1 Month	Area	Change From 3 Months
Hydrophobic	20.82 ± 0.79	20.21 ± 0.94	0.61 ± 0.59	19.38 ± 1.16	0.83 ± 0.73	18.96 ± 1.20	0.43 ± 0.37
Hydrophilic	20.84 ± 0.71	19.58 ± 1.69	1.27 ± 1.55	18.22 ± 2.26	1.36 ± 1.49	17.64 ± 2.26	0.59 ± 0.51
P value*	0.774	<0.001	<0.001	<0.001	<0.001	<0.001	0.001

Data are presented as mean ± standard deviation.

*Mann-Whitney U test.

Table 6. The Change of Circumference (mm) of Anterior Capsule Opening in Hydrophobic and Hydrophilic Group

	1 Week	1 Month		3 Months		1 Years	
	Circumference	Circumference	Change From 1 Week	Circumference	Change From 1 Month	Circumference	Change From 3 Months
Hydrophobic	16.18 ± 0.39	15.89 ± 0.42	0.30 ± 0.25	15.55 ± 0.50	0.34 ± 0.29	15.35 ± 0.53	0.20 ± 0.20
Hydrophilic	16.16 ± 0.36	15.62 ± 0.73	0.54 ± 0.65	15.07 ± 1.04	0.55 ± 0.70	14.76 ± 1.09	0.31 ± 0.27
P value†	0.565	<0.001	<0.001	<0.001	<0.001	<0.001	<0.001

Data are presented as mean ± standard deviation.

†Mann-Whitney U test.

postoperative three months to one year. Therefore the contraction of the area gradually slowed down after postoperative three months.

The rates of Nd:YAG laser treatment for CCS in the MI60, 509M, iSert250, and ZCB00 groups at postoperative one year were two cases (2.7%), one case (1.1%), zero cases (0%), and zero cases (0%), respectively, which had no statistically significant difference ($P = 0.270$). CDVA (LogMAR) of the MI60, 509M, iSert250, and ZCB00 groups at postoperative one year were 0.11 ± 0.11 , 0.12 ± 0.13 , 0.13 ± 0.19 , and 0.09 ± 0.78 , respectively. There was no statistically significant differ-

ence in CDVA (LogMAR) between the four groups ($P = 0.488$).

Discussion

Progressive contraction of the anterior capsule opening is the most common complication of cataract surgery, which may lead to CCS. Residual LECs at the edge of the anterior capsule opening come into contact with IOLs postoperatively, which leads to the proliferation, migration, and differentiation of the LECs.

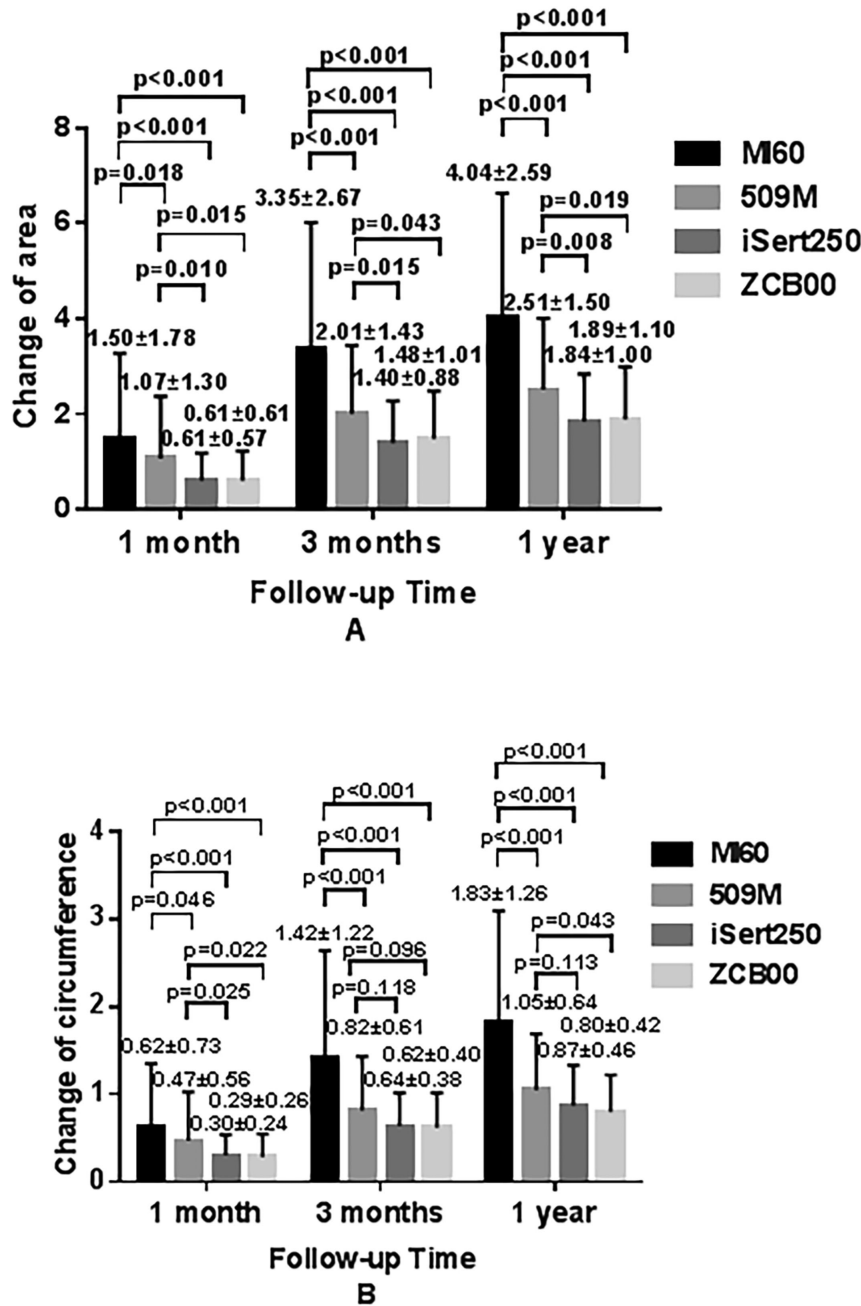


Figure 3. Changes in the area (A) and circumference (B) of the anterior capsule opening in M60 (n = 75), 509M (n = 89), iSert250 (n = 85), and ZCB00 (n = 71) group.

This results in fibrosis of the anterior capsule, contraction of the anterior capsule opening area, decentration, tilt and curling of the IOL optic, reduction in the free optic zone, and dislocation of IOL with a capsule bag. Besides, this causes glare, visual impairment, reduced contrast sensitivity, and refractive changes.¹⁸ Factors that affect capsule contraction included the size of the capsulorrhexis, the material of the IOL, postoperative inflammation, and systemic or ocular diseases.¹³ The incidence of ACC is higher

in patients with high myopia, diabetic retinopathy, pseudo-exfoliation syndrome, uveitis, advanced age, retinitis pigmentosa, lens ligament laxity after eye trauma, history of eye surgery, ciliary bodies, myotonic dystrophy, allergic dermatitis, and Marfan syndrome.¹⁹ The contraction of the anterior capsule opening is related to the IOL haptic design. Tsinoopoulos²⁰ showed that the IOL haptic design affects the force balance of the anterior capsule opening. IOLs with long, hard and circular loops fit the capsular membrane more

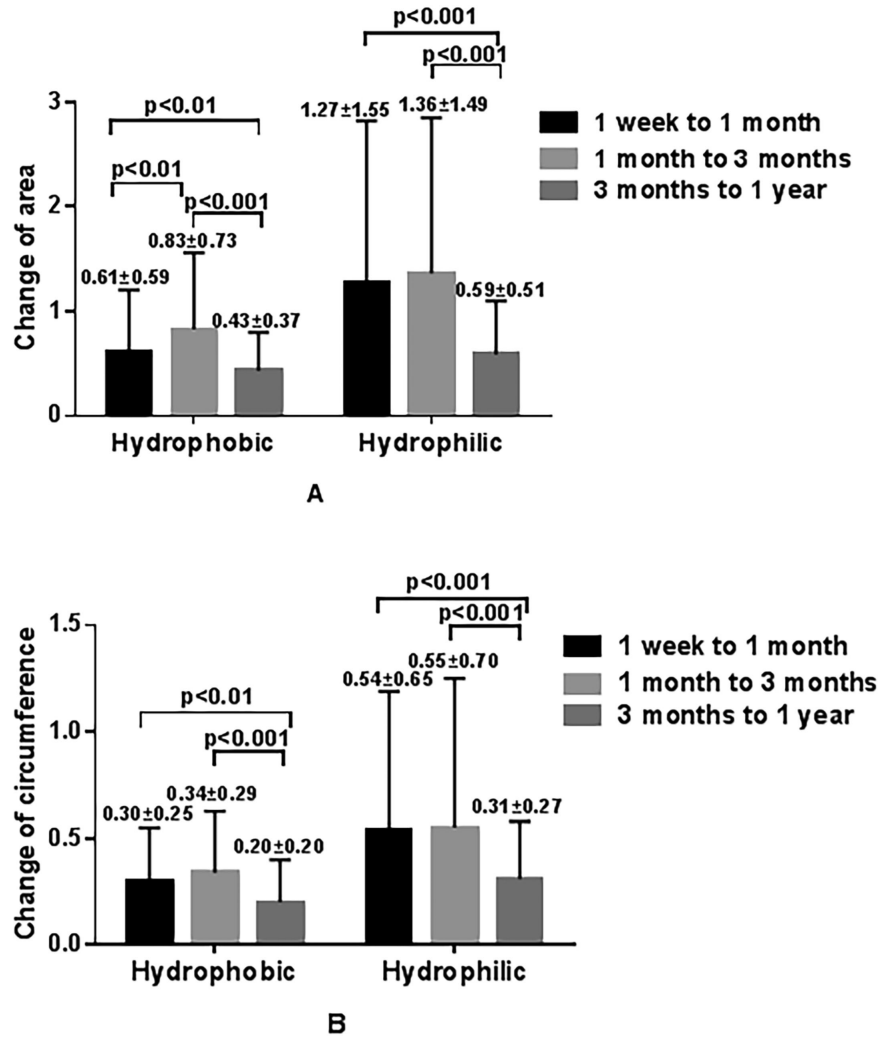


Figure 4. The speed of change in the area (A) and circumference (B) of the anterior capsule opening in hydrophobic (n = 156) and hydrophilic (n = 164) group.

closely, which reduced the contraction of the anterior capsule opening. However, Sacu²¹ showed that the IOL haptic design of the hydrophobic acrylate IOLs will not affect the contraction of the anterior capsule opening. In 2005, Hayashi⁷ compared the acrylic IOL with a rounded optical part and the acrylic IOL with a sharp edge in the optical part, which had no significant difference between the contraction of the anterior capsule opening. The design of the optical part and loop of one-piece acrylate IOLs were not related to the contraction of the anterior capsule opening.²²

Most previous studies believed that IOL optical material is the most important factor in ACC.^{7,21,23} When the capsulorrhexis was too small or too large, it would increase the risk of postoperative ACC.¹⁰ Traditional phacoemulsification cataract surgery was the primary method used in the previous studies. Some

previous studies did not fix the size of the capsulorrhexis,¹² although some researchers tried to fix the size of the capsulorrhexis, which might actually lead to large deviations with CCC.¹¹ Their results could be better convinced if they can make the capsulorrhexis fixed. FLACS could achieve more precise capsulotomy sizing and centering than CCC.³ A standard 5.0 mm capsulorrhexis with more accurate shape and more precise location could be obtained by FLACS rather than manual CCC.^{3,24,25} Thus this study compared the impact of the implantation of four IOLs—two hydrophobic and two hydrophilic—on ACC under the same size capsulotomy with FLACS. To be more accurate, AutoCAD software was used to precisely calculate the area and circumference of the anterior capsule opening.

This study demonstrates that ACC in the hydrophilic group was larger than that in the

hydrophobic group at postoperative 1 month, 3 months, and 1 year. Hydrophobic IOLs have better biocompatibility with the capsule bag than do hydrophilic IOLs. However, it has been reported that hydrophilic IOLs have better biocompatibility with the anterior chamber than do hydrophobic IOLs, which have better flexibility and foldability, less inflammatory cell adhesion on the front surface, and less inflammatory response and pupil adhesion.^{26,27} In hydrophobic IOLs, the postoperative early adhesion between the IOL and capsule bag inhibits the proliferation and migration of the LECs, which in turn prevents the formation of posterior capsule opacification. In addition, the stronger adhesion between the capsule bag and the IOL prevents the anterior capsule from contracting. This study verifies that ACC of hydrophobic IOLs was less than that of hydrophilic IOLs, and hydrophobic acrylic IOLs had better capsule biocompatibility under the same size capsulotomy.

The present study also shows that the contraction of the anterior capsule opening area in MI60 was larger than in 509M, and larger in 509M than in iSert250 and ZCB00, although there were no statistically significant differences observed between iSert250 and ZCB00. The hydrophilic IOL 509M was modified with a hydrophobic surface, which to a certain extent can perhaps reduce ACC.^{28,29}

This study dynamically evaluates the effect of different IOLs on ACC. We treat postoperative one week as the baseline, postoperative one month as the recent assessment, postoperative three months as the mid-term assessment, and postoperative one year as the long-term assessment. Segmented assessment can better compare the degree and speed of ACC. And it was determined that ACC was time-dependent. Tsinoopoulos et al.⁹ showed that in postoperative three months, the contraction speed was faster, but no longer time follow-up. This study shows that from postoperative one month to three months, all groups had the maximum contraction of the anterior capsule area and circumference, while from postoperative three months to one year, all groups had the minimum changes.

The present study has several limitations. The focus of this study is on ACC of IOLs of different materials, but the effect of IOL shape and length on contraction was less considered. Although the four IOLs were provided to the surgeon by an assistant with an equal number method, they were not assigned by the random computer-generated table method, which could perhaps lead to a certain deviation. The number of IOLs is not enough, so we have not verified what IOL has a higher incidence of CCS by Nd:YAG laser treatment, although there was a trend showing that

hydrophilic IOLs have a higher rate than hydrophobic IOLs.

In conclusion, under the same size capsulotomy with FLACS, the postoperative ACC induced by hydrophobic IOLs was less than that of hydrophilic IOLs, which implied that patients with a high risk of ACC, such as those who have high myopia, pseudoexfoliation syndrome, or retinitis pigmentosa, should choose hydrophobic IOLs. The contraction in MI60 was larger than in 509M, and larger in 509M than in iSert250 and ZCB00, although there were no differences between two hydrophobic iSert250 and ZCB00. ACC was time-dependent. During postoperative one to three months, all groups had the largest anterior capsule contraction, which suggests that nonsteroidal anti-inflammatory drugs may be used for a longer period in patients with high risk of CCS.

Acknowledgments

Supported by Programs of National Natural Science Foundation of China (81600716, 81870641, 81970779) and Development Project of Zhejiang Province (2020C03035).

Disclosure: **Y. Wang**, None; **W. Wang**, None; **Y. Zhu**, None; **J. Xu**, None; **C. Luo**, None; **K. Yao**, None

References

1. Davis G. The evolution of cataract surgery. *Misouri Med.* 2016;113:58–62.
2. Liu Y, Wilkins M, Kim T, Malyugin B, Mehta JS. Cataracts. *Lancet.* 2017;390:600–612.
3. Kránitz K, Takacs A, Miháltz K, Kovács I, Knorz MC, Nagy ZZ. Femtosecond laser capsulotomy and manual continuous curvilinear capsulorrhexis parameters and their effects on intraocular lens centration. *J Refract Surg.* 2011;27:558–563.
4. Chen X, Chen K, He J, Yao K. Comparing the curative effects between femtosecond laser-assisted cataract surgery and conventional phacoemulsification surgery: a meta-analysis. *Plos One.* 2016;11:e152088.
5. Zhang X, Yu Y, Zhang G, et al. Performance of femtosecond laser-assisted cataract surgery in Chinese patients with cataract: a prospective, multicenter, registry study. *BMC Ophthalmol.* 2019;19:77.
6. Davison JA. Capsule contraction syndrome. *J Cataract Refract Surg.* 1993;19:582–589.

7. Hayashi K, Hayashi H. Intraocular lens factors that may affect anterior capsule contraction. *Ophthalmology*. 2005;112:286–292.
8. Nagata M, Matsushima H, Mukai K, Terauchi W, Gotoh N, Matsui E. Comparison of anterior capsule contraction between 5 foldable intraocular lens models. *J Cataract Refract Surg*. 2008;34:1495–1498.
9. Tsinopoulos IT, Tsaousis KT, Kymionis GD, et al. Comparison of anterior capsule contraction between hydrophobic and hydrophilic intraocular lens models. *Graefes Arch Clin Exp Ophthalmol*. 2010;248:1155–1158.
10. Michael K, O'Colmain U, Vallance JH, Cormack TGM. Capsule contraction syndrome with haptic deformation and flexion. *J Cataract Refr Surg*. 2010;36:686–689.
11. Kugelberg M, Wejde G, Jayaram H, Zetterström C. Two-year follow-up of posterior capsule opacification after implantation of a hydrophilic or hydrophobic acrylic intraocular lens. *Acta Ophthalmol*. 2008;86:533–536.
12. Leydolt C, Schartmüller D, Schwarzenbacher L, Schranz M, Schriefl S, Menapace R. Comparison of posterior capsule opacification development with 2 single-piece intraocular lens types. *J Cataract Refract Surg*. 2017;43:774–780.
13. Chomańska U, Kraśnicki P, Proniewska-Skrettek E, Mariak Z. Anterior capsule contraction syndrome after cataract phacoemulsification surgery. *Klinika Oczna*. 2010;112:243–246.
14. Kato S, Oshika T, Numaga J, et al. Anterior capsular contraction after cataract surgery in eyes of diabetic patients. *Br J Ophthalmol*. 2001;85:21–23.
15. Hayashi H, Hayashi K, Nakao F, Hayashi F. Anterior capsule contraction and intraocular lens dislocation in eyes with pseudoexfoliation syndrome. *Br J Ophthalmol*. 1998;82:1429–1432.
16. Hansen SO, Crandall AS, Olson RJ. Progressive constriction of the anterior capsular opening following intact capsulorhexis. *J Cataract Refract Surg*. 1993;19:77–82.
17. Hayashi K, Hayashi H, Matsuo K, Nakao F, Hayashi F. Anterior capsule contraction and intraocular lens dislocation after implant surgery in eyes with retinitis pigmentosa. *Ophthalmology*. 1998;105:1239–1243.
18. Masket S. Postoperative complications of capsulorhexis. *J Cataract Refr Surg*. 1993;19:721–724.
19. Gallagher SP, Pavilack MA. Risk factors for anterior capsule contraction syndrome with polypropylene or poly(methyl methacrylate) haptics. *J Cataract Refract Surg*. 1999;25:1356–1361.
20. Tsinopoulos IT, Tsaousis KT, Symeonidis C, Dimitrakos SA. Bilateral manifestation of severe anterior capsule contraction syndrome after implantation of a preloaded intraocular lens. *Clin Exp Optom*. 2009;92:503–504.
21. Sacu S, Menapace R, Findl O. Effect of optic material and haptic design on anterior capsule opacification and capsulorhexis contraction. *Am J Ophthalmol*. 2006;141:488–493.
22. Hayashi K, Hayashi H. Comparison of the stability of 1-piece and 3-piece acrylic intraocular lenses in the lens capsule. *J Cataract Refr Surg*. 2005;31:337–342.
23. Abela-Formanek C, Amon M, Schauersberger J, Kruger A, Nepp J, Schild G. Results of hydrophilic acrylic, hydrophobic acrylic, and silicone intraocular lenses in uveitic eyes with cataract: comparison to a control group. *J Cataract Refr Surg*. 2002;28:1141–1152.
24. Grewal DS, Schultz T, Basti S, Dick HB. Femtosecond laser-assisted cataract surgery—current status and future directions. *Surv Ophthalmol*. 2016;61:103–131.
25. Nagy ZZ, Kránitz K, Takacs AI, Miháltz K, Kovács I, Knorz MC. Comparison of intraocular lens decentration parameters after femtosecond and manual capsulotomies. *J Refract Surg*. 2011;27:564–569.
26. Özyol P, Özyol E, Karel F. Biocompatibility of Intraocular Lenses. *Turk J Ophthalmol*. 2017;47:221–225.
27. Choi M, Lazo MZ, Kang M, Lee J, Joo CK. Effect of number and position of intraocular lens haptics on anterior capsule contraction: a randomized, prospective trial. *BMC Ophthalmol*. 2018;18:78.
28. Pérez-Vives C. Biomaterial influence on intraocular lens performance: an overview. *J Ophthalmol*. 2018;2018:2687385.
29. Matsushima H, Iwamoto H, Mukai K, Katsuki Y, Nagata M, Senoo T. Preventing secondary cataract and anterior capsule contraction by modification of intraocular lenses. *Expert Rev Med Devices*. 2008;5:197–207.