

Perineal warty plaques: A case of verrucous porokeratosis

Prakriti Shukla, Swastika Suvirya, Parul Verma, Meenakshi Batrani¹, Sucheta Pathania, Kiran Preet Malhotra²

Department of Dermatology, King George's Medical University, ²Department of Pathology, Dr. RML Institute of Medical Sciences, Lucknow, Uttar Pradesh, ¹Pathology, Delhi Dermopath Laboratory, New Delhi, India

Address for correspondence:

Dr. Swastika Suvirya, Department of Dermatology, King George's Medical University, Lucknow - 226 003, Uttar Pradesh, India.
E-mail: swastika.p@gmail.com

Abstract

Nonvenereal genital dermatoses form an important category of disorders, and verrucous porokeratosis is a rare and less recognized entity among the same. We present the case of a young adult male with warty growths over scrotum and buttocks for a year. Characteristic cornoid lamellae with typical differentiating features were seen in the histopathology, establishing the diagnosis. This case emphasizes the rare nonvenereal cause for a condition clinically mimicking condyloma acuminata.

Key words: Perineum, porokeratosis, ptychotropa, verrucous, warty

INTRODUCTION

Porokeratosis is a group of keratinization disorder, characterized clinically by plaques with a keratotic rim that corresponds histologically to the characteristic cornoid lamellae. It has several clinical variants, each with slightly different presentation, histological features, and prognosis. Verrucous porokeratosis, which some authors also refer to as genitogluteal porokeratosis or porokeratosis ptychotropa, is a rare subtype.^[1] It presents as a diagnostic challenge and an important disorder to be considered among nonvenereal genital dermatosis. This case is being reported owing to its rarity and close clinical mimic of condyloma acuminata.

CASE REPORT

A 27-year-old male, otherwise healthy, presented to the dermatology outpatient with the complaint of multiple, gradually expanding, dark-colored warty growths over scrotum and buttocks, for the past 1 year. The lesions were not associated with itch or

pain. He was unmarried and disclosed a history of unprotected heterosexual encounters with multiple partners. A written informed consent was taken from the patient for clinical examination and pictures. On cutaneous examination, multiple hyperpigmented annular plaques ranging from 1 cm to 3 cm, with verrucous surface and prominent ridge-like borders over a background of hyperpigmented and velvety skin, were found over the perineal region, involving the ventral aspect of scrotum, medial aspect of both thighs and buttocks [Figure 1]. There was no previous history of genital ulcer or discharge (purulent or otherwise). His past medical history was noncontributing and systemic examination did not reveal any abnormality.

Laboratory investigations were insignificant, and viral markers were negative. A provisional diagnosis of verrucae, Bowenoid papulosis, tuberculosis

This is an open access journal, and articles are distributed under the terms of the Creative Commons Attribution-NonCommercial-ShareAlike 4.0 License, which allows others to remix, tweak, and build upon the work non-commercially, as long as appropriate credit is given and the new creations are licensed under the identical terms.

For reprints contact: WKHLRPMedknow_reprints@wolterskluwer.com

How to cite this article: Shukla P, Suvirya S, Verma P, Batrani M, Pathania S, Malhotra KP. Perineal warty plaques: A case of verrucous porokeratosis. *Indian J Sex Transm Dis* 2021;42:159-62.

Submitted: 21-Sep-2019

Revised: 28-Sep-2020

Accepted: 19-Jan-2021

Published: 27-Jul-2021

Access this article online

Quick Response Code:



Website:

www.ijstd.org

DOI:

10.4103/ijstd.IJSTD_74_19

verrucosa cutis, and prokeratosis were reached, and punch biopsy from a lesion was sent for histopathology. Histopathological examination revealed irregular psoriasiform hyperplasia with compact orthokeratotic hyperkeratosis, multiple broad cornoid lamellae overlying shallow epidermal invagination with hypogranulosis, and numerous dyskeratotic keratinocytes [Figures 2 and 3]. These features helped in establishing the diagnosis of verrucous porokeratosis. The patient was given topical imiquimod and reported mild resolution after 4 weeks of therapy but was later lost to follow-up.

DISCUSSION

Verrucous porokeratosis poses a diagnostic challenge, not only because it closely resembles the more common entities such as condyloma acuminata and psoriasis but also because of its rarity and lack of knowledge of the condition among treating physicians. We could find only <40 cases of verrucous porokeratosis in literature.^[2] Classically, it has been described to present as symmetrical verrucous papules and plaques with satellite lesions involving the genitogluteal region.^[3] The word *ptychotropica* itself is derived from Greek “*ptyche*” meaning fold and “*trope*” meaning turning and was first described as a separate entity in 1995 by Lucker *et al.* who called it “*porokeratosis ptychotropica*.”^[4] Its pathogenesis has not been clearly deciphered yet, with repeated friction being proposed as a triggering factor, as could also have been in this case as the patient was obese and had acanthosis nigricans too; other than infections, drugs, ultraviolet radiation, and immunosuppression.^[3] Furthermore, it has been found to occur more frequently in men.^[5] The condition is known to evade diagnosis for years, with patients undergoing a number of therapeutic trials, and respite from seemingly none.^[1] Absence of the characteristic keratotic rim makes it difficult to recognize, as does the presentation as a verrucous plaque. Although it has a predilection for genitogluteal region, lesions over thighs and lower legs have also been reported.^[5]

The various subtypes of porokeratosis are differentiated mainly on clinical grounds. Verrucous porokeratosis appears as annular white-yellow structure demarcating a central scar-like area surrounded by minimal peripheral vascularization on dermoscopy, which further aids in diagnosis, though the feature is not specific to this subtype.^[6] Cornoid lamellae, a histological *sine qua non* of porokeratosis not only helps to distinguish the entity from other clinical differentials, but also the various subtypes on the basis of its distribution,

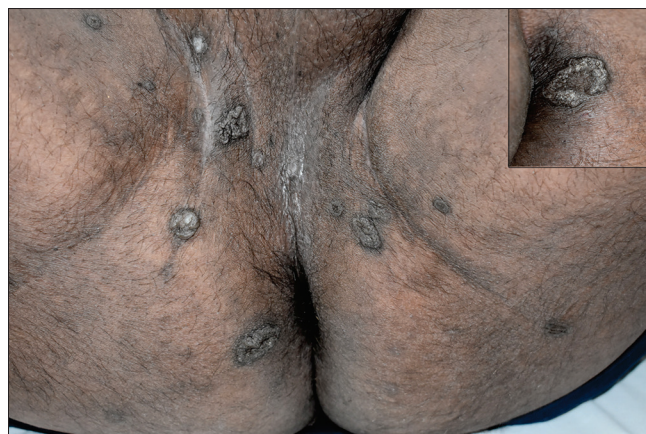

Figure 1: Multiple hyperpigmented annular plaques with verrucous surface. Inset shows closer view of a lesion with ridge-like prominent border

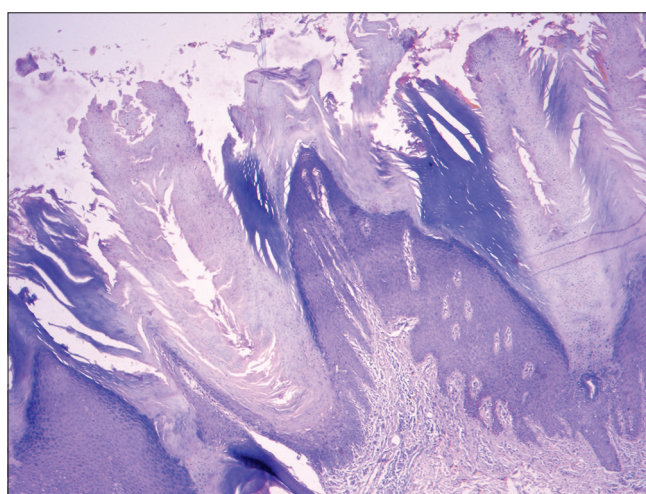


Figure 2: Orthokeratotic hyperkeratosis covering epidermis showing irregular psoriasiform hyperplasia and two adjacent broad cornoid lamellae (H and E, x40)

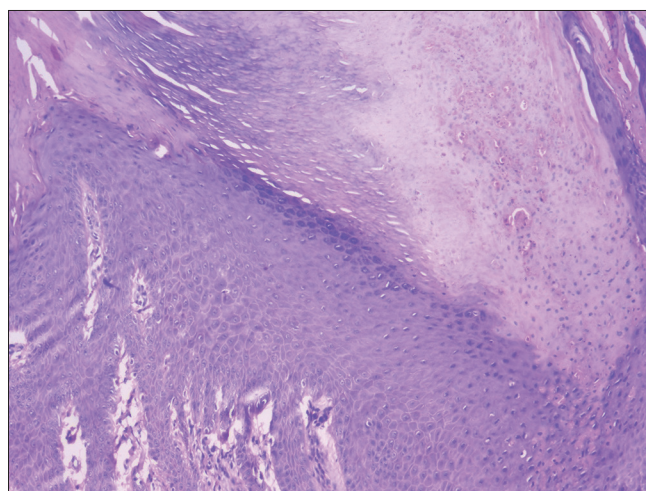


Figure 3: Cornoid lamella comprising vertically column of parakeratosis overlying shallow epidermal invagination with loss of granular layer and dyskeratotic keratinocytes (H and E, x100)

extent, and degree of prominence. Verrucous porokeratosis has a unique morphology and is

relatively refractory to treatment, therefore, requires differentiation from porokeratosis of Mibelli. This can be accomplished by the morphology of cornoid lamellae which are shown to be multiple, larger, and/or confluent, sometimes even spanning the entire surface, in verrucous porokeratosis.^[7] Moreover, psoriasiform hyperplasia, hyperkeratosis, dermal telangiectasia, and papillomatosis are few other features seen that often add to the already pronounced confusion of clinical similarity with psoriasis.^[8] Several cases have also been reported with cutaneous amyloid deposition secondary to frequent rubbing and scratching caused by itch.^[1] A noteworthy issue is the presence of dyskeratotic cells overexpressing p53 gene underlying the cornoid lamellae, indicating the role of tumor suppressor gene in its pathogenesis.^[8]

There is a lack of literature regarding difference in presentation of verrucous porokeratosis in immunocompetent and immunocompromised individuals, though porokeratosis in general has more extensive presentation in immunocompromised patients.^[9] Nature of the disease as revealed by clinical and histopathologic findings is essentially the same in both the group of patients.^[10]

Treatment options are largely limited for verrucous porokeratosis with the condition being mostly refractory to conventional therapy and none so far has been reported to achieve complete clearance. 5-fluorouracil, imiquimod, steroids, calcipotriol, tacrolimus, Vitamin A, and cryotherapy have been used but with variable results.^[11] Photodynamic therapy was found to be useful as an alternative treatment, but its utility remains limited to providing symptomatic relief in itch and partial clearance of lesion, and it did not achieve curative response.^[12] Smaller lesions can be approached for surgical intervention as has been shown in a few case reports, but it is difficult to comment upon the rate of recurrence on the basis of only these few.^[13] Further studies are required to ascertain the role and prognosis of surgery in verrucous porokeratosis.

Close follow-up is necessary, for there is a yet uncertain risk of malignancy given the known risk of 7%–11% with porokeratosis, mainly squamous cell carcinoma, and also Bowen disease and basal cell carcinoma.^[8] Although no such transformation has yet been reported with verrucous porokeratosis, this figure can run as high as up to 24% in porokeratosis in patients with risk factors (linear variant, long-standing large lesion, late onset, old age, and history of prior radiation exposure).^[14] Verrucous porokeratosis is known to run a long

course before being adequately diagnosed, and so need to be monitored to look for any possible malignant degeneration.

To conclude, verrucous porokeratosis is an important differential to be considered among nonvenereal dermatosis and needs histological confirmation for diagnosis. Refractoriness to conventional therapy and a possible potential of malignant transformation emphasize the need to keep the condition under monitoring. Better understanding of pathogenesis and advent of further therapeutic modalities may improve clinical outcome of these patients.

Declaration of patient consent

The authors certify that they have obtained all appropriate patient consent forms. In the form the patient(s) has/have given his/her/their consent for his/her/their images and other clinical information to be reported in the journal. The patients understand that their names and initials will not be published and due efforts will be made to conceal their identity, but anonymity cannot be guaranteed.

Financial support and sponsorship

Nil.

Conflicts of interest

There are no conflicts of interest.

REFERENCES

1. Yu YF, Wu YH. Verrucous porokeratosis (porokeratosis ptychotropica) with dermal amyloid deposits. *Dermatol Sin* 2013;31:145-48.
2. Tiwary AK, Mishra DK. Giant verrucous porokeratosis with psoriasiform alteration: A rare entity with atypical clinico-histopathologic features. *Indian J Dermatopathol Diagn Dermatol* 2017;4:19-20.
3. Chen TJ, Chou YC, Chen CH, Kuo TT, Hong HS. Genital porokeratosis: A series of 10 patients and review of the literature. *Br J Dermatol* 2006;155:325-9.
4. Lucker GP, Happle R, Steijlen PM. An unusual case of porokeratosis involving the natal cleft: Porokeratosis ptychotropica? *Br J Dermatol* 1995;132:150-1.
5. Takiguchi RH, White KP, White CR Jr, Simpson EL. Verrucous porokeratosis of the gluteal cleft (porokeratosis ptychotropica): A rare disorder easily misdiagnosed. *J Cutan Pathol* 2010;37:802-7.
6. Cabete J, Fidalgo A, Lencastre A, Diamantino E, João A. Porokeratosis ptychotropica of the scrotum: Dermoscopic evaluation of an atypical presentation. *An Bras Dermatol* 2015;90:191-3.
7. Biswas A. Cornoid lamellation revisited: Apropos of porokeratosis with emphasis on unusual clinicopathological variants. *Am J Dermatopathol* 2015;37:145-55.
8. Malek J, Chedraoui A, Kibbi AG, Ghosn S. Genitogluteal porokeratosis: 10 years to make the diagnosis! *Am J Dermatopathol* 2009;31:604-6.
9. Neumann RA, Knobler RM, Metze D, Jurecka W. Disseminated superficial porokeratosis and immunosuppression. *Br J Dermatol* 1988;119:375-80.

10. Raychaudhuri SP, Smoller BR. Porokeratosis in immunosuppressed and nonimmunosuppressed patients. *Int J Dermatol* 1992;31:781-2.
11. Tebet AC, Oliveira TG, Oliveira AR, Moriya FS, Filho OJ, Cucé LC. Porokeratosis ptychotropica. *An Bras Dermatol* 2016;91:134-36.
12. Fustà-Novell X, Podlipnik S, Combalia A, Morgado-Carrasco D, Ferrando J, Mascaró JM Jr., *et al.* Porokeratosis ptychotropica responding to photodynamic therapy: An alternative treatment for a refractory disease. *Photodermatol Photoimmunol Photomed* 2017;33:271-74.
13. Weidner T, Illing T, Miguel D, Elsner P. Treatment of porokeratosis: A systematic review. *Am J Clin Dermatol* 2017;18:435-49.
14. Otsuka F, Iwata M, Watanabe R, Chi HI, Ishibashi Y. Porokeratosis: Clinical and cellular characterization of its cancer-prone nature. *J Dermatol* 1992;19:702-6.