

Recurrent Cardiac Myxoma: A Case Report

Ravi K Mahavar, Dheeraj Arora, Ajmer Singh, Manisha Mishra

Department of Cardiac Anaesthesiology, Medanta-The Medicity, Gurugram, Haryana, India

ABSTRACT

Cardiac myxomas are the most common benign tumors of the heart. They are most commonly found in the left atrium, followed by a right atrium and rarely in the left ventricle. Herein, we report a rare case of left ventricular myxoma in a patient who had twice undergone removal of left atrial myxoma. Complete removal of the tumor through aortotomy, without causing fragmentation led to the uneventful recovery of the patient.

Keywords: Cardiac myxoma, left ventricular myxoma, recurrent myxoma

Address for correspondence: Dr. Ravi K Mahavar, Department of Cardiac Anaesthesiology, Medanta-The Medicity, Gurugram - 122 001, Haryana, India.

E-mail: drravimahavar@gmail.com

Submitted: 10-Jan-2020 **Revised:** 19-Mar-2020 **Accepted:** 25-Mar-2020 **Published:** 18-Oct-2021

INTRODUCTION

Cardiac myxomas are round or oval-shaped, pedunculated, mobile, intracavitary tumors. Myxomas are the most common benign tumors of heart occurring with a frequency of 7 cases per 10,000 population. The majority of myxomas are found in the left atrium (75%), followed by right atrium (20%), and rarely (3–4%) in the left ventricle (LV).^[1,2] Patients with LV myxoma are at risk of sudden cardiac death due to intracardiac obstruction, or cerebrovascular accident due to embolization. In rare cases, the patient may be asymptomatic and diagnosis is made on a routine checkup with an echocardiogram or magnetic resonance imaging (MRI). Once the diagnosis is made, immediate surgical removal of the tumor is recommended to prevent possible life-threatening complications.^[3]

CASE REPORT

A 20-year-old female patient from the Middle East was admitted to our institute with a chief complaint of

worsening dyspnea for the last 3 months (New York Heart Association class III). She had an episode of syncope with bilateral upper limb numbness a month ago. History was significant for surgical removal of left atrial myxoma in 2011 and 2015. Medical records of the previous cardiac surgeries were not available. Family history was negative for such illness in the siblings or parents. Her physical examination was unremarkable except for the presence of a previous sternotomy scar. Routine laboratory parameters and endocrine hormone levels such as thyroid hormones, adrenocorticotrophic hormone, and growth hormone were within normal limits. Whole-body computed tomography (CT) scan was performed to exclude any other primary tumor. Non-contrast CT scan of the brain showed an old wedge-shaped infarct in the right temporoparietal region with gliotic changes. 2-D transthoracic echocardiography (TTE) showed a 20 × 19 mm hyperechoic mass in the left ventricular outflow tract (LVOT) adherent to a ventricular aspect of the anterior mitral leaflet (AML). The mass swung back and forth with each beat into the LVOT cavity. There was no LVOT obstruction, no aortic regurgitation, trace mitral regurgitation with normal ventricular function. The

Videos Available on: www.annals.in

Access this article online

Quick Response Code:



Website:

www.annals.in

DOI:

10.4103/aca.ACA_7_20

This is an open access journal, and articles are distributed under the terms of the Creative Commons Attribution-NonCommercial-ShareAlike 4.0 License, which allows others to remix, tweak, and build upon the work non-commercially, as long as appropriate credit is given and the new creations are licensed under the identical terms.

For reprints contact: WKHLRPMedknow_reprints@wolterskluwer.com

How to cite this article: Mahavar RK, Arora D, Singh A, Mishra M. Recurrent cardiac myxoma: A case report. *Ann Card Anaesth* 2021;24:490-2.

cardiac MRI reported an oval lesion in LVOT measuring 21×18 mm, suggestive of myxoma [Figure 1].

The patient was taken up for surgical resection of the mass with a high-risk consent. Considering a re-redo surgery, necessary precautions were taken including the application of external defibrillator pads, availability of blood, and looping of the femoral vessel for emergent cardiopulmonary bypass institution, etc. Intraoperative transesophageal echocardiography (TEE) confirmed the findings of TTE. The mass was seen adherent to AML [Figure 2] and was swinging back and forth into the LVOT cavity [Video 1]. After sternotomy, aorto-bicaval cannulation, normothermic antegrade cardioplegia, a transverse aortotomy was performed. A translucent jelly-like myxomatous mass became visible through the aortic cusps. The pedicle of the mass was seen attached to the junction of anterolateral papillary muscle and its chordae. *En-masse* removal of the tumor was done carefully [Figure 3] without causing its fragmentation, or any damage to the mitral valve apparatus. TEE evaluation confirmed the complete removal of the mass and trace mitral regurgitation. Histopathology examination of the specimen confirmed the diagnosis of myxoma. The postoperative course was uneventful, and a 6-month follow-up echocardiogram did not show recurrence of the tumor.

DISCUSSION

Primary cardiac tumors of the LV are extremely rare. A recent, thorough review of literature has reported only 73 cases of LV myxoma treated surgically, and most of them as single case reports.^[4] Though histologically benign, LV myxomas can lead to devastating complications such as sudden cardiac death or stroke, if left untreated. Myxomas are generally round or oval, pedunculated tumors with a broad base. They grow at a rate of about 0.15 cm per month.^[5] Even if the patient is asymptomatic, surgical removal of the myxoma should be performed as soon as the diagnosis is made. Around 5% of myxomas have familial pattern and shows a high recurrence rate (up to 21–67%) after surgical resection.^[6] Carney's complex, seen in the majority of familial myxomas, carries a high recurrence rate (20%) even after adequate surgical resection.^[7,8] It must be excluded by measuring endocrine hormone levels in patients with recurrent myxomas.

Sign and symptoms of an LV myxoma depend on its size, location, and mobility. LV myxoma can produce symptoms by interfering valvular function or causing LVOT obstruction or congestive heart failure. Embolic

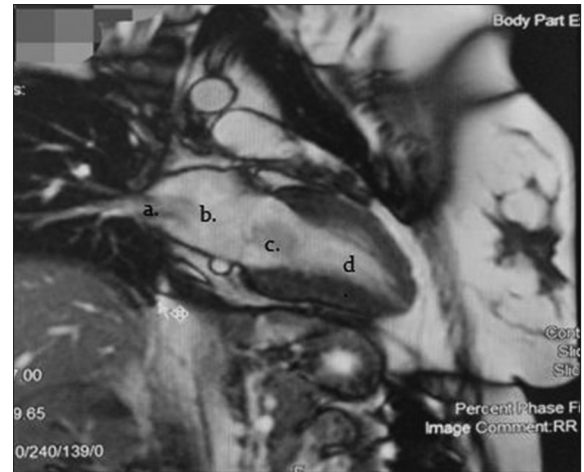


Figure 1: Cardiac MRI showing (a) pulmonary veins, (b) left atrium, (c) myxomatous mass, and (d) left ventricular cavity

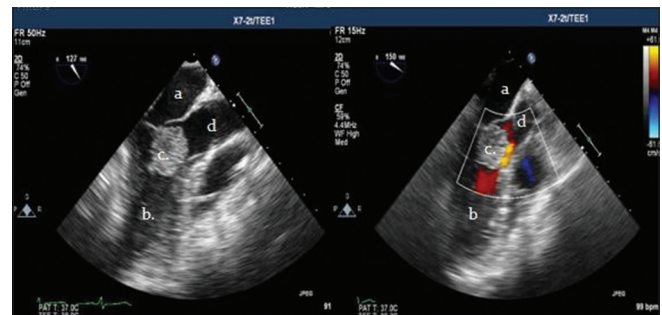


Figure 2: Mid esophageal long-axis view on transesophageal echocardiography showing (a) left atrium, (b) left ventricle, (c) myxoma, (d) left ventricular outflow tract. Color Doppler image is shown on the right

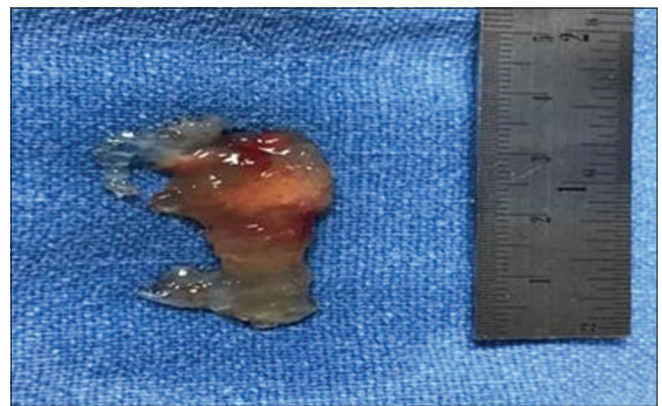


Figure 3: Resected myxoma

incidence is very high in LV myxoma (64%) and the brain is the most prone organ for embolization.^[9] TEE is the most appropriate imaging modality for screening and diagnosis of myxomas. It is required to evaluate tumor size, location, mobility, and attachment. It can detect tumors as small as 1 to 3 mm in diameter. Intraoperative TEE is also useful to ensure complete resection of the tumor before the patient leaves the operating room. MRI

can differentiate between tumor and non-tumor mass, benign and malignant mass, and can tell the characteristics and invasion of the tumor.

Recurrence of myxoma can occur due to (i) tumor implantation (seeding at the time of removal), (ii) incomplete removal, or (iii) growth from a new focus (multicentric origin). The incidence of recurrence is 1–4% in sporadic myxoma, and 21–67% in familial myxoma. The site of recurrence can be different from the primary site, as happened in this patient. Though family history was negative for the presence of myxoma in this patient, screening of first-degree relatives should be considered to find out any occult tumor.

Surgical resection is the only treatment for any myxoma and surgical approach depends on the site and attachment of the tumor. A transverse aortotomy approach, used in this patient, has previously been described by Quin *et al.*^[3] This approach helps in avoiding ventriculotomy and its potential complications. The surgical approaches described in the literature include (i) through the left atrium and mitral valve, (ii) right atrium and atrial septum, (iii) ascending aorta, with or without video assistance, or (iv) left ventriculotomy for bigger tumors.^[10,11] Complete resection of the base of the tumor (at the attachment site) is more important to prevent the recurrence, than the choice of the approach itself. It is also important to have careful handling of the cardiac structures (valve, chordae tendinea, papillary muscles) and tumor during its removal to reduce the possibility of fragmentation and the occurrence of the embolic phenomenon.

In conclusion, successful management of recurrent cardiac myxoma, which recurred twice after surgical resection, is reported. However, regular follow-up of the patient is essential to exclude recurrence, and her family members too need serial monitoring.

Declaration of patient consent

The authors certify that they have obtained all appropriate patient consent forms. In the form the patient(s) has/have given his/her/their consent for his/her/their images and other clinical information to be reported in the journal. The patients understand that their names and initials will not be published and due efforts will be made to conceal their identity, but anonymity cannot be guaranteed.

Financial support and sponsorship

Nil.

Conflicts of interest

There are no conflicts of interest.

REFERENCES

1. Reynen K. Cardiac myxomas. *N Engl J Med* 1995;333:1610-17.
2. Hassan M, Smith JM. Robotic assisted excision of a left ventricular myxoma. *Interact Cardiovasc Thorac Surg* 2012;14:113-4.
3. Qin W, Wang L, Chen X, Liu P, Wang R. Left ventricular myxoma: A case report. *J Biomed Res* 2014;28:506-8.
4. Abad C, Novoa J, Delgado A, Alonso A. Myxoma of the left ventricle. *Tex Heart Inst J* 2014;41:395-400.
5. Rendón F, Agosti J, Llorente A, Rodrigo D, Montes K. Intramural cardiac myxoma in left ventricular wall: An unusual location. *Asian Cardiovasc Thorac Ann* 2002;10:170-2.
6. King YL, Dickens P, Chan ACL. Tumors of the heart. *Arch Pathol Lab Med* 1993;117:1027.
7. Carney JA. Differences between nonfamilial and familial cardiac myxoma. *Am J Surg Pathol* 1985;9:53-5.
8. Aspres N, Bleasel NR, Stapleton KM. Genetic testing of family with Carney complex member leads to successful early removal of asymptomatic atrial myxomas in mother of patient. *Australia J Dermatol* 2003;44:121-22.
9. Meller J, Teichholz LE, Pickard AD, Matta R, Litwak R, Herman MV, *et al.* Left ventricular myxoma: Echocardiographic diagnosis and review of the literature. *Am J Med* 1977;63:816-23.
10. Robert J, Brack M, Hottinger S, Kadner A, Baur HR. A rare case of left ventricular cardiac myxoma with obstruction of the left ventricular outflow tract and atypical involvement of the mitral valve. *Eur J Echocardiogr* 2009;10:593-5.
11. Arruda MV, Braile DM, Joaquim MR, Soares MJ, Alves RH. Resection of left ventricular myxoma after embolic stroke. *Rev Bras Cir Cardiovasc* 2008;23:578-80.