

Magnetic Resonance Imaging in the Evaluation of Cesarean Scar Defect

Wu Shun Felix Wong¹, Wing Tak Fung²

¹Department of Obstetrics and Gynecology, The University of New South Wales, Sydney, New South Wales, Australia, ²Hong Kong Medical Imaging Limited, Hong Kong

Abstract

The incidence of Cesarean scar defect (CSD) would increase with the increasing trends of cesarean section delivery. The actual incidence of this condition is unknown, but it had been estimated by hysteroscopy, sonohysterography, or transvaginal ultrasound to be around 50% of patients with cesarean section. CSD is often asymptomatic, but it may produce common symptoms such as abnormal uterine bleeding, infertility, and pelvic pain. Adverse pregnancy outcomes with scar ectopic pregnancy, uterine rupture had been reported. The use of magnetic resonance imaging (MRI) imaging of this condition is seldom performed and reported. This paper is to analyze retrospectively the MRI finding of 158 women, so as to review the MRI findings of CSD, their appearances and measurements.

Keywords: Cesarean scar defect, MRI measurements, MRI appearances

INTRODUCTION

With increasing cesarean section rate nowadays, the risks of cesarean scar defect (CSD) should increase. CSD is defined by ultrasound imaging as a triangular hypoechoic defect in the myometrium at the site of the previous cesarean section scar. However, patients with CSD are sometimes asymptomatic. Therefore, the actual incidence of this complication is unknown and likely underreported. Yet, some patients with CSD can have symptoms of abnormal uterine bleeding, pelvic pain, infertility, uterine rupture, and potential risks of adverse pregnancy outcome. However, the clinical awareness of CSD is still lacking among many gynecologists and their patients.

There are increasing clinical reports of CSD in the literature,^[1] most CSD are diagnosed by ultrasound scan during investigations for miscarriage, CS ectopic pregnancy, and sometimes abnormal uterine bleeding. In nonpregnancy women, ultrasound scans for the diagnosis and assessment of this condition had been reported.^[2-4] In pregnant women, the defect becomes easily diagnosed by ultrasound scan due to the distending amniotic fluid filling the CSD.^[5] Armstrong *et al.* 2003 stated that transvaginal ultrasound (TVU) was useful and highly accurate in detecting CSD, defined by the presence of fluid within the scar niche.^[6]

Magnetic resonance imaging (MRI) imaging of CSD has not been commonly reported because MRI is an expensive imaging tool and is not often requested for investigations of abnormal uterine bleeding or other noncancerous pathologies. Besides, due to unawareness of the clinical significance of CSD by the radiologists, MRI scans as requested by gynecologists often failed by radiologists to look for and make a diagnosis of this emerging condition of CSD. MRI scan is often performed for nongynecological conditions in our practice, and in this study, we retrospectively reviewed all outpatient cases over a period of 1 year to evaluate the incidence and finding of MRI imaging to define the incidence of CSD in our asymptomatic patients. It is also the purpose of this paper to present the various MRI appearances and measurements of CSD, so as to, arouse interest toward the direction of the management and lead to larger retrospective or prospective MRI studies of CSD in the near future.

MATERIALS AND METHODS

Our practice is a busy private imaging practice in the Central district, Hong Kong. We provide MRI imaging

Address for correspondence: Dr. Wu Shun Felix Wong,
Room 521, Central Building, 1-3 Pedder Street, Central, Hong Kong.
E-mail: fwong3@hotmail.com.hk

Access this article online

Quick Response Code:



Website:
www.e-gmit.com

DOI:
10.4103/GMIT.GMIT_23_18

This is an open access journal, and articles are distributed under the terms of the Creative Commons Attribution-NonCommercial-ShareAlike 4.0 License, which allows others to remix, tweak, and build upon the work non-commercially, as long as appropriate credit is given and the new creations are licensed under the identical terms.

For reprints contact: reprints@medknow.com

How to cite this article: Wong WS, Fung WT. Magnetic resonance imaging in the evaluation of cesarean scar defect. *Gynecol Minim Invasive Ther* 2018;7:104-7.

services to patients as outpatients for the investigations of nongynecological conditions. We retrieved 158 pelvic MRI scans in the computer records of those women referred to us from May 20, 2014, to April 26, 2015. Each MRI scan record was reassessed and studied by one of the authors, a consultant radiologist. All MRI pictures were reviewed to detect any CSD which was defined as a focal area of myometrial thinning at the anterior lower uterine segment.

A sagittal T2-weighted scan of the uterus was examined for a scar niche, which was defined as an anechoic area at the site of the cesarean scar with a depth of at least 1 mm. As shown in Figure 1, the niche was measured by the depth (the vertical distance between the base and apex of the defect), by the width (the distance of the base of the defect), and the remaining myometrium (the distance from the serosal surface of the uterus to the apex of the niche) (t). The total myometrial thickness adjacent to the niche was also measured next to the base of the defect (T). The measurements are expressed as millimeters, and the mean and standard deviation of all CSD measurement were calculated. The appearances of all MRI diagnosed CSD were grouped and described in Figure 2.

RESULTS

From May 2014 to April 2015, 10 out of 158 patients (6.3%) had CSD detected by pelvic MRI scans in our practice. The patients' characteristics and their MRI measurements are listed in Table 1. The median width of the base was 6.45 mm (range 3.78–13), median depth of the niche was 4.6 mm (range 2.5–5.93), the remaining myometrial thickness was 4.29 mm (range 3.41–7.39), and the median total myometrial thickness adjacent to the niche is 12 mm (range 6.58–18.1).

The shapes of MRI diagnosed CSD are triangular (60%), linear (30%), and irregular rectangular (10%) [Figure 2]. We used the criteria of defining a CSD niche as used by Bij de Vaate *et al.*^[7]

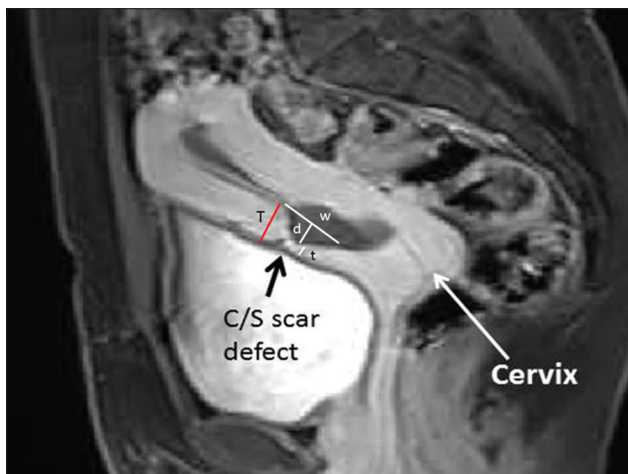


Figure 1: Magnetic resonance imaging measurement of Cesarean scar defect: D = Depth of the defect; w = Width of the defect; t = Thickness of scar myometrium; T = Adjacent myometrial thickness

DISCUSSION

A systematic literature review on women who underwent previous cesarean section, as evaluated by hystero-graphy, sonohysterography (SHG), or TVU, had demonstrated that the incidence of uterine scar defects is up to 50% in women with infertility and previous cesarean section.^[8] Transvaginal sonography is a simple, low cost, and noninvasive investigation that should be considered as the first choice for screening. Tower and Frishman 2013 proposed that a CSD can also be defined on transvaginal SHG as a triangular hypoechoic defect in the myometrium at the anterior lower uterine segment.^[4] Using ultrasound imaging, Ofili-Yebovi *et al.* defined the degree of severity of the defect based on the ratio of the myometrial thickness at the scar to the thickness of adjacent myometrium, i.e. severe defect is a ratio of <50%.^[9] Osseer *et al.* defined a large defect as scar myometrial thickness of <2.2 mm on TVUS or <2.5 mm on the sonohysterogram.^[11] Nevertheless, the unskilled gynecologists or the use of low-resolution ultrasound machine could have missed the defect during routine ultrasound scan especially the operator does not have a high index of suspicion of CSD and looking for it.

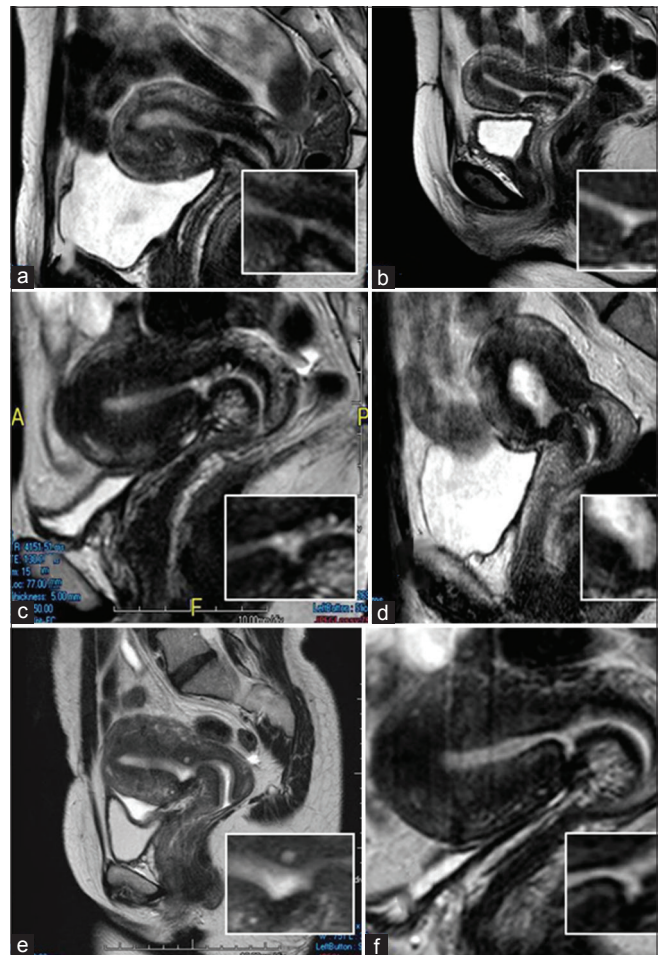


Figure 2: The shapes of magnetic resonance imaging diagnosed Cesarean scar defect are (1) linear (a and b), (2) triangular (c), and (3) irregular rectangular in shape (d-f)

Table 1: The magnetic resonance imaging measurements from the 10 patients with cesarean scar defect

Patients	Age	Width of scar (w) (All measurements in mm)	Depth of scar (d)	Scar myometrial thickness (t)	Adjacent myometrial thickness (T)	Ratio t/T
1	50	8.44	3.86	3.86	6.58	0.59
2	46	9.47	5.93	6.02	9.64	0.62
3	36	7.39	4.40	7.39	15.00	0.49
4	43	4.46	4.34	7.00	13.40	0.52
5	43	13.00	4.80	6.02	18.10	0.33
6	39	5.51	5.80	4.82	16.40	0.29
7	48	11.80	3.96	3.41	9.33	0.37
8	40	5.44	4.99	4.87	10.60	0.46
9	42	5.27	5.26	4.25	14.40	0.30
10	51	3.78	2.50	4.29	10.40	0.41
Median	43	6.45	4.60	4.85	12.00	0.40
Total=158 patients						
Incidence 10/158=6.33%						

Regarding the CSD shapes on hysterosalpingography, Surapaneni and Silberzweig 2008 defined the CSD as a diverticulum at the lower uterine cavity, uterine isthmus, or upper endocervical canal. In their study of 148 patients with previous CS and infertility, 60% of their patients had defects showing anterior uterine diverticula. Fifty-eight (65%) of the diverticula were focal outpouchings, and 31 (35%) were thin linear defects.^[10]

However, the incidence of CSD as reported by MRI had not been reported. It is because MRI is not widely employed as an investigative imaging tool for abnormal uterine bleeding or infertility. It is also not a surprise for radiologists not reporting it because it is not being asked for or considered the reporting is irrelevant. In our small series, we found that only 6.3% of women had CSD in the general population investigated by MRI for other pathology. The limitation of this study is that we did not have a detailed clinical history of women referred to us for MRI investigations. Compared to up to 50% CSD reported by ultrasound scan, this lower incidence might be due to this group of patients with various pathologies and symptoms being investigated.

A prospective MRI study if ethically feasible could give a clearer picture of the incidence of CSD in the general population or different groups of patients for investigations. It is because MRI can accurately define the CS scar lesions. The sensitivity of ultrasound scan to diagnose CS scar defect depends on the skill and deliberate search for the defect at the time of performing the scan. MRI, on the other hand, can easily define the defects and can also be retrospectively reviewed.

From our data, when we used the same criteria of Ofili-Yebovi *et al.* to define the severe defect based on the ratio of the myometrial thickness at the scar to the thickness of adjacent myometrium as a ratio of <50%. We had seven out of ten patients with severe CSD.^[9] On the other hand, using the criteria of Osser *et al.* who defined a large defect as scar myometrial thickness of < 2.2–2.5 mm on

the sonohysterogram,^[1] none of our patients had large CS defect. As there is lack of studies using MRI measurements to correlate with any clinical presentation and outcome, we could not draw any conclusion from our data with this preliminary and retrospective study.

The purpose of our study is to arouse the interest of using MRI in the evaluation of CSD. Hopefully, in larger centers or hospitals where MRI was often performed to study gynecological conditions, similar retrospective analysis of these patients' presentation and outcome might help to evaluate the clinical significance of various MRI appearance and measurements of CSD. Future prospective MRI study might be able to correlate the findings with other investigative imaging, to yield a better picture of the outcome when CSD is diagnosed. For the time being, as the significance of myometrial scar thickness or large defect are not known, incidental finding of CSD using ultrasound or MRI investigation can pose a management problem for the women with CSD.

Up to now, it is still controversial about (when, how, and what) treatment should be offered to our patients. There is a lack of large series or prospective randomized trials to determine the best treatment and whether patient after surgery will have reduced ectopic CS pregnancies, improved fertility, reduced ruptures after the above surgical treatment.

CONCLUSION

Both MRI and ultrasound scan are useful investigations to detect and define the extent of the "defect," and hopefully, large retrospective study with MRI measurements of CSD can correlate and predict the clinical symptoms and its pregnancy outcome. This will also help to make a diagnosis to guide the best treatment for CSD.

Financial support and sponsorship

Nil.

Conflicts of interest

There are no conflicts of interest.

REFERENCES

1. Osser OV, Jokubkiene L, Valentin L. High prevalence of defects in cesarean section scars at transvaginal ultrasound examination. *Ultrasound Obstet Gynecol* 2009;34:90-7.
2. Thurmond AS, Harvey WJ, Smith SA. Cesarean section scar as a cause of abnormal vaginal bleeding: Diagnosis by sonohysterography. *J Ultrasound Med* 1999;18:13-6.
3. Naji O, Abdallah Y, Bij De Vaate AJ, Smith A, Pexsters A, Stalder C, *et al.* Standardized approach for imaging and measuring cesarean section scars using ultrasonography. *Ultrasound Obstet Gynecol* 2012;39:252-9.
4. Tower AM, Frishman GN. Cesarean scar defects: An underrecognized cause of abnormal uterine bleeding and other gynecologic complications. *J Minim Invasive Gynecol* 2013;20:562-72.
5. Mohammed AB, Al-Moghazi DA, Hamdy MT, Mohammed EM. Ultrasonographic evaluation of lower uterine segment thickness in pregnant women with previous cesarean section. *Middle East Fertil Soc J* 2010;15:188-93.
6. Armstrong V, Hansen WF, Van Voorhis BJ, Syrop CH. Detection of cesarean scars by transvaginal ultrasound. *Obstet Gynecol* 2003;101:61-5.
7. Bij de Vaate AJ, Brölmann HA, van der Voet LF, van der Slikke JW, Veersema S, Huirne JA, *et al.* Ultrasound evaluation of the cesarean scar: Relation between a niche and postmenstrual spotting. *Ultrasound Obstet Gynecol* 2011;37:93-9.
8. Roberge S, Boutin A, Chaillet N, Moore L, Jastrow N, Demers S, *et al.* Systematic review of cesarean scar assessment in the nonpregnant state: Imaging techniques and uterine scar defect. *Am J Perinatol* 2012;29:465-71.
9. Ofili-Yebovi D, Ben-Nagi J, Sawyer E, Yazbek J, Lee C, Gonzalez J, *et al.* Deficient lower-segment cesarean section scars: Prevalence and risk factors. *Ultrasound Obstet Gynecol* 2008;31:72-7.
10. Surapaneni K, Silberzweig JE. Cesarean section scar diverticulum: Appearance on hysterosalpingography. *AJR Am J Roentgenol* 2008;190:870-4.