

Axillary artery fibromuscular dysplasia in a symptomatic type B aortic dissection causing acute limb ischemia

Brian Sullivan, MD, Nathan Droz, MD, and Vipul Khetarpaul, MD, *St. Louis, MO*

ABSTRACT

Fibromuscular dysplasia (FMD) can manifest outside of its classic presentation with unusual pathology. In the present report, we have described a case of an older male patient with aortic degeneration related to acute type B dissection who had required emergent left carotid–subclavian transposition and aortic stenting. Intraoperatively, his axillary artery FMD led to acute upper extremity ischemia. The patient was treated with classic maneuvers, including balloon angioplasty, reflecting the best practices in vascular surgery. We have also discussed the diagnosis, classification, and management of FMD. (*J Vasc Surg Cases Innov Tech* 2022;8:813-5.)

Keywords: Aortic dissection; Best practices; Fibromuscular dysplasia; Upper limb ischemia

Fibromuscular dysplasia (FMD) is a nonatherosclerotic disease characterized by abnormal arterial wall proliferation and architecture. Classically, FMD will affect medium-size arteries, such as the renal and extracranial vascular beds. However, it can affect nearly any vessel in the body, including the aorta. The common manifestations of FMD include arterial dissection, aneurysm, and the sequelae of arterial stenosis in middle-age women. In the present report, we have described the case of a 75-year-old male patient with type B aortic dissection who had required emergent left carotid–subclavian transposition and endograft placement. However, his axillary artery FMD had resulted in upper extremity ischemia necessitating reexploration and treatment. The patient provided written informed consent for the report of his case details and imaging studies.

CASE REPORT

The present patient was a 75-year-old man with history of acute type B aortic dissection managed medically at an outside hospital. He had presented to our institution with new-onset back and chest pain. Computed tomography angiography revealed 15 mm of interval growth of his thoracic aorta compared with an outside imaging study 3 weeks earlier. His symptomatic enlarging aorta was treated with impulse control, and he was taken emergently to the operating room for repair. We performed an uncomplicated left subclavian-to-carotid

transposition via supraclavicular incision and zone 2 to 5 thoracic endograft placement via percutaneous femoral access. During the procedure, a radiology addendum was telephoned to the operating team to report the finding of beading of the bilateral distal subclavian and axillary arteries consistent with FMD (Fig). Robust Doppler signals had been noted proximally and distally to the anastomosis, and the patient had had a palpable pulse after transposition. However, at completion of the procedure, a thorough examination had revealed that the patient had had a newly pale left hand and no radial pulse. Bedside ultrasound demonstrated no flow near the level of the pectoralis minor tendon. Initially suspecting an arterial embolism or thrombosis, we performed a left brachial cutdown. A Fogarty balloon was passed distally without retrieval of any thrombus. The Fogarty balloon was then passed retrogradely, and resistance was noted. Withdrawal resulted in fresh, brisk inflow but no thrombus. Suspecting pathology related to his FMD, left brachial wire and catheter access were obtained. Angiography confirmed distal axillosubclavian narrowing and no anastomotic defect. Serial angioplasty was performed with good angiographic results. The arteriotomy was closed, and the patient was noted to have strongly palpable pulses in his left arm at completion of the case.

DISCUSSION

The diagnosis of FMD can be elusive and should be supported by the presence of one or several criteria. The first FMD international consensus guidelines were reported in 2019. The guidelines suggested criteria for diagnosis including imaging findings and exclusion of differential diagnoses, and a standard classification system.¹

Our patient had had an unusual case of FMD, because of both the anatomic location and the patient's sex. However, our patient had had several important factors supporting the diagnosis of FMD. First, he had the primary risk factor of smoking. Second, tortuosity and hallmark multifocal stenoses were present and had been confirmed via two imaging modalities. Third, a differential diagnosis of native vessel arteriospasm, one or more vasculitides, or connective tissue disorders was less likely

From the Section of Vascular Surgery, Department of General Surgery, Washington University in St. Louis

Author conflict of interest: none.

Correspondence: Vipul Khetarpaul, MD, Section of Vascular Surgery, Department of General Surgery, Washington University in St. Louis, 660 South Euclid Ave, Campus Box 8109, St. Louis, MO 63110 (e-mail: khetarpaulv@wustl.edu).

The editors and reviewers of this article have no relevant financial relationships to disclose per the Journal policy that requires reviewers to decline review of any manuscript for which they may have a conflict of interest.

2468-4287

© 2022 Published by Elsevier Inc. on behalf of Society for Vascular Surgery. This is an open access article under the CC BY-NC-ND license (<http://creativecommons.org/licenses/by-nc-nd/4.0/>).

<https://doi.org/10.1016/j.jvscit.2022.08.021>

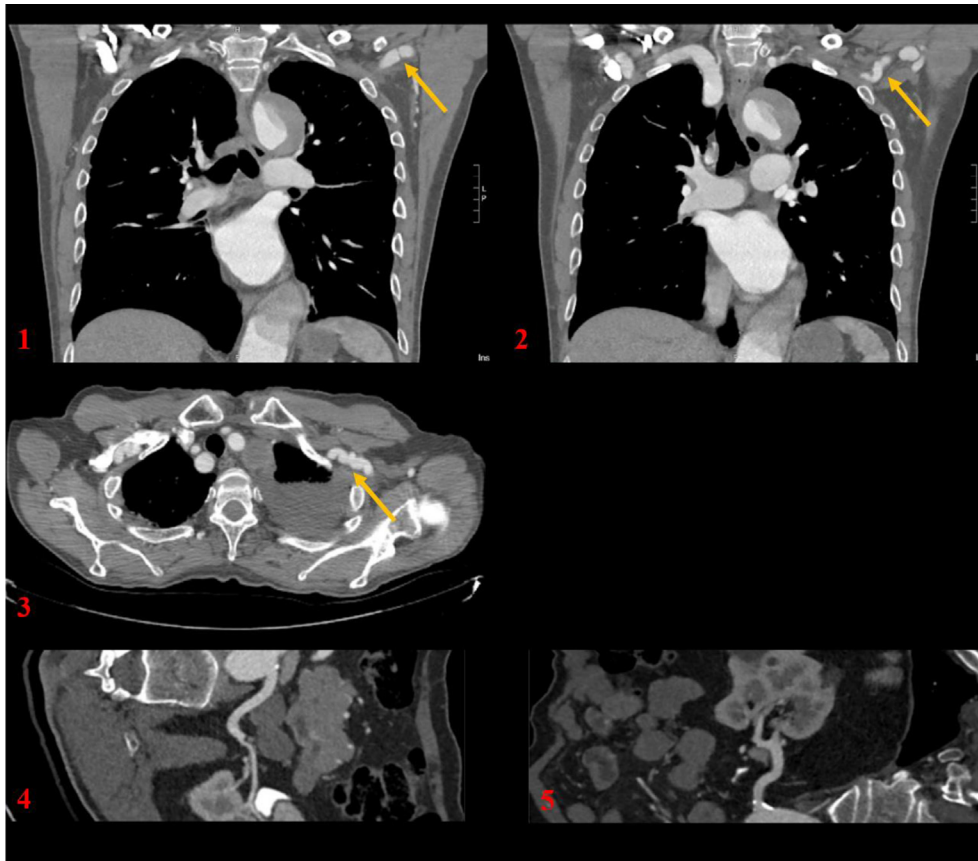


Fig. 1-3, Selected computed tomography angiographic images. *Yellow arrows* indicate webbing, tortuosity, and beading consistent with fibromuscular dysplasia (FMD). Also visible is patient's thoracic aortic aneurysm resulting from his acute type B dissection. **4,5,** Contour mapping of right and left renal arteries, respectively, with no evidence of FMD within the renal arteries identified.

owing to the agreement of the findings from multiple imaging modalities, negative review of systems for systemic inflammatory or autoimmune conditions, and the lack of clinical findings indicating Ehlers-Danlos syndrome or Loeys-Dietz syndrome.

Other factors that can support the diagnosis of upper extremity FMD include discrepant cuff pressures and the presence of Reynaud's phenomenon. Because of our patient's acute presentation to our institution and the resultant carotid–subclavian transposition, we were unable to confirm whether the arterial pressure index had been discrepant because of disease. We could not determine whether our patient had experienced episodes of Raynaud's phenomenon preoperatively. For FMD of any type, the U.S. FMD registry has recognized hypertension, headaches, pulsatile tinnitus, and dizziness as the most common symptoms.² Of these, our patient had had only hypertension, although it was not renovascular in nature (Fig). In classifying our patient's FMD, it was present within the upper extremities and was symptomatic, multifocal, and bilateral.

The FMD international consensus guidelines support the use of aspirin to treat FMD. Our patient's therapy

was maintained with aspirin 81 mg. It has been recommended to monitor the affected artery beds with imaging studies. For our patient, upper extremity duplex ultrasound and Doppler ultrasound were used to evaluate for changes suggestive of disease recurrence. The guidelines have also suggested that all patients with FMD should undergo one-time cranial CTA to assess for intracranial aneurysms.

An intriguing possibility in the present case was whether our patient's type B aortic dissection might have resulted from his FMD. Data from the U.S. FMD registry support the idea that FMD-associated arterial dissection can occur. This phenomenon might be more common in men than in women. Kim et al³ reported that men had had a 39.6% incidence of any arterial dissection compared with 20% for women. Nevertheless, reports of tandem aortic conditions have been rare. Kar et al⁴ described a case of a 58-year-old woman with multivessel FMD who had presented with acute aortic dissection. However, histopathologic examination from her eventual aortic repair did not include obvious evidence of FMD.⁴ Ciura et al⁵ reported the case of a 64-year-old man with carotid FMD who had presented

with type A dissection and whose aortic histopathologic findings confirmed the presence of FMD. Likewise, Tasaki et al⁶ described the case of a 40-year-old woman with aortic dissection and histopathologic evidence of FMD. The fourth case was the index report of aortic FMD by Gatalica et al.⁷ They reported the case of an 18-year-old man whose histopathologic findings confirmed the presence of aortic FMD.⁷ In our patient, a histopathologic evaluation of the aortic tissue was not performed owing to his endovascular repair, although we have remained suspicious of a contributing etiology.

The treatment of FMD starts with optimal medical management for the sequelae of the lesions. Thus, headache or tinnitus caused by cerebrovascular FMD can be controlled with an appropriate antihypertensive regimen. Likewise, uncomplicated renovascular hypertension should preferentially be treated medically, with surgical treatment reserved for progressive renal failure or refractory hypertension despite the best multiple medical therapy. Regardless of the location, endovascular options such as percutaneous transluminal angioplasty should be the treatment modality of choice owing to their ability to disrupt the abnormal collagen and smooth muscle within the target lesion. In the case of our patient, the use of a Fogarty balloon and angioplasty might have served the purpose of disrupting the intraluminal webbing and releasing the vasospasm present within the FMD-affected lesion.

Additionally, we believe that the events that unfolded represented the best practices in vascular surgery. Thus, intraoperatively, an experienced radiology team laid the groundwork for diagnosing this complication by issuing an insightful addendum regarding their concern for the presence of FMD. Also, A hybrid operating room was available to treat our patient's acute aortic pathology. In addition, a thorough postoperative examination by

the surgical team in the operating suite had identified the threatened limb. Therefore, the patient did not leave the operating room before the new deficit of unknown origin had been addressed. Finally, a multidisciplinary patient care team consisting of anesthesia staff and technologists, scrub nurses, radiology technicians, circulators, and vascular surgeons were able to work together to rapidly return the operating room to action and ensure a good patient outcome.

CONCLUSIONS

FMD continues to be a mysterious and challenging disease, and rare encounters can result in significant morbidity for patients. In the present patient, the unique and untimely presentation of upper extremity FMD associated with an acute aortic pathology and resulting in limb-threatening ischemia was resolved by angioplasty.

REFERENCES

1. Cornik H, Persu A, Adlam D, Aparicio L, Azizi M, Boulanger M, et al. First international consensus on the diagnosis and management of fibromuscular dysplasia. *Vasc Med* 2019;24:164-89.
2. Olin J, Froehlich J, Gu X, Bacharach J, Eagle K, Gray B, et al. The United States registry for fibromuscular dysplasia. *Circulation* 2012;125:3182-90.
3. Kim E, Olin J, Froehlich J. Clinical manifestations of fibromuscular dysplasia vary by patient sex: a report of the United States registry for fibromuscular dysplasia. *J Am Coll Cardiol* 2013;62:2026-8.
4. Kar S, Gopaladas R, Kumar A. Acute aortic dissection and stroke in multivessel fibromuscular dysplasia. *Tex Heart Inst J* 2013;40:88-90.
5. Ciura V, Bromley A, Wong J. A case of type A aortic dissection with underlying fibromuscular dysplasia. *J Radiol Case Rep* 2011;5:22-8.
6. Tasaki T, Hatanaka K, Kirishma M, Ohnishi S, Goto Y, Kitazono I, et al. Aortic fibromuscular dysplasia complicated by dissection: a case report and review of literature. *Cardiovasc Pathol* 2017;31:41-6.
7. Gatalica Z, Gibas Z, Martinez-Hernandez A. Dissecting aortic aneurysm as a complication of generalized fibromuscular dysplasia. *Hum Pathol* 1992;23:586-8.

Submitted May 11, 2022; accepted Aug 22, 2022.