



Opinion Paper

Could radiation exposure be the Achilles' heel of distal transradial artery access?



Anastasios Apostolos, MD, Georgios Vasilagkos, MD, Grigorios Tsigkas, MD, PhD *

Department of Cardiology, University General Hospital of Patras, Patras, Greece

ARTICLE INFO

Article history:

Received 10 April 2022

Received in revised form

11 June 2022

Accepted 14 June 2022

Available online 15 June 2022

Keywords:

Distal transradial access

Anatomical snuffbox

Angiography

Transradial approach

ABSTRACT

Distal transradial access for vascular interventions has gained ground recently. While the novel approach is associated with reduced radial artery occlusion and faster hemostasis, it could be related with prolonged procedural time, higher crossover rate and increased radiation, comparing to conventional transradial approach. Whether the radiation is increased in the procedures performed by the novel approach remains unambiguous. In the specific article, we aim to review the current literature and to propose possible explanations for this phenomenon. Could radiation be the Achilles' heel of distal transradial artery access?

© 2022 Cardiological Society of India. Published by Elsevier, a division of RELX India, Pvt. Ltd. This is an open access article under the CC BY-NC-ND license (<http://creativecommons.org/licenses/by-nc-nd/4.0/>).

In 2017, Kiemenej et al proposed a novel approach for vascular access through anatomical snuffbox.¹ Distal transradial access (dTRA) has gained ground for both cerebral and coronary angiography and interventions.^{2,3} Notably, dTRA could be used for complex cases, such as the recanalization of chronic total occlusions, as a second access site for transcatheter aortic valve implantation, for coil embolization and carotid stenting.^{3–5} The first observational, non-randomized studies supported that dTRA could be used as an alternative approach for conventional transradial access (TRA), presenting it as a safe and feasible method. Recently, the first large-scale randomized control trials comparing dTRA versus TRA for coronary angiography and interventions were published, confirming that radial artery occlusion and hemostasis time were decreased in dTRA arm; nevertheless, crossover rate, procedural time and radiation were increased.^{6–8}

The radiation consists a major disadvantage of coronary angiography and interventions, as it has been associated with numerous serious diseases for the interventional cardiologists; glaucoma, brain tumors and skin cancer.⁹ Fluoroscopy time consists the total amount of time fluoroscopy used and it has been utilized as the simplest indicator for radiation. While FDA considers

fluoroscopy time as a surrogate marker for periprocedural radiation exposure, recent study supports that Dose Area Product (DAP) and Air Kerma are more precise indicators.¹⁰ DAP and Air Kerma are two measurements commonly used to represent the dose patient receives, during such procedures. Generally, DAP provides more a general dose reference and acts as risk scale, while Air Kerma predicts more accurately the radiation dose received by the patient in a particular spot. DAP reflects the sum of fluoroscopy time, and the number of cine exposures during the procedure. Although fluoroscopy time contributes to DAP estimation, they are not affected equally (See Fig. 1).

Recently, Tsigkas and his colleagues concluded that a higher DAP was found in dTRA group, comparing to TRA. The increase was small but statistically significant; absolute difference was 3.82 Gy/cm² in DAP and 0.764 mSv in patients' effective dose. Paradoxically, this trial did not detect any difference in fluoroscopy time between the two arms.^{7,11} The most recent DISCO RADIAL, the largest randomized trial in this topic, did not find any difference regarding radiation dose between the two arms.^{12,13} A numerically but not significantly increase in DAP in dTRA group was also noticed in another randomized trial.⁸ Fluoroscopy time was significantly increased in the dTRA comparing to TRA arm in a non-randomized study by Lu et al.¹⁴ A recent meta-analysis, including four randomized-control trials, supported that fluoroscopy time was elevated in dTRA group in a non-significant way,¹⁵ while another claimed that fluoroscopy time was significantly longer in dTRA arm.^{15,16} However, no difference was observed in DAP.¹⁶

* Corresponding author. Department of Cardiology, University Hospital of Patras, Ippokratous str. 00, 26504, Rion-Patras, Greece.

E-mail addresses: anastasisapostolos@gmail.com (A. Apostolos), gregtsig@hotmail.com (G. Tsigkas).

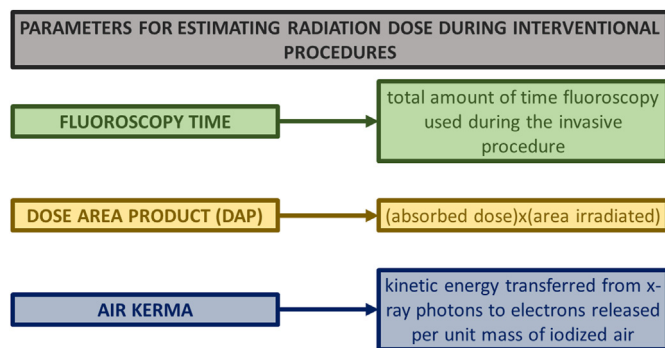


Fig. 1. Parameters for estimating Radiation Dose during Interventional Procedures.

Moreover, studies investigating the role of dTRA in neuro-interventions concluded in similar results. More specifically, Hoffman et al compared retrospectively dTRA versus TRA for performing cerebral angiography. A total of 244 patients were included and TRA was associated significantly with shorter fluoroscopy time and lower radiation dose.³

It is clear that the existing literature cannot unambiguously answer to whether dTRA approach in vascular interventions increase the DAP and fluoroscopy time. It could be hypothesized that the lack of catheter support engagement during maneuvers or the extra distance from the puncture site to the target vessel with dTRA could attribute to this conclusion. These findings require validation from additional clinical trials; the results by the DOSE trial (NCT04023838) may shed the lights on this dilemma, as its primary endpoint is the radiation dose of operator.

In our opinion, dTRA approach could be related with higher fluoroscopy time and radiation exposure, due to the distal catheterization and the more catheters' manipulation. The radiation exposure according to the learning curve of each operator has not been studied yet; nevertheless, we do not believe that the impact of learning curve could affect these parameters.

In conclusion, exposure to radiation after dTRA approach could be a major drawback of this novel technique. Current literature shows a notable trend, but more research is required to conclude whether these limited and preliminary data reflect the reality behind “snuffbox” approach.

Funding sources

None.

Declaration of competing interest

None.

Acknowledgments

None.

References

- Kiemeneij F. Left distal transradial access in the anatomical snuffbox for coronary angiography (ldTRA) and interventions (ldTRI). *EuroIntervention J Eur Collab with Work Gr Interv Cardiol Eur Soc Cardiol*. 2017;13(7):851–857. <https://doi.org/10.4244/EIJ-D-17-00079>.
- Tsigkas G, Mouliaas A, Papageorgiou A, et al. Transradial access through the anatomical snuffbox: results of a feasibility study. *Hellenic J Cardiol*. 2021;62(3): 201–205. <https://doi.org/10.1016/j.hjc.2020.02.002>.
- Hoffman H, Bunch KM, Mikhailova T, et al. Comparison of the safety, efficacy, and procedural characteristics associated with proximal and distal radial access for diagnostic cerebral angiography. *J stroke Cerebrovasc Dis Off J Natl Stroke Assoc*. 2021;31(1), 106204. <https://doi.org/10.1016/j.jstrokecerebrovasdis.2021.106204>.
- Oliveira MDP, Navarro EC, Caixeta A. Distal transradial access for post-CABG coronary and surgical grafts angiography and interventions. *Indian Heart J*. 2021;73(4):440–445. <https://doi.org/10.1016/j.ihj.2021.06.005>.
- Kühn AL, Singh J, Moholkar VM, et al. Distal radial artery (snuffbox) access for carotid artery stenting - technical pearls and procedural set-up. *Interv Neuro-radiol J Peritherapeutic Neuroradiol Surg Proced Relat Neurosci*. 2021;27(2): 241–248. <https://doi.org/10.1177/1591019920959537>.
- Eid-Lidt G, Rivera Rodríguez A, Jimenez Castellanos J, Farjat Pasos JI, Estrada López KE, Gaspar J. Distal radial artery approach to prevent radial artery occlusion trial. *JACC Cardiovasc Interv*. 2021;14(4):378–385. <https://doi.org/10.1016/j.jcin.2020.10.013>.
- Tsigkas G, Papageorgiou A, Mouliaas A, et al. Distal or traditional transradial access site for coronary procedures: a single-center, randomized study. *JACC Cardiovasc Interv*. December 2021;15(1):22–32. <https://doi.org/10.1016/j.jcin.2021.09.037>.
- Koutouzis M, Kontopodis E, Tassopoulos A, et al. Distal versus traditional radial approach for coronary angiography. *Cardiovasc Revascularization Med*. 2019;20(8):678–680. <https://doi.org/10.1016/j.carrev.2018.09.018>.
- Eagan JTJ, Jones CT, Roubin GS. Interventional cardiologists: beware and be aware: an updated report of radiation-induced cutaneous cancers. *Catheter Cardiovasc Interv Off J Soc Card Angiogr Interv*. 2018;91(3):475–477. <https://doi.org/10.1002/ccd.27258>.
- Skiprchnik E, Loh SA. Fluoroscopy time is not accurate as a surrogate for radiation exposure. *Vascular*. 2017;25(5):466–471. <https://doi.org/10.1177/1708538117698342>.
- Tsigkas G, Papageorgiou A, Mouliaas A, Apostolos A, Kalogeropoulos AP, Davlourous P. Reply: distal transradial access for primary PCI in ST-segment elevation myocardial infarction. *JACC Cardiovasc Interv*. 2022;15(7):795–796. <https://doi.org/10.1016/j.jcin.2022.02.039>.
- Aminian A, Sgueglia GA, Wiemer M, et al. Distal versus conventional radial access for coronary angiography and intervention (DISCO RADIAL). *JACC Cardiovasc Interv*. May 2022;22(S1936-8798). <https://doi.org/10.1016/j.jcin.2022.04.032>, 00897–4.
- Tsigkas G, Apostolos A, Davlourous P. Less is more, but not always; distal transradial access for radial artery occlusion prevention. *JACC Cardiovasc Interv*. May 2022;S1936-8798(22). <https://doi.org/10.1016/j.jcin.2022.05.001>, 00916–5.
- Lu H, Wu D, Chen X. Comparison of distal transradial access in anatomic snuffbox versus transradial access for coronary angiography. *Heart Surg Forum*. 2020;23(4):E407–E410. <https://doi.org/10.1532/hsf.3041>.
- Mhanna M, Beran A, Nazir S, et al. Outcomes of distal versus conventional transradial access for coronary angiography and intervention: an updated systematic review and meta-analysis. *Int J Cardiol*. October 2021;344:47–53. <https://doi.org/10.1016/j.ijcard.2021.10.003>.
- Liang C, Han Q, Jia Y, Fan C, Qin G. Distal transradial access in anatomical snuffbox for coronary angiography and intervention: an updated meta-analysis. *J Intervent Cardiol*. 2021;2021, 7099044. <https://doi.org/10.1155/2021/7099044>.