

Received: 2019.07.21
Accepted: 2019.10.29
Available online: 2020.01.24
Published: 2020.02.05

Abdominal Tuberculosis Mimicking Cancer Clinically and on Fluorodeoxyglucose (FDG)-Positron Emission Tomography (PET) Imaging: A Two-Case Series

Authors' Contribution:
Study Design A
Data Collection B
Statistical Analysis C
Data Interpretation D
Manuscript Preparation E
Literature Search F
Funds Collection G

BEF 1,2 **Chiara Di Renzo**
E 1 **Parissa Tabrizian**
BEF 1 **David E. Kozuch**
D 3 **Maria Isabel Fiel**
ACE 1 **Myron E. Schwartz**

1 Liver Surgery at Recanati/Miller Transplantation Institute, Icahn School of Medicine at Mount Sinai, New York City, NY, U.S.A.
2 Hepatobiliary and Liver Transplant Unit, Padova University Hospital, Padova, Italy
3 Department of Pathology, Icahn School of Medicine at Mount Sinai, New York City, NY, U.S.A.

Corresponding Author: Chiara Di Renzo, e-mail: chiara.di-renzo@hotmail.com
Conflict of interest: None declared

Case series

Patients: Male, 76-year-old • Male, 53-year-old
Final Diagnosis: Disseminate tuberculosis and liver tuberculoma
Symptoms: Fatigue
Medication: —
Clinical Procedure: —
Specialty: Surgery

Objective: Unknown etiology


Background: Miliary tuberculosis (MT) is the disseminated form of tuberculosis (TB) and it is a potentially fatal condition. Diagnosis is often delayed because symptoms are typically nonspecific or absent, and misdiagnosis in favor of other diseases is common. We report 2 cases of disseminated TB that were diagnosed during or after surgeries performed for other suspected diseases.

Case Report: Imaging findings are not specific and cannot be relied upon to raise suspicion of MT. In the first case, besides other imaging techniques, we also performed a positron emission tomography-computed tomography (PET-CT) on the patient and the resulting, thick, fluorodeoxyglucose (FDG)-avid ring surrounding the liver first led to concern for peritoneal carcinomatosis. TB peritonitis was only identified on laparoscopy and biopsy. In the second case, CT and magnetic resonance imaging (MRI) findings of a solitary liver mass with an irregular enhancing rim and progressive enhancement led to a radiographic diagnosis of likely intrahepatic cholangiocarcinoma. The subsequent finding that the lesion was intensely FDG-avid without other foci of FDG uptake led to the decision to proceed with resection without a prior biopsy.

Conclusions: We have presented 2 patients with TB in whom clinical and imaging findings, and in particular, FDG-PET imaging, led to an erroneous clinical diagnosis of malignancy. An awareness that TB remains very much an active clinical problem in North America and that there are other reasons for FDG uptake on PET imaging besides cancer, is necessary in order to avoid unnecessary and potentially deleterious interventions in patients with TB.

MeSH Keywords: Fluorodeoxyglucose F18 • *Mycobacterium Tuberculosis* • Tuberculosis, Gastrointestinal • Tuberculosis, Hepatic

Full-text PDF: <https://www.amjcaserep.com/abstract/index/idArt/918901>



1591



1



5



15



Background

Miliary tuberculosis (MT) is the disseminated form of tuberculosis (TB) that can involve several organs via lymphohematogenous spread of acid-fast bacilli (AFB) from the primary infectious focus [1]. It is a potentially fatal condition and most cases in the literature, especially in the past, were diagnosed at autopsy. This condition is more common in immunocompromised patients. Diagnosis is often delayed because symptoms are typically nonspecific or absent, and misdiagnosis in favor of other diseases is common. We report 2 cases of disseminated TB that were diagnosed during or after surgeries performed for other suspected diseases. The first is a case of peritoneal TB mimicking carcinomatosis in a patient with myeloma, and the second is a case of a liver tuberculoma with radiographic features suggesting cholangiocarcinoma.

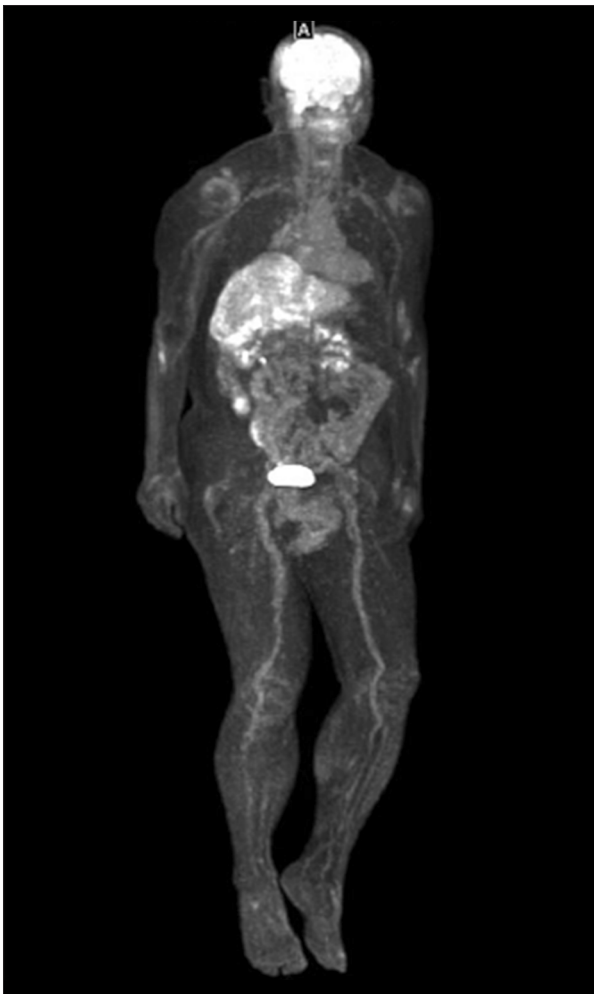


Figure 1. Positron emission tomography-computed tomography (PET/CT) scan (coronal section): the examination was performed for routine follow-up. No abnormal fluorodeoxyglucose (FDG) uptake in osseous structures is noted.

Case Reports

Case #1

A 76-year-old Japanese male with multiple myeloma first diagnosed in July 2017 was in clinical remission after treatment with venetoclax, ixazomib, and nelfinavir with no M-spike on serum protein electrophoresis and a normal bone marrow examination. There was no history of liver disease and liver function tests were within the normal range except gamma-glutamyl transferase (GGT), which was elevated at 162 U/L. Comorbidities included hypertension, hypothyroidism, benign prostatic hyperplasia, and diabetes mellitus. A chest x-ray has not been performed because the patient had a previous whole-body magnetic resonance imaging (MRI) done for its multiple myeloma follow-up, that did not reveal any abnormality in the chest. A radiotracer fluorodeoxyglucose (FDG) positron emission tomography-computed tomography (PET/CT) scan was done as part of routine follow-up. There was no abnormal FDG uptake in osseous structures to suggest active myeloma, but uptake was noted surrounding the liver without clear CT correlation (Figures 1, 2).

Diagnostic laparoscopy was undertaken and revealed diffuse white, nodular lesions covering the peritoneum and the omentum with thickened omental attachments to the abdominal wall, suspicious for peritoneal carcinomatosis (Figures 3, 4).

Biopsies of the peritoneum and omentum were sent for frozen section which showed caseating granulomas, and no malignant cells. Final pathology confirmed the diagnosis of tuberculosis; a single acid-fast bacillus was identified on Ziehl-Neelsen stain (Figure 5). Other tests like molecular biology and polymerase

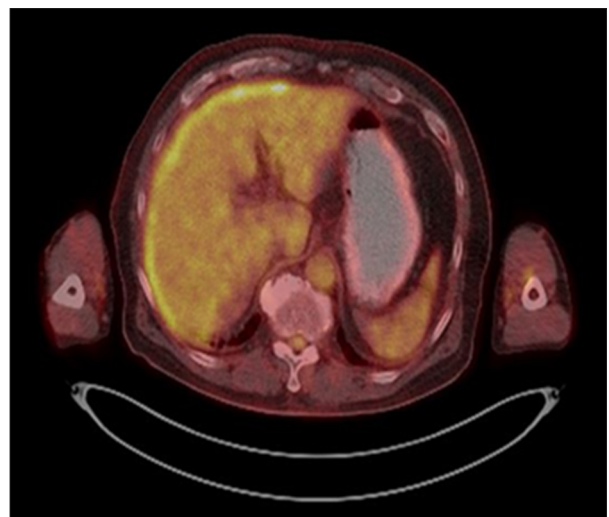


Figure 2. Positron emission tomography-computed tomography (PET/CT) scan (transversal section): uptake was noted surrounding the liver without clinical correlation.

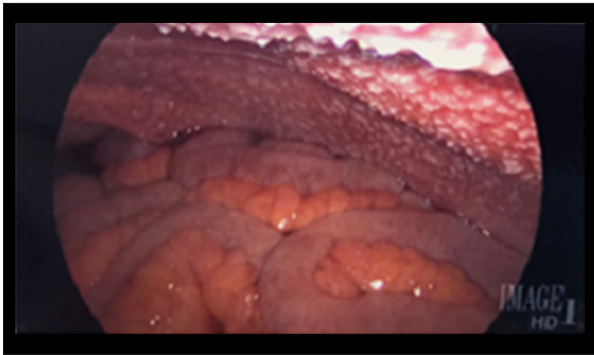


Figure 3. Laparoscopic image: intraoperative evidence showing nodules in the median and right parietal peritoneum.

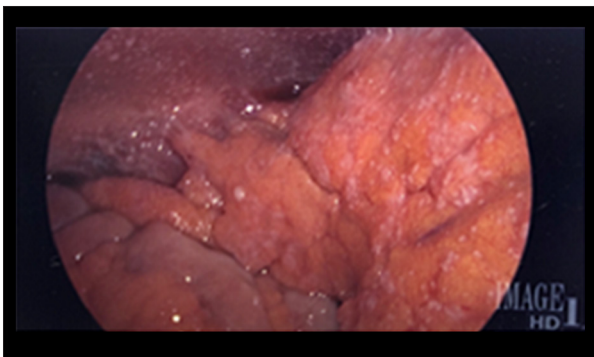


Figure 4. Laparoscopic image (second view): laparoscopic abdominal exploration showing omental nodules and inflammatory adhesions in the right hypocondrium.

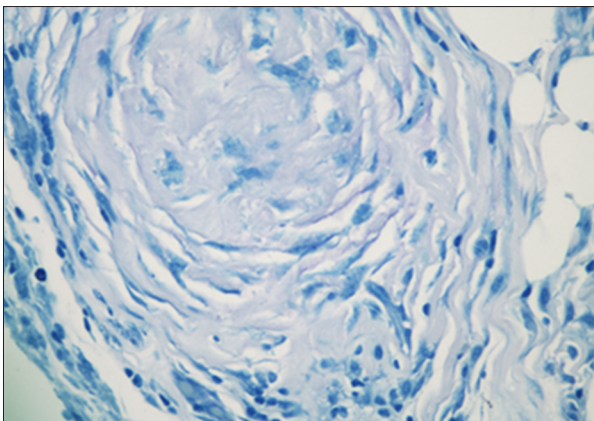


Figure 5. Surgical specimen: surgical specimen showing necrotizing epithelioid granulomas with single acid-fast bacillus on Ziehl-Neelsen stain.

chain reaction (PCR) have not been performed since not necessary for the diagnosis.

Case #2

A 53-year-old male from Bangladesh with past medical history of hypertension, hyperlipidemia, diabetes, and a 2-month

history of right upper quadrant abdominal pain radiating to his back, not related to meals, decreased appetite, and 6.8 kg (15 lbs) weight loss. He presented to the emergency department after 2 days of vomiting. His surgical history included prior laparoscopic cholecystectomy and subsequent umbilical hernia repair with MESH. CT Scan of the abdomen and pelvis done at admission showed a large hypoattenuating mass measuring approximately 6.1×8.7×7.4 cm within the right hepatic lobe (segment 5/6) and multiple prominent retroperitoneal, pericaval, and periportal lymph nodes. In the lower chest, multiple abnormal cardiophrenic lymph nodes were noted. Further evaluation by MRI abdomen with contrast was performed with evidence of a large liver lesion in segment 6, in the setting of cirrhosis. The lesion was isointense to liver parenchyma on most sequences with early hyperemia of the surrounding liver on the immediate postcontrast sequences and with gradual central reticular enhancement, though less so than the surrounding liver. There appeared to be extracapsular extension of the mass which seemed to invade the right posterolateral peritoneal reflection. These findings favored a diagnosis of cholangiocarcinoma. A whole-body PET/CT demonstrated the right hepatic lobe mass to be FDG-avid; the standardized uptake value (SUV) in the enlarged lymph nodes was similar to background. Liver function was normal, hepatitis B and C serologies were negative, and a recent colonoscopy showed no malignancy. AFP (alpha-fetoprotein) was <2. The chest x-ray was normal. After multidisciplinary discussion, the patient underwent a right hepatectomy, hilar lymph node dissection and right diaphragm resection with primary repair. Pathology demonstrated granulomas with caseous necrosis consistent with TB; Ziehl-Neelsen stain failed to demonstrate acid-fast bacilli. Lymph nodes were reported as hyperplastic.

Discussion

Miliary tuberculosis (MT) is a disseminated form of TB due to the lympho-hematogenous spread of *Mycobacterium tuberculosis* from the primary site of infection. MT is present in about 2% of active tuberculosis cases in immunocompetent adults, but its prevalence can range from 16% up to 78% in case series of patients with concurrent hematological malignancies [2,3].

With regard to liver tuberculomas, as in the second case, approximately 80% of all reported hepatic TB cases are due to systemic dissemination of AFB [4,5]. Isolated liver involvement is an extremely rare entity, occurring in <1% of TB patients with <100 cases reported in the literature [4,6]. Isolated hepatic TB results either from tubercle bacilli gaining access to the portal vein from a focus in the bowel, or by contiguous spread from hilar lymph nodes [4,6]. Recognized risk factors for MT are all immunocompromising diseases such as acquired immunodeficiency syndrome (AIDS) (in the terminal stages of

Table 1. Literature review: Cases of difficult differential diagnoses between disseminated TB and other conditions reported in the literature*.

Article type, pub date	Authors	Age (years)/ sex	Symptoms and signs	Site	History of TB	Chest x-ray	Performed exam	Suspected disease	Diagnostic procedure
Case Report, 2017	Jain et al. [14]	50/Male	Weight loss and appetite, jaundice	Liver	No	Normal	US, CT	Cholangiocarcinoma	Intraoperatively (left hepatectomy)
Case Report, 2010	Tian et al. [12]	50/Male	Left abdominal pain and weight loss	Pancreas and spleen	No	–	US, FDG PET/CT	TB	Laparoscopic biopsy
Case Report, 2010	Tian et al. [12]	61/Female	Right abdominal pain and weight loss	Hepatic hilar region, vertebrae, paraaortic nodes	No	–	US, CT, FDG-PET/CT	Malignancy with multiple metastases	Laparoscopic biopsy
Case Report, 2010	Tian et al. [12]	37/Male	Abdominal pain, weight loss and malaise	Hepatic hilar region, pancreatic head, retroperitoneum	No	–	US, CT, FDG-PET/CT	TB (Authors suspected TB thanks to the previous 2 cases described in their paper)	Mantoux test
Review, 2014	Chaudhary [13]	–	–	Gallbladder	No	–	–	Calculous cholecystitis	Surgery (pathologic exam)
Review, 2014	Chaudhary [13]	–	–	Liver	No	–	–	Hydatid cyst or pyogenic abscess	Surgery (pathologic exam)
Case Report, 2017	Kandasamy et al. [5]	50/Female	Abdominal pain, low grade fever and weight loss	Liver	No	Normal	US, CT, MRI/MRCP	Liver metastases, abscesses, cholangiocarcinoma	USG-guided biopsy

* In Most of these cases the diagnosis of disseminated tb was obtained during procedures/surgeries performed for other suspected diseases. TB – tuberculosis; US – ultrasound; CT – computed tomography; FDG – fluorodeoxyglucose; PET/CT – positron emission tomography-computed tomography; MRI – magnetic resonance imaging; MRCP – magnetic resonance cholangiopancreatography.

human immunodeficiency virus [HIV] infection, almost 50% of all cases of TB are miliary) [1,7], diabetes mellitus, organ transplant, prolonged therapy with corticosteroids, immunosuppressive, cytotoxic and immunomodulator drugs, hematologic malignancies, and carcinoma of the head and neck [8]. Its pathophysiology is thought to be related to an inefficient containment of AFB by effector T-cells as a result of suppression by regulatory T-cells at the pathologic site.

MT can develop as a result of progression of a primary infection (progressive primary TB) or, more often, the reactivation of latent disease due to precipitating factors.

Clear clinical manifestations are often not present and liver function is generally preserved, with mild increase in liver enzymes but rare evidence of hyperbilirubinemia. Jaundice, ascites, and hepatomegaly (in adults) are also rare [9,10] except among foreign-born individuals from high-risk countries [1]. Because of the rarity of this disease, the nonspecific symptoms, and relatively normal laboratory findings, the diagnosis of TB was not suspected in either case.

As demonstrated in the 2 cases presented, imaging findings are not specific and cannot be relied upon to raise suspicion of MT. In the first case, the thick, FDG-avid ring surrounding the

liver first led to concern for peritoneal carcinomatosis. Such findings are most commonly seen in women with peritoneal dissemination of ovarian cancer, but may be seen in other abdominal malignancies, most notably colorectal carcinoma. Similar to previously reported cases, TB peritonitis was not recognized in our case based on imaging and was only identified on laparoscopy and biopsy. A recent cohort study that compared PET/CT findings in TB peritonitis and peritoneal carcinomatosis showed similar FDG uptake for the 2 entities, with no significant difference in SUV max. The distribution of disease was more relevant: carcinomatosis tended to be completely or primarily localized in the pelvic and/or right subdiaphragmatic regions (78.4% sensitivity, 72.0% specificity), while peritoneal TB tended to have a more diffuse and uniform distribution (72.0% sensitivity and 94.1% specificity). In our case, however, the findings of TB were quite well-localized in the right upper quadrant [11,12].

In the second case, CT and MRI findings of a solitary liver mass with an irregular enhancing rim and progressive enhancement led to a radiographic diagnosis of likely intrahepatic cholangiocarcinoma. The subsequent finding that the lesion was intensely FDG-avid without other foci of FDG uptake led to the decision to proceed with resection without a prior biopsy. The typical appearance of a liver tuberculoma on CT and MRI is as a nonenhancing lesion with central low density related to caseation necrosis, and with an enhancing peripheral rim corresponding to surrounding granulation tissue.

Staining for acid-fast bacilli is commonly negative, as in our case; evidence of caseating granulomata in the appropriate clinical setting is generally considered sufficient to establish the diagnosis [13,14].

By presenting our cases, we want to highlight that even PET/CT is not specific for TB (in the first case the pattern of FDG uptake is not typical for disseminated TB, while in the second case the imaging is totally compatible with liver cancer (that is what we actually suspected and the reason why

we performed a liver surgery). In this scenario we want to remind the medical community the increasing prevalence of TB in the rich-western countries. Furthermore, even if PET/CT is an irreplaceable diagnostic tool for TB, clinical suspicion is needed to correctly interpret it.

We summarized in the Table 1 all the cases similar to ours that we found in the literature. It is evident that there are few published cases and that diagnostic difficulties can be present. Considering the possibility of disseminated TB is the only way to fasten the diagnostic process or to point directly to the correct diagnosis in order to lower patients' morbidity and mortality.

Conclusions

We have presented the cases of 2 patients with TB in whom clinical and imaging findings, and in particular, FDG-PET imaging, led to an erroneous clinical diagnosis of malignancy, in one case leading to diagnostic laparoscopy and in the other to hepatic resection. The first patient was in clinical remission from myeloma, but nonetheless should have been considered to some extent immunocompromised; the second case was an immigrant from Bangladesh, where TB is the leading cause of death [15]. An awareness that TB remains very much an active clinical problem in North America, and it is important to consider that there are other reasons for FDG uptake on PET imaging besides cancer, in order to avoid unnecessary and potentially deleterious interventions in patients with TB.

Department and institution in which the work was done

Liver Surgery at Recanati/Miller Transplantation Institute, Icahn School of Medicine at Mount Sinai, New York City, NY, U.S.A.

Conflict of interest

None.

References:

1. Sharma SK, Mohan A, Sharma A: Challenges in the diagnosis & treatment of military tuberculosis. *Indian J Med Res*, 2012; 135: 703–30
2. Sia IG, Wieland ML: Current concepts in the management of tuberculosis. *Mayo Clin Proc*, 2011; 86: 348–61
3. Sharma SK, Mohan A: Military tuberculosis. *Microbiol Spectr*, 2017; 5(2)
4. Hickey AJ, Gounder L, Moosa MY: A systematic review of hepatic tuberculosis with considerations in human immunodeficiency virus co-infection. *BMC Infect Dis*, 2015; 15: 209
5. Kandasamy S, Govindarajalou R, Chakkalakkoombil SV, Penumadu P: Isolated hepatobiliary tuberculosis: a diagnostic challenge. *BMJ Case Rep*, 2018; 2018: pii: bcr-2017-223912
6. Karaosmanoglu AD, Onur MR, Sahani DV: Hepatobiliary tuberculosis: Imaging findings. *Am J Roentgenol*, 2016; 207: 694–704
7. Sharma SK, Mohan A, Kadiravan T: HIV-TB co-infection: Epidemiology, diagnosis & management. *Indian J Med Res*, 2005; 121: 550–67
8. Cheng MP, Abou Chakra CN, Yansouni CP: Risk of active tuberculosis in patients with cancer: A systematic review and meta-analysis. *Clin Infect Dis*, 2017; 64(5): 635–44
9. Essop AR: Tuberculous hepatitis: A clinical review of 96 cases. *QJ Med*, 1984; 212: 465–77
10. Munt PW: Military tuberculosis in the chemotherapy era: With a clinical review in 69 American adults. *Medicine*, 1971; 51: 139–55
11. Wang SB, Ji YH, Wu HB: PET/CT for differentiating between tuberculous peritonitis and peritoneal carcinomatosis. *Medicine*, 2017; 96: 2
12. Tian G, Xiao Y, Chen B: Multi-site abdominal tuberculosis mimics malignancy on 18F-FDG PET/CT: Report of three cases. *World J Gastroenterol*, 2010; 16(33): 4237–42

13. Chaudhary P: Hepatobiliary tuberculosis. *Ann Gastroenterol*, 2014; 27: 207–11
14. Jain A, Chaturvedi R, Kantharia C: Secondary sclerosing cholangitis in localized hepatobiliary tuberculosis simulating cholangiocarcinoma: A rare case report. *BMC Gastroenterol*, 2017; 17: 126
15. World Health Organization Bangladesh (Country Office for Bangladesh). World TB DAY 2016: Bangladesh continues its battle against the disease. Available from: url: <http://www.searo.who.int/bangladesh/world-tb-day-2016/en>