

## Superior Vena Cava Clamping during Thoracic Surgery: Implications for the Anesthesiologist

### Abstract

Resection and reconstruction of the SVC is a challenging Intraoperative situation owing to the potential complications after clamping a patent vessel. Hemodynamic imbalance and neurological effects of SVC clamping can be life threatening. These complications can be prevented by careful intraoperative monitoring and management. Anaesthesiologist must be aware of different options to manage such challenging situations.

**Keywords:** Neuroprotective, superior vena cava, thoracic surgery

### Introduction

Mediastinal mass (benign and malignant) can involve superior vena cava (SVC) mandating its surgery also. Complication of SVC injury caused by thoracic trauma or some diagnostic and therapeutic procedures such as mediastinoscopy may also lead to need for surgery on SVC. Patients with long-term central venous catheters or permanent pacing electrodes may develop stenosis and obstruction of the SVC requiring its repair.<sup>[1]</sup> Such patients needing SVC reconstruction may have the presence or absence of SVC syndrome. Significant SVC compression along with collateral vein networks formation is indicated by clinical findings such as swelling of the head, neck and upper limbs, profound dilated veins over the upper half of the body, and cyanosis. However, the absence of these features of chronic SVC compression suggests lack of adequate collateral venous networks. This also means venous return from the head will be severely hindered when SVC is clamped acutely.<sup>[1]</sup> It is difficult to manage the hemodynamic consequences of sudden clamping of SVC. Unanticipated clinical situation may land up patient in poor postoperative outcomes.

### Case Report

A 45-year-old male patient presented with shortness of breath on mild exertion since 1 month. His chest X-ray - posterioranterior view [Figure 1] and computed tomography

scan revealed large soft tissue density mass lesion (12.5 cm × 12 cm) with areas of necrosis and internal calcification in the right side of mediastinum [Figure 2]. The mass was impinging on right atrium and SVC. There was absence of left SVC. Histopathological examination of the mass was suggestive of malignant leiomyosarcoma. The patient was scheduled for surgical removal of tumor. After smooth anesthesia induction, the patient was intubated with left-sided double-lumen tube considering the need for split-lung ventilation. Femoral venous sheath 6 Fr. was inserted for fluid resuscitation. Intraoperative transesophageal echocardiography examination revealed mass around right atrium and SVC [Figures 3 and 4]. After midline sternotomy, anterior mediastinal mass was resected. Considering the malignant potential of the tumor, it was decided to remove the encased portion of SVC during the surgery. Preparations for cardiopulmonary bypass institution were kept in standby. SVC was clamped and transected proximal to mass, and prosthetic graft (polytetrafluoroethylene PTFE-Gore-Tex 18 mm) was anastomized after adequate heparinization. Nasopharyngeal temperature was maintained at 34°C with the help of cooling blanket and cooling ambient operating room temperature. Intravenous thiopentone 1 g was given. Total SVC clamping time was 55 min. Low-dose vasopressor-noradrenaline 0.03 µg/kg/min was started

**Monish S Raut,  
Swetanka Das<sup>1</sup>,  
Rohitash Sharma,  
Elvin Daniel,  
Amit Motihar,  
Arvind Verma<sup>1</sup>,  
Sibashankar Kar<sup>1</sup>,  
Arun Maheshwari,  
Ganesh Shivnani<sup>1</sup>,  
Arvind Kumar<sup>2</sup>**

*Departments of Cardiac Anesthesiology, <sup>1</sup>Cardiac Surgery and <sup>2</sup>Thoracic Surgery, Sir Ganga Ram Hospital, New Delhi, India*

### Address for correspondence:

*Dr. Monish S Raut,  
Department of Cardiac Anesthesiology, Sir Ganga Ram Hospital, New Delhi, India.  
E-mail: drmonishraut@gmail.com*

### Access this article online

Website: [www.annals.in](http://www.annals.in)

DOI: 10.4103/aca.ACA\_125\_17

### Quick Response Code:



**How to cite this article:** Raut MS, Das S, Sharma R, Daniel E, Motihar A, Verma A, *et al.* Superior vena cava clamping during thoracic surgery: Implications for the anesthesiologist. *Ann Card Anaesth* 2018;21:85-7.

This is an open access article distributed under the terms of the Creative Commons Attribution-NonCommercial-ShareAlike 3.0 License, which allows others to remix, tweak, and build upon the work non-commercially, as long as the author is credited and the new creations are licensed under the identical terms.

For reprints contact: [reprints@medknow.com](mailto:reprints@medknow.com)

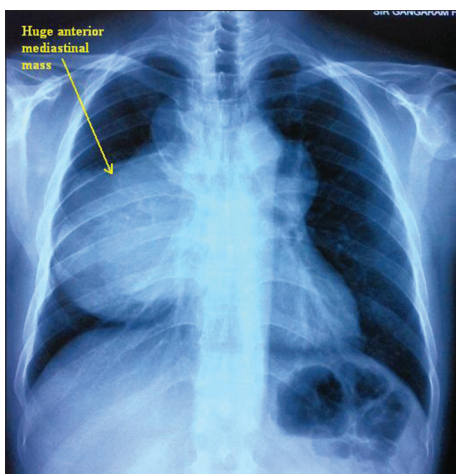


Figure 1: Chest X-ray showing anterior mediastinal mass

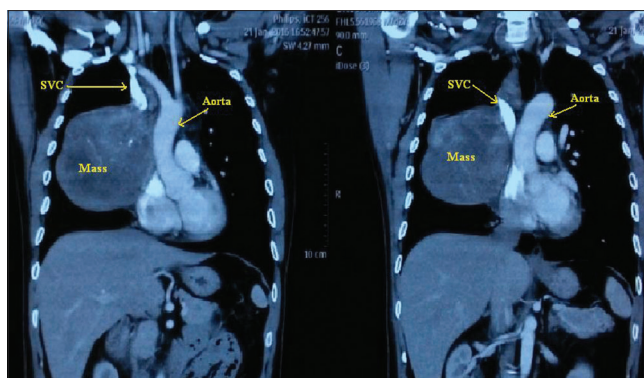


Figure 2: Computed tomography showing mediastinal mass encasing superior vena cava

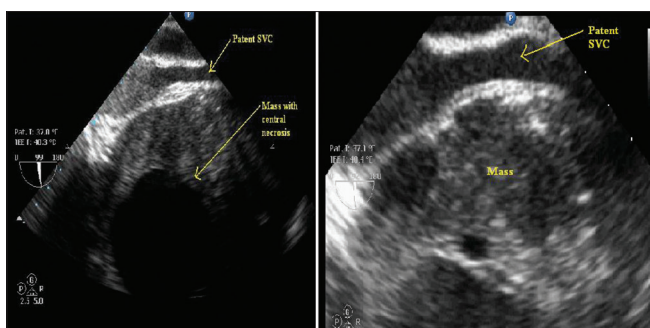


Figure 3: Transesophageal echocardiography image with bicaval view (zoom view-right panel) showing mediastinal mass lateral to superior vena cava but without any infiltration or compression

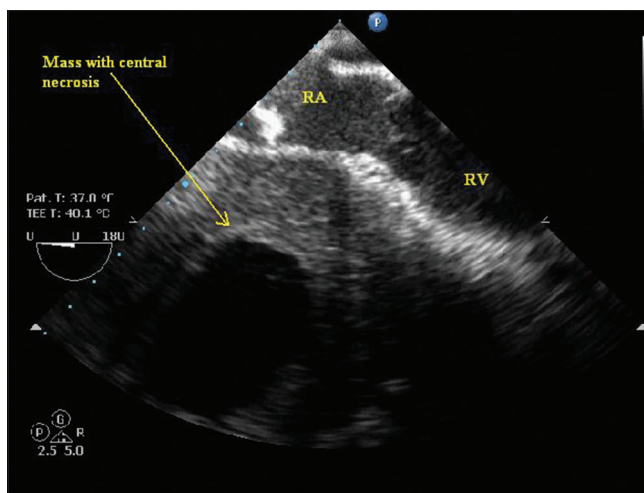


Figure 4: Transesophageal echocardiography image showing mediastinal mass lateral to right atrium and right ventricle

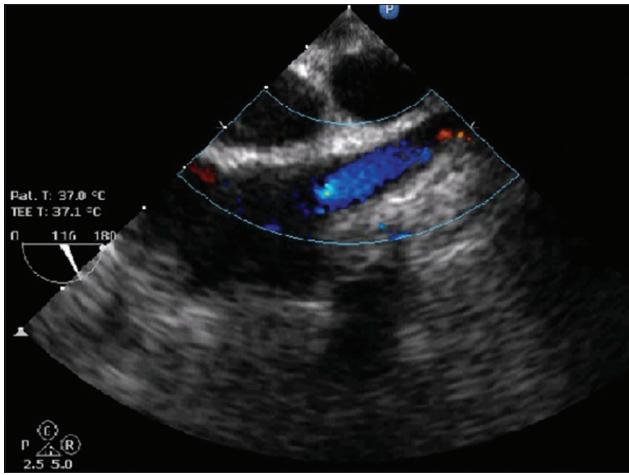
to maintain hemodynamics. Mean arterial pressure was maintained between 80 and 85 mm Hg. After completion of anastomosis, free flow of SVC was verified on transesophageal echocardiographically [Figure 5]. Intraoperatively and postoperatively, the patient was given reverse Trendelenburg position. The patient was extubated after 6 h of surgery. Neurological functions were normal postoperatively.

## Discussion

SVC clamping in conditions such as invasive tumor-like thymoma or lung carcinoma with obstructed SVC would not cause hemodynamic effects due to well-developed venous collaterals.<sup>[2]</sup> In patients with unobstructed SVC, its clamping can cause significant hemodynamic effects due to the absence of alternate venous channels. Venous return from SVC contributes to 50% of cardiac output in children and 35% in adults.<sup>[3]</sup> SVC clamping would cause decreased cardiac output and mean arterial pressure on one side and raised cerebral venous hypertension on other side. Resultant effect is fall in cerebral perfusion pressure with potential to cause irreversible brain damage.<sup>[4]</sup> Experimental studies in animals anesthetized with barbiturates have shown safe duration of SVC to be around 1 h.<sup>[5]</sup> Measures to reduce central venous pressure and cerebral metabolic rate (CMRO<sub>2</sub>)

can effectively allow to increased SVC clamping time.<sup>[4,5]</sup> However, fluid infusion through cannula placed in upper limbs would cause further rise in cerebral venous pressure. Femoral venous or right atrial cannula would be effective in fluid resuscitation. Neuroprotective methods such as use of thiopentone and mild hypothermia can be used. Cerebral oximetry using near-infrared spectroscopy technology should be considered during such surgery.

Use of extracorporeal circulation electively or urgently during the resection of locally advanced thoracic malignancies has been described.<sup>[6]</sup> Cardiopulmonary bypass provides safety net in situations of vascular damage during mass resection. SVC decompression can be done by creating temporary venoatrial shunt or cavopulmonary anastomosis for drainage of the SVC.<sup>[2]</sup> Perentes *et al.* described a new temporary SVC bypass technique - preoperative jugulo-femoral bypass or intraoperative innominate-femoral bypass using standard perfusion tubing. SVC clamping induced jugulofemoral pressure gradient drives blood from jugular to femoral vein without any need of a pumping device or additional heparinization beyond that required for SVC reconstruction.<sup>[7]</sup>



**Figure 5: Transesophageal echocardiography bicaval view showing free flow of superior vena cava with no turbulence on color Doppler after excision of the tumor**

Alternatively, a temporary bypass between right atrium and innominate vein<sup>[8,9]</sup> or axillocephalic,<sup>[10]</sup> axillofemoral,<sup>[11,12]</sup> venovenous bypass using perfusion tubing and cavopulmonary anastomosis<sup>[2]</sup> for SVC decompression, before SVC clamping, has also been reported. Advantages of such system are simplicity, no need of heart–lung machine and full heparinization, low costs, and reduced inflammatory response. However, it would always be imperative to keep preparations for cardiopulmonary bypass intraoperatively in case of hemodynamic instability or significant bleeding, and it would also permit the application of hypothermia.

Hemodynamic imbalance and neurological effects of SVC clamping can be life-threatening. Non-programmed clamping of SVC can be the anesthesiologist's Achilles' heel. Anesthesiologist must be aware of different options to manage such challenging situations.

#### **Declaration of patient consent**

The authors certify that they have obtained all appropriate patient consent forms. In the form the patient(s) has/have given his/her/their consent for his/her/their images and other clinical information to be reported in the journal. The patients understand that their names and initials will not be published and due efforts will be made to conceal their identity, but anonymity cannot be guaranteed.

#### **Financial support and sponsorship**

Nil.

#### **Conflicts of interest**

There are no conflicts of interest.

#### **References**

1. Vretzakis G, Didilis V, Dragoumanis C, Mikroulis D, Lazarides M. Non-programmed clamping of superior vena cava. The anesthesiologist's Achilles' heel. *Acta Anaesthesiol Belg* 2006;57:59-62.
2. Leo F, Della Grazia L, Tullii M, Gasparri R, Borri A, Venturino M, *et al.* Hemodynamic instability during superior vena cava crossclamping: Predictors, management, and clinical consequences. *J Thorac Cardiovasc Surg* 2007;133:1105-6.
3. Mohiaddin RH, Wann SL, Underwood R, Firmin DN, Rees S, Longmore DB. Vena caval flow: assessment with cine MR velocity mapping. *Radiology*. 1990 Nov;177(2):537-41.
4. Gonzalez-Fajardo JA, Garcia-Yuste M, Florez S, Ramos G, Alvarez T, Coca JM. Hemodynamic and cerebral repercussions arising from surgical interruption of the superior vena cava. Experimental model. *J Thorac Cardiovasc Surg* 1994;107:1044-9.
5. Masuda H, Ogata T, Kikuchi K. Physiological changes during temporary occlusion of the superior vena cava in cynomolgus monkeys. *Ann Thorac Surg* 1989;47:890-6.
6. Byrne JG, Leacche M, Agnihotri AK, Paul S, Bueno R, Mathisen DJ, *et al.* The use of cardiopulmonary bypass during resection of locally advanced thoracic malignancies: A 10-year two-center experience. *Chest* 2004;125:1581-6.
7. Perentes JY, Erling CC, Ris HB, Corpataux JM, Magnusson L. A simple bypass technique for superior vena cava reconstruction. *Interact Cardiovasc Thorac Surg* 2011;12:15-9.
8. Chuang HI, Wong KL, Lai KB, Wong KS, Wei TT, Chern FC. Anesthetic considerations in complete obstruction of major veins of upper trunk – report of two cases. *Ma Zui Xue Za Zhi* 1989;27:385-8.
9. Sugiuchi N, Yagi K, Suzuki T, Okano Y, Kikuchi S, Aoki T. Anesthetic management for reconstruction of the superior vena cava by monitoring of peripheral venous pressure in a patient with a mediastinum tumor. *Masui* 2000;49:655-8.
10. Gutowicz MA, Quinones-Baldrich WJ, Lieber CP, Pecora DV. Operative treatment of refractory superior vena cava syndrome. *Am Surg* 1984;50:399-401.
11. Shimokawa S, Yamashita T, Kinjyo T, Iwamura H, Watanabe S, Moriyama Y, *et al.* Extracorporeal venous bypass: A beneficial device in operation for superior vena caval syndrome. *Ann Thorac Surg* 1996;62:1863-4.
12. Shimokawa S, Yamashita T, Kinjyo T, Watanabe S, Yamaoka A, Moriyama Y, *et al.* Temporary extracorporeal axillofemoral venous bypass – A beneficial device in operation for superior vena caval syndrome due to intrathoracic malignancies. *Nihon Kyobu Geka Gakkai Zasshi* 1997;45:1827-32.