

Multidisciplinary Management of an Orbitocranial Penetrating Injury by a Pencil in a Paediatric Patient - A Case Report

Karim Tewfik, Claudia Covelli¹, Manuela Rossini, Caterina Peta, Dante Burlini

Paediatric Head and Neck Department, Paediatric Maxillo-Facial Surgery Unit, ASST Spedali Civili of Brescia, ¹Services Department, Pathology Unit, ASST del Garda, Brescia, Italy

Abstract

Rationale: Orbitocranial penetrating injuries can accidentally occur in children while handling pencils and can cause severe sequelae such as ocular damage, brain lesion, intracranial haemorrhage, and infections. **Patient Concerns:** We report the case of a 7-year-old child with an orbitocranial penetrating injury by a pencil, initially gone undetected, that caused a direct damage to the optic nerve. **Diagnosis:** Computed tomography scan with contrast detected the foreign body and the presence of a lesion of the left internal carotid artery. **Treatment:** Angiography was performed to treat the vascular lesion and to prevent haemorrhage. Subsequently, a craniotomy was performed to assist the extraction of the pencil from the entry wound and to remove residual fragments. **Outcomes:** Left eye vision was lost. The 1-year follow-up was uneventful. **Take-away Lessons:** Operative angiography is mandatory before the surgical extraction of the orbitocranial penetrating injury in case of documented intracranial vessel damage.

Keywords: Angiography, orbitocranial trauma, pencil, penetrating injury

INTRODUCTION

Penetrating orbital and orbitocranial injuries with wooden foreign bodies are relatively rare.^[1] Wooden objects are nonmissile, with an impact velocity of <100 m/s, and damage is usually caused by tissue laceration and maceration.^[2] They more frequently affect children, especially when handling pencils while playing at both school and home.^[1] While common household objects such as scissors and knives are readily identified as dangerous, pencils are an under-recognised source of penetrating injuries^[3] and often regarded as harmless.^[4] Furthermore, in some cases, if the pencil is completely retained, it can go potentially undetected in paediatric patients.^[5] Consequences of an orbitocranial injury from a wooden foreign body can be catastrophic when involving the eye function^[6] and potentially fatal when associated with brain damage, intracranial infection or haemorrhage.^[7] Injuries of intracranial vessels by nonmissile orbitocranial penetrating objects are extremely rare.^[8] Damage to these vital structures can occur as a direct consequence of the foreign body or during the removal of the penetrating object. In case of documented intracranial vessel injury, it is essential to perform a prompt and combined

endovascular and open approach to save the patient's life and reduce possible sequelae.^[9] Therefore, referring complex paediatric orbitocranial penetrating injury to highly specialised paediatric centres for a multidisciplinary management^[10] is crucial. We report the case of a 7-year-old child with an orbitocranial penetrating trauma by a pencil, initially gone undetected, causing a damage to the internal carotid artery (ICA).

CASE REPORT

A 7-year-old girl presented at the primary hospital for a periorbital trauma after an accidental domestic fall, as reported by her father. The clinical evaluation revealed a small wound (<1 cm) in the left inferior eyelid, associated with anisocoria and loss of left eye vision [Figure 1].

Address for correspondence: Mr. Karim Tewfik, Piazzale Dell'Ospedale, 1 25123, Brescia, Italy. E-mail: karim.tewfik@gmail.com

Received: 05-02-2022

Last Revised: 28-03-2022

Accepted: 03-05-2022

Published: 16-08-2022

This is an open access journal, and articles are distributed under the terms of the Creative Commons Attribution-NonCommercial-ShareAlike 4.0 License, which allows others to remix, tweak, and build upon the work non-commercially, as long as appropriate credit is given and the new creations are licensed under the identical terms.

For reprints contact: WKHLRPMedknow_reprints@wolterskluwer.com

How to cite this article: Tewfik K, Covelli C, Rossini M, Peta C, Burlini D. Multidisciplinary management of an orbitocranial penetrating injury by a pencil in a paediatric patient - A case report. *Ann Maxillofac Surg* 2022;12:72-5.

Access this article online

Quick Response Code:



Website:
<https://journals.lww.com/aoms/>

DOI:
10.4103/ams.ams_33_22

The computed tomography (CT) scan revealed the presence of a completely retained pencil crossing the optic canal into the skull base [Figure 2]. The patient confirmed that she fell while

running with a pencil in her hand. No other neurological signs were observed, and vital parameters were stable. The child was referred to our paediatric trauma centre, where a multidisciplinary team composed of paediatric anaesthesiologists, neurosurgeons, maxillofacial surgeons, ophthalmologists, and radiologists performed clinical and radiological evaluations. Since CT scan showed the foreign object in close proximity to the left ICA,

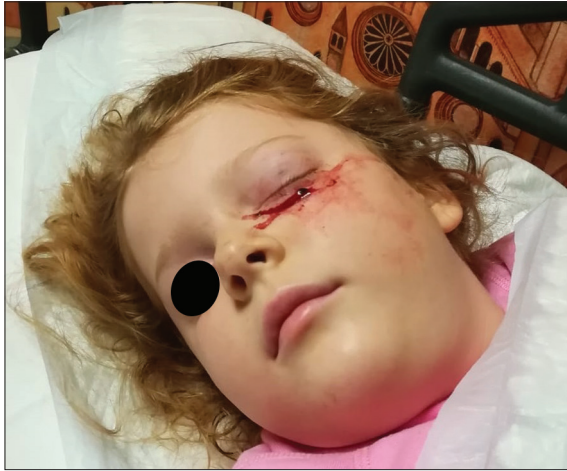

Figure 1: The cutaneous wound on the left inferior eyelid

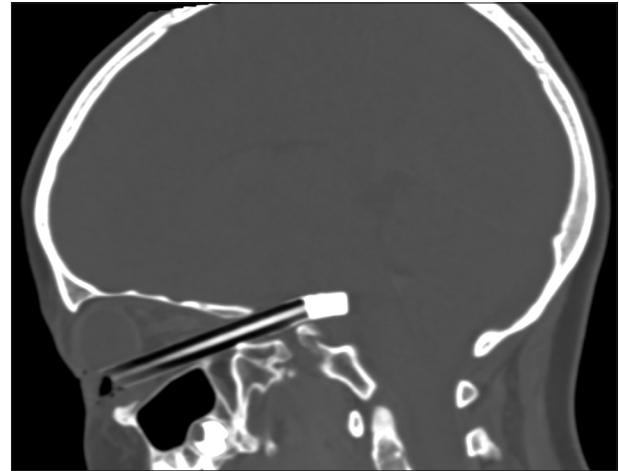


Figure 2: Preoperative CT scan showing the pencil crossing the left orbit toward the brain

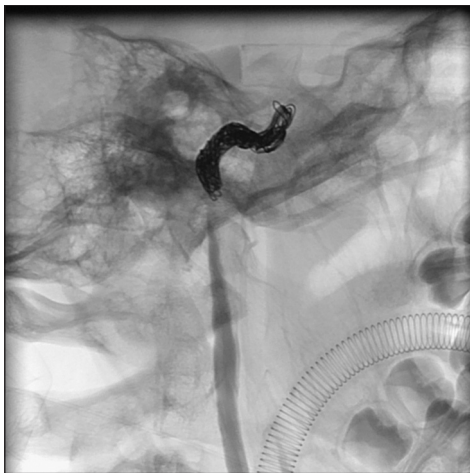

Figure 3: Angiography showing the embolised petrous part of the left ICA



Figure 4: The pencil after removal in theatre

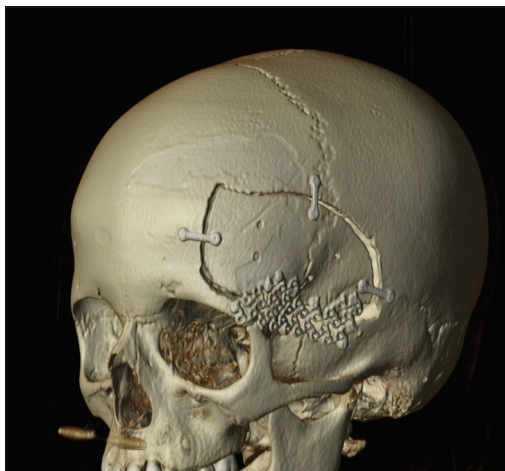

Figure 5: Postoperative CT scan showing left parietal cranioplasty

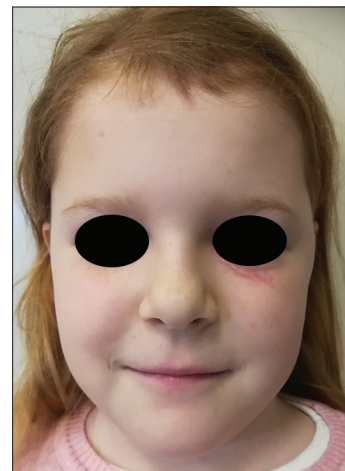

Figure 6: Frontal view of the patient 1 year after surgery

with the suspicion of a vascular damage, an angiography was requested.

After obtaining the parents' consent, the patient was intubated to complete the diagnostic path. A selective angiography confirmed the presence of a lesion at the lacerous part of the intracranial left ICA and also a lesion of the left ophthalmic artery. The petrous part and the cervical segment of the left ICA were unremarkable. Since the cerebral perfusion was supplied by the left anterior and left posterior communicating arteries, the petrous part of the left ICA was embolised to prevent massive bleeding during the surgical extraction of the pencil [Figure 3]. Subsequently, the neurosurgeons started the surgical procedure with a left parietal craniotomy, followed by the dissection of the Sylvian fissure and the isolation of the left ICA and the left posterior communicating artery. A subarachnoid haemorrhage in the cisterna magna was noted and drained. The maxillofacial surgeons proceeded to remove the foreign object through the cutaneous wound in the eyelid [Figure 4]. Finally, the neurosurgeons removed the residual fragments of the pencil and repaired the dural defect. An immediate postoperative CT scan [Figure 5] showed no evidence of bleeding or retained fragments of the foreign body. The patient was transferred to the intensive care unit, where she was extubated the next day, and then moved to the paediatric maxillofacial unit 2 days later. The brain magnetic resonance imaging (MRI) performed 5 days after the operation showed correct embolisation of the lacerous part of the left ICA, with normal brain perfusion, the occluded ophthalmic artery, and a lesion of the optic nerve, with no evidence of infection.

The patient was discharged fit and well 6 days after surgery. Unfortunately, due to the direct damage to the optic nerve and the ophthalmic artery incurred during the accident, she lost her left eye vision.

The 1-year follow-up was uneventful, and the child showed good aesthetic outcomes [Figure 6]. The MRI did not show any complications such as cerebral abscess, meningitis or encephalitis.

DISCUSSION

When dealing with orbitocranial injuries caused by a penetrating foreign body, the correct diagnostic and surgical approach is fundamental to prevent life-threatening consequences.

Foreign objects penetrating the orbit at low velocity can reach the brain as they are directed by the bony anatomy to the orbital roof that represents a fragile wall in close relation to the frontal lobe. Another possible trajectory for an orbitocranial penetrating object is the superior orbital fissure, with possible damage to the cavernous sinus, producing its thrombosis or rarely a carotid-cavernous fistula. The less common access is through the optic canal with possible injuries to the optic nerve, the ophthalmic artery and the ICA,^[8] as occurred in our case. Consequently, imprudent manoeuvres to extract the

foreign body in nonhospital environments can be catastrophic due to the possibility that the object may plug an injured vessel.^[3]

As regards the diagnostic tools, a retained pencil can be easily detected by CT scan^[5] due to the radiopacity of the graphite contained within, and the use of contrast also allows identification of any vascular lesions or bleeding. Some authors suggested the use of MRI^[10] which is superior to CT scan for detecting retained wooden pieces, as CT misses 42% of the nonmetallic foreign bodies. However, MRI is not usually performed in emergencies, especially in case of potential acute bleeding in progress.

If vascular lesions are documented, an angiography should be performed before the surgical extraction of the orbitocranial foreign body to check the integrity of vessels and to control or prevent any bleeding,^[8] as described in the reported case. To the best of our knowledge, an operative angiography has never been reported in the literature in case of orbitocranial wooden foreign body injury in a child. Wu *et al.*^[9] described the use of a diagnostic angiography in a similar case without performing the vascular embolisation; consequently, bleeding could not be prevented, and two consecutive open procedures were required in 14 h for its control. In concordance with other authors,^[8] our case shows that in the event of a transorbital intracranial penetrating object with documented vascular injury, an operative angiography is mandatory to reduce the risk of imminent death or brain damage.

Despite the pencil being extracted intact, the concomitant neurosurgical approach in the current case report was crucial not only to directly check for any possible bleeding but also to eliminate any graphite and wood residues that could have caused short- and long-term infections^[5] and to repair the dural defect. Postoperative complications also include cerebrospinal fluid leak; carotid cavernous fistula; traumatic aneurysm and progressive intravascular thrombosis. Cerebral abscess, meningitis, or encephalitis represent the main long-term complications that can cause death even after several years,^[5] therefore, requiring a long term follow up.

CONCLUSION

Our case highlights the role of angiography in the control of intracranial vascular lesions and the need for a multidisciplinary approach for the correct management of complex orbitocranial penetrating injuries, especially in paediatric patients.

Declaration of patient consent

The authors certify that they have obtained appropriate patient consent form. In the form, the patient's parents have given their consent for images and other clinical information to be reported in the journal. The parents understand that name and initials of the patient will not be published and due efforts will be made to conceal the patient's identity, but anonymity cannot be guaranteed.

Acknowledgments

Dr. Claudio CEREDA, Neurosurgeon involved in the surgical procedure and Dr. Mardighian Dikran, Neuroradiologist who performed the angiography.

Financial support and sponsorship

Nil.

Conflicts of interest

There are no conflicts of interest.

REFERENCES

1. Cho WK, Ko AC, Eatamadi H, Al-Ali A, Abboud JP, Kikkawa DO, *et al.* Orbital and orbitocranial trauma from pencil fragments: Role of timely diagnosis and management. *Am J Ophthalmol* 2017;180:46-54.
2. Borkar SA, Garg K, Garg M, Sharma BS. Transorbital penetrating cerebral injury caused by a wooden stick: Surgical nuances for removal of a foreign body lodged in cavernous sinus. *Childs Nerv Syst* 2014;30:1441-4.
3. Fisher SB, Clifton MS, Bhatia AM. Pencils and pens: An under-recognized source of penetrating injuries in children. *Am Surg* 2011;77:1076-80.
4. Turbin RE, Maxwell DN, Langer PD, Frohman LP, Hubbi B, Wolansky L, *et al.* Patterns of transorbital intracranial injury: A review and comparison of occult and non-occult cases. *Surv Ophthalmol* 2006;51:449-60.
5. Al-Otaibi F, Baeesa S. Occult orbitocranial penetrating pencil injury in a child. *Case Rep Surg* 2012;2012:716791.
6. Tabatabaei SA, Soleimani M, Naderan M, Ahmadraji A, Rajabi MB, Jafari H, *et al.* A survey of incidental ocular trauma by pencil and pen. *Int J Ophthalmol* 2018;11:1668-73.
7. Del Verme J, Giordan E, Marton E, Zanata R, Di Paola F, Canova G, *et al.* Classification of orbitocranial wooden foreign body penetration injuries: What to do when they violate the intracranial space? A systematic review. *J Neurosurg Sci* 2020;64:190-9.
8. Özkan Arat Y, Arat A, Aydın K. Cerebrovascular complications of transorbital penetrating intracranial injuries. *Ulus Travma Acil Cerrahi Derg* 2015;21:271-8.
9. Wu Y, Chen T, Yuan M, Mzimhiri JM, Liu Z, Chen Y, *et al.* Orbitocranial penetrating injury with multiple vessel invasion in an infant: A case report and literature review. *Front Neurol* 2020;11:591431.
10. Wahyudi, Zaky A, Islam AA, Prihantono, Rosyidi RM. An extremely rare case: Transorbital penetrating intracranial injury by wooden foreign body. *Case report. Ann Med Surg (Lond)* 2021;71:102937.