



## *Aspergillus fumigatus* endocarditis in an indigenous Australian male without classic risk factors



Tina Marinelli<sup>a,\*</sup>, Sarah Kidd<sup>b</sup>, David Shaw<sup>a</sup>, Emily Rowe<sup>a</sup>

<sup>a</sup> The Royal Adelaide Hospital, Port Road, Adelaide 5000, Australia

<sup>b</sup> SA Pathology, Frome Road, Adelaide 5000, Australia

### ARTICLE INFO

#### Keywords:

Aspergillus  
Endocarditis  
Voriconazole  
Indigenous  
Immunosuppression

### ABSTRACT

*Aspergillus* endocarditis is rare with most cases occurring in immunosuppressed patients. We present the case of an “immunocompetent” Indigenous Australian male with culture confirmed *Aspergillus* brain abscesses complicating bilateral endocarditis. The reported mortality rate for *Aspergillus* endocarditis approaches 100%. Despite sub-optimal therapy this patient survived beyond expectation.

### 1. Introduction

*Aspergillus* species are ubiquitous fungal saprophytes that are abundant in soil and vegetative material. Fungal endocarditis accounts for less than 2% of all cases of endocarditis [1]. *Aspergillus* endocarditis is a rare entity [2] accounting for approximately one quarter of fungal endocarditis cases [3] with *Aspergillus fumigatus* being the most common causative subspecies [4].

In most cases of *Aspergillus* endocarditis a predisposing condition is readily identifiable [4]. Optimal therapy is unknown. Combination therapy with voriconazole plus prompt surgical intervention is recommended [3,7,8,11]. Survival rates without surgery have been reported as low as 4% [10] and can approach 100% [11]. We report a case of an Indigenous Australian male without classic risk factors for *Aspergillus* endocarditis, who survived beyond 12 months despite sub-optimal therapy.

### 2. Case

39-year-old urban-dwelling Indigenous man presented to an Australian tertiary hospital on day 0 following a fall with head-strike. He had a history of heavy alcohol consumption and was intoxicated at the time of fall. At presentation, he was confused with slurred speech and ataxia. Investigations demonstrated a white blood cell count of 29.4 (4.00–11.00 × 10<sup>9</sup>/L) and mildly deranged cholestatic liver function tests. Computed tomography (CT) brain on day 0 revealed numerous peripherally enhancing hypodense lesions in the supra and infratentorial areas with obstructive hydrocephalus. Subsequent magnetic

resonance imaging (MRI) brain on day + 2 demonstrated the lesions to have restricted diffusion centrally and surrounding vasogenic edema consistent with cerebral abscesses (Fig. 1).

His past medical history was significant for pulmonary nocardiosis, diagnosed five months prior to presentation on day – 194. At that time, a CT chest demonstrated several areas of round mass-like areas of dense consolidation with perihilar cavitation and early paraseptal, apical emphysematous changes. The radiographic evidence of chronic obstructive pulmonary disease was attributed to his cigarette smoking. *Nocardia transvalensis* was isolated from sputum, as was *Aspergillus fumigatus* (*A. fumigatus*). In this context, the *A. fumigatus* was considered a colonizing organism. Transthoracic echocardiography (TTE) did not reveal any significant valvular pathology. He was treated with intravenous ceftriaxone for 38 days when he was changed to oral trimethoprim/sulphamethoxazole. Oral antibiotics were ceased by the patient several weeks prior to representation at day 0.

At the current admission, tests for immunodeficiency including human immunodeficiency virus were negative. There was no clinical history suggestive of an inherited immune deficiency, diabetes mellitus or malignancy. There was no known history intravenous drug use. Stealth-guided decompression of the posterior cranial fossa contents was undertaken for diagnostic purposes on day + 3 and *A. fumigatus* was isolated on culture, with no growth of *Nocardia* sp. or other bacteria. Diagnosis was made on the basis on morphologic characteristics of culture isolates alone without requiring the use of molecular methods. Supporting blood-based diagnostic tests including galactomannan, [1–3]-β-D-glucan and panfungal polymerase chain reaction (PCR) were not requested. Antifungal susceptibility testing was performed using the

\* Corresponding author.

E-mail address: [tina.marinelli@gmail.com](mailto:tina.marinelli@gmail.com) (T. Marinelli).

<https://doi.org/10.1016/j.mmcr.2018.09.005>

Received 20 August 2018; Received in revised form 17 September 2018; Accepted 20 September 2018

Available online 21 September 2018

2211-7539/© 2018 The Authors. Published by Elsevier B.V. on behalf of International Society for Human and Animal Mycology. This is an open access article under the CC BY-NC-ND license (<http://creativecommons.org/licenses/by-nc-nd/4.0/>).

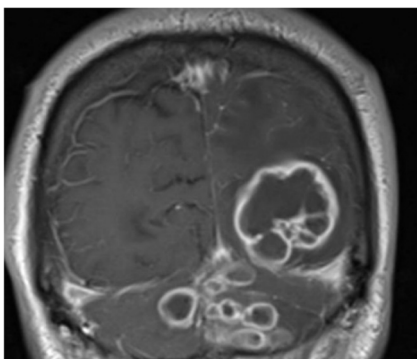


Fig. 1. MRI Brain demonstrating numerous lesions with restricted diffusion centrally and surrounding vasogenic edema.

Table 1  
*Aspergillus fumigatus* antifungal susceptibility testing.

Antifungal drug	MIC (mg/mL)
Anidulafungin	0.015
Micafungin	0.008
5-Fluorocytosine	> 64.0
Posaconazole	0.12
Voriconazole	0.25
Itraconazole	0.25
Fluconazole	> 256.0
Amphotericin B	2.0

Sensitire YeastOne YO10 microbroth dilution system and the minimum inhibitory concentrations (MIC) are demonstrated in Table 1. Fungal blood cultures were negative. There was no evidence of pulmonary or intra-abdominal disease.

Transesophageal echocardiogram (TOE) on day + 17 demonstrated a 2.7-centimetre-long mobile projection attached to a papillary muscle in the left ventricle (Fig. 2) with a large echogenic multilobular mass attached to the posterior tricuspid valve leaflet. The final diagnosis was *A. fumigatus* endocarditis with mycotic cerebral abscesses.

Initial antifungal management was combination therapy

commenced on day + 5 with liposomal amphotericin at a dose of 5 mg/kg (milligram/kilogram) (250 mg) daily plus intravenous voriconazole at a loading dose of 6 mg/kg (400 mg) for two doses followed by 4 mg/kg (200 mg) twice daily. An asymptomatic supratherapeutic voriconazole level of 11.1 mg/L (milligram/liter) was achieved on day + 9. The drug was subsequently held for 24 h and then restarted at 100 mg twice daily. While on this dose, a level of 1.1 mg/L on day + 24 was recorded, which was the minimum level attained while on therapy during the inpatient admission. Amphotericin was ceased on day + 34, at which time the voriconazole was within therapeutic range with a level of 1.8 mg/L. Voriconazole was increased to 200 mg orally twice daily on day + 35 targeting a higher trough level of 4.0–5.0 mg/L, with a level of 4.0 mg/L achieved on day + 51.

Cardiac surgery was considered, however given the location of the vegetations there was a prohibitive risk of surgery-related mortality in the acute setting. Repeat TOE on day + 33 demonstrated a decrease in vegetation size, possibly representing fibrinous contraction or embolization, although no new embolic phenomena were clinically apparent.

His mobility and function improved with rehabilitation. The patient was discharged home on day + 56 with oral voriconazole 200 mg twice daily, planned to continue for at least one year.

Following discharge, the patient was lost to follow-up at the institution to which he initially presented. He completed 50 days of voriconazole therapy in hospital and likely a further 14 days up until day + 70, as an outpatient, based on prescribing history. Remarkably, over a year later, on day + 397 this patient lived independently in the community. He presented to the emergency department of the original institution following a seizure. CT brain demonstrated enhancement within the left occipital lobe consistent with scarring or granulation tissue. There was no evidence of a focal mass lesion to suggest active infection.

### 3. Discussion

This case is unique for the positive outcome despite suboptimal therapy as well as the lack of classic risk factors for fungal endocarditis.

Most cases of *Aspergillus* endocarditis occur in patients with a predisposing condition [9]. The aortic and mitral valves are most commonly involved [3]. Up to 74% of patients have a history of any

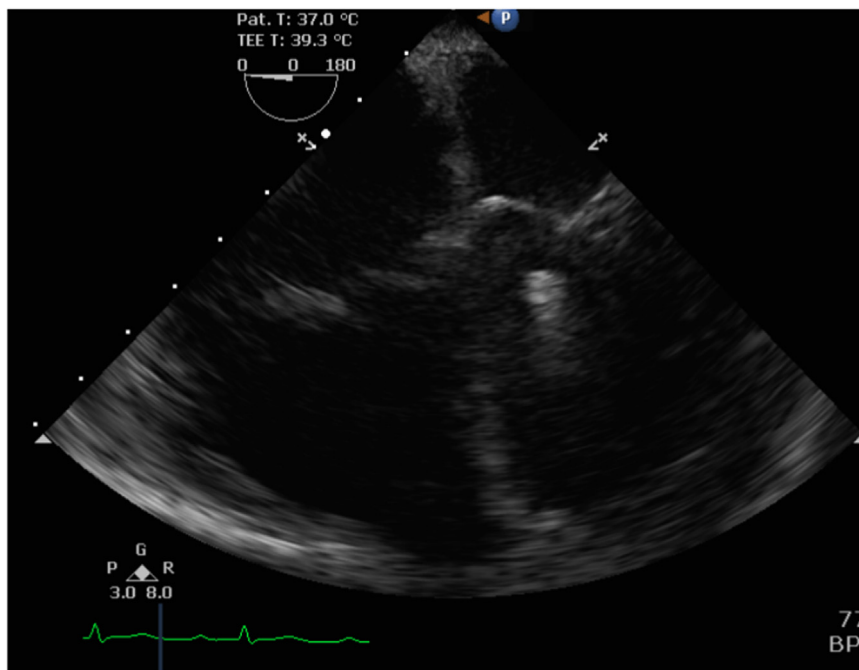


Fig. 2. Transesophageal echocardiograph demonstrating left ventricular finger-like projection attached to the posteromedial papillary muscle.

surgery, with heart valvular surgery making up almost 50% of cases and other cardiac surgery including coronary artery bypass grafting and cardiac transplantation posing a lesser risk [10]. Fungal endocarditis complicates 0.1% of all prosthetic valves, with *Aspergillus* identified as the pathogen in a quarter of these cases [6]. Risk is increased by the presence of structural cardiac valvular abnormalities due to bacterial endocarditis, rheumatic heart disease and valvular surgery, with mitral valve prolapse pertaining particularly elevated risk [6,9,11]. Heart and lung transplant recipients are the highest risk group of solid organ transplant recipients due to higher level of immunosuppressive therapy and structural abnormalities [10,11]. Other identified risk factors include malignancy, the presence of an indwelling central venous catheter, use of broad-spectrum antibiotics and intravenous drug use [4,9,11].

Our patient did not have any identifiable classical risk factors for *Aspergillus* endocarditis and had an unremarkable TTE prior to this presentation. He was, however, known to have pulmonary colonization and excessive alcohol consumption likely increased his risk for infection. Indigenous Australians, particularly those living in rural and remote communities have an increased risk of infection, including sexually transmitted infections, skin and soft tissue infections, pulmonary infections, invasive pneumococcal disease, various parasitic infections and viral hepatitis [12–15]. Published case series indicate that Indigenous Australians living in Northern Queensland are at increased risk of fungal keratitis [16] and fungal peritonitis, in those receiving peritoneal dialysis [17]. There is no specific evidence to suggest an increased risk of invasive aspergillosis in the Indigenous Australian population. The increased risk of infection has been attributed to various environmental and social factors, with no specific evidence of impaired immunity. In the case of fungal infections, there is often an accompanying risk factor such as diabetes, alcohol consumption or the use of immunosuppressive drugs. The resulting degree of immunosuppression may be underestimated as each risk factor on its own may not be viewed as sufficient to predispose to a fungal infection, however the cumulative risk may be high. Unfortunately, clinical diagnostics to accurately predict the risk of fungal infections in both Indigenous and non-Indigenous populations are not available.

The clinical presentation of *Aspergillus* endocarditis is vague with fever and cardiac murmurs being the most common presenting features [3,7,18], followed by symptoms related to embolization and cardiac failure [10]. Classic signs of bacterial endocarditis are usually absent [11]. The friable, large and/or pedunculated nature of *Aspergillus* vegetations makes embolization more common than is experienced with bacterial endocarditis [3,4,11]. A review of 35 published cases between 2003 and 2009 found that 38% of patients had evidence of embolization at presentation, with 18% having central nervous system involvement [10]. Cerebral imaging is recommended at the time diagnosis of *Aspergillus* endocarditis to ascertain the extent of disease [3]. Up to one third of cases of *Aspergillus* endocarditis are diagnosed post-mortem [10].

Culture of embolic material or vegetations is the gold standard for diagnosis as blood cultures are negative in most cases [5,10,11,19]. Non-culture based methods such as galactomannan [5] and *Aspergillus* polymerase chain reaction (PCR) on surgical samples may play a role [7,10] and should be considered on a case-by-case basis in conjunction with other diagnostic tests [3] when the diagnosis of endocarditis is unclear, in an at-risk patient. Molecular methods are strongly recommended when isolates display atypical growth and when species identification is critical, including when there is concern regarding antifungal resistance [3]. The Infectious Diseases Society of America (IDSA) recommends that culture is combined with histopathologic/cytologic analysis for diagnosis of invasive aspergillosis [3], including endocarditis. Histology of valvular tissue can confirm the presence of *Aspergillus* endocarditis [10,11]. In this case, diagnosis was made based on a positive culture for *A. fumigatus* from cerebral abscess contents in the context of vegetations seen on TOE, as valvular tissue was not

obtained.

There is a relative paucity of evidence regarding optimal therapy, however voriconazole therapy plus combined with prompt surgical intervention is recommended to prevent embolization and valvular decompensation [3,7,8,11]. Due to the inherent difficulties in conducting a prospective trial, the optimal duration of antifungal therapy is unknown and most available treatment data is from case reports, case series and animal models. Four weeks of initial therapy with either voriconazole or liposomal amphotericin B, followed by two years secondary prophylaxis with voriconazole appears to be the minimum suggested duration [10]. Many would recommend that regardless of whether the affected valve(s) has been surgically replaced or not, antifungals are continued life-long [7,9] or at least until the precipitating risk factor is removed. There is no evidence to support the superiority of combination antifungal directed therapy over single agent therapy.

The overall mortality rate of *Aspergillus* endocarditis is reported between 62.5% and 90% [5–7,9]. The natural history of this disease has the potential to be rapidly lethal, with one study in the pre-voriconazole era demonstrating a mean survival period of just 11 days [6]. The lower mortality rates in more recent studies may be attributable to molecular diagnostics, which allow for a more rapid diagnosis, better supportive care and prolonged treatment with voriconazole [5].

This case highlights the need to be vigilant and to have a high index of suspicion of fungal and other infections in Indigenous patients as well as other individuals with several “lower risk” risk factors for fungal infections. The optimum management of *Aspergillus* endocarditis remains unclear; however, it is likely that the widespread availability and use voriconazole has contributed to decreased mortality. More research is required to develop tools and tests to quantitatively assess the risk of fungal infection, which may allow for prophylaxis and other preventative interventions. There is an evolving role for PCR and molecular-based diagnostics, however at the present time they should be considered adjuncts to culture, clinical and imaging-based diagnostics.

#### Acknowledgements

Thank you to the doctors from the cardiology and radiology departments at the Royal Adelaide Hospital for their assistance in diagnostic imaging as well as to the microbiologists and scientists at the National Fungal Reference Laboratory at SA Pathology for providing diagnostic mycology services.

#### Conflict of interest

There are no conflicts of interest to report.

#### References

- [1] T. Walsh, Invasive aspergillosis in patients with neoplastic diseases, *Sem. Resp. Infect.* 5 (1990) 111–122.
- [2] T. Walsh, D.M. Dixon, Nosocomial aspergillosis: environmental microbiology, hospital epidemiology, diagnosis and treatment, *Eur. J. Epidemiol.* 5 (1989) 131–142.
- [3] T. Patterson, G. Thompson III, D. Denning, et al., Practice guidelines for the diagnosis and management of aspergillosis: 2016 update by the infectious diseases Society of America, *Clin. Infect. Dis.* (2016).
- [4] P. Tattavin, M. Revest, et al., Fungal endocarditis: current challenges, *Int. J. Antimicrob. Agents* 44 (2014) 290–294.
- [5] S. Riviere, O. Lortholary, et al., *Aspergillus* endocarditis in the era of new antifungals: major role for antigen detection, *J. Infect.* 67 (1) (2013) 85–88.
- [6] M. Ellis, H. Al-Abdely, et al., Fungal endocarditis: evidence in the world literature 1965–1995, *Clin. Infect. Dis.* 32 (2001) 50–62.
- [7] A. Kalokhe, N. Roupheal, et al., *Aspergillus* endocarditis: a review of the literature, *Int. J. Infect. Dis.* 14 (2010) e1040–e1047.
- [8] M. Lazaro, A. Ramos, et al., *Aspergillus* endocarditis in lung transplant recipients: case report and literature review, *Transpl. Infect. Dis.* 13 (2011) 186–191.
- [9] L. Pierotti, L.M. Baddour, Fungal endocarditis 1995–2000, *Chest* 122 (1) (2002) 302–310.
- [10] J. McCormack, J. Pollard, *Aspergillus* endocarditis 2003–2009, *Med. Mycol.* 49 (Suppl. 1) (2011) S30–S34.
- [11] I. El-Hamamsy, N. Durrleman, et al., *Aspergillus* endocarditis after cardiac surgery,

- Ann. Thorac. Surg. 80 (2005) 359–364.
- [12] P. Boan, H.L. Tan, et al., Epidemiological, clinical, outcome and susceptibility differences between PVL positive and PVL negative *Staphylococcus aureus* infections in Western Australia: a case control study, *BMC Infect. Dis.* 15 (10) (2015).
- [13] R. Menzies, C. Turnour, et al., Vaccine preventable diseases and vaccination coverage in aboriginal and Torres Strait Islander people, Australia, 2003 to 2006, *Commun. Dis. Intell. Q Rep.* 32 (Suppl) (2008) S1–S67.
- [14] F. Johnson, P.S. Morris, et al., Strongyloidiasis: a review of the evidence for Australian practitioner, *Aust. J. Rural Health* 13 (2005) 247–254.
- [15] A. Bright, National notifiable diseases surveillance system surveillance report: sexually transmissible infections in Aboriginal and Torres Strait Islander people, *Commun. Dis. Intell. Q. Rep.* 2008 39 (2015) E584–E589.
- [16] M. Thew, B. Todd, Fungal keratitis in far north Queensland, Australia, *Clin. Exp. Ophthalmol.* 36 (8) (2008) 721–724.
- [17] R. Baer, J. Killen, et al., Non-candidal fungal peritonitis in far North Queensland: a case series, *Perit. Dial. Int.* 33 (5) (2013) 559–564.
- [18] E. Rubinstein, R. Lang, Fungal endocarditis, *Eur. Heart J.* 16 (Suppl B) (1995) 84–89.
- [19] D. Denning, D.A. Stevens, Antifungal and surgical treatment of invasive aspergillosis: review of 2,121 published cases, *Rev. Infect. Dis.* 12 (1990) 1147–1201.