

CASE REPORT

Open Access



Identification of a novel pathogenic *TBCK* variant in a Chinese patient with infantile hypotonia with psychomotor retardation and characteristic facies type 3 (IHPRF3): a case report

Hao-Yi Tan¹, Bin Wang² and Yuan-Zong Song^{1*}

Abstract

Background: Infantile hypotonia with psychomotor retardation and characteristic facies type 3 (IHPRF3) (OMIM #616,900) is an autosomal recessive disorder caused by biallelic pathogenic variants of the *TBCK* gene, and to date, this disease was reported rather limitedly in number and all described cases were Caucasians.

Case presentation: This paper reported the clinical and genetic features of a Chinese patient with IHPRF3. The patient was a 15-month-old male with global developmental delay, profound hypotonia, and typical facial dysmorphic features including mildly coarse facial appearance, hypertelorism, tented upper lip, exaggerated Cupid's bow, macroglossia and arched eyebrows. Magnetic Resonance Imaging (MRI) analysis of the brain revealed slightly widened bilateral ventricles and subarachnoid space. On genetic analysis, the patient was homozygous for a novel *TBCK* variant c.247C > T(p.Arg83Ter). The parents were both carriers without any positive symptoms or signs. With an extremely low frequency (0.0000082) in Exome Aggregation Consortium, the variant has not been reported in any other databases or official literatures, and was diagnosed to be pathogenic according to the American College of Medical Genetics and Genomics (ACMG) standards and guidelines. Neurorehabilitation training did not work well and the long-term prognosis remained to be observed.

Conclusions: This study reported the clinical and molecular features of the first non-Caucasian patient with IHPRF3 arising from a novel homozygous *TBCK* mutation, which provided a novel molecular marker for the definite diagnosis of IHPRF3 patients and for its genetic counseling and prenatal diagnosis in the affected families.

Keywords: IHPRF3, *TBCK*, Genetic mutation, Child, Hypotonia

Background

Infantile hypotonia with psychomotor retardation and characteristic facies type 3 (IHPRF3) is an infantile encephalopathy syndrome caused by biallelic pathogenic mutations in the *TBCK* (TBC1 domain containing kinase) gene, which is located on chromosome 4 with a total of 26 exons and encodes an 893-aa protein with kinase, TBC (Tre-2, Bub2, and Cdc16) and Rhodanese homology

*Correspondence: songyuanzong@vip.tom.com

¹ Department of Pediatrics, The First Affiliated Hospital, Jinan University, Guangdong 510630, China

Full list of author information is available at the end of the article



domains [1]. *TBCK* is involved in the regulation of cell proliferation, cell growth, and actin organization by making an impact on the expression of mammalian target of rapamycin (mTOR) complex (mTORC) components at the transcriptional level. The main clinical manifestations included systemic growth retardation, special facial features, drug-resistant epilepsy, and chronic respiratory failure. Other frequently occurring phenotypes included poor language expression ability, hypotonia, visual impairment, hearing impairment and bone metabolism disorders [2].

The first case of *IHPRF3* was reported in 2008 [3], and to date, this disease was still a rare condition with patients extremely limited in number. So far as we know, only 45 such patients have been reported worldwide and all of them were Caucasians [4–6]. Hence, the clinical and molecular characteristics of this disease remain open for investigation, especially in non-Caucasian populations. Herein, we reported the clinical and genetic presentations of the first *IHPRF3* patient in Asian population.

Case presentation

The patient was a 15-month-old boy with global developmental delay noticed for 10 months. He was found to be unable to raise his head at 5 months of age when electroencephalogram was normal but brain Magnetic Resonance Imaging (MRI) (Fig. 1) revealed slightly widened bilateral ventricles and subarachnoid space. No abnormalities were found in chromosome karyotype analysis and screening for genetic metabolic diseases. Physiotherapy and rehabilitation training was performed but the effect was not promising. When aged 15 months, he could still neither lift his head nor be seated unsupportedly, and could not call “mom” and “dad” intendedly.

He was born at the gestational age of 38 weeks and one day as the product of a non-consanguineous couple, with a birth weight of 3.75 kg and body length 50 cm that were appropriate for gestational age but with an occipitofrontal head circumference of 38 cm with a Z score +2.91SD. When aged 6 days, he was admitted into the Division of Neonatology in the Department of Pediatrics of our hospital for 12 days because of neonatal hyperbilirubinemia and pneumonia, where low muscular tension and muscle strength were noticed. Because of the lack of other positive symptoms or signs, the family decided to observe his development without any treatment.

Physical examination at referral revealed a body weight of 10 kg, body length 80 cm and head circumference 48.5 cm (+1SD). No jaundice was observed in the skin and sclera. Special facial features were observed, including mildly coarse facial, hypertelorism, tented upper lip,

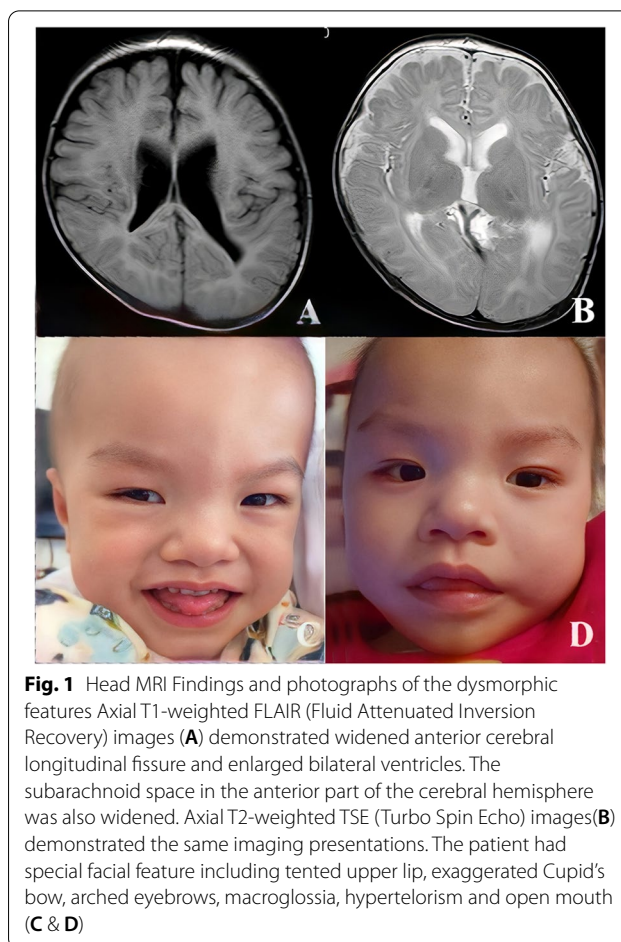


Fig. 1 Head MRI Findings and photographs of the dysmorphic features Axial T1-weighted FLAIR (Fluid Attenuated Inversion Recovery) images (A) demonstrated widened anterior cerebral longitudinal fissure and enlarged bilateral ventricles. The subarachnoid space in the anterior part of the cerebral hemisphere was also widened. Axial T2-weighted TSE (Turbo Spin Echo) images (B) demonstrated the same imaging presentations. The patient had special facial feature including tented upper lip, exaggerated Cupid's bow, arched eyebrows, macroglossia, hypertelorism and open mouth (C & D)

exaggerated Cupid's bow, macroglossia, open mouth and arched eyebrows (Fig. 1). No stridor, crackles or crepitus could be heard in the two lungs, and the heart sound was normal without any murmurs. There was no abdominal distention, and the liver and spleen were non-palpable. Marked hypotonia was found especially at the lower limbs. Abdominal wall reflex was weak, and neither achilles nor knee tendon reflex could be drawn. The ribbed arch valgus and pectus excavatum were observed. The palm and sole prints were deep, and horizontal wrinkles could be seen on both knees. The testis had not descended into the scrotum.

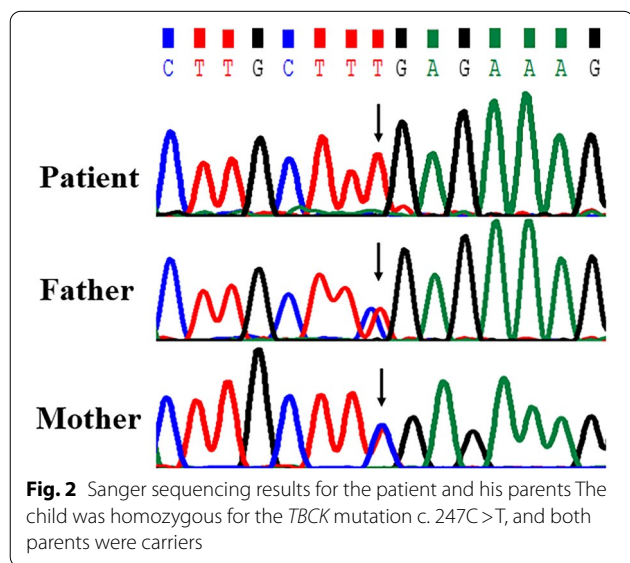
The Gesell Developmental Schedules (GDS) analysis was conducted, and a score of 8.9 for gross motor function was got, along with the scores 23.7 for fine motor function, 26.6 for adaptive behavior, 26.6 for language ability and 26.6 for social skill, indicating global developmental delay.

Considering his clinical presentations, genetic neuromuscular disease was highly suspected and hence Next Generation Sequencing (NGS) was carried

out to explore the underlying genetic etiology. As a result, NGS detected a homozygous *TBCK* mutation c.247C>T(p.Arg83Ter) in the patient, which was a nonsense mutation located in exon 3. Sanger sequencing confirmed that the child was homozygous for this variant, and his healthy father and mother were both carriers (Fig. 2). To the best of our knowledge, the variant, with an extremely low frequency (0.0000082) in Exome Aggregation Consortium, has not been reported in any other databases or official literatures.

Based on the clinical and genetic findings above, the patient in this study was diagnosed with IHPRF3. Neurorehabilitation training was continued, but on a follow-up at his age of 17 months, no significant improvement was observed in the clinical manifestations such as growth retardation. The long-term prognosis remained to be observed.

Figure 3 illustrated the relevant information of the patient in a timeline.

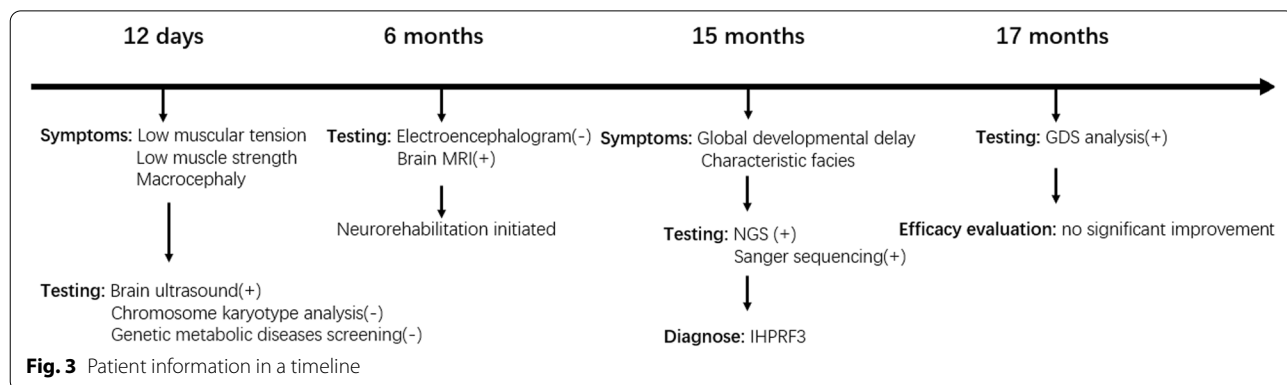


Discussion and conclusions

In this study, the patient had phenotypes of severe global developmental delay, while low muscle tension and strength, special facial features and macrocephaly at birth were noticed. Although positive, the brain MRI findings was not severe or specific. On genetic analysis, the child was a homozygote of the *TBCK* mutation c.247C>T which caused transcription to stop at 83-aa, giving rise to a truncated protein p.Arg83Ter, which met the PVS1 criteria in the American College of Medical Genetics and Genomics (ACMG) standard and guidelines [7]. Both parents were carriers of this mutation without positive signs or symptoms, which reached the PP1 criteria. Moreover, the variant was found with an extremely low frequency (0.0000082) in Exome Aggregation Consortium (EAC) and no matching records found in Exome Variant Server (EVS) or official literatures, which was a PM2 evidence. Hence, the variant c.247C>T(p.Arg83Ter) was diagnosed as “pathogenic” and the patient was thus diagnosed to suffer from IHPRF3.

TBCK was documented to play an important role in the control of cell proliferation, cell size, and actin-cytoskeleton dynamics by modulation of the mTOR signaling network [1, 8]. And in this case, the patient’s severe global developmental delay might be attributed to dysregulated mTOR signaling which caused his thinner bilateral cerebral cortex shown on brain MRI. The patient also had severe hypotonia, which was not surprising since mTOR mediated key endogenous neuroprotective mechanisms in motoneurons [9]. The patient in this study had an obvious macrocephaly at birth, but when aged 15 months, his head circumference became normal. To date, only four IHPRF3 patients were mentioned with macrocephaly [10]. Whether and how macrocephaly was associated with IHPRF3 remained an issue needing to be addressed.

At present, the treatment of IHPRF3 was mainly symptomatic and supportive, including regular follow-up, rehabilitation training and giving respiratory support if necessary to delay the progression of the disease. Of



note, *TBCK* influences the expression of mTOR components at the transcriptional level [11], and therapeutic mTORC1 activation may be a potential strategy to prevent the progression of the disease. Actually, the mTOR pathway could be stimulated by exogenous L-leucine supplementation [12], and leucine supplementation was already clinically available for certain metabolic disorders [10, 12]. However, the prognosis generally appeared to be unfavorable [6]. Delayed motor function and severe hypotonia were common in IHPRF3, which caused a decline in the quality of life and respiratory failure posed a threat to the lives in patients with involvement of respiratory muscles.

In conclusion, this study reported the clinical and molecular features of the first non-Caucasian patient with IHPRF3 arising from a novel homozygous *TBCK* mutation, which provided a novel molecular marker for the definite diagnosis of IHPRF3 patients, and for its genetic counselling and prenatal diagnosis in the affected families.

Abbreviations

IHPRF3: Infantile hypotonia with psychomotor retardation and characteristic facies type 3; MRI: Magnetic Resonance Imaging; ACMG: American College of Medical Genetics and Genomics; *TBCK*: TBC1 domain containing kinase; mTOR: Mammalian target of rapamycin; GDS: The Gesell Developmental Schedules; NGS: Next Generation Sequencing; EAC: Exome Aggregation Consortium; EVS: Exome Variant Server; FLAIR: Fluid Attenuated Inversion Recovery; TSE: Turbo Spin Echo; INSDC: International Nucleotide Sequence Collaboration.

Acknowledgements

We thank the family of the patient for their cooperation and participation in this study.

Authors' contributions

HYT and YZS together designed the work, and analyzed and interpreted the patient data. HYT drafted and modified the manuscript. BW contributed to the conception of the work as well as the acquisition, analysis and interpretation of the imaging data. YZS and BW reviewed and approved the submission. The authors declare that they have no competing interests. All authors contributed to manuscript revision, read and approved the submitted version.

Funding

The authors did not receive support from any organization for the submitted work.

Availability of data and materials

The datasets generated and analyzed during the current study are available in the GenBank of International Nucleotide Sequence Collaboration (INSDC) repository (GenBank: OP113122.1).

Declarations

Ethics approval and consent to participate

This study has been approved by the Committee for Medical Ethics, the First Affiliated Hospital, Jinan University. The patient's parents had provided written informed consent to participate in genetic analysis.

Consent for publication

The authors declare that this study was performed after written informed consent had been obtained from the parents who permitted publication of

their child's personal or clinical details along with any identifying images in this study.

Competing interests

The authors have no relevant financial or non-financial interests to disclose.

Author details

¹Department of Pediatrics, The First Affiliated Hospital, Jinan University, Guangdong 510630, China. ²Department of Pediatrics, Zhujiang Hospital, Southern Medical University, Guangdong 510280, China.

Received: 19 April 2022 Accepted: 16 October 2022

Published online: 22 October 2022

References

- Liu Y, Yan X, Zhou T. *TBCK* influences cell proliferation, cell size and mTOR signaling pathway. *PLoS ONE*. 2013;8(8): e71349. <https://doi.org/10.1371/journal.pone.0071349>.
- Zapata-Aldana E, Kim DD, Remtulla S, et al. Further delineation of *TBCK* - Infantile hypotonia with psychomotor retardation and characteristic facies type 3. *Eur J Med Genet*. 2019;62(4):273–7. <https://doi.org/10.1016/j.ejmg.2018.08.004>.
- Smith A, Leask K, Tomlin P, et al. A familial dysmorphic condition with hypotonia, seizures and precocious puberty. *Clin dysmorphol*. 2008;17(3):161–4. <https://doi.org/10.1097/MCD.0b013e328302f0c4>.
- Alazami AM, Patel N, Shamseldin HE, et al. Accelerating novel candidate gene discovery in neurogenetic disorders via whole-exome sequencing of prescreened multiplex consanguineous families. *Cell Rep*. 2015;10(2):148–61. <https://doi.org/10.1016/j.celrep.2014.12.015>.
- Guerreiro RJ, Brown R, Dian D, et al. Mutation of *TBCK* causes a rare recessive developmental disorder. *Neurol Genet*. 2016;2(3): e76. <https://doi.org/10.1212/NXG.0000000000000076>.
- Mandel H, Khayat M, Chervinsky E, et al. *TBCK*-related intellectual disability syndrome: Case study of two patients. *Am J Med Genet A*. 2017;173(2):491–4. <https://doi.org/10.1002/ajmg.a.38019>.
- Richards S, Aziz N, Bale S, et al. Standards and guidelines for the interpretation of sequence variants: a joint consensus recommendation of the American College of Medical Genetics and Genomics and the Association for Molecular Pathology. *Genet Med*. 2015;17(5):405–24. <https://doi.org/10.1038/gim.2015.30>.
- Wu J, Li Q, Li Y, et al. A long type of *TBCK* is a novel cytoplasmic and mitotic apparatus-associated protein likely suppressing cell proliferation. *J Genet Genomics*. 2014;41(2):69–72. <https://doi.org/10.1016/j.jgg.2013.12.006>.
- Saxena S, Roselli F, Singh K, et al. Neuroprotection through excitability and mTOR required in ALS motoneurons to delay disease and extend survival. *Neuron*. 2013;80(1):80–96. <https://doi.org/10.1016/j.neuron.2013.07.027>.
- Bhoj EJ, Li D, Harr M, et al. Mutations in *TBCK*, Encoding TBC1-Domain-Containing Kinase, Lead to a Recognizable Syndrome of Intellectual Disability and Hypotonia. *Am J Hum Genet*. 2016;98(4):782–8. <https://doi.org/10.1016/j.ajhg.2016.03.016>.
- Laplante M, Sabatini DM. mTOR signaling in growth control and disease. *Cell*. 2012;149(2):274–93. <https://doi.org/10.1016/j.cell.2012.03.017>.
- Pedroso JA, Zampieri TT, Donato J Jr. Reviewing the Effects of L-Leucine Supplementation in the Regulation of Food Intake, Energy Balance, and Glucose Homeostasis. *Nutrients*. 2015;7(5):3914–37. <https://doi.org/10.3390/nu7053914>.

Publisher's Note

Springer Nature remains neutral with regard to jurisdictional claims in published maps and institutional affiliations.