

# A simple technique to strengthen the initial and mid-term to long-term stability of the cup during total hip arthroplasty in developmental dysplasia of the hip

Mingqiang Guan, MD, Guanming Zhou, MS, Xue Li, MD.

### ABSTRACT

**الأهداف:** يقيم تأثير التطبيق لكأس التعزيز الحقي المقرون بتطعيم العظم في علاج مريض لخلع الورك النمو عندما يجري باستبدال مفصل الورك.

**الطريقة:** خلال غسطس في عام 2011م إلى يوليو في عام 2015م، تجري مستشفانا باستبدال مفصل الورك (THA) لـ 59 مريض المصاب بخلع الورك النمو (DDH)، كما نطبق تقنية كأس التعزيز الحقي المقرون بتطعيم العظم. وبعد الجراحة نجري بالمتابعة النشطة للمريض ونجمع البيانات السريرية والتصوير.

**النتائج:** معايير التقييم للورك (HHS) ترتفع من 41.24 قبل الجراحة إلى 91.49 ( $p < 0.001$ ) في سجل التتبع الأخير. عدم متساوية الأطراف السفلية (LLD) ينخفض من 28.97 ملم قبل الجراحة إلى 6.08 ملم ( $p > 0.001$ ). ولم يجد ارتخاء الكأس في سجل التتبع الأخير. ويوجد الفرق كبير في زاوية أمامية الكأس ونسبة التغطية لـ DDH ( $p < 0.05$ ) من Crowe II و III و IV.

**الخاتمة:** التقنية لكأس التعزيز الحقي المقرون بتطعيم العظم بسيطة وآمنة، من السهل أن يصل إلى الاستقرار في مرحلة البداية لاستبدال مفصل الورك، كما يعزز الاستقرار في المرحلة المتوسطة.

**Objectives:** To assess the effects of a technique of cup blocking screws combined with impaction bone grafting during total hip arthroplasty (THA) for patients with developmental dysplasia of the hip (DDH).

**Methods:** From August 2011 to July 2015, 53 patients (59 hips) with DDH in our hospital were treated with THA using the technique of cup blocking screws combined with impaction particulate bone grafting. These patients were prospectively followed, and the clinical and imaging results were collected.

**Results:** Harris hip score (HHS) was raised from 41.24 before surgery to 91.49 at the latest follow-up ( $p < 0.001$ ). Length discrepancy (LLD) was reduced from 28.97 mm before surgery to 6.08 mm after surgery ( $p < 0.001$ ). No loosening of the cup was detected at the last follow-up. The differences were insignificant in cup inclination and rate of cup coverage among the 3 groups of Crowe type II, type III, and type IV DDH ( $p > 0.05$ ).

**Conclusion:** The technique of cup blocking screws combined with impaction particulate bone grafting is simple and reliable, and it not only simplifies the attainment of initial stability, but also strengthens the mid-term to long-term stability during THA in DDH.

*Saudi Med J 2018; Vol. 39 (4): 342-346  
doi: 10.15537/smj.2018.4.21684*

*From the Department of Orthopedics and Traumatology, Fosban Hospital of Traditional Chinese Medicine, Guangdong Province, China.*

*Received 14th November 2017. Accepted 14th February 2018.*

*Address correspondence and reprint request to: Dr. Mingqiang Guan, Department of Orthopedics and Traumatology, Fosban Hospital of Traditional Chinese Medicine, Guangdong Province, China. E-mail: hipknee66@163.com  
ORCID ID: orcid.org/0000-0002-5612-290X*

**B**one defect on the superolateral border of the acetabulum is quite common in patients with developmental dysplasia of the hip (DDH).<sup>1</sup> During total hip arthroplasty (THA), this defect often acts as the main challenge in obtaining the initial stability of the acetabular component.<sup>2</sup> Additionally, without appropriate management, it may also undermine the mid-term to long-term stability of the cup. To resolve this problem, several methods have been developed, including shift-up of the rotational center, medialization of the rotational center, impaction particulate bone grafting, structural bone grafting, reinforcement rings

and metal acetabular augments.<sup>3-9</sup> The majority of the mild and moderate bone defects could be successfully treated by the first 2 methods. For severe defects, the other methods were often needed. Impaction particulate bone grafting is a frequently used method for the treatment of bone defects. However, it could only strengthen the mid-term to long-term stability and is of little help in the obtaining of initial stability. It still remains controversial regarding the application of structural bone grafting during THA in DDH, although it is helpful in the achievement of initial stability. Some studies reported satisfactory follow-up results, while others demonstrated that cup loosening was of high rate resulting from graft collapse or resorption.<sup>7,10,11</sup> Several metal devices, such as reinforcement rings and acetabular augments, were reported to be helpful in facilitating the achievement of initial and mid-term to long-term stability; however, they could also increase the costs and complexity of the operation. To strengthen the initial stability, as well as the mid-term to long-term stability of the cup, the impaction particulate bone grafting was used in combination with a technique of cup blocking screws in our hospital. The main purpose of the present study was to introduce the clinical and imaging outcome of this technique during THA in DDH.

**Methods.** *Study design and setting.* In this prospective study, we followed 53 patients (59 hips) with DDH in our hospital who were treated with THA using the technique of cup blocking screws combined with impaction particulate bone grafting between August 2011 and July 2015. The average follow-up time of the patients was 4.62 years (2-6 years). Three patients (4 hips) were dead for reasons that were not related to operation. Another 9 cases (12 hips) were lost to follow-up. No signs of loosening was detected in these 12 patients until the latest follow-up. Therefore, there were 41 patients (43 hips) in all that were available for review. Patients' demographic information is summarized in Table 1. Ethical approval was obtained from the review board in our hospital, and every patient had signed the informed consent. The research was carried out according to the Declaration of Helsinki.

*Surgical procedure.* All operations were performed through posterolateral approach by the same Orthopedic

**Table 1** - Demographic data of 53 patients with developmental dysplasia of the hip treated with total hip arthroplasty using the technique of cup blocking screws combined with impaction particulate bone grafting.

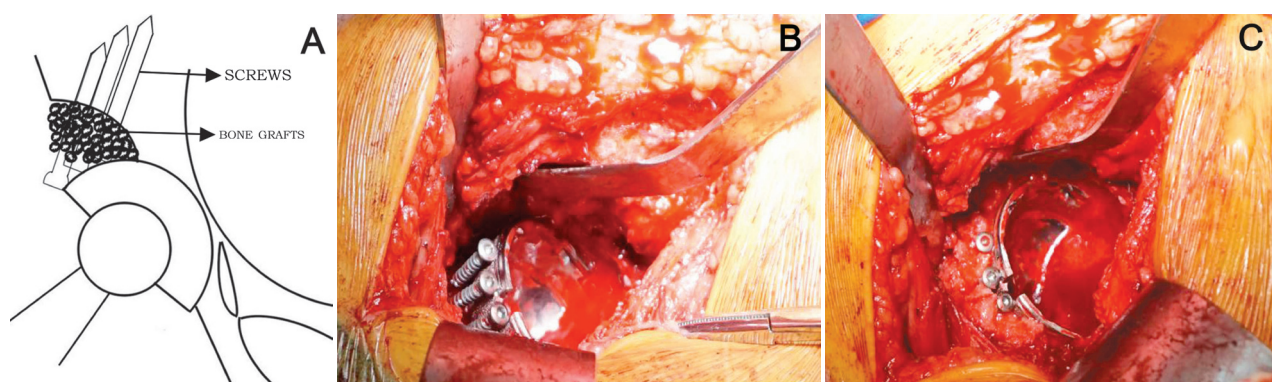
Variables	Values (range)
<i>Gender</i>	
Female	39
Male	2
Age (years)	58.67 (37-81)
Height (cm)	156.80 (150.93-177.32)
Weight (kg)	53.73 (46.56-74.21)
Body mass index (kg/m <sup>2</sup> )	21.94 (20.63-23.56)
<i>Crowe classification</i>	
II	14
III	21
IV	8

Surgeon. The real acetabulum was firstly defined by the ischium, obturator, and pubis. To expose the acetabular medial wall and incisura acetabuli, soft tissue and bony layers had to be removed. The acetabulum was gradually prepared with acetabular reamer until the cartilage in the superior, anterior, posterior and medial walls of the acetabulum was removed. Remnants of cartilage in the inferior acetabular wall were allowed. Then, we evaluated the proportion of the bony coverage of the cup according to the last acetabular reamer. If the uncovered portion above the cup was more than 40%, the technique of cup blocking screws combined with impaction particulate bone grafting was used. Three to 4 screws were implanted in the area of bone defect close to the upper edge of the last reamer, which was kept in the acetabulum. Then, a cementless acetabular component was inserted, and the initial stability was assessed. The autogenous bone particles obtained from the patients' femoral head were placed around the screws and impacted firmly (Figure 1). All of the femoral stems were also uncemented.

*Perioperative management.* Antibiotics were applied half an hour before skin incision and stopped 24 hours after operation. Enoxaparin was firstly administered 12 hours after operation for thromboembolic prophylaxis. All patients received the same procedure of perioperative pain management. With the help of crutches or walkers, we directed the patients to walk off the bed with touchdown weight-bearing from the second day postoperatively. The patients were allowed to walk with partial weight-bearing as tolerated until 4 weeks postoperatively, and then with full weight-bearing 8 weeks after operation.

*Clinical and radiographic evaluation.* Postoperatively, all patients were evaluated 6 weeks, 12

**Disclosure.** Authors have no conflict of interests, and the work was not supported or funded by any drug company.



**Figure 1** - Technique of cup blocking screws combined with impaction particulate bone grafting: (A) Schematic diagram of the technique. (B) Three to four screws were implanted in the area of bone defect to strengthen the cup initial stability. (C) The autogenous bone particles harvested from femoral head were placed around the screws and impacted firmly to strengthen the midterm to long-term stability.

weeks, half a year, one year, and then annually thereafter. Length discrepancy (LLD) was recorded before and after the operation. Harris hip score (HHS) was recorded before surgery and at each follow-up postoperatively.<sup>12</sup> A patient satisfaction scale was applied to assess patients' satisfaction with the effect of THA.<sup>13</sup> On the anteroposterior pelvic x-ray films, the inclination of the cup was determined by the interteardrop line and the face of the cup. The coverage rate of the cup was calculated with the methods introduced by Spangehl et al.<sup>11</sup> Cup loosening was identified according to the standard introduced by Maruyama et al.<sup>14</sup>

**Statistical analysis.** Statistical analysis was performed with the Statistical Package for the Social Science (SPSS) version 23.0 (IBM Corp., Armonk, NY, USA). Preoperative and postoperative HHS and LLD were compared with paired-sample t-tests. Comparison of qualitative variables among groups was performed by one-way ANOVA with Bonferroni post-hoc test. Kruskal-Wallis test was performed to compare the cup coverage rate among the groups.  $p < 0.05$  was used to determine statistical significance.

**Results.** The mean HHS was raised from 41.24 (range, 21-60) preoperatively to 91.49 (range, 78-100) at the latest follow-up ( $p < 0.001$ ). The mean LLD was 28.97 mm (range, 0-50 mm) preoperatively, which was decreased to 6.08 mm (range, 0-11 mm) postoperatively ( $p < 0.001$ ). At the latest follow-up after surgery, no significant differences was detected in the aspect of HSS, LLD and satisfaction among patients with Crowe type II, type III, and type IV DDH (Table 2).

Posterior dislocation of the hip happened in one patient 2 months after operation when she tried to stand up from a low chair. We managed the dislocation

**Table 2** - Comparison of clinical results among subgroups.

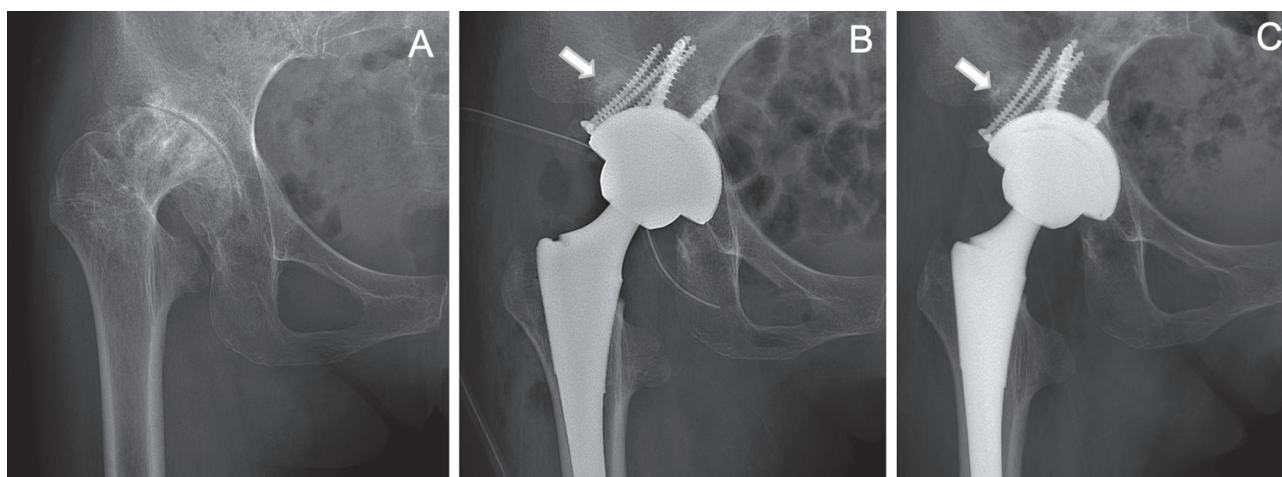
Parameters	Crowe classification			P-value
	II	III	IV	
HSS	93.23±4.71	91.68±6.67	87.71±7.89	0.189
LLD (mm)	5.54±3.63	5.89±4.16	7.57±4.10	0.511
Satisfaction	85.08±6.78	79.58±10.16	81.43±7.41	0.228
HSS - harris hip score, LLD - leg length discrepancy				

by closed reduction under spinal anesthesia, and the hip abduction brace was applied for 1 month. The hip dislocation did not happen again. At last follow-up, no loosening of the cup was detected in any of the patients (Figure 2).

For patients with Crowe type II, type III, and type IV DDH, no significant differences were detected in the aspects of cup inclination, and rate of cup coverage ( $p > 0.05$ ). Patients in Crowe type IV group experienced more femoral head inferior shift ( $p < 0.001$ ) (Table 3).

**Discussion.** Owing to the bone defect often encountered, the most common difficulties often lie with acetabular reconstruction during THA for DDH, especially for patients with Crowe types III and IV DDH. Although it has been reported that most of the mild and moderate bone defects could be successfully treated by medialization of the rotational center, there has not been a consensus on the threshold of medial protrusion. Some reports proposed  $< 45\%$ , while others proposed  $< 50\%$  or even  $60\%$ .<sup>15-17</sup> Excessive medialization will further undermine the bone stock of the acetabulum, which may worsen the complexity if a revision operation is needed in the future. In addition, there has also not been a consensus on the cup coverage





**Figure 1** - Radiographic evaluation: (A) Preoperative radiograph of a 53-year-old female patient with DDH. (B) Radiograph immediately after surgery. (C) Radiograph 3 years after operation. No signs of loosening was detected.

rate of host bone to ensure the stability. The proposed uncovered portion of the cup ranged from  $\leq 30\%$  to  $\leq 50\%$ .<sup>18-21</sup> Due to these uncertainties, it is often quite difficult for the surgeons to make sure if the initial stability of the cup is reliable enough and whether mid-term to long-term stability is guaranteed.

Bone grafting, including structural bone grafting and impaction bone grafting, is the most efficient method in improving the acetabular bone stock. Although structural bone grafting is helpful in obtaining the cup initial stability, it is reported that the effect of structural bone grafting on the mid-term to long-term stability is not always secured.<sup>22,23</sup> We believe that structural bone grafting requires highly experienced surgeons who should be quite skillful in the grafts preparation and fixation.<sup>24</sup> Additionally, the surface of the bone defect should also be carefully prepared by drilling and roughening to promote vascularization. In contrast to structural bone grafting, favorable mid-term to long-term effects of impaction bone grafting have been reported in the treatment of bone defects during THA for DDH.<sup>6,25</sup> However, impaction bone grafting is not helpful in the achievement of the initial stability of the cup. To overcome this weakness, we tried to apply impaction bone grafting in combination with cup blocking screws. Under the help of cup blocking screws, we obtained the cup initial stability without significant difficulties in all the patients during this study. At the last follow-up, all of the cups demonstrated satisfactory coverage and inclination degrees. No loosening of the cup was detected.

**Table 3** - Comparison of imaging results among subgroups.

Parameters	Crowe classification			P-Value
	II	III	IV	
Cup inclination (°)	41.93±2.97	42.01±4.42	44.89±5.25	0.218
Femoral head inferior shift (mm)	17.32±5.11	22.82±6.21	37.85±3.28	<0.001
Rate of cup coverage (%)	96.70±4.53	97.65±3.56	94.41±4.12	0.081

We have summarized 3 recommendations regarding the technique of cup blocking screws combined with impaction bone grafting: 1) 3-4 screws are recommended to be implanted. Too many screws may further undermine the dome of the acetabulum, while too few screws may not provide enough support; 2) The screws should be implanted closely to the upper edge of the last reamer, and the reamer should be kept at the position of 40° of abduction and 10° of anteversion; 3) Before impaction bone grafting, the surface of the bone defect should be carefully prepared by drilling and roughening.

**Study limitation.** First, the sample size was small. Second, only one type of cup was used in the present research, and thus it may lead to certain bias. Third, patients included in this research were all Chinese with lower body weight in comparison with people in western countries, which may be one of the reasons why the screws could provide enough support for the cup.

In conclusion, the technique of cup blocking screws combined with impaction bone grafting is simple and reliable, which is not only helpful in obtaining initial

cup stability but also in strengthening mid-term to long-term stability during THA for DDH. Nonetheless, further studies on this technique with larger sample sizes are needed.

**Acknowledgment.** *The authors gratefully acknowledge the radiologists, Professor Jinxiong Zhang and Dr. Lilei Yi, for their assistance in reviewing the x-ray films.*

## References

- Li H, Mao Y, Oni JK, Dai K, Zhu Z. Total hip replacement for developmental dysplasia of the hip with more than 30% lateral uncoverage of uncemented acetabular components. *Bone Joint J* 2013; 95: 1178-1183.
- Greber EM, Pelt CE, Gililand JM, Anderson MB, Erickson JA, Peters CL. Challenges in total hip arthroplasty in the setting of developmental dysplasia of the hip. *J Arthroplasty* 2017; 32: S38-S44.
- Zhang Z, Wu P, Huang Z, Yu B, Sun H, Fu M, et al. Cementless acetabular component with or without upward placement in dysplasia hip: Early results from a prospective, randomised study. *J Orthop* 2017; 14: 370-376.
- Chen M, Luo ZL, Wu KR, Zhang XQ, Ling XD, Shang XF. Cementless total hip arthroplasty with a high hip center for hartofilakidis type b developmental dysplasia of the hip: Results of midterm Follow-Up. *J Arthroplasty* 2016; 31: 1027-1034.
- Zha GC, Sun JY, Guo KJ, Zhao FC, Pang Y, Zheng X. Medial protrusio technique in cementless total hip arthroplasty for developmental dysplasia of the hip: A prospective 6- to 9-Year Follow-Up of 43 consecutive patients. *J Arthroplasty* 2016; 31: 1761-1766.
- Iwase T, Morita D, Ito T, Takemoto G, Makida K. Favorable results of primary total hip arthroplasty with acetabular impaction bone grafting for large segmental bone defects in dysplastic hips. *J Arthroplasty* 2016; 31: 2221-2226.
- Kim M, Kadowaki T. High long-term survival of bulk femoral head autograft for acetabular reconstruction in cementless THA for developmental hip dysplasia. *Clin Orthop Relat Res* 2010; 468: 1611-1620.
- Judas FM, Lucas FM, Fonseca RL. Favorable outcome of a total hip arthroplasty with insufficient bone coverage of the roof reinforcement ring. *Int J Surg Case Rep* 2015; 16: 130-133.
- Bicanic G, Barbaric K, Bohacek I, Aljinovic A, Delimar D. Current concept in dysplastic hip arthroplasty: Techniques for acetabular and femoral reconstruction. *World J Orthop* 2014; 5: 412-424.
- Chougle A, Hemmady MV, Hodgkinson JP. Severity of hip dysplasia and loosening of the socket in cemented total hip replacement. A long-term follow-up. *J Bone Joint Surg Br* 2005; 87: 16-20.
- Spanghel MJ, Berry DJ, Trousdale RT, Cabanela ME. Uncemented acetabular components with bulk femoral head autograft for acetabular reconstruction in developmental dysplasia of the hip: Results at five to twelve years. *J Bone Joint Surg Am* 2001; 83: 1484-1489.
- Harris WH. Traumatic arthritis of the hip after dislocation and acetabular fractures: Treatment by mold arthroplasty. An end-result study using a new method of result evaluation. *J Bone Joint Surg Am* 1969; 51: 737-755.
- Mahomed N, Gandhi R, Daltroy L, Katz JN. The self-administered patient satisfaction scale for primary hip and knee arthroplasty. *Arthritis* 2011; 2011: 591253.
- Maruyama M, Tensho K, Wakabayashi S, Hisa K. Standing versus supine radiographs to evaluate femoral head penetration in the polyethylene liner after total hip arthroplasty. *J Arthroplasty* 2014; 29: 2415-2419.
- Dorr LD, Tawakkol S, Moorthy M, Long W, Wan Z. Medial protrusio technique for placement of a porous-coated, hemispherical acetabular component without cement in a total hip arthroplasty in patients who have acetabular dysplasia. *J Bone Joint Surg Am* 1999; 81: 83-92.
- Kim YL, Nam KW, Yoo JJ, Kim YM, Kim HJ. Cotyloplasty in cementless total hip arthroplasty for an insufficient acetabulum. *Clin Orthop Surg* 2010; 2: 148-153.
- Karachalios T, Roidis N, Lampropoulou-Adamidou K, Hartofilakidis G. Acetabular reconstruction in patients with low and high dislocation. 20- to 32-year survival of an impaction grafting technique (named cotyloplasty). *Bone Joint J* 2013; 95: 887-892.
- Kim YH, Kim JS. Total hip arthroplasty in adult patients who had developmental dysplasia of the hip. *J Arthroplasty* 2005; 20: 1029-1036.
- Shetty AA, Sharma P, Singh S, Tindall A, Kumar SV, Rand C. Bulk femoral-head autografting in uncemented total hip arthroplasty for acetabular dysplasia: Results at 8 to 11 years follow-up. *J Arthroplasty* 2004; 19: 706-713.
- Gross AE, Allan DG, Catre M, Garbuz DS, Stockley I. Bone grafts in hip replacement surgery. The pelvic side. *Orthop Clin North Am* 1993; 24: 679-695.
- Barrack RL, Newland CC. Uncemented total hip arthroplasty with superior acetabular deficiency. Femoral head autograft technique and early clinical results. *J Arthroplasty* 1990; 5: 159-167.
- Garvin KL, Bowen MK, Salvati EA, Ranawat CS. Long-term results of total hip arthroplasty in congenital dislocation and dysplasia of the hip. A follow-up note. *J Bone Joint Surg Am* 1991; 73: 1348-1354.
- Mulroy RJ, Harris WH. Failure of acetabular autogenous grafts in total hip arthroplasty. Increasing incidence: A follow-up note. *J Bone Joint Surg Am* 1990; 72: 1536-1540.
- Farrell CM, Berry DJ, Cabanela ME. Autogenous femoral head bone grafts for acetabular deficiency in total-hip arthroplasty for developmental dysplasia of the hip: Long-term effect on pelvic bone stock. *J Arthroplasty* 2005; 20: 698-702.
- Li H, Wang L, Dai K, Zhu Z. Autogenous impaction grafting in total hip arthroplasty with developmental dysplasia of the hip. *J Arthroplasty* 2013; 28: 637-643.