

Use of Mitrofanoff and Yang–Monti Techniques as Ureteric Substitution for Severe Schistosomal Bilateral Ureteric Stricture: A Case Report and Review of the Literature

Abubakar Alhaji Bakari, Ibrahim Ahmed Gadam, Suleiman Aliyu, Ibrahim Suleiman, Ahmed A Ahidjo¹, Umaru Hamid Pindiga²

Departments of Surgery, ¹Radiology and ²Histopathology, College of Medical Sciences, University of Maiduguri, Nigeria

ABSTRACT

Distal ureteric stricture is a common complication of urinary schistosomiasis which is a disease more prevalent in the tropics and subtropics. The surgical management of this complication is more challenging when it affects more than half of both ureters. We report the case of a 17-year-old Nigerian with a long standing recurrent painless terminal hematuria associated with bilateral colicky loin pains. Ultrasound scan showed bilateral hydro ureters and hydro nephrosis with deranged biochemical renal function. The patient had bilateral tube nephrostomy and antibiotic therapy. Definitive bilateral ureteric substitution was done using Mitrofanoff technique for the right ureter and Yang–Montie technique for the left ureter. The patient's renal function became normal and he was discharged home without complication. The related literatures were reviewed. Surgical nonurothelial ureteral substitution is necessary for long, extensive, severe bilateral ureteric strictures so as to prevent progressive renal damage and end stage renal failure.

KEYWORDS: Appendix, intestine, schistosomiasis, stricture, ureter, ureteric substitution

INTRODUCTION

Schistosomiasis is one of the most prevalent parasitic infestations worldwide and highly endemic in Africa and Middle East.^[1] Ureteric obstruction as a result of ureteric stricture is a late presentation of severe schistosomal infestation of the urinary tract.^[2] This may be complicated by secondary bacterial infection, renal colic, hydro nephrosis and renal failure.^[1] The ureteric fibrosis is usually bilateral and commonly affects only the distal 1/3 of the ureters but in this case study, more than 1/2 of both ureters were affected. Hence, substitution of these severely fibrosed ureters require a more technically demanding surgical procedure. We report a case of severe schistosomal bilateral long segment ureteric stricture and review of the literature.

Address for correspondence:

Dr. Abubakar Alhaji Bakari,
Department of Surgery, College of Medical Sciences, University of
Maiduguri, PMB 1069, Maiduguri, Nigeria.
E-mail: drabakari@yahoo.com

Access this article online

Quick Response Code:



Website: www.nigerianjsurg.com

DOI:
10.4103/1117-6806.95490

CASE REPORT

A 17-year-old Nigerian presented with 1½ year history of recurrent painless terminal hematuria associated with bilateral loin colicky pains, occasional fever, headache, facial puffiness, and malaise. He was first seen in the referral hospital and had bilateral reimplantation of the ureters seven weeks prior to presentation. The condition of the patient deteriorated, not making urine, hence referred. On admission, the patient was acutely ill looking, febrile, pale with facial puffiness, and bilateral leg edema. Pulse rate was 100 beats per minute, blood pressure of 140/100 mmHg. Chest examination was clinically clear. Abdominal examination revealed bilateral loin tenderness and ballotable kidneys; bowel sounds normoactive and no ascites. Rectal examination was normal. An assessment of acute renal failure with bilateral ureteric obstruction was made. Serum electrolyte, urea and creatinine estimation showed deteriorating renal function. Serum potassium 6.2 mmol/l (3–5), creatinine 344 µmol/l and urea was 24.3 mmol/l (2.5–5.8). Patient was given parenteral ciprofloxacin 200 mg 12 hourly and emergency percutaneous bilateral foley catheter tube nephrostomies were done to relieve the kidneys of back pressure effect. Serial serum electrolyte, urea and creatinine were repeated which showed remarkable improvement in the

renal function; potassium 3.7 mmol/l (3–5), creatinine 90 μ mol/l (44–132), urea 3.6 mmol/l (2.5–5.8). Abdominal ultrasound scan and intravenous urogram [Figure 1] which were done at the referral hospital showed bilateral hydronephrosis and strictures of distal $\frac{3}{4}$ of left and distal $\frac{1}{2}$ of right ureters, respectively, the urinary bladder was normal no calcification. Urine microscopy, culture and sensitivity tests yielded significant growth of proteus species sensitive to ciprofloxacin. Repeated urine culture after 2 weeks of ciprofloxacin treatment yielded no bacterial growth. The patient was prepared for bilateral ureteral augmentation. The preoperative mechanical and antibiotic bowel preparation was done and the procedure was done per abdominal cavity. Through the paracolic gutters the left and right ureters were dissected respectively. The 16-cm fibrosed distal segment of left ureter was excised. A 5-cm segment of ileum was isolated on its pedicle and then divided into three equal parts [Figure 2]. The middle segment was spatulated at the antimesenteric border and, proximal and distal segments were opened very close to their antimesenteric borders, respectively [Figure 3]. The shorter length of all of them were then sutured end to end to get an augmented length of 18 cm of spatulated intestinal ileum which was tabularized over a stent. The proximal end of the tabularized ileum was anastomosed to the proximal end of the ureter, and the distal end anastomosed by Politano–Leadbetter anti-reflux procedure, tunneling the distal 1 cm in to the bladder wall. The 8-cm fibrosed distal segment of right ureter was excised. The appendix was amputated on its pedicle and its tip excised [Figure 4]. The appendix was anastomosed end to end with the proximal ureter and the distal end to the urinary by Politano–Leadbetter antireflux technique. The stents from both substituted ureters [Figure 5] were through the bladder and then to suprapubic region outside [Figure 6]. The peritoneum was lavaged with normal saline and then closed in layers. The histology of the excised fibrosed ureters showed features of severe schistosomiasis [Figure 7]. A course of praziquantel was given to the patient. The patient was discharged from the hospital 4 weeks postoperation and followed up as an outpatient for over a year with stable renal function and without evidence of obstruction.

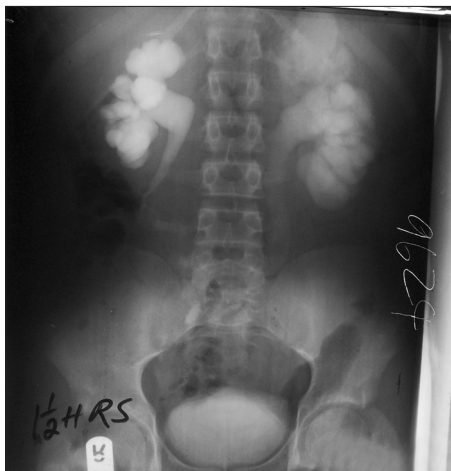

Figure 1: Preoperative intravenous urogram

DISCUSSION

Bilateral distal $\frac{1}{3}$ ureteric obstruction is a common complication of urinary tract Schistosomiasis, a specific trait, *S. haematobium* which causes chronic inflammatory reaction resulting in to ureteral fibrosis.^[1] Idiopathic and tuberculous retroperitoneal fibrosis may give similar ureteral stricture and obstruction.^[2,3] Yeboah *et al.*^[4] also reported $\frac{1}{4}$ and $\frac{1}{3}$ schistosomal ureteric obstructions, in this case we found severe fibrosis of distal $\frac{3}{4}$ of the left and $\frac{1}{2}$ of the right ureters, respectively. Fibrotic ureteral strictures lead to hydroureters and hydronephrosis and dysuria, proteinuria and haematuria are the most common clinical presentation.^[1] Late manifestations include renal colic, ureteral obstructions and hydronephrosis [Figure 1], and renal failure.^[1] Pre-operative anatomical and functional assessments are very important and are best often accomplished by renal ultrasonography, ureteroscopy, Intravenous and retrograde pyelography, and spiral computerized tomography (CT) scanning with delayed contrast views. The degree of ureteric obstruction and relative renal function are best assessed by nuclear renal scanning. In our own setting were able to use the intravenous urogram [Figure 1] and abdomino pelvic ultrasound scan reports from the referral hospital in assessing the patient. Preliminary percutaneous bilateral tube nephrostomy drainages were carried out in order to relieve pressure on the kidneys, and had improved the deteriorating renal function of the patient.^[4] However, we do not have nuclear renal scan in the centre to determine the relative renal function of the kidneys. There are various options of treating benign ureteral strictures, depending on the location and its length, ranging from Ballon dilatation, endoureterotomy to open surgical managements, such as psoas hitch, Boari flap, ureteroneocystostomy, transureteroureterostomy, renal mobilization, autotransplant, and then to laparoscopic and robot-assisted laparoscopic repair.^[5] Long term chemotherapy has also being advocated.^[1,2] A course of Praziquantel and Artemether can be given in order to forestall further progression of the complication and intralesional injection of steroid in long segment strictures has also being advocated.^[1,2,5] The time period for effective chemotherapy required may not be possible in severe ureteral strictures.^[2,5] The patient had a course of praziquantel 40 mg/kg postoperatively. Intestine substitution was the best option for this patient with severe long segment bilateral ureteral strictures [Figure 1]. Both Mitrofanoff and Yang–Monti principles were basically used as urinary diversion for functional and continent stoma both in adults and children.^[6] We used Mitrofanoff's principle by substituting strictured right ureter with the appendix Figure 4 and Yang–Manti's principle on the left. Yang–Monti used 1–2 cm length of small intestine, but in this case, 5 cm of the ileum was prepared and tabularized to make up a length of 18 cm to substitute the left strictured ureter [Figures 2 and 3]. Both techniques were done with no intra or postoperative complications. These techniques were employed in wide arrays of clinical situations but there was no reported case of combining both techniques in substitution of long segment strictured ureters [Figure 5].^[7,8] Staged ureteral substitution would have been considered but due to its attendant morbidity, inability to determine relative function of each kidney and financial

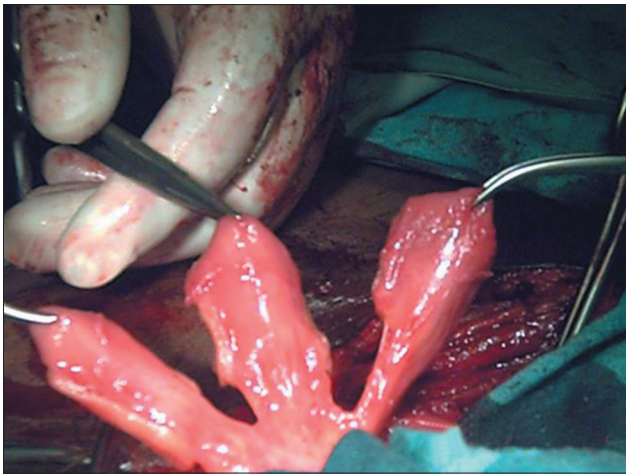


Figure 2: Three segments of intestinal ileum on its mesentery

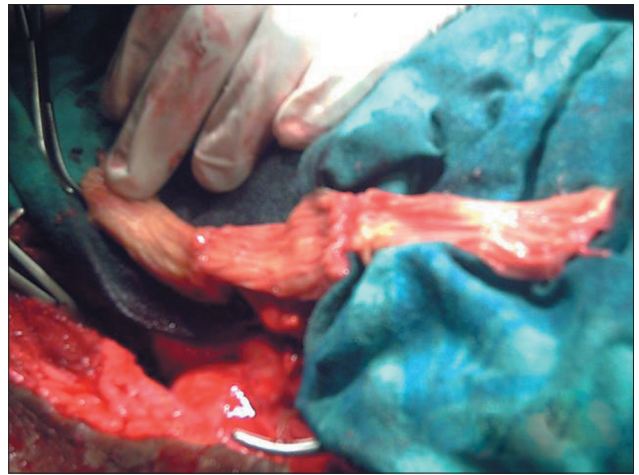


Figure 3: Segments of intestinal ileum lengthened for left ureteric substitution

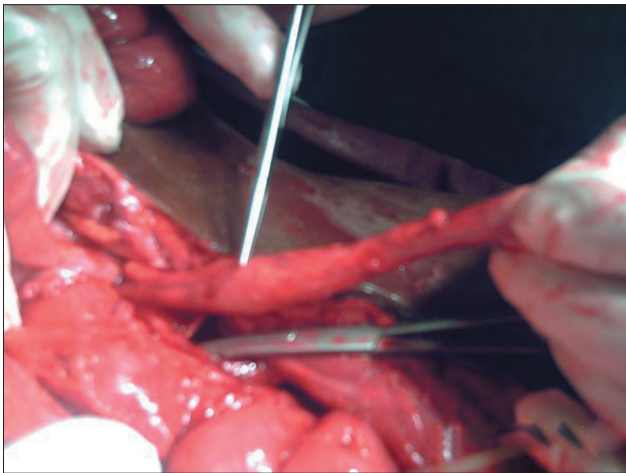


Figure 4: Use of appendix as distal right ureteric substitution

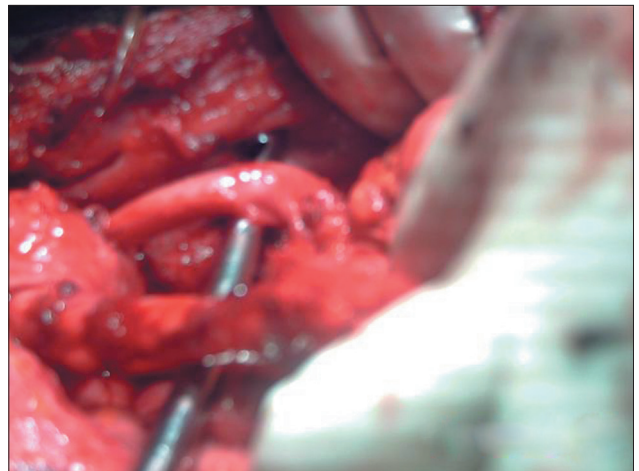


Figure 5: Substituted distal ureters left and right

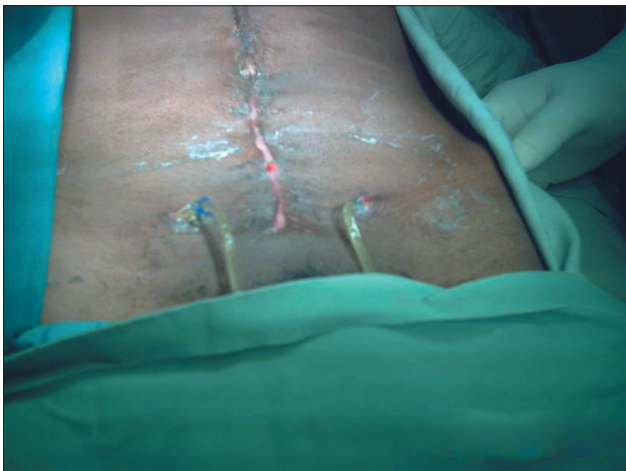

Figure 6: Stents of substituted ureters left and right

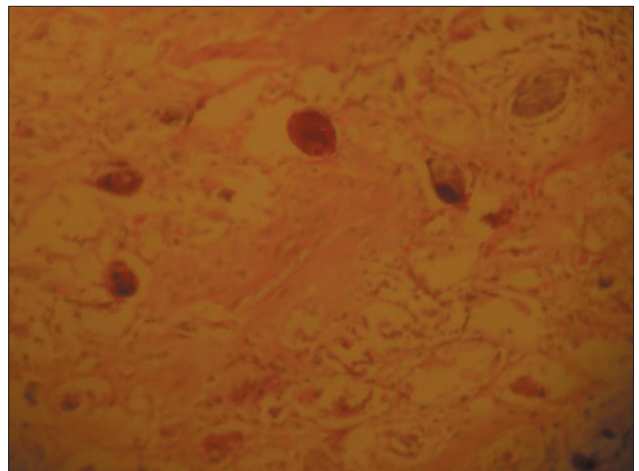


Figure 7: Histology of the excised fibrosed ureters showed features of severe schistosomiasis

constraint, one stage procedure was considered. Options for right ureteric substitution in the absence of appendix include the use of caecum or ascending colon reflected and rotated superiorly to ensure isoperistaltic orientation. Long segment of ileum can also be used from left kidney to the right kidney and then to

the bladder. Long term follow up in some series showed that reconfigured small intestine can equally promote effective efficient urine flow mechanism that persists for long periods with minimal

or no metabolic complications.^[2,4,6,8] The Platino–Leadbetter antireflux technique was done for the bilateral ileal anastomoses to the bladder, however, the usefulness of tunneled anastomoses in adult is probably small because the risk of obstruction is likely to be greater than the risk of reflux. The patient was followed up for over a year and only serum electrolyte, urea and Creatinine, urine microscopy, culture and sensitivity, and abdomino–pelvic ultrasound scan were done which showed no recurrent infection or evidence of obstruction. Patient could not do intravenous urogram due to financial constraint. The future of ureteral stricture management may involve the use of other non urothelial tissues, such as buccal mucosa, as grafts or vascular pedicle flaps.^[9] Other innovative tissue engineering technology, artificial ureter crafted from silicone–polyester and some groups have used xenogenic acellular collagen membranes such as porcine small intestine submucosa for ureteral substitution.^[10]

Transverse tabularized bowel tube is an effective and efficient substitution of severe long segment strictured ureter with sustained good long term results.

REFERENCES

1. Alam K, Maheshwari V, Jain A, Siddiqui FA, Hag ME, Parasad S, *et al.* Schistosomiasis: A case series, with review of literatures. *Internet J Infect Dis* 2009;7:1.
2. Badmos KB, Popoola AA, Buhari MO, Abdulkadir AY. Ureteric

schistosomiasis with obstructive uropathy. *J Coll Physicians Surg Pak* 2009;19:456-8.

3. Muttarak M, ChiangMai WN, Lojanapiwat B. Tuberculosis of the genitourinary tract: Imaging features with pathological correlation. *Singapore Med J* 2005;46:568-74; quiz 575.
4. Yeboah ED. The use of small intestinal segments to replaced diseased bilherzial ureters—a prospective study. *West Afr J Med* 1993;12:162-5.
5. Hafez KS, Wolf JS Jr. Update on minimally invasive management of ureteral strictures. *J Endourol* 2003;17:453-64.
6. Monti PR, de Carvalho JR, Arap S. The Monti procedure: Applications and complications. *Urology* 2000;55:616-21.
7. Shan TP, Vishana K, Ranka P, Shah H, Choudhary R. Mitrofanoff procedure: A versatile method of continent catheterizable urinary diversion. *Indian J Urol* 2002;19:4-8.
8. Ghoneim MA, Ali-El-Dein B. Replacing the ureter by an ileal tube, using the Yang-Monti procedure. *BJU Int* 2005;95:455-70.
9. Pais VM, Strandhoy JW, Assimos DG. Pathophysiology of urinary tract obstruction. In: Wein AJ, Kavoussi LR, Novick AC, Partin AW, Peters CA, editors. *Campbell-Walsh Urology*. 9th ed. Vol. 2. Philadelphia, Pa: WB Saunders; 2007. p. 1195-226.
10. Andonian S, Zorn KC, Paraskevas S, Anidjar M. Artificial ureters in renal transplantation. *Urology* 2005;66:1109.

How to cite this article: Bakari AA, Gadam IA, Aliyu S, Suleiman I, Ahidjo AA, Pindiga UH. Use of mitrofanoff and Yang-Monti techniques as ureteric substitution for severe schistosomal bilateral ureteric stricture: A case report and review of the literature. *Niger J Surg* 2012;18:30-3.

Source of Support: Nil. **Conflict of Interest:** None declared.

Announcement

Android App



Download
**Android
application**

FREE

A free application to browse and search the journal's content is now available for Android based mobiles and devices. The application provides "Table of Contents" of the latest issues, which are stored on the device for future offline browsing. Internet connection is required to access the back issues and search facility. The application is compatible with all the versions of Android. The application can be downloaded from <https://market.android.com/details?id=comm.app.medknow>. For suggestions and comments do write back to us.