



Contents lists available at ScienceDirect

## International Journal of Surgery Case Reports

journal homepage: [www.casereports.com](http://www.casereports.com)

## Adhesive capsulitis of the hip joint in a young female. A case-report

Yahya Alborno<sup>a</sup>, Motasem Salameh<sup>a,\*</sup>, Mohanad Aboulebd<sup>a</sup>, Syed Alam<sup>b</sup>, Ghalib Ahmed<sup>a</sup><sup>a</sup> Department of Orthopedic Surgery, Hamad General Hospital, Hamad Medical Corporation, P.O Box 3050, Arrayan Street, Doha, Qatar<sup>b</sup> Department of Radiology, Hamad General Hospital, Hamad Medical Corporation, P.O Box 3050, Arrayan Street, Doha, Qatar

## ARTICLE INFO

## Article history:

Received 3 June 2020

Accepted 5 August 2020

Available online 15 August 2020

## Keywords:

Adhesive capsulitis

Hip joint

Relaxin

Pregnancy

Case report

## ABSTRACT

**INTRODUCTION:** Adhesive capsulitis of the hip is a rare presenting pathology. History and physical examination are essential for diagnosis. Conservative management is the main line of treatment with surgical intervention preserved for resistant cases.

**PRESENTATION OF CASE:** The authors report a case of young female diagnosed with adhesive capsulitis of the hip with two pain free periods during pregnancy and after arthrogram.

**DISCUSSION:** The relation between the pregnancy hormones and generalized laxity is well established. Animals studies proved the role of female hormones in treatment of adhesive capsulitis of the shoulder.

**CONCLUSION:** Hip pain relief during pregnancy can raise the suspicion of adhesive capsulitis of the hip. Further investigations are needed to prove this relation.

© 2020 Published by Elsevier Ltd on behalf of IJS Publishing Group Ltd. This is an open access article under the CC BY-NC-ND license (<http://creativecommons.org/licenses/by-nc-nd/4.0/>).

## 1. Introduction

Adhesive capsulitis of the hip joint (ACH) is a rare pathology with challenges in the diagnosis and treatment. It was first reported by Caroit et al. [1]. This condition is commonly affecting young women and may be primary (idiopathic), or secondary to hip surgery, hip infection, or repetitive microtrauma [2–5].

ACH is similar to adhesive capsulitis of the shoulder (ACS) with similar clinical and pathological characteristics [6]. It might be self-limiting with spontaneous resolution within 3–18 months. However sometimes it takes longer time [1,3,7,8].

History and clinical examination are the cornerstones of diagnosis. Usually, the pain has an insidious onset, exaggerated with activities. Limitation of active and passive range of motion is a recognized feature in physical examination [2,6]. Laboratory tests and standard image are essential to rule out other diseases [3]. Capsular thickening, especially in the superior and posterior recess of the joint's capsule, might be associated with ACH [4].

This work has been reported in line with the SCARE criteria [9].

## 2. Presentation of case

A 30-year-old house wife presented with a four-year history of left hip pain, which was insidious in onset and progressive. She denied any previous trauma or infection. There were no associated neurological features. Initially, the pain attributed to prolonged or

strenuous exercise, but gradually it progressed to affect the patient at rest and while sleeping. The patient described the pain to be as constant that was exaggerated with walking for few minutes, and laying down over her back. She also described difficulty in getting up from the bed in the morning.

During the four years of symptoms the patient reported two pain-free periods. The first was during her pregnancy in which she was active without any hip pain. The second time was after magnetic resonant arthrogram (MRA), with complete pain relief for two months, however, the pain recurred with higher severity after both periods of pain relief.

On examination there was a limitation of hip range of motion, especially flexion and internal rotation. Stretching the hip at the end of each movement exacerbates the pain, especially in internal rotation and abduction. The examination of the right side was normal. The Blood workup (complete blood count, complete metabolic profile, rheumatoid factor, anti-double-stranded DNA, and anti-nuclear antibodies) were normal. The plain radiograph was normal, (Fig. 1) and MRI study was unremarkable. The MRA showed capsular thickening in most of its parts; anterior 4 mm, posterior 3 mm, superior 3 mm and inferior 2.2 mm, (Figs. 2 and 3).

The capsule thickness was measured by a senior musculoskeletal radiologist and compared to the control group of patients with normal arthrogram finding from Joo, Y.D. et al. study; (anterior; 2.61+0.84, posterior; 1.94+0.57, superior; 1.88+0.53, inferior; 1.84+0.53) [4]. There was no labral tear, cartilage damage, or femoroacetabular impingement. Other causes of hip pain were excluded. The Patient was advised to continue on conservative management including stretching exercises, physical therapy, and non-steroidal anti-inflammatory drugs.

\* Corresponding author.

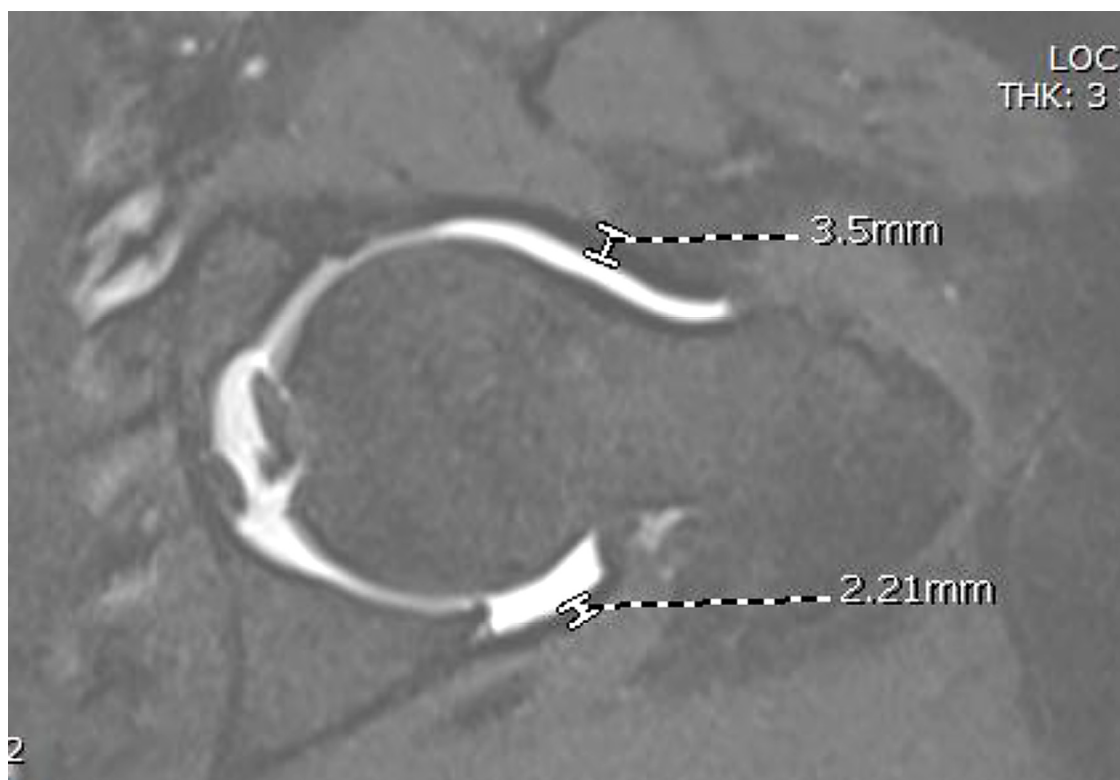
E-mail address: [Msalameh2@hamad.qa](mailto:Msalameh2@hamad.qa) (M. Salameh).

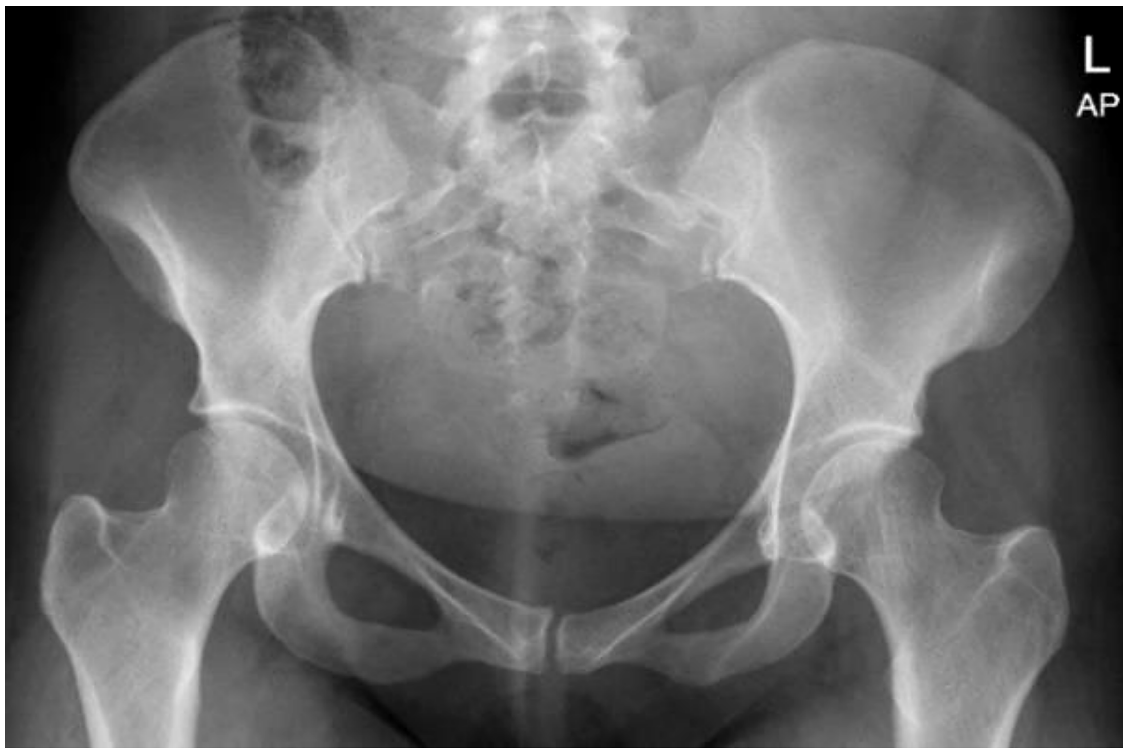

Fig. 1. Anteroposterior pelvis radiograph of the reported case.

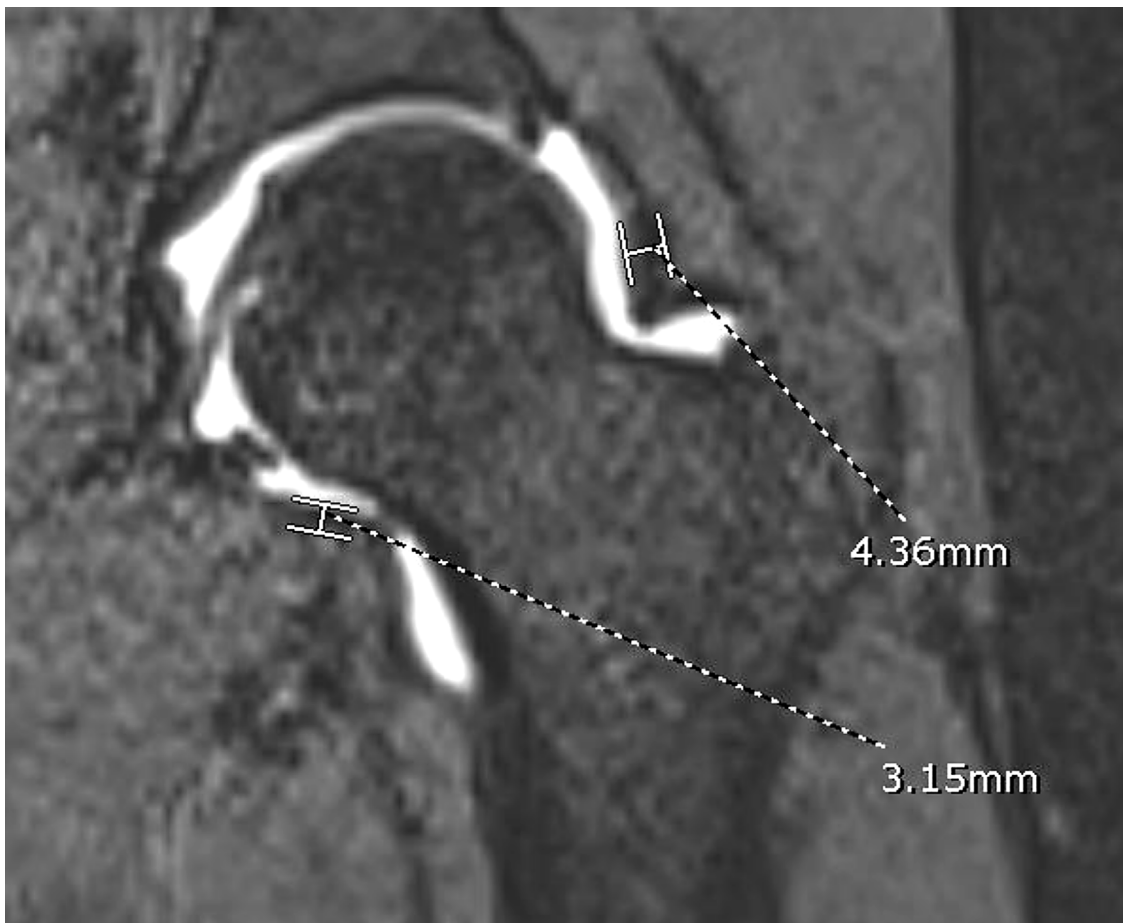

Fig. 2. Magnetic Resonance Arthrogram Coronal images showing superior and inferior capsule.



**Fig. 3.** Magnetic Resonance Arthrogram oblique axial images showing Anterior capsule and posterior capsule.

### 3. Discussion

The authors reported a rare case of left hip adhesive capsulitis in a young female with two pain free periods during pregnancy and after hip arthrogram.

ACH is a poorly understood condition that can occur without any concomitant pathology [2]. The natural history of the disease starts with inflammatory synovitis and ends with chronic fibrosis [3,9]. Exclusion of other hip pathologies essential, MRA can be used if ACH is suspected; Joo YD et al. reported capsular thickening in most of patients with the diagnosis of ACH, especially the superior, and the posterior recess [4].

Conservative management is the first line of treatment. It includes lifestyle modifications, avoiding pain-provoking activities, physical therapy, non-steroidal anti-inflammatory drugs and local steroid injection. Manipulation under anesthesia and pressure dilatation therapy are the second treatment option in recalcitrant cases, and surgical intervention should be considered as the last option [3]. Arthroscopy is considered to be diagnostic as well as a therapeutic tool [2,6].

The reported case described two periods of complete pain relief. First, during her pregnancy the patient had no hip symptoms with full relief without taking any medications. This can be contributed to the hormonal changes during pregnancy and the upregulation of particular proteins such as Relaxin that can lead to soft tissue laxity. The effect of pregnancy on ACH was not reported before in human literature. However, animals' studies showed a role of pregnancy on joint contractures. Ohtera et al. reported a lower trend in joint contractures in pregnant rats compared to none pregnant ones [10]. Jeyabalan et al. reported an upregulation of matrix metalloproteinase (MPP-2), a collagen degrading enzyme, in both pregnant and Relaxin-treated non-pregnant rats [11]. Recently, Blessinga et al. used localized injection of Relaxin in female rats with induced shoulder fibrosis and reported significant improvement of shoulder ROM [12] Second, the improvement after MRA might be due

to stretching and dilatation of the joint's capsule that relieved the pain for a short period [3].

### 4. Conclusion

In conclusion, we report a case of ACH in a young female with temporary complete relief of symptoms during pregnancy. The role of hormones and their effect on adhesive capsulitis need further investigations. A higher level clinical studies are needed to prove the relation of female hormones and adhesive capsulitis.

### Conflicts of interest

The authors declare that they have no conflicts of interest.

### Sources of funding

No source of funding to be declared.

### Ethical approval

Approval for the study was obtained from the Medical Research Center review board (Hamad Medical Corporation, reference number MRC-04-20-190).

### Consent

Written informed consent was obtained from the patient for publication of this case report and accompanying images. A copy of the written consent is available for review by the Editor-in-Chief of this journal on request.

### Author contribution

Yahya Alborno: study concept, data collection, interpretation, writing the first draft, editing the paper, and approved the final version.

Mohanad Aboulebdia: study concept, writing the first draft.

Syed Alam: interpretation, data collection.

Ghalib Ahmed: study concept, interpretation, help writing first draft, editing the paper, approved the final version, and Supervision.

Motasem Salameh: interpretation, help writing first draft, editing the paper, and approved the final version.

### Registration of research studies

NA.

### Guarantor

Yahya Alborno

Motasem Salameh

### Provenance and peer review

Not commissioned, externally peer-reviewed.

### Acknowledgements

We thank the patient for providing consent for this case report.

### References

- [1] M. Caroit, A. Djian, A. Hubault, C. Normandin, S. De Seze, 2 cases of retractile capsulitis of the hip [French], *Rev. Rhum. Mal. Osteoartic.* 30 (1963) 784–789.
- [2] C.G. Looney, B. Raynor, R. Lowe, Adhesive capsulitis of the hip: a review, *J. Am. Acad. Orthop. Surg.* 21 (12) (2013) 749–755, <http://dx.doi.org/10.5435/jaaos-21-12-749>.
- [3] D. de SA, M. Phillips, M. Catapano, N. Simunovic, E.L. Belzile, J. Karlsson, O.R. Ayeni, Adhesive capsulitis of the hip: a review addressing diagnosis, treatment and outcomes, *J. Hip Preserv. Surg.* (2016), <http://dx.doi.org/10.1093/jhps/hnv075>.
- [4] Y.-D. Joo, A.S. Sobti, K.-J. Oh, Measurement of capsular thickness in magnetic resonance arthrography in idiopathic adhesive capsulitis of hip, *Hip Pelvis* (2014), <http://dx.doi.org/10.5371/hp.2014.26.3.178>.
- [5] K.M. Usher, S. Zhu, G. Mavropalias, J.A. Carrino, J. Zhao, J. Xu, Pathological mechanisms and therapeutic outlooks for arthrofibrosis, *Bone Res.* (2019), <http://dx.doi.org/10.1038/s41413-019-0047-x>.
- [6] J.W.T. Byrd, K.S. Jones, Adhesive capsulitis of the hip, *Arthroscopy* (2006), <http://dx.doi.org/10.1016/j.arthro.2005.10.009>.
- [7] R. Luukkainen, E. Sipola, P. Varjo, Successful treatment of frozen hip with manipulation and pressure dilatation, *Open Rheumatol. J.* (2008), <http://dx.doi.org/10.2174/1874312900802010031>.
- [8] M. Lequesne, J. Becker, M. Bard, J. Witvoet, M. Postel, Capsular constriction of the hip: arthrographic and clinical considerations, *Skeletal Radiol.* (1980), <http://dx.doi.org/10.1007/BF00347339>.
- [9] R. Agha, M.R. Borrelli, R. Farwana, K. Koshy, A. Fowler, D.P. Orgill, For the SCARE group, The SCARE 2018 statement: updating consensus surgical CAse REport (SCARE) guidelines, *Int. J. Surg.* 60 (2018) 132–136.
- [10] K. Ohtera, M.E. Zobitz, Z.P. Luo, B.F. Morrey, S.W. O'Driscoll, K.D. Ramin, K.N. An, Effect of pregnancy on joint contracture in the rat knee, *J. Appl. Physiol.* (2002), <http://dx.doi.org/10.1152/jappphysiol.00614.2001>.
- [11] A. Jeyabalan, L.J. Kerchner, M.C. Fisher, J.T. McGuane, K.D. Doty, K.P. Conrad, Matrix metalloproteinase-2 activity, protein, mRNA, and tissue inhibitors in small arteries from pregnant and relaxin-treated nonpregnant rats, *J. Appl. Physiol.* (2006), <http://dx.doi.org/10.1152/jappphysiol.01330.2005>.
- [12] W.A. Blessing, S.M. Okajima, M. Belen Cubria, J.C. Villa-Camacho, M. Perez-Viloria, P.M. Williamson, A.N. Sabogal, S. Suarez, L.H. Ang, S. White, E. Flynn, E.K. Rodriguez, M.W. Grinstaff, A. Nazarian, Intraarticular injection of relaxin-2 alleviates shoulder arthrofibrosis, *Proc. Natl. Acad. Sci. U. S. A.* (2019), <http://dx.doi.org/10.1073/pnas.1900355116>.

### Open Access

This article is published Open Access at [sciencedirect.com](https://www.sciencedirect.com). It is distributed under the [IJSCR Supplemental terms and conditions](#), which permits unrestricted non commercial use, distribution, and reproduction in any medium, provided the original authors and source are credited.