

Prevalence of ulnar-to-median nerve motor fiber anastomosis (Riché-Cannieu communicating branch) in hand: An electrophysiological study

Tannaz Ahadi¹, Gholam Reza Raissi*², Masood Yavari³, Lobat Majidi⁴

Received: 24 May 2015

Accepted: 22 August 2015

Published: 9 February 2016

Abstract

Background: Two main muscles studied in the hand for evaluation of median nerve injuries are opponens pollicis (OP) and abductor pollicis brevis (APB). However, Riché-Cannieu communicating branch (RCCB) may limit the use of these muscles in electrodiagnosis. This condition is confusing in the case of median nerve injuries. This study was conducted to evaluate the prevalence of RCCB.

Methods: Twenty-three consecutive cases of complete median nerve injury were studied. Evoked responses via stimulation of median and ulnar nerves in the wrist and recording with needle in the thenar area were studied.

Results: Of the patients, 82.6% exhibited RCCB. In 14 (60.8%) cases the OP and in 19(82.6%) cases APB was supplied by the ulnar nerve.

Conclusion: RCCB was detected to be 60.8% in OP and 82.6% in APB, so OP is preferable to APB in the study of median nerve.

Keywords: Median Nerve, Electromyography, Ulnar Nerve, Ulnar-to-Median Nerve Anastomosis, Nerve Injury.

Cite this article as: Ahadi T, Raissi GhR, Yavari M, Majidi L. Prevalence of ulnar-to-median nerve motor fiber anastomosis (Riché-Cannieu communicating branch) in hand: An electrophysiological study. *Med J Islam Repub Iran* 2016 (9 February). Vol. 30:324.

Introduction

Riché (1) and Cannieu (2) described a neural connection between the deep branch of the ulnar nerve and the recurrent branch of the median nerve within the thenar eminence (Fig. 1), so it is called Riché-Cannieu communicating branch (RCCB) or Riche-Cannieu anastomosis (RCA). The incidence of RCA is controversial (3). RCCB has been anatomically detected in 0-77% of hands (4-6). However, electrophysiological studies based on surface motor response have detected RCCB in 83.3% of the cases (7).

Misinterpretation of RCCB may cause

several diagnostic problems; for example, in ulnar nerve injury, presence of signs of denervation in the median-innervated muscles, the abductor pollicis brevis (APB), and opponens pollicis (OP) would lead one to suspect the possibility of a C8-T1 or brachial plexus injury (8). Complete median nerve injury accompanied by RCCB may be misinterpreted as partial injury as well.

Previous studies have been based on anatomical findings and surface motor response for assessment of RCCB. The lower percent (77%) (5) of RCCB in anatomical studies compared to electrophysiological studies (7) can be attributed to inability

¹. MD, Assistant Professor of Physical Medicine and Rehabilitation, Firoozgar Hospital, Iran University of Medical Sciences, Tehran, Iran. Tannaz.ahadi@yahoo.com

². (**Corresponding author**) MD, Associate Professor of Physical Medicine and Rehabilitation, Firoozgar Hospital, Iran University of Medical Sciences, Tehran, Iran. Grezaraissi@yahoo.com

³. MD, Associate Professor of Hand and Plastic Surgery, Panzdah Khordad Hospital, Shahid Beheshti University of Medical Sciences, Tehran, Iran. dr.masoudyavari@yahoo.com

⁴. MD, Physical Medicine and Rehabilitation Specialist, Firoozgar Hospital, Iran University of Medical Sciences, Tehran, Iran. Lobat.majidi@gmail.com

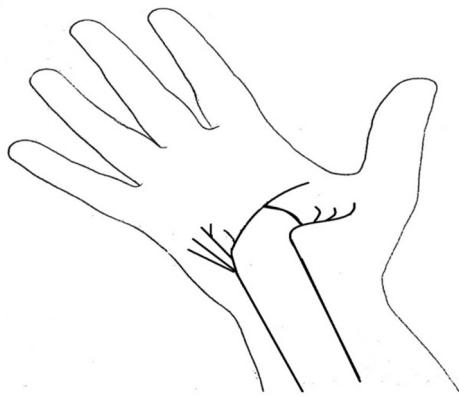


Fig. 1. Riche-Cannieu Communicating Branch

to find nerve fibers in dissections. However, in electrophysiological tests, study of motor response with superficial recording can be problematic. Thenar muscles are innervated by both median and ulnar nerves. Therefore, the recorded response cannot be differentiated specifically with surface recording. In addition, the sensitivity of surface recording is much less than motor evoked response by needle. Moreover, surface stimulation of median nerve at wrist area may co-stimulate ulnar nerve, and this finding cannot be well differentiated with surface recording. Proximal stimulation of median and ulnar nerves from elbow can help overcome this problem. However, in smaller nerve bundles and with increase in the distance, the amplitude of recorded compound muscle action potential (CMP) decreases with associated decrease in test's sensitivity. Furthermore, presence of concomitant RCCB with Martin-Gruber anastomosis may result in problems in interpretation of the findings. Using needle EMG for detection of nerve anastomosis can overcome these problems. This study was conducted to evaluate the accurate prevalence of physiologically proven RCCB.

Methods

Twenty-three consecutive cases of sharp median nerve injury at wrist or 1/3 distal of forearm whose nerve injury was physiolog-

ically complete were studied. Patients were referred to Firoozgar hospital over a period of 21 months from 2012 to 2014. This study was approved by The Ethical Committee of Iran University of Medical Sciences. Patients were informed that in this study two needling sites were used. Written consent was obtained from all the patients. Patients with nerve injury between 2 weeks to one month were selected when Wallerian degeneration was completed and regeneration was less possible. On the other hand, these patients were referral cases whose surgery date has been postponed due to the absence of an experienced surgeon for early nerve repair. We used a two-channel Schwarzer (topas) electrodiagnosis apparatus with sensitivity of 20 $\mu\text{V}/\text{div}$ for sensory with 5 and 2000 Hz filtering, 200mV/div for motor study of median nerve. Sensitivity of 2 mV/div for motor response of ulnar nerve was used. For recording, we used a standard bar electrode with fixed 4 cm inter electrode distance. Median nerve injury was determined by studying sensory and motor responses as well as needle EMG findings in OP and APB. Physiologically complete median nerve lesion was diagnosed through the following methods:

1. Absent compound muscle action potential (CMAP) of median nerve with surface stimulation of the median nerve proximal to wrist crease distal to injury site as well as the elbow and recording thenar eminence by surface electrode with sensitivity of 100 micV/division.
2. Absence of sensory nerve action potential (SNAP) of median nerve, recorded from third digit by surface electrode and stimulation proximal to the wrist crease and distal to injury site with sensitivity of 20 micV/division.
3. Absence of motor evoked response recorded by needle electrode at APB and OP with surface stimulation of median nerve at wrist and elbow level (Fig. 2).

The exclusion criteria were as follows: Those patients with history of previous surgery in the wrist area, concomitant ulnar

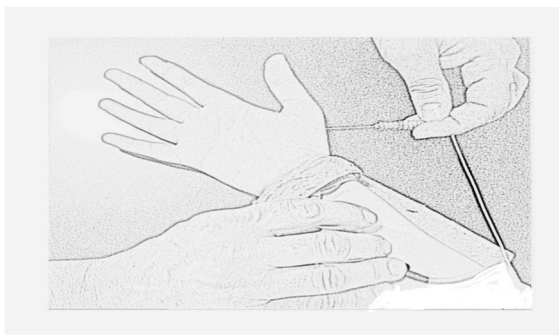


Fig. 2. Motor Evoked Response from APB

nerve lesion, incomplete median nerve lesion, evidence of peripheral neuropathy, thenar and palmar area injury, burn injury, electrical shock injury and injury at distal wrist that posed problems in stimulation of the median nerve distal to the injury site. SNAP of radial and ulnar nerves as well as CMAP of ulnar nerve were studied and recorded to rule out concomitant ulnar nerve lesion or neuropathic process according to the standard protocol (9,10). EMG examination of the APB, OP and first dorsal interosseous (FDI) muscles were performed using concentric needle. The APB was studied by inserting the needle at the radial side of the thenar eminence adjacent to the proximal half of the first metacarpal bone. When studying the OP, the needle was inserted close to the metacarpal bone. Finding obvious positive sharp waves and fibrillation potentials was considered as a positive sign that the needle was in the median injured muscle. If motor units were present in the muscle, the needle was moved toward them until the shortest duration of the motor unit was recorded. Evoked responses with needle recording were evaluated by stimulation of median and ulnar nerves at the wrist. Absence of any response with median stimulation from the wrist (below the injury site) and elbow was considered as complete median nerve injury. Presence of evoked response as a sharp deflection from the baseline in OP and APB with stimulation of the ulnar nerve was considered RCCB. FDI was evaluated to rule out significant ulnar nerve injury.

Results

Twenty-three patients met the inclusion criteria. These included 19 men and 4 women with mean \pm SD age of 29.4 ± 5.6 years. All patients were Iranian. Mechanism of injury was stab wound in 8 (35%) cases and laceration due to glass in 15 (65%) cases. Fourteen injuries (61%) were on the right wrist and nine (39%) on the left wrist. Of these 23 cases with complete median lesion, 60.8% and 82.6% had anastomosis from ulnar nerve in the hand according to the muscles studied. Mean \pm SD amplitude of ulnar nerve sensory action potential in patients with and without anastomosis was 37.3 ± 9.8 and 40.0 ± 10.3 , respectively. Mean \pm SD amplitude of ulnar nerve motor action potential in patients with and without anastomosis was 14.0 ± 0.88 and 13.1 ± 1.7 , respectively. Ulnar motor latency of 3.3 ± 0.6 and antidromic sensory latency of 2.5 ± 0.2 was recorded. There was no contribution from ulnar nerve in 4 (17.4%) cases. In 14 (60.8%) cases, the OP and in 19 (82.6%) cases APB was supplied by the ulnar nerve. Using the chi-square test, the prevalence of ulnar innervation to OP was less than APB ($p < 0.005$).

Discussion

Needle electromyography is the most accurate routine electrodiagnostic tool for evaluation of nerve physiological continuity. Activation of only one motor unit with concentric needle recording produces an evoked response of about 0.6–1.5 mV in normal subjects, so small nerve fibers can be revealed by this method (11). In our study, with needle recording and studying physiologically complete median nerve injured patients, problems with surface recording have been overcome. However, the amplitude of motor evoked potential is of no value in predicting the amount of communicating nerve fibers. Presence of positive sharp wave and fibrillation potential in median innervated muscles was a strong evidence for the fact that needle had not been placed in the ulnar innervated muscles of the thenar area. In addition, absence of

any response with surface stimulation of the median nerve while the needle was inserted to APB and OP was another confirmatory clue to ensure that the needle had been placed correctly. Cross talk by ulnar innervated muscles in the thenar area was lessened by positioning the needle proximal to single or few motor units found in the muscle with denervation potential. The proximity of the needle was determined by placing the needle to the motor units with shortest duration.

However, considering the close proximity of OP and APB as well as atrophy of these muscles in median nerve injury, we could not completely assert that the needle has been inserted in one of these two muscles. Nevertheless, we can compare the approaches of needle insertion, and claim that in needling approach to OP there is less possibility to find RCCB. It must be considered that weakness of the abduction and opposition of the thumb may not be an accurate predictor of median nerve compromise (12-15).

Median to ulnar nerve anastomosis in the forearm is referred to as Martin-Gruber Anastomosis (MGA); concomitant MGA and RCCB has been reported, and we have stimulated median nerve in wrist area. Moreover, MGA is a median to ulnar nerve anastomosis; consequently, the presence of concomitant MGA in our study could not interfere with the results.

The prevalence of RCA is different in different ethnical groups (7). We have studied Iranian patients, and our result is in agreement with that of Kimura (1983). However, our method is different.

Collision technique (16) can be used to study RCA. However, our method is simple and can be used in routine electrodiagnostic studies.

The most common type of RCA is between the ulnar nerve ramus for the flexor pollicis brevis (FPB) and the ramus of the recurrent branch of the median nerve (6). We could not exactly identify FPB by EMG and it is not used routinely in needle EMG studies.

Our study method is the most accurate report of physiologically proven RCCB. Although it has been mentioned that about one third of cases with median nerve lesion at wrist are misinterpreted, this study emphasized that neglect of RCCB in patients with complete median nerve injury can lead to mistake in interpretation of 60.8-82.6% of complete median injury cases. Even in diagnosis of carpal tunnel syndrome, attention to RCCB is of importance (17). For that reason, in all cases of median nerve injury, evoked response recorded by needle at the thenar muscles should be studied. Moreover, OP is preferable to APB in the study of median nerve.

References

1. Riche P. Le nerf cubital et les muscles de l'eminence thenar. Bull Mem Soc Anat Paris 1897; 5:251-2.
2. Canne A. Note sur une anastomose entre la branche profonde du cubital et le median. Bull. Soc. Anat. Physiol. Horm. Path. Bordeaux 1897; 17:339-342.
3. Paraskevas G, Ioannidis O, Martoglou S. Cannieu-Riche anastomosis of the ulnar to median nerve in the hand: case report. Chirurgia 2010; 105:839-842.
4. Budak F, Gönenç Z. Innervation anomalies in upper and lower extremities (an electrophysiological study). Electromyography and clinical neurophysiology 1999;39:231-234
5. Harness D, Sekeles E. The double anastomotic innervation of thenar muscles. Journal of anatomy 1971;109:461.
6. Sarikcioglu L, Sindel M. A variant of the Cannieu-Riche communication: case report. Morphologie: bulletin de l'Association des anatomistes 2002;86:35-37.
7. Kimura I, Ayyar DR, Lippmann SM. Electrophysiological verification of the ulnar to median nerve communications in the hand and forearm. The Tohoku journal of experimental medicine 1983;141(3):269-274.
8. Saperstein D, King R. Motor neuron presentation of an ulnar neuropathy and Riche-Cannieu anastomosis. Electromyography and clinical neurophysiology 2000;40:119-122.
9. Mackenzie K, DeLisa J. Distal sensory latency measurement of the superficial radial nerve in normal adult subjects. Archives of physical medicine and rehabilitation 1981;62(1):31-34.
10. Melvin JL, Harris DH, Johnson EW. Sensory and motor conduction velocities in the ulnar and

median nerves. Archives of physical medicine and rehabilitation 1966;47(8):511-519.

11. Amoiridis G, Vlachonikolis IG. Verification of the median-to-ulnar and ulnar-to-median nerve motor fiber anastomosis in the forearm: an electrophysiological study. Clinical neurophysiology 2003;114:94-98.

12. Clifton EE. Unusual innervation of the intrinsic muscles of the hand by median and ulnar nerve. Surgery 1984;23:12-31.

13. Murphey F, Kirklin JW, Finlayson A. Anomalous innervation of the intrinsic muscles of the hand. Surgery, gynecology & obstetrics 1964; 83:15-23.

14. Refaeian M, King J, Dumitru D, Cuetter A.

Carpal tunnel syndrome and the Riche-Cannieu anastomosis: electrophysiologic findings. Electromyography and clinical neurophysiology 2001;41:377-382.

15. Rowntree T. Anomalous innervation of the hand muscles. Journal of Bone & Joint Surgery 1949;31:505-510.

16. Kimura J. Collision technique Physiologic block of nerve impulses in studies of motor nerve conduction velocity. Neurology 1976;26:680-680.

17. Brown JV1, Landau ME. Sparing of the second lumbrical in a Riche-Cannieu anastomosis: the nearly all-ulnar hand. J Clin Neuromuscul Dis 2013;14(4):184-187.