

Guillain-Barre Syndrome Following SARS-CoV-2 Vaccination: A Case Report

Pricilla Yani Gunawan^{1,2}, Pamela Tiffani¹, Lilie Lalisang^{1,2}

¹Department of Neurology, Faculty of Medicine, Universitas Pelita Harapan, ²Department of Neurology, Siloam Hospital Lippo Village, Tangerang, Indonesia

After more than a year of Coronavirus disease 2019 pandemic, in 2021 Severe Acute Respiratory Syndrome Coronavirus 2 (SARS-CoV-2) vaccination have been made possible and vaccine was distributed globally. Since then, there have been reports of symptoms following SARS-CoV-2 vaccination, including neurological symptoms of ascending paralysis known as Guillain-Barre syndrome. In this report, we describe the first case of Guillain-Barre syndrome following vaccination in Indonesia. Symptoms of ascending paralysis were of late onset after the first dose, however, were full blown after receiving the second dose followed by left-sided facial paralysis.

KEY WORDS: SARS-CoV-2; Vaccination; Guillain-Barre syndrome; Facial paralysis.

INTRODUCTION

Most countries including Indonesia commenced a mass public immunization program against Severe Acute Respiratory Syndrome Corona Virus-2 (SARS-CoV-2) [1]. Vaccination of COVID-19 have been an important subject for the whole year, and despite of its lucid importance in achieving herd immunity, there were concerns about its adverse effects. One of the most disabling and feared neurological adverse event following vaccination is Guillain-Barre syndrome [2].

Guillain-Barre syndrome (GBS) is the most frequent cause of acute flaccid paralysis worldwide since the polio eradication program [2]. It has been reported to have an annual incidence between 0.4 and 4 cases per 100,000 population per year [3]. In children, the incidence was 0.1 case per 100,000 population between the ages of 5 and 14 years, and 0.62 per 100,000 population between the ages of 10 and 19 years [4]. GBS is described as various subtypes including Acute Inflammatory Demyelinating

Polyradiculoneuropathy (AIDP), Acute Motor Axonal Neuropathy and Miller Fisher syndrome [5].

In children, recovery is more rapid and tends to be complete with fatalities rare, whereas in elderly prognosis is worse, mostly requiring mechanical ventilation. Severe weakness at nadir and rapid onset of weakness have been identified as adverse prognostic factors. Treatment with either plasmapheresis or intravenous immunoglobulin has been shown to improve outcome, and these are considered the gold standard for treatment, although data are lacking for treatment in children [2]. GBS after SARS-CoV-2 vaccination have been reported across all vaccine platforms, but not much came from the CoronaVac vaccine. Here, we reported a case of GBS after the first dose of CoronaVac COVID-19 vaccination, followed by a left-sided Bell's Palsy after the second dose.

Patient written consent for publication was obtained. This study has ethical approval from Universitas Pelita Harapan No: 118/K-LK)/ETIK/III/2022.

CASE

A 14-year-old male came to the neurophysiology clinic with a history of progressive bilateral upper and lower limb weakness 3 weeks prior to admission. There were no

Received: March 15, 2022 / **Accepted:** April 2, 2022

Address for correspondence: Pricilla Yani Gunawan

Department of Neurology, Faculty of Medicine, Universitas Pelita Harapan, Jl. Jend. Sudirman No.20, Tangerang 15810, Indonesia

E-mail: pricilla.gunawan@uph.edu

ORCID: <https://orcid.org/0000-0002-5620-3267>

© This is an Open-Access article distributed under the terms of the Creative Commons Attribution Non-Commercial License (<http://creativecommons.org/licenses/by-nc/4.0>) which permits unrestricted non-commercial use, distribution, and reproduction in any medium, provided the original work is properly cited.

history of diarrhoea, respiratory tract infection, and consumption of medications. He had received the first and second dose of CoronaVac COVID-19 vaccine 7 weeks and 3 weeks before. Two days before the second dose (3 weeks after the first), he felt tingling sensations on his fingertips. Weakness appeared a day after the second dose, which started as difficulty moving both legs and arms, along with numbness on hands and feet. Weakness and numbness became worse the next 5 days, and he was ad-

mitted to the nearest hospital. There were no data of cerebrospinal fluid analysis. On the second day after admission, there was drooping on the left side of his mouth, and his left eyelid could not close tightly. Following 2 weeks of hospital care, facial drooping and eyelid weakness showed marked improvement. Numbness and weakness became less, and he could walk unassisted. He did not obtain plasmapheresis or intravenous immunoglobulin and was on supportive therapy.

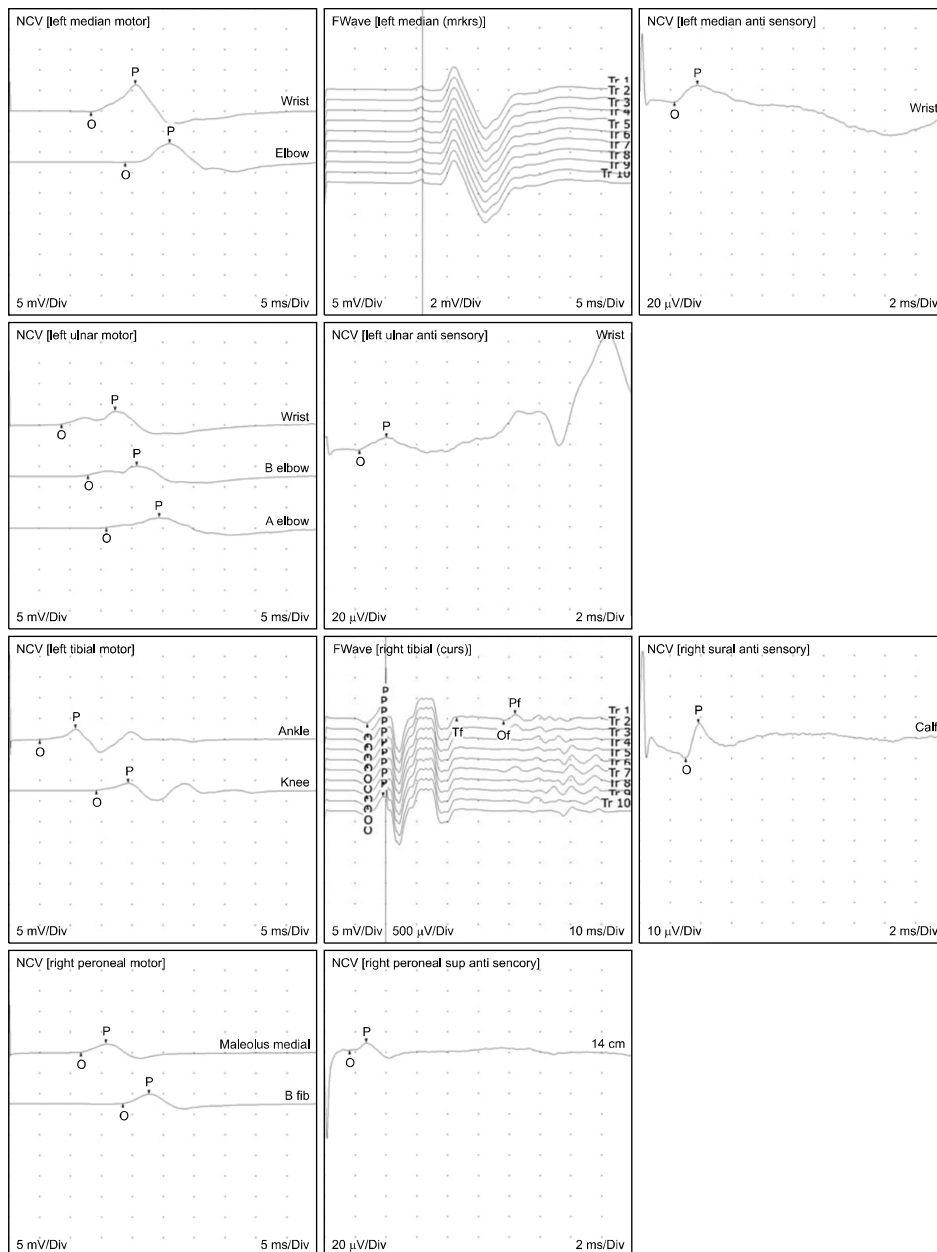


Fig. 1. Electroneurography showing distal symmetrical demyelinating motor polyradiculoneuropathy of the tibial, peroneal, median and ulnar nerves. NCV, nerve conduction velocity; O, onset; P, peak.

Upon arrival on our clinic, vital signs were within normal limits. Distal limbs showed minimal weakness, whereas proximal limbs were normal. Muscle stretch reflexes were absent and general somatic sensations were unremarkable. Electroneurography showed prolonged distal onset latency in all peripheral nerves which is consistent with AIDP (Fig. 1).

DISCUSSION

Guillain-Barre syndrome is defined as an acute or sub-acute immune-mediated polyradiculoneuropathy characterized by varying degrees of limbs or cranial-nerve weakness, sensory and dysautonomia symptoms due to peripheral nerves and root demyelination with or without axonal damage [3,6]. In two thirds of cases, neurological symptoms appeared several days up to 4 weeks after an upper respiratory tract infection or diarrhoea [7]. GBS was associated with several bacteria and virus [8-14], and most recently, the SARS-CoV-2. Other stimuli that appear to be temporally associated with GBS include some malignancies and various vaccines including SARS-CoV-2 [1,5,13-17].

Patients who develop GBS in association with SARS-CoV-2 typically occurred within 2 weeks of infection [6,18-22]. In our case, first symptoms of GBS were more than 3 weeks after the first dose, which is consider as late onset. It is commonly accepted that the association between vaccination and GBS was speculative or coincidental [7]. However, although the underlying aetiology and pathophysiology of GBS are not completely understood, immune stimulation was convinced to play a role in its pathogenesis [5]. Immunization had potentially stimulated the immune system to produce antigen-specific humoral and/or cellular immunity leading to ascending paralysis [23,24]. Several possible mechanisms theoretically result in GBS through vaccination were: (1) molecular mimicry involving a situation in which the epitopes of a live or attenuated vaccine could initiate the development of antibodies and/or T cells that could cross-react with epitopes on myelin or axonal glycoproteins of peripheral nerves; (2) axonal or myelin membranes presumably destroyed by vaccine virus or vaccine-associated products, or direct infection and damage of surrounding supporting cells by virus, leading to insertion of virus-specified polypeptides into host cell membranes; and (3) predisposition of host factors (human leukocyte antigen) and genetic poly-

morphisms [24-27]. At least two from five previous reports have highlighted the development of GBS after CoronaVac COVID-19 vaccine [13-16,28]. Besides of ascending paralysis, patient experienced left-sided lower motor neuron facial weakness a week after the second dose [27,31,32]. Previously, data of Bell's palsy occurring after SARS-CoV-2 vaccination were after the first dose [5,16,27,29-31]. Rapid and excellent recovery of limb and facial paralysis in this case was feasibly due to young age.

To our knowledge, this is the first published report of GBS after SARS-CoV-2 vaccination in Indonesia. Although benefit of vaccination outweighs risk of contracting the virus (which has a higher probability of developing GBS), it should be highlighted that patients with history of sensorimotor disturbance after the first dose warrants vigilance and should be under surveillance should the second dose be administered.

■ Funding

None.

■ Conflicts of Interest

No potential conflict of interest relevant to this article was reported.

■ Author Contributions

Conceptualization: Pricilla Yani Gunawan, Pamela Tiffani. Data acquisition: Pricilla Yani Gunawan, Pamela Tiffani, Lilie Lalisang. Supervision: Pricilla Yani Gunawan. Writing – original draft: Pricilla Yani Gunawan, Pamela Tiffani. Writing – review and editing: Pricilla Yani Gunawan.

■ ORCID

Pricilla Yani Gunawan

<https://orcid.org/0000-0002-5620-3267>

Pamela Tiffani

<https://orcid.org/0000-0001-6053-0183>

Lilie Lalisang

<https://orcid.org/0000-0002-0919-8020>

REFERENCES

1. Finsterer J. *Exacerbating Guillain-Barré syndrome eight days after vector-based COVID-19 vaccination. Case Rep Infect Dis* 2021;2021:3619131.
2. Yuki N, Hartung HP. *Guillain-Barré syndrome. N Engl J Med* 2012;366:2294-2304. *Erratum in: N Engl J Med* 2012;367:1673.
3. Hughes RA, Rees JH. *Clinical and epidemiologic features of Guillain-Barré syndrome. J Infect Dis* 1997;176 Suppl 2:S92-S98.
4. Winner SJ, Evans JG. *Age-specific incidence of Guillain-Barré*

- syndrome in Oxfordshire. Q J Med 1990;77:1297-1304.*
5. Haber P, Sejvar J, Mikaeloff Y, DeStefano F. *Vaccines and Guillain-Barré syndrome. Drug Saf 2009;32:309-323.*
 6. Padroni M, Mastrangelo V, Asioli GM, Pavolucci L, Abu-Rumeileh S, Piscaglia MG, et al. *Barré syndrome following COVID-19: new infection, old complication? J Neurol 2020; 267:1877-1879.*
 7. Poropatich KO, Walker CL, Black RE. *Quantifying the association between Campylobacter infection and Guillain-Barré syndrome: a systematic review. J Health Popul Nutr 2010;28: 545-552.*
 8. Hadden RD, Karch H, Hartung HP, Zielasek J, Weissbrich B, Schubert J, et al. *Preceding infections, immune factors, and outcome in Guillain-Barré syndrome. Neurology 2001;56: 758-765.*
 9. Fokke C, van den Berg B, Drenthen J, Walgaard C, van Doorn PA, Jacobs BC. *Diagnosis of Guillain-Barré syndrome and validation of Brighton criteria. Brain 2014;137(Pt 1):33-43.*
 10. Orlikowski D, Porcher R, Sivadon-Tardy V, Quincampoix JC, Raphaël JC, Durand MC, et al. *Guillain-Barré syndrome following primary cytomegalovirus infection: a prospective cohort study. Clin Infect Dis 2011;52:837-844.*
 11. Kang JH, Sheu JJ, Lin HC. *Increased risk of Guillain-Barré syndrome following recent herpes zoster: a population-based study across Taiwan. Clin Infect Dis 2010;51:525-530.*
 12. Lunn MP, Cornblath DR, Jacobs BC, Querol L, van Doorn PA, Hughes RA, et al. *COVID-19 vaccine and Guillain-Barré syndrome: let's not leap to associations. Brain 2021;144:357-360.*
 13. Woo EJ, Mba-Jonas A, Dimova RB, Alimchandani M, Zinderman CE, Nair N. *Association of receipt of the Ad26.COVS.2 COVID-19 vaccine with presumptive Guillain-Barré syndrome, February-July 2021. JAMA 2021;326:1606-1613.*
 14. Finsterer J, Scorza FA, Scorza CA. *Post SARS-CoV-2 vaccination Guillain-Barre syndrome in 19 patients. Clinics (Sao Paulo) 2021;76:e3286.*
 15. Allen CM, Ramsamy S, Tarr AW, Tighe PJ, Irving WL, Tanasescu R, et al. *Guillain-Barré syndrome variant occurring after SARS-CoV-2 vaccination. Ann Neurol 2021;90:315-318.*
 16. McKean N, Chircop C. *Guillain-Barré syndrome after COVID-19 vaccination. BMJ Case Rep 2021;14:e244125.*
 17. Arce Gálvez L, Ramírez Abadía LA, de los Reyes Guevara CA, Hernández Orozco JF. *[Guillain-Barre syndrome after vaccination for COVID-19. The first report in Latin America]. Neurol Perspect 2021;1:236-238. Latin.*
 18. Toscano G, Palmerini F, Ravaglia S, Ruiz L, Invernizzi P, Cuzzoni MG, et al. *Guillain-Barré syndrome associated with SARS-CoV-2. N Engl J Med 2020;382:2574-2576.*
 19. Sedaghat Z, Karimi N. *Guillain Barre syndrome associated with COVID-19 infection: a case report. J Clin Neurosci 2020;76:233-235.*
 20. Virani A, Rabold E, Hanson T, Haag A, Elrufay R, Cheema T, et al. *Guillain-Barré syndrome associated with SARS-CoV-2 infection. IDCases 2020;20:e00771.*
 21. Alberti P, Beretta S, Piatti M, Karantzoulis A, Piatti ML, Santoro P, et al. *Guillain-Barré syndrome related to COVID-19 infection. Neurol Neuroimmunol Neuroinflamm 2020;7:e741.*
 22. Aladawi M, Elfil M, Abu-Esheh B, Abu Jazar D, Armouti A, Bayoumi A, et al. *Guillain Barre syndrome as a complication of COVID-19: a systematic review. Can J Neurol Sci 2022;49: 38-48.*
 23. Shoenfeld Y, Aron-Maor A. *Vaccination and autoimmunity- 'vaccinosis': a dangerous liaison? J Autoimmun 2000;14:1-10.*
 24. Chen RT, DeStefano F, Pless R, Mootrey G, Kramarz P, Hibbs B. *Challenges and controversies in immunization safety. Infect Dis Clin North Am 2001;15:21-39, viii.*
 25. McCombe PA, Csurhes PA, Greer JM. *Studies of HLA associations in male and female patients with Guillain-Barré syndrome (GBS) and chronic inflammatory demyelinating polyradiculoneuropathy (CIDP). J Neuroimmunol 2006;180:172-177.*
 26. Caporale CM, Papola F, Fioroni MA, Aureli A, Giovannini A, Notturmo F, et al. *Susceptibility to Guillain-Barré syndrome is associated to polymorphisms of CD1 genes. J Neuroimmunol 2006;177:112-118.*
 27. Jin PP, Sun LL, Ding BJ, Qin N, Zhou B, Xia F, et al. *Human leukocyte antigen DQB1 (HLA-DQB1) polymorphisms and the risk for Guillain-Barré syndrome: a systematic review and meta-analysis. PLoS One 2015;10:e0131374.*
 28. Patone M, Handunnetthi L, Saatci D, Pan J, Katikireddi SV, Razvi S, et al. *Neurological complications after first dose of COVID-19 vaccines and SARS-CoV-2 infection. Nat Med 2021;27:2144-2153. Erratum in: Nat Med 2021;27:2249.*
 29. Wan EYF, Chui CSL, Lai FTT, Chan EWY, Li X, Yan VKC, et al. *Bell's palsy following vaccination with mRNA (BNT162b2) and inactivated (CoronaVac) SARS-CoV-2 vaccines: a case series and nested case-control study. Lancet Infect Dis 2022; 22:64-72.*
 30. Kuitwaard K, Bos-Eyssen ME, Blomkwist-Markens PH, van Doorn PA. *Recurrences, vaccinations and long-term symptoms in GBS and CIDP. J Peripher Nerv Syst 2009;14:310-315.*
 31. Burrows A, Bartholomew T, Rudd J, Walker D. *Sequential contralateral facial nerve palsies following COVID-19 vaccination first and second doses. BMJ Case Rep 2021;14:e243829.*