

A life-threatening spontaneous ascending aortic rupture due to a small penetrating aortic ulcer

SAGE Open Medical Case Reports
Volume 9: 1–3
© The Author(s) 2021
Article reuse guidelines:
sagepub.com/journals-permissions
DOI: 10.1177/2050313X211037784
journals.sagepub.com/home/sco



Yasuhito Nakamura¹, Kiyoshi Doi, Syojiro Yamaguchi, Etsuji Umeda, Osamu Sakai and Katsuya Shimabukuro

Abstract

We reported a rare case of spontaneous frank rupture of a small (4 mm) penetrating aortic ulcer in the ascending aorta resulted in catastrophic bleeding. The ulcer only created a pinhole wound in the adventitia without saccular aneurysms, intramural hematomas, or aortic dissections. Notably, the wound could be directly closed because the aortic wall was intact only 5 mm away from the bleeding site. The postoperative course was uneventful, and the patient was discharged on the 11th postoperative day. After 8 months, follow-up computed tomography showed no abnormality of the aortic wall at the repair site.

Keywords

Spontaneous rupture, ascending aorta, penetrating atherosclerotic ulcer

Date received: 3 March 2021; accepted: 20 July 2021

Introduction

We report a rare case of spontaneous frank rupture of a small (4 mm) penetrating aortic ulcer (PAU) in the ascending aorta that resulted in catastrophic bleeding. The ulcer only created a pinhole wound in the adventitia and did not accompany saccular aneurysms, intramural hematomas, or aortic dissections. To our knowledge, this is the smallest spontaneously ruptured PAU to be reported in the literature.^{1–4}

Case report

An 80-year-old man, who experienced sudden chest pain, was transferred to our emergency unit. There was no indication of recent trauma.

He was in cardiogenic shock at the time of admission. Echocardiography revealed a moderate amount of pericardial effusion, while contrast-enhanced computed tomography (CT) revealed extravasation of contrast media from the distal ascending aorta; this created a massive hematoma in the anterior mediastinum and right hemothorax (Figure 1(a)). The ascending aorta was slightly dilated (37 mm). There was a focal contrast-filled outpouching on the anterior aspect of the aorta in the absence of a dissecting flap, false lumen, or aortic aneurysm. The bleeding point was surrounded by multiple

calcified plaques (Figure 1(b)). Although the etiology of bleeding could not be determined, emergency surgery was performed.

The mediastinal space and right thoracic cavity were filled with fresh blood coagulation, but the pericardial space did not contain obvious blood. Upon coagulation removal, blood spurting from a 2-mm hole located on the anterior wall of the distal ascending aorta (Figure 2(a)). Although there were small lacerations in the adventitia, we did not observe any saccular aneurysm formations. Epiaortic echocardiography revealed a PAU (4 mm in diameter), with subsequent penetration into the media and adventitia, which resulted in a frank rupture of the aorta (Figure 3).

We closed the pinhole directly with 3-0 interrupted sutures and Teflon felt strips (Figure 2(b)). After 8 months, follow-up CT showed no abnormality of the aortic wall at the repair site.

Department of Cardiovascular Surgery, School of Medicine, Gifu University, Gifu, Japan

Corresponding Author:

Yasuhito Nakamura, Department of Cardiovascular Surgery, School of Medicine, Gifu University, 1-1 Yangido, Gifu 501-1193, Japan.
Email: g501g434@gifu-u.ac.jp



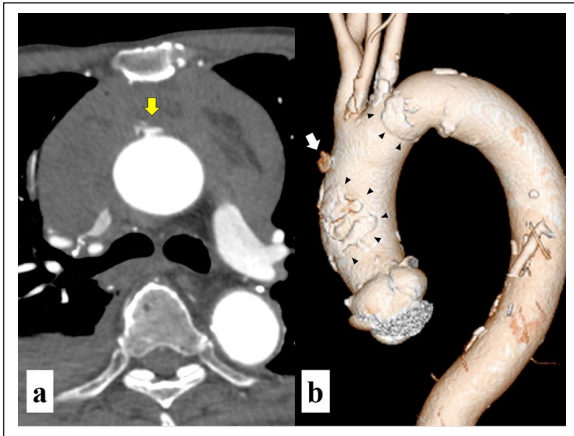


Figure 1. (a) CT reveals the extravasation of contrast media from the ascending aorta (yellow arrow) that created a large hematoma in the anterior mediastinum and right hemithorax. (b) The bleeding point (white arrow), located at the distal ascending aorta, is surrounded by multiple calcium plaques (black arrowheads).

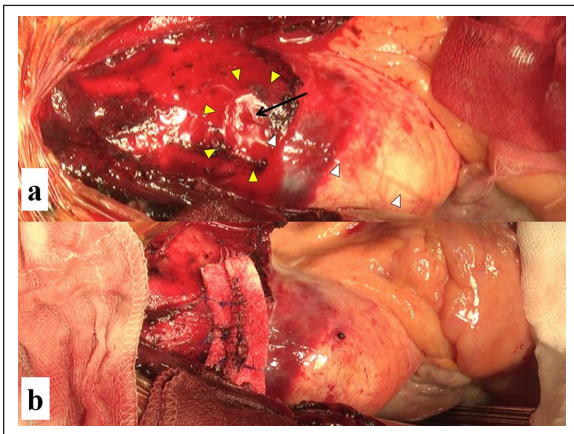


Figure 2. (a) Intraoperative view. Blood (white arrowhead) is leaking from a wound (arrow) on the distal ascending aorta. There is a small laceration around the wound (yellow arrowhead). (b) The wound is directly closed with 3-0 sutures and felt strips.

Discussion

PAUs, which are small intimal erosions of the aorta, are now believed to be potential risk factors for aortic ruptures.¹ PAU is often found in elderly men with severe cardiovascular comorbidities such as coronary, cerebral, and peripheral artery disease. Occasionally, the atheromatous ulcer can burrow into the aortic wall and penetrate through the internal elastic lamina into the media, leading to aortic wall dissections or pseudoaneurysms. Conversely, there have been a few reports of PAUs penetrating through the whole aortic wall, causing frank ruptures.^{2,3}

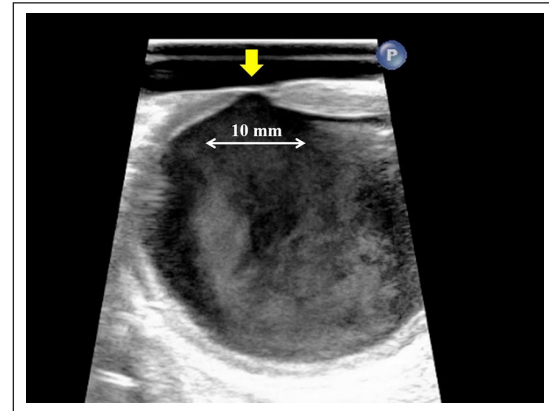


Figure 3. Epaortic echocardiography demonstrates intimal ulceration (arrow) with subsequent penetration into the media and adventitia. However, neither aortic dissection nor intramural hematoma was observed adjacent to the ulcer.

In this case, the patient had severe calcification of the aorta. No aortic wall thickening or adhesions suggesting previous inflammation were observed. In addition, preoperative CT and intraoperative epiaortic echocardiography showed no evidence of aortic dissection, intramural hematoma, or aortic aneurysm. Therefore, PAU seemed to be the cause of the spontaneous rupture of the ascending aorta.

Because of the fragility of the arterial wall, ruptured site resections and vascular replacements are desirable. However, our patient had extreme calcification of the aorta and multiple comorbidities. The bleeding point was small, and the wall structure of the aorta was normal except for the area 5 mm around the bleeding site. Therefore, we decided to close the wound by direct suture. We agreed that the replacement of the ascending aorta was a reasonable surgical option. However, long cardiopulmonary bypass time with hypothermic circulatory arrest was very likely to compromise the patient's activity of daily living. Because follow-up CT did not show any recurrent adverse aortic wall abnormality, our decision seemed to be acceptable.

Current guidelines recommend early surgical intervention in asymptomatic patients with PAUs of a diameter >20 mm and a neck >10 mm.⁵ However, this recommendation is based on the natural history of PAUs in the descending and abdominal aorta (type B).⁴ Little is known about the natural history of PAUs in the ascending aorta (type A) because they occur far less frequently. However, previous case reports suggested that type A PAUs are more virulent than type B because ulcers with diameters of <20 mm could rupture.^{2,3} In this case, a 4-mm PAU created a pinhole wound in the adventitia without saccular aneurysm development, resulting in catastrophic bleeding.

Conclusion

Although treatment strategies for asymptomatic type A PAU accidentally found remain controversial, this report

demonstrated that early surgical intervention might be acceptable, even if ulcer size is small.

Acknowledgements

The authors thank Editage (www.editage.jp) for English language editing.

Declaration of conflicting interests

The author(s) declared no potential conflicts of interest with respect to the research, authorship, and/or publication of this article.

Ethical approval

Our institution does not require ethical approval for reporting individual cases or case series.

Funding

The author(s) received no financial support for the research, authorship, and/or publication of this article.

Informed consent

Written informed consent was obtained from the patient for his anonymized information to be published in this article.

ORCID iD

Yasuhiro Nakamura  <https://orcid.org/0000-0003-1030-1643>

References

1. Chou AS, Ziganshin BA, Charilaou Tranquilli M, et al. Long-term behavior of aortic intramural hematomas and penetrating ulcers. *J Thorac Cardiovasc Surg* 2016; 151(2): 361–373.
2. Srettabunjong S. Ascending aortic rupture through a penetrating atherosclerotic ulcer: a rare cause of sudden unexpected death. *J Forensic Sci* 2018; 63(2): 608–610.
3. Liu YH, Ke HY, Lin YC, et al. A penetrating atherosclerotic ulcer rupture in the ascending aorta with hemopericardium: a case report. *J Cardiothorac Surg* 2016; 11: 103.
4. Ganaha F, Miller C, Sugimoto K, et al. Prognosis of aortic intramural hematoma with and without penetrating atherosclerotic ulcer: a clinical and radiological analysis. *Circulation* 2002; 106: 342–348.
5. Czerny M, Schmidli J, Adler S, et al. Current options and recommendations for the treatment of thoracic aortic pathologies involving the aortic arch: an expert consensus document of the European Association for Cardio-Thoracic surgery (EACTS) and the European Society for Vascular Surgery (ESVS). *Eur J Cardiothorac Surg* 2019; 55: 133–162.