



Case report

Youngest reported Seasonal Hyperacute Panuveitis case

Ranju Kharel (Sitaula)^{a,*}, Pratap Karki^a, Sagun Nayayan Joshi^a, Ananda K. Sharma^a,
Madan P. Upadhyay^b

^a Department of Ophthalmology, Maharajgunj Medical Campus, Tribhuvan University, Institute of Medicine, B. P. Koirala Lions Centre for Ophthalmic Studies, Maharajgunj, Kathmandu, Nepal

^b Chair Emeritus B. P. Eye Foundation, CHEERS, Lokanthali, Kathmandu, Nepal

ARTICLE INFO

Keywords:

Intravitreal injection
Leukocoria
Moth
SHAPU
Vitrectomy

ABSTRACT

Purpose: Seasonal Hyperacute Panuveitis (SHAPU) is a mysterious but rapidly devastating intraocular inflammatory disease reported only from Nepal during odd years after monsoon. Though it predominantly affects children, it has been reported between 9 months and 50 years age. But herein, we report a case of SHAPU in a 38-days-baby during 2017 SHAPU outbreak.

Observations: Parents of a 38-days-healthy male baby from Pokhara noticed redness in child's right eye since 5 days (October 2017). They noticed the fall of a white moth from the tubelight over the child's face 1-day prior to symptom onset. On examination, both eyes followed and fixated at light. The right eye was congested with dense anterior chamber reaction and white pupillary reflex obscuring the glow of the retina. Ultrasonography showed hyperechoic vitreous shadows with choroidal thickening. Left eye was normal. The child underwent vitreous tap with core vitrectomy + lensectomy with intravitreal antibiotics and steroid IGA. The blood investigations were normal and the vitreous sample yielded no organism growth. Viral PCR analysis was negative. The intraocular inflammation decreased and fundal glow was visible.

Conclusions: AND IMPORTANCE: SHAPU can occur in a child as young as 38 days. Link with moth remains the strongest suspect.

1. Introduction

Seasonal hyperacute panuveitis (SHAPU) is a unique, most rapidly destructive intraocular inflammatory disease reported only from Nepal soon after monsoon season of 1975.¹ It occurs in epidemic form beginning with end of monsoon (August–September) and usually ending with peaking of winter in December–January.^{2,3} The children are the predominant victim of this disease and the youngest affected child is reported as 9-month-baby.¹ But herein we report the occurrence of SHAPU in a 38-day-infant, the youngest case of SHAPU till date.

2. Case report

Parents of a 38-days-healthy male baby from Pokhara noticed redness in child's right eye since 5 days during October 2017 (Fig. 1). There was no previous history of febrile illness, trauma and hospitalization. He was vaccinated for Bacillus Calmette–Guérin (BCG) vaccine against tuberculosis on the second day of birth. During evening hours, they noticed the fall of a white moth from the tubelight over the child's face

1-day prior to symptom onset. Mild erythema over that area with redness of eye of same side was identified the following day. The red eye was initially ignored but as the parents noted whitish reflex from the affected eye, they rushed to the capital city and presented at our eye centre on 5th day.

On examination, both eyes followed and fixated at light. The right eye was congested with dense anterior chamber reaction and white pupillary reflex obscuring the glow of the retina (Fig. 2). Ultrasonography showed hyperechoic vitreous shadows with choroidal thickening (Fig. 3A). Left eye was normal.

Same day examination under general anesthesia (EUA) done and intraocular pressure measurement with Perkins tonometer showed 10 and 13 mmHg in each eye. The child underwent RE aqueous tap and vitreous tap followed by core vitrectomy with 23G needle along with posterior capsulotomy and lens aspiration. As per our SHAPU treatment protocol, for gram positive and gram negative coverage; RE Intravitreal Vancomycin (1 mg/0.1 ml) + Ceftazidime (2.25mg/0.1ml) was given along with Dexamethasone injection (0.4mg/0.1ml) for the control of the inflammation due to toxins released. Subconjunctival Vancomycin

* Corresponding author.

E-mail addresses: helloranju50@gmail.com (R. Kharel (Sitaula)), karkipratap@gmail.com (P. Karki), sagun.j3@gmail.com (S.N. Joshi), dr.anandasharma@gmail.com (A.K. Sharma), madanupadhyay@hotmail.com (M.P. Upadhyay).

<https://doi.org/10.1016/j.ajoc.2019.100523>

Received 30 January 2019; Received in revised form 5 June 2019; Accepted 17 July 2019

Available online 19 July 2019

2451-9936/ © 2019 The Authors. Published by Elsevier Inc. This is an open access article under the CC BY-NC-ND license (<http://creativecommons.org/licenses/by-nc-nd/4.0/>).

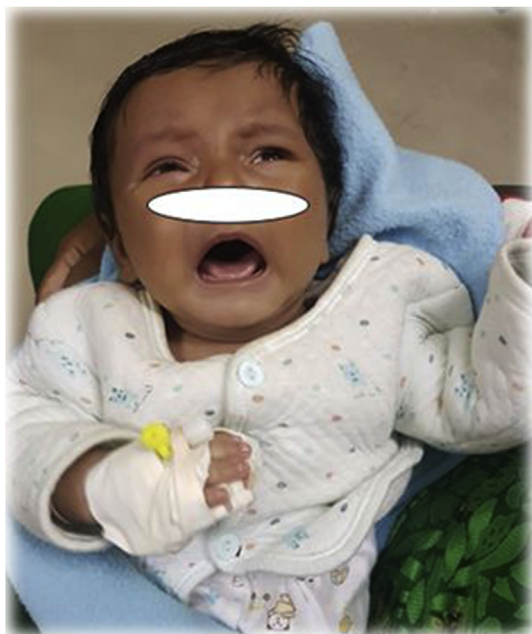

Fig. 1. A 38-day-infant with SHAPU at presentation with affected right eye.

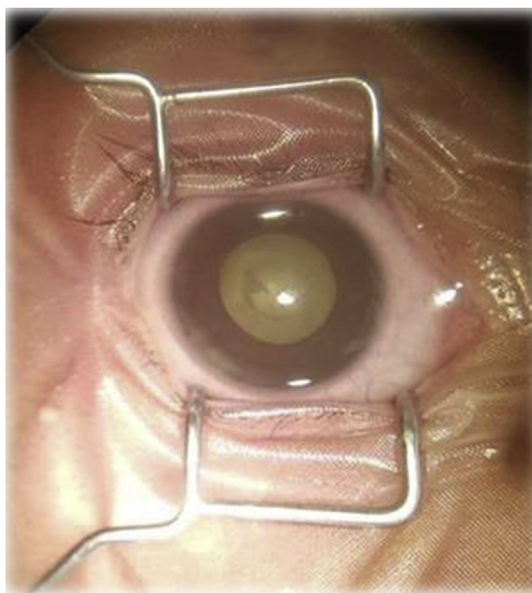

Fig. 2. Congested right eye with leukocoria.

and Dexamethasone also given at the end of the surgery. The child was maintained on topical antibiotics and corticosteroids eye drops with cycloplegics.

The baseline blood investigations were normal. Negative blood culture, urine culture and nasal swab culture ruled out the endogenous endophthalmitis. Aspirated anterior chamber and vitreous samples showed no bacteria and fungus on staining and no growth noted in culture medias (blood agar, brain heart infusion, Sabouraud dextrose agar) within 2 weeks. Nested Polymerase chain reaction (PCR) for Herpes Simplex Virus I/II, Varicella Zoster Virus, Epstein-Barr virus, Adenovirus, Cytomegalovirus and Human herpes viruses 6 & 7 were negative in vitreous fluid analysis.

After the vitrectomy, the signs of intraocular inflammation dramatically decreased. The anterior chamber reaction gradually cleared, the vitreous hyperechoic shadows resolved in USG (Fig. 3B), leukocoria disappeared thus the fundal glow was visible.

Amblyopia therapy was started with aphakic glasses. The child is stable (Fig. 4), and no recurrence has been noted till 18 months follow up.

3. Discussion

SHAPU, predominantly a disease of childhood, is reported only from Nepal. It comes in the alternate odd years in the form of an endophthalmitis outbreak affecting only one eye of otherwise healthy individuals. Among pediatric uveitis patients of Nepal, the most common cause of uveitis is reported as SHAPU (27.7%), followed by Toxoplasmosis (9.3%).⁴

Epidemic of SHAPU usually occur in the post monsoon season, hence SHAPU is also known as Seasonal Endophthalmitis.⁵ This reported case also occurred in the post monsoon season. Pokhara is reported as the place of Nepal where the first SHAPU epidemic occur¹ and the last SHAPU epidemic of the year 2017 also happened to be in Pokhara, hence this child also belonged to the same geographical location.

Few reports had suggested it to be induced after direct or indirect contact of the affected eye with a kind of white moth.² Hair follicles of moth have also been identified in the different layers of the cornea and in the anterior vitreous of the affected eye.⁶ Our case had the preceding history of contact with white moth but no hair particles were identified from the affected eye during examination and surgery. The release of toxins during the contact with moth could be the probable culprit leading to acute hypersensitivity reaction causing endophthalmitis and vision loss. But the future studies directed to analyse immunological biomarkers in ocular fluids and identification of signature interleukin in SHAPU is needed to confirm the hypothesis.

Swinging between non-infective to infective aetiology, the definitive etiopathogenesis of SHAPU is still a mystery. SHAPU is considered as deadly ocular disease as it causes with permanent loss of vision in the affected eye with subsequent cosmetic disfigurement within a week.² But early identification of the disease and timely management could save the sight and globe of this 38-day-baby.

SHAPU is prevalent among pediatric population. About 87% of cases reported by Upadhyay et al.¹ were children < 16 years of age while Manandhar et al.⁶ reported incidence of 58.8% among children < 16 years of age in a series of 34 cases. In Shrestha et al.⁷ series of 21 SHAPU cases, (61.9%) occurred in children < 16 years. The preferential affection of children has remained unexplained although it would be natural to attribute this to the low immunity in children or due to child's nature of being attracted towards the moths. The youngest case of SHAPU found in literature was 9-month-baby.¹ But herein, we report the youngest case of 38-day-infant with SHAPU treated successfully.

4. Conclusion

SHAPU predominately occurs in children and can affect the eye of even infant. White moth remains a strong risk for its aetiology and timely intervention can save the sight and prevent from cosmetic disfigurement of the patient.

Patient consent statement

Written consent to publish case details was obtained from the patient legal guardian.

Funding

No funding or grant support.

Conflicts of interest

All the authors have no financial disclosures.

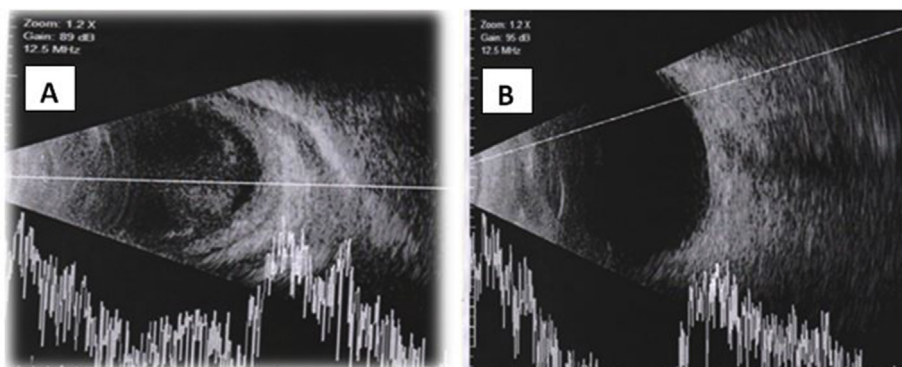


Fig. 3. USG (A + B) scan RE showing dense hyperechoic shadows in the vitreous(A) which resolved after vitrectomy and intravitreal injections (B).

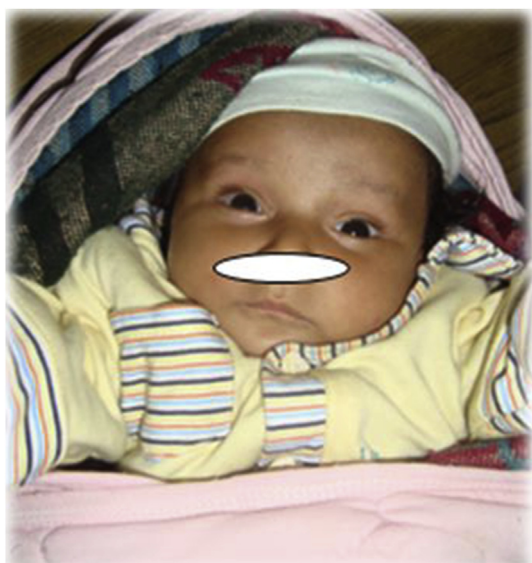

Fig. 4. The comfortable child after treatment for RE SHAPU.

Authorship

All authors attest that they meet the current ICMJE criteria for Authorship.

Previous presentation

This case was received the **Best Poster 3** Award at XIV Biennial SAARC Academy of Ophthalmology (SAO) Conference 2018 in Conjunction with XXth Nepal Ophthalmic Society Annual Meeting. June

21st –24th, 2018 Kathmandu, Nepal.

Disclosure

Financial Disclosures none.

Acknowledgements

Dr Harimaya Gurung from referring the case and Dr Suresh Raj Sharma for the Clinical photography.

Appendix A. Supplementary data

Supplementary data to this article can be found online at <https://doi.org/10.1016/j.ajoc.2019.100523>.

References

1. Upadhyay MP, Rai NC, Ogg JE, Shrestha BR. Seasonal hyperacute panuveitis of unknown etiology. *Ann Ophthalmol*. 1984 Jan;16(1):38–44 PubMed PMID: 6703576.
2. Upadhyay M, Kharel Sitaula R, Shrestha B, et al. Seasonal hyperacute panuveitis in Nepal: a review over 40 Years of surveillance. *Ocul Immunol Inflamm*. 2018 Mar 15:1–9. <https://doi.org/10.1080/09273948.2018.1439643> PubMed PMID: 29543556.
3. Upadhyay MP, Shrestha BR. SHAPU: forty years on mystery persists. *Nepal J Ophthalmol*. 2017 Jan;9(18):13–16. <https://doi.org/10.3126/nepjoph.v9i1.17527> PubMed PMID:29022949.
4. Manandhar A. Patterns of uveitis and scleritis in Nepal: a tertiary referral center study. *Ocul Immunol Inflamm*. 2017;25(sup1):S54–S62. <https://doi.org/10.3109/09273948.2016.1161804> PubMed PMID: 27191731.
5. Malla O. Endophthalmitis probably caused by Tussock moth. *Report of the Proceedings of the First National Seminar on Prevention of Blindness*. vol. 44. 1978; 1978.
6. Manandhar A. Seasonal hyperacute panuveitis: an update. *Curr Opin Ophthalmol*. 2011;22:496–501.
7. Shrestha E. A profile and treatment outcome of seasonal hyper-acute panuveitis. *Nepal J Ophthalmol*. 2010 Jan-Jun;2(1):35–38 PubMed PMID: 21141325.