

Treatment-related brain tumor imaging changes: So-called “pseudoprogression” vs. tumor progression: Review and future research opportunities

Diem Kieu Thi Tran¹, Randy L. Jensen^{1,2}

¹Department of Neurosurgery, University of Utah, ²Huntsman Cancer Institute, Salt Lake City, Utah, USA

E-mail: Diem Kieu Thi Tran - kieu.tran@hsc.utah.edu; *Randy L. Jensen - randy.jensen@hsc.utah.edu

*Corresponding author:

Received: 24 January 13 Accepted: 05 February 13 Published: 17 April 13

This article may be cited as:

Tran DK, Jensen RL. Treatment-related brain tumor imaging changes: So-called "Pseudoprogression" vs. tumor progression: Review and future research opportunities. *Surg Neurol Int* 2013;4:129-35.

Available FREE in open access from: <http://www.surgicalneurologyint.com/text.asp?2013/4/4/129/110661>

Copyright: © 2013 Tran DKT. This is an open-access article distributed under the terms of the Creative Commons Attribution License, which permits unrestricted use, distribution, and reproduction in any medium, provided the original author and source are credited.

Abstract

Background: Glioblastoma multiforme (GBM) has a dismal prognosis despite aggressive therapy. Initial diagnosis and measurement of response to treatment is usually determined by measurement of gadolinium-enhanced tumor volume with magnetic resonance imaging (MRI). Unfortunately, many GBM treatment modalities can cause changes in tumor gadolinium enhancement patterns that mimic tumor progression. The lack of a definitive imaging modality to distinguish posttreatment radiographic imaging changes (PTRIC), including pseudoprogression and radiation necrosis, from true tumor progression presents a major unmet clinical need in the management of GBM patients.

Methods: The authors discuss current modalities available for differentiating PTRIC and tumor progression, describe development of an animal model of PTRIC, and consider potential molecular and cellular pathways involved in the development of PTRIC.

Results: An animal model using glioma cells transfected with a luciferase reporter has been developed, and after conventional GBM therapy, this animal model can be evaluated with posttreatment bioluminescence imaging and various MR tumor imaging modalities.

Conclusions: Posttreatment radiographic changes that mimic tumor progression can influence clinicians to make treatment decisions that are inappropriate for the patient's actual clinical condition. Several imaging modalities have been used to try to distinguish PTRIC and true progression, including conventional MRI, perfusion MRI, MR spectroscopy, and positron emission tomography (PET); however, none of these modalities has consistently and reliably distinguished PTRIC from tumor growth. An animal model using glioma cells transfected with a luciferase reporter may enable mechanistic studies to determine causes and potential treatments for PTRIC.

Key Words: Brain, chemotherapy, imaging, models, pseudoprogression, radiation injury, rat

Access this article online

Website:

www.surgicalneurologyint.com

DOI:

10.4103/2152-7806.110661

Quick Response Code:



INTRODUCTION

Glioblastoma multiforme (GBM), the most common and most malignant brain tumor in humans, has a dismal prognosis despite aggressive therapy. Initial diagnosis and measurement of response to treatment is usually determined by measurement of gadolinium-enhanced tumor volume with magnetic resonance imaging (MRI). Unfortunately, many GBM treatment modalities can cause changes in tumor gadolinium enhancement patterns that mimic tumor progression. These changes are usually found to improve or remain stable on follow-up MRI and have thus been termed “pseudoprogression”.^[4,7,9-11,14,18,36] The lack of a definitive imaging modality to distinguish posttreatment radiographic imaging changes (PTRIC), including pseudoprogression and radiation necrosis, from true tumor progression presents a major unmet clinical need in the management of GBM patients.^[36] To date, no single imaging modality, including MRI, magnetic resonance spectroscopy (MRS), and positron emission tomography (PET), has been successful in making this determination. At present, only direct examination of tumor histopathology can discriminate tumor progression from PTRIC. Furthermore, there is no clear understanding of the molecular, biochemical, and cellular mechanisms mediating PTRIC.

CLINICAL PROBLEM OF PSEUDOPROGRESSION AND RADIATION NECROSIS

Among patients on temozolomide (TMZ) therapy with early progression in the first 3 months, approximately one-third were found to have pseudoprogression/PTRIC.^[31] What makes pseudoprogression so difficult clinically is that an incorrect diagnosis of progression could result in termination of an effective treatment because of apparent lack of response. This could have a negative influence on survival if a less effective treatment is instituted. Pseudoprogression differs from radiation necrosis in that the increase in contrast

enhancement is transient and resolves without changes in management with the former, whereas clinical worsening is more likely with the latter [Figure 1].^[32] Follow-up scans offer the best indication of pseudoprogression, because true tumor and enhancement changes due to other variables cannot be differentiated with current imaging techniques.^[20]

PTRIC AND TUMOR BIOLOGY

Pseudoprogression usually occurs in patients that have received TMZ therapy combined with radiotherapy. The rapid onset in patients treated with both radio- and chemotherapy suggests the presence of damage to both the neuroglia and the vasculature supplying it. The biology of pseudoprogression is not entirely clear as several hypotheses have been proposed. The alkylating agent TMZ causes replication arrest in the G2/M cell cycle phase and increases the number of breaks in DNA. Radiation therapy has similar mechanistic events. It has been proposed that the combination of these effects sets in motion an exaggerated cellular response within the tumor cells, in the surrounding astrocytes, or in the peritumoral vasculature that subsequently results in imaging changes consistent with pseudoprogression.^[7] Why this does not happen in every case of GBM treated with this therapeutic regimen remains a question. A recent study showed the level of cellular proliferation, as measured by Ki67 index at the time of initial surgery, can be a prognostic marker for distinguishing pseudoprogression from actual progression.^[28] Higher levels of Ki67 expression were associated with development of pseudoprogression on follow-up imaging studies. True progression of GBM, in contrast, was associated with initial lower levels of cellular proliferation. Further studies need to be done to confirm this finding, which from a mechanistic standpoint seems paradoxical. Interestingly, patients with a malignant glioma who developed pseudoprogression were found to have a more favorable prognosis than patients without development of this radiological phenomenon.^[7] It has been hypothesized that these

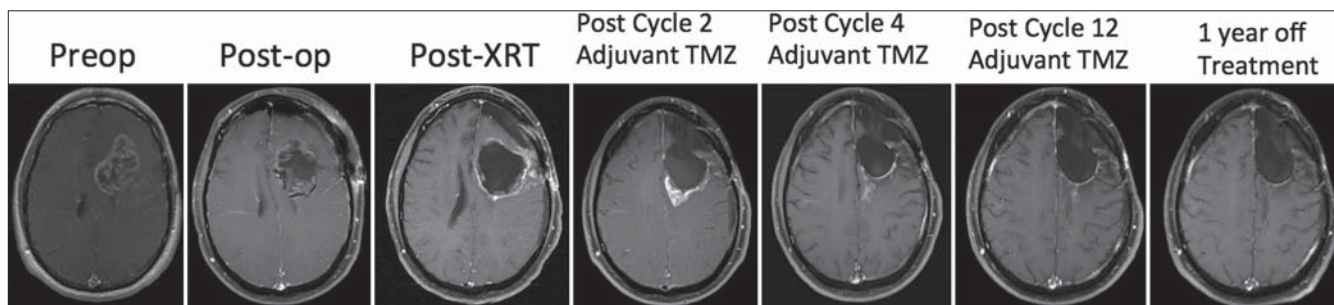


Figure 1: MRIs showing imaging pseudoprogression in a 51-year-old man with a left frontal heterogeneously enhancing mass (Preoperative). After surgical resection (Postoperative), histological evaluation was consistent with glioblastoma. The patient was then treated with fractionated radiotherapy with concurrent temozolomide (PostXRT). At the end of two cycles of adjuvant temozolomide, a new enhancing lesion was found in the mesial posterior resection cavity, which suggested a recurrent tumor (Postcycle 2 adjuvant TMZ). After two more cycles of TMZ, the enhancing lesion resolved, suggesting that the enhancement had been due to pseudoprogression (Postcycle 4 adjuvant TMZ). There was no further development of enhancement within the resection bed throughout the completion of 12 total adjuvant TMZ cycles (Postcycle 12 adjuvant TMZ) and even after 1 year off of any therapy (1 year off treatment)

patients may be genetically predisposed to respond to TMZ with O6-methylguanine-DNA methyltransferase (MGMT) promoter methylation. This marker was reported to be an important prognostic factor in GBM as the development of pseudoprogression was significantly correlated with the MGMT promoter methylation status.^[6]

MR IMAGING, MR SPECTROSCOPY, AND PTRIC

The standard of care for measurement of response to treatment is gadolinium-enhanced MRI; however, conventional MRI is not always helpful at distinguishing pseudoprogression. When evaluating patient tumor response, it is well known that conventional MRI does not reliably distinguish radiation necrosis from tumor recurrence after stereotactic radiosurgery.^[33] In a similar fashion, conventional MRI has little use in diagnosing pseudoprogression in glioblastoma, although it has been demonstrated that subependymal spread of enhancing lesion is found more commonly in tumor progression rather than in pseudoprogression.^[39]

Other forms of MRI that have been evaluated also do not consistently or reliably discriminate PTRIC from true progression. This is especially true during bevacizumab therapy for recurrent GBM. In fact, a nonenhancing tumor pattern of progression is common after treatment with bevacizumab for GBM but does not necessarily translate into improved survival.^[21] Diffusion-weighted MRI can be helpful in differentiation of true progression from pseudoprogression after concomitant radiotherapy with TMZ in patients with newly diagnosed high-grade gliomas.^[26] Patients with pseudoprogression also have lower diffusion-weighted imaging (DWI) signal intensity (rim of high or no signal intensity pattern) and higher apparent diffusion coefficient (ADC) values than the patients with true progression.^[26,37]

Attempts have been made to use perfusion MRI to estimate tumor burden, as opposed to pseudoprogression or radiation necrosis, and have correlated this with overall patient survival.^[19,38] Regional cerebral blood volume (rCBV) measured by dynamic susceptibility-weighted contrast-enhanced perfusion MR images has been used to help predict pseudoprogression in patients with GBM,^[23] with a significantly lower mean rCBV demonstrated in pseudoprogression compared with real tumor progression. Despite the promise of these findings, in our experience, patients often have a mixed pattern of perfusion, suggestive of both tumor progression and pseudoprogression, which makes interpretation of this imaging modality no matter how elegant or sophisticated, very difficult. Our group has recently finished a prospective clinical trial measuring MR perfusion from various areas within a given tumor and correlated this with hypoxia

tumor markers. We found very different expression of hypoxia-regulated proteins and perfusion MR in different areas of a given tumor (unpublished data). This implies that regional differences in MR perfusion might hamper interpretation of these measurements in *de novo* tumor and would be even more complicated in a treated tumor with suspected PTRIC.

MR spectroscopy was initially thought to differentiate between radiation necrosis and tumor progression but has proved not to be completely effective.^[20,30,39] MR spectroscopy can, however, depict structural degradation in cerebral tissues after radiation therapy and can show alterations in brain metabolites. MR spectroscopy has not been shown to be very effective in distinguishing pseudoprogression and true tumor progression,^[20] most likely because of sampling issues and mixed tumor/pseudoprogression content of voxels being interrogated.

PET IMAGING AND PTRIC

Positron emission tomography, with its ability to measure metabolic activity, has been proposed as an imaging modality with high potential to distinguish between pseudoprogression, true progression, and radiation necrosis. PET imaging has allowed highly sensitive measurements to be taken of biochemically active molecules using labeled, short-lived positron-emitting radionuclides. The most common PET imaging tracer for clinical use is the glucose analog 2-deoxy-2-(¹⁸F) fluoro-D-glucose, also called ¹⁸fluorodeoxyglucose ([¹⁸F] FDG), whose function in PET imaging is based on the principle of glycolytic metabolism; areas with high activity correspond to increased glucose metabolism commonly found in tumors. In contrast, the dead tissue of radiation necrosis or pseudoprogression should have low radionuclide uptake and activity. PET imaging is increasingly implemented in neuro-oncology since it can provide a metabolic component to measure a specific pathway in a given tumor or tumor cell. [¹⁸F] FDG PET is useful for imaging gliomas because high-grade gliomas have increased glucose metabolism, which can be identified on [¹⁸F] FDG PET; however, current data on [¹⁸F] FDG PET are inconsistent and show limited accuracy for the differentiation between tumor progression and the imaging changes that are the subject of this review.^[25] This is probably related to sampling issues described earlier as well as the lower spatial resolution of this imaging modality.

ANIMAL MODELS OF RADIATION NECROSIS

As described earlier, there is a significant lack of understanding of the molecular underpinnings behind the development of PTRIC. One significant step toward this end would be the development of a model to elucidate these pathways. To date, there is no animal model of

PTRIC. There have been attempts to develop a radiation necrosis rodent model using a 4-mm radiosurgery cone to deliver 60 Gy to an implanted GBM cell line.^[24] Histological evaluation of the brains of rats with implanted irradiated GBM cells showed central liquefaction necrosis in high-dose regions consistent with necrosis and viable tumor growth in low-dose regions. A similar mouse glioma model has also shown changes in MR perfusion and diffusion after radiation treatments.^[12] This same model has demonstrated similar MR perfusion and diffusion changes after combination chemo- and radiation therapy.^[12] Diffusion tensor MRI has been reported to be helpful in distinguishing radiation necrosis and viable glioma in a rat radiation necrosis model.^[35] In lesions caused by radiation necrosis, a visible isotropic ADC pattern was observed. Areas that were hypointense, the central necrotic zone, corresponded to a lower ADC, while areas that were hyperintense, the peripheral zone, corresponded to a higher ADC. Histological analysis showed parenchymal coagulative necrosis in the central zone and damaged vessels and reactive gliosis in the peripheral zones.

Magnetically labeled cytotoxic T-cells (CTLs) have been used to differentiate glioma progression from radiation injury in a rat model.^[2] Dendritic cells were primed with glioblastoma tumor cell lysates to generate CTLs sensitized to these tumor cells. These labeled CTLs were injected into rats with implanted tumors as well as rats with focal radiation injury. MRIs showed accumulation of CTLs in actively growing tumor areas and not at sites of radiation necrosis. Radiation necrosis is much easier to model than PTRIC given the reversible nature of PTRIC and the fact that radiation necrosis can be induced simply by high-dose radiation treatment.

PRELIMINARY WORK ON AN ANIMAL MODEL OF PTRIC

We have begun to develop an animal model of PTRIC using established glioma cell lines and hope to extend this to tumor-derived GBM stem cells. Nonirradiated, sublethally irradiated, and lethally irradiated brain tumor cells were transfected with a constitutively active luciferase reporter and stereotactically implanted into rats. The rats were then treated with TMZ chemotherapy and received either no irradiation, sublethal irradiation (2 Gy), or lethal irradiation (10 Gy) to the implanted tumor cells and surrounding brain. Cell growth was monitored by bioluminescence imaging of the luciferase reporter and brain MRI measurement of tumor growth [Figures 2 and 3].

We then evaluated which combination of preimplanted cellular conditioning (no, sublethal, or lethal irradiation) and postimplantation conditions (chemotherapy alone or with sublethal or lethal radiation) shows MRI enhancement after radiation and chemotherapy while

demonstrating decreasing luciferase activity. Rats were also imaged weekly when intracranial tumor luciferase activity was found. We have previously demonstrated that luciferase activity is correlated with intracranial tumor proliferation.^[22,29] We hypothesize that comparing patterns of luciferase activity with tumor gadolinium enhancement measured by MRI will allow us to differentiate between tumor progression, pseudoprogession, and radiation necrosis. We predict that tumor progression would be manifested by high and weekly increasing luciferase activity coupled with increasing gadolinium-enhanced tumor volume [Figure 2]. Similarly, we would expect pseudoprogession to be modeled by weaker and weekly decreasing luciferase activity with increasing gadolinium-enhanced tumor volume over time [Figure 3]. In the future, we plan to perform histological and immunological analysis of the treated brain and tumor, as well as measure vascularity, apoptosis, proliferation, and various signaling molecules to further work out this model. Our plans also include experiments using the hypoxia marker pimonidazole and perfusion marker Hoechst 33342 for measurement of tumor vascular perfusion to allow for the determination of tumor blood flow and its relationship to areas of hypoxia for correlation with imaging data. Tumor histology will be confirmed by light microscopy and MIB-1 (for proliferative index), Factor-8 or CD31 (for vascularity), Caspase-3 (for apoptosis) evaluation. Hypoxia-regulated protein expression, including hypoxia-inducible factor-1 α (HIF-1 α), vascular endothelial growth factor (VEGF), carbonic anhydrase-IX (CA-IX), glucose transporter-1 (Glut-1), stromal cell-derived factor-1 (SDF-1), and CXC chemokine ligand 12 (CXC-12), will be immunohistochemically analyzed for preliminary study of the role of these proteins in pseudoprogession development. The histological measures will be correlated with PET tracer studies using ¹⁵O H₂O for perfusion, ¹⁸F-misonidazole for hypoxia, ¹⁸F-fluorodeoxythymidine for proliferation, and ¹⁸F-deoxyglucose for tumor metabolic activity to demonstrate the ability of these tracers (or combination of tracers) to differentiate between pseudoprogession, radiation necrosis, and tumor progression. We will eventually expand these studies to include subjecting the cell to be implanted to hypoxic conditions (with or without irradiation) before placement into the rat brain. We will also study glioma cells with inhibited HIF-1 α pathways or overexpression of these pathways.

MOLECULAR PATHWAYS INVOLVED IN PTRIC

We speculate that PTRIC is mediated by treatment-associated, hypoxia-regulated stimulation of glioma or peritumoral endothelial cells with subsequent attraction and migration of bone marrow-derived

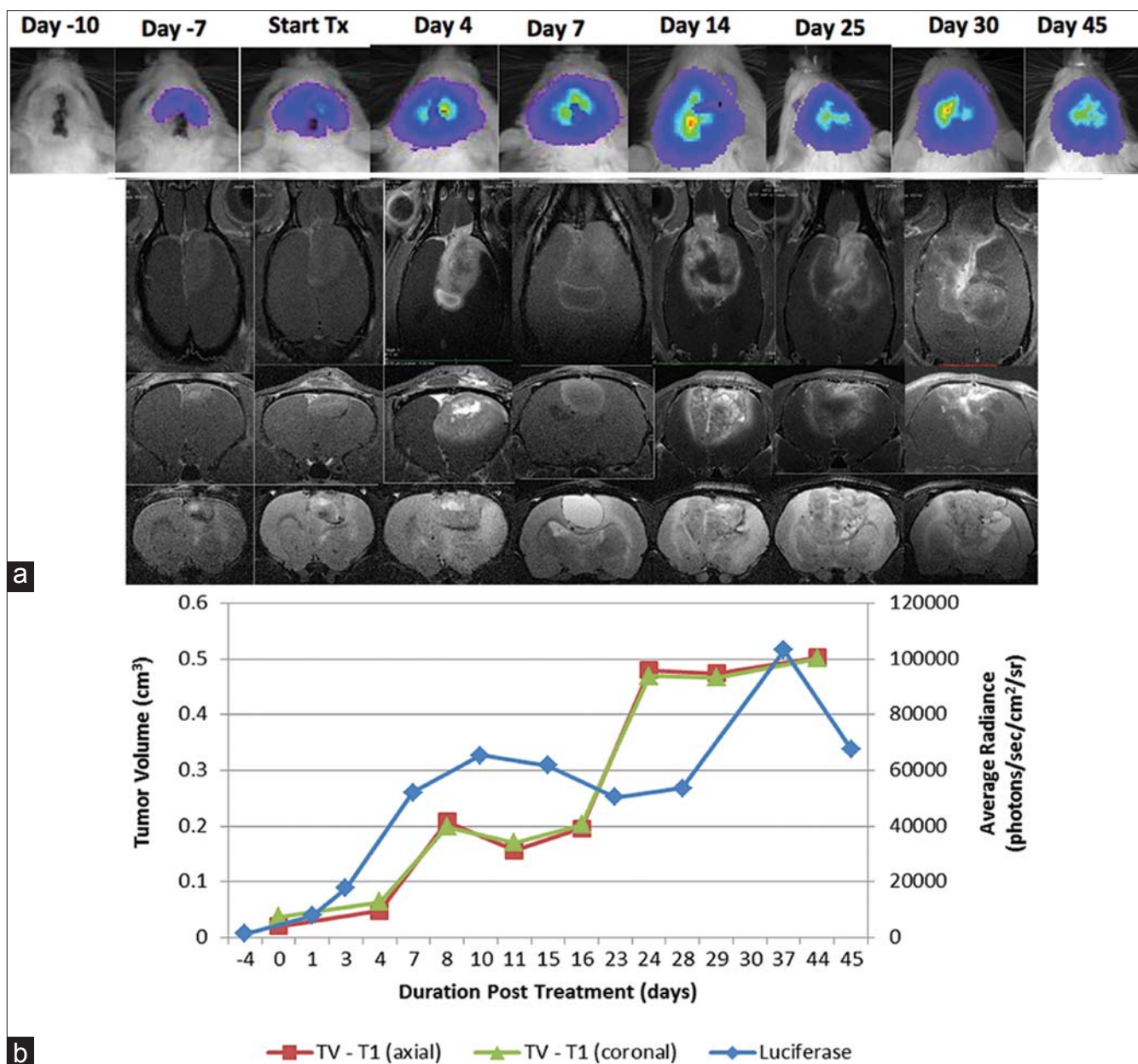


Figure 2: Tumor progression. (a) Correlation of bioluminescence imaging (top row) and T1-weighted gadolinium-enhanced MRI (coronal views, 2nd row and axial views, 3rd row) and T2-weighted MRI (coronal views, 4th row) over time. Time labels at time represent time of tumor implantation and establishment (Day-7 and -3), start of radiation (2 Gy, three treatments given over 5 days) with no chemotherapy (Start Tx), and days after treatment started. (b) Graphic representation of luciferase activity and gadolinium-enhanced MRI tumor volume over time. This pattern of increasing gadolinium-enhanced volume and increasing bioluminescence activity is suggestive of tumor progression

cells (BMDCs), neural stem cells (NSCs), or even possibly glioma stem cells (GSCs). This is based on prior studies that have demonstrated that BMDCs and glioma tumor stem-like cell recruitment and vasculogenesis is mediated by hypoxia-regulated proteins including HIF-1 α and SDF-1/CXC-12.^[1,3,8,13,15,16,27,34,40] In a similar manner, human umbilical cord blood stem cells show platelet-derived growth factor-D-dependent glioma cell tropism *in vitro* and *in vivo*.^[17] To test these ideas, we hope to further develop our rodent model of PTRIC and apply novel imaging modalities to distinguish PTRIC from true tumor progression.

CONCLUSIONS

Response to treatment of patients with GBM is usually measured by gadolinium-enhanced MRI; however, up to one-third of patients will develop posttreatment radiographic changes that can mimic tumor progression. These changes can influence clinicians to make treatment decisions that are inappropriate for the patient's actual clinical condition. Not much is known about the tumor biology of pseudoprogression, with only a limited number of predictive biomarkers available. Several imaging modalities have been used to try to distinguish PTRIC and true progression,

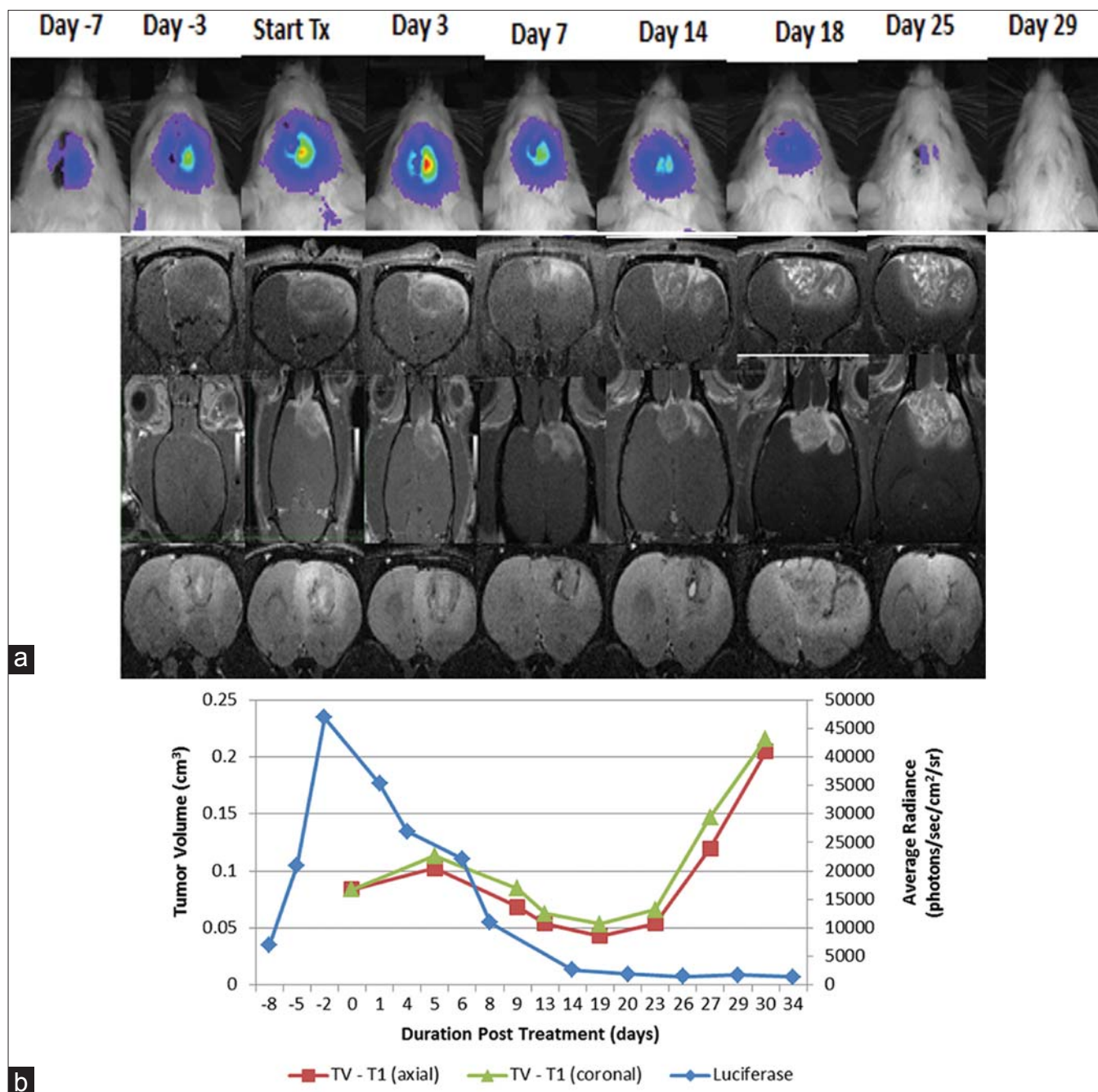


Figure 3: Pseudoprogession. (a) Correlation of bioluminescence imaging (top row) and T1-weighted, gadolinium-enhanced MRI (coronal views, 2nd row; axial views, 3rd row) and T2-weighted MRI (coronal views, 4th row) over time. Time labels represent time of tumor implantation and establishment (Day -7 and -3), start of radiation (2 Gy, three treatments given over 5 days) and chemotherapy (temozolomide, 7.5 mg/kg, six treatments) (Start Tx), and days after treatment started. (b) Graphic representation of luciferase activity and gadolinium-enhanced MRI tumor volume over time. This pattern of increasing gadolinium-enhanced volume and decreased bioluminescence activity is suggestive of pseudoprogession

including conventional MRI, perfusion MRI, MR spectroscopy, and PET; however, none of these modalities has consistently and reliably distinguished PTRIC from tumor growth. We describe preliminary work on an animal model using glioma cells transfected with a luciferase reporter. After conventional GBM therapy, this animal model can be evaluated with posttreatment bioluminescence imaging and various MR tumor imaging modalities. We hope to use

this model for mechanistic studies to determine causes and potential treatments for PTRIC.

REFERENCES

1. Aghi M, Cohen KS, Klein RJ, Scadden DT, Chiocca EA. Tumour stromal-derived factor-1 recruits vascular progenitors to mitotic neovasculature, where microenvironment influences their differentiated phenotypes. *Cancer Res* 2006;66:9054-64.

2. Arbab AS, Janic B, Jafari-Khouzani K, Iskander AS, Kumar S, Varma NR, et al. Differentiation of glioma and radiation injury in rats using *in vitro* produce magnetically labeled cytotoxic T-cells and MRI. *PLoS One* 2010;5:e9365.
3. Bao S, Wu Q, Sathornsumetee S, Hao Y, Li Z, Hjelmeland AB, et al. Stem cell-like glioma cells promote tumour angiogenesis through vascular endothelial growth factor. *Cancer Res* 2006;66:7843-8.
4. Brandes AA, Franceschi E, Tosoni A, Blatt V, Pession A, Tallini G, et al. MGMT promoter methylation status can predict the incidence and outcome of pseudoprogression after concomitant radiochemotherapy in newly diagnosed glioblastoma patients. *J Clin Oncol* 2008;26:2192-7.
5. Brandes AA, Tosoni A, Franceschi E, Reni M, Gatta G, Vecht C. Glioblastoma in adults. *Crit Rev Oncol Hematol* 2008;67:139-52.
6. Brandsma D, Stalpers L, Taal W, Sminia P, van den Bent MJ. Clinical features, mechanisms, and management of pseudoprogression in malignant gliomas. *Lancet Oncol* 2008;9:453-61.
7. Brandsma D, van den Bent MJ. Pseudoprogression and pseudoresponse in the treatment of gliomas. *Curr Opin Neurol* 2009;22:633-8.
8. Ceradini DJ, Kulkarni AR, Callaghan MJ, Tepper OM, Bastidas N, Kleinman ME, et al. Progenitor cell trafficking is regulated by hypoxic gradients through HIF-1 induction of SDF-1. *Nat Med* 2004;10:858-64.
9. Chamberlain MC. Pseudoprogression in glioblastoma. *J Clin Oncol* 2008;26:4359.
10. Chamberlain MC, Glantz MJ, Chalmers L, Van Horn A, Sloan AE. Early necrosis following concurrent Temodar and radiotherapy in patients with glioblastoma. *J Neuro-oncol* 2007;82:81-3.
11. Chaskis C, Neyns B, Michotte A, De Ridder M, Everaert H. Pseudoprogression after radiotherapy with concurrent temozolomide for high-grade glioma: Clinical observations and working recommendations. *Surg Neurol* 2009;72:423-8.
12. Chung C, Jalali S, Foltz W, Burrell K, Wildgoose P, Lindsay P, et al. Imaging biomarker dynamics in an intracranial murine glioma study of radiation and antiangiogenic therapy. *Int J Radiat Oncol Biol Phys* 2013;85:805-12.
13. De Falco E, Porcelli D, Torella AR, Straino S, Iachinino MG, Orlandi A, et al. SDF-1 involvement in endothelial phenotype and ischemia-induced recruitment of bone marrow progenitor cells. *Blood* 2004;104:3472-82.
14. de Wit MC, de Bruin HG, Eijkenboom W, Sillevis Smitt PA, van den Bent MJ. Immediate post-radiotherapy changes in malignant glioma can mimic tumour progression. *Neurology* 2004;63:535-7.
15. Du R, Lu KV, Petrutsch C, Liu P, Ganss R, Passegue E, et al. HIF1 α induces the recruitment of bone marrow-derived vascular modulatory cells to regulate tumour angiogenesis and invasion. *Cancer Cell* 2008;13:206-20.
16. Folkins C, Shaked Y, Man S, Tang T, Lee CR, Zhu Z, et al. Glioma tumour stem-like cells promote tumour angiogenesis and vasculogenesis via vascular endothelial growth factor and stromal-derived factor 1. *Cancer Res* 2009;69:7243-51.
17. Gondi CS, Veeravalli KK, Gorantla B, Dinh DH, Fassett D, Klopfenstein JD, et al. Human umbilical cord blood stem cells show PDGF-D-dependent glioma cell tropism *in vitro* and *in vivo*. *Neuro Oncol* 2010;12:453-65.
18. Hoffman WF, Levin VA, Wilson CB. Evaluation of malignant glioma patients during the postirradiation period. *J Neurosurg* 1979;50:624-8.
19. Hu LS, Eschbacher JM, Heiserman JE, Dueck AC, Shapiro WR, Liu S, et al. Reevaluating the imaging definition of tumour progression: perfusion MRI quantifies recurrent glioblastoma tumour fraction, pseudoprogression, and radiation necrosis to predict survival. *Neuro Oncol* 2012;14:919-30.
20. Hygino da Cruz LC Jr., Rodriguez I, Domingues RC, Gasparetto EL, Sorensen AG. Pseudoprogression and pseudoresponse: imaging challenges in the assessment of posttreatment glioma. *AJNR Am J Neuroradiol* 2011;32:1978-85.
21. Iwamoto FM, Abrey LE, Beal K, Gutin PH, Rosenblum MK, Reuter VE, et al. Patterns of relapse and prognosis after bevacizumab failure in recurrent glioblastoma. *Neurology* 2009;73:1200-6.
22. Jensen RL, Soleau S, Bhayani MK, Christiansen D. Expression of hypoxia inducible factor-1 alpha and correlation with preoperative embolization of meningiomas. *J Neurosurg* 2002;97:658-67.
23. Kong DS, Kim ST, Kim EH, Lim DH, Kim WS, Suh YL, et al. Diagnostic dilemma of pseudoprogression in the treatment of newly diagnosed glioblastomas: The role of assessing relative cerebral blood flow volume and oxygen-6-methylguanine-DNA methyltransferase promoter methylation status. *AJNR Am J Neuroradiol* 2011;32:382-7.
24. Kumar S, Arbab AS, Jain R, Kim J, deCarvalho AC, Shankar A, et al. Development of a novel animal model to differentiate radiation necrosis from tumour recurrence. *J Neuro Oncol* 2012;108:411-20.
25. la Fougere C, Suchorska B, Bartenstein P, Kreth FW, Tonn JC. Molecular imaging of gliomas with PET: opportunities and limitations. *Neuro Oncol* 2011;13:806-19.
26. Lee WJ, Choi SH, Park CK, Yi KS, Kim TM, Lee SH, et al. Diffusion-weighted MR imaging for the differentiation of true progression from pseudoprogression following concomitant radiotherapy with temozolomide in patients with newly diagnosed high-grade gliomas. *Acad Radiol* 2012;19:1353-61.
27. Petit I, Jin D, Rafii S. The SDF-1-CXCR4 signaling pathway: A molecular hub modulating neo-angiogenesis. *Trends Immunol* 2007;28:299-307.
28. Pouleau HB, Sadeghi N, Baleriaux D, Melot C, De Witte O, Lefranc F. High levels of cellular proliferation predict pseudoprogression in glioblastoma patients. *Int J Oncol* 2012;40:923-8.
29. Ragel BT, Elam IL, Gillespie DL, Flynn JR, Kelly DA, Mabey D, et al. A novel model of intracranial meningioma in mice using luciferase-expressing meningioma cells. Laboratory investigation. *J Neurosurg* 2008;108:304-10.
30. Rock JP, Hearshen D, Scarpace L, Croteau D, Gutierrez J, Fisher JL, et al. Correlations between magnetic resonance spectroscopy and image-guided histopathology, with special attention to radiation necrosis. *Neurosurgery* 2002;51:912-9.
31. Sanghera P, Perry J, Sahgal A, Symons S, Aviv R, Morrison M, et al. Pseudoprogression following chemoradiotherapy for glioblastoma multiforme. *Can J Neurol Sci* 2010;37:36-42.
32. Sanghera P, Rampling R, Haylock B, Jefferies S, McBain C, Rees JH, et al. The concepts, diagnosis and management of early imaging changes after therapy for glioblastomas. *Clin Oncol (R Coll Radiol)* 2012;24:216-27.
33. Stockham AL, Tievsky AL, Koyfman SA, Reddy CA, Suh JH, Vogelbaum MA, et al. Conventional MRI does not reliably distinguish radiation necrosis from tumour recurrence after stereotactic radiosurgery. *J Neuro Oncol* 2012;109:149-58.
34. Tabatabai G, Frank B, Mohle R, Weller M, Wick W. Irradiation and hypoxia promote homing of haematopoietic progenitor cells towards gliomas by TGF- β -dependent HIF-1 α -mediated induction of CXCL12. *Brain* 2006;129:2426-35.
35. Wang S, Chen Y, Lal B, Ford E, Tryggstad E, Armour M, et al. Evaluation of radiation necrosis and malignant glioma in rat models using diffusion tensor MR imaging. *J Neuro Oncol* 2012;107:51-60.
36. Wen PY, Macdonald DR, Reardon DA, Cloughesy TF, Sorensen AG, Galanis E, et al. Updated response assessment criteria for high-grade gliomas: Response assessment in Neuro-Oncology Working Group. *J Clin Oncol* 2010;28:1963-72.
37. Yang I, Aghi MK. New advances that enable identification of glioblastoma recurrence. *Nat Rev Clin Oncol* 2009;6:648-57.
38. Young RJ, Gupta A, Shah AD, Graber JJ, Chan TA, Zhang Z, et al. MRI perfusion in determining pseudoprogression in patients with glioblastoma. *Clin Imaging* 2013;37:41-9.
39. Young RJ, Gupta A, Shah AD, Graber JJ, Zhang Z, Shi W, et al. Potential utility of conventional MRI signs in diagnosing pseudoprogression in glioblastoma. *Neurology* 2011;76:1918-24.
40. Zhao D, Najbauer J, Garcia E, Metz MZ, Gutova M, Glackin CA, et al. Neural stem cell tropism to glioma: critical role of tumour hypoxia. *Mol Cancer Res* 2008;6:1819-29.