



Case report

Deep neck space infection and Lemierre's syndrome caused by *Streptococcus anginosus*: A case report



Fábio Videira Santos^{a,e,*}, Sara Xavier Pires^{b,e}, Cristina Pereira^{c,e}, Lúcia Gonçalves^{d,e}, Sara Martins^{b,e}, Irene Aragão^e

^a Serviço de Doenças Infecciosas do Centro Hospitalar Universitário do Porto, Portugal

^b Serviço de Medicina Interna do Centro Hospitalar Universitário do Porto, Portugal

^c Serviço de Anestesiologia do Centro Hospitalar do Centro Hospitalar Universitário do Porto, Portugal

^d Serviço de Anestesiologia do Centro Hospitalar de Leiria, Portugal

^e Unidade de Cuidados Intensivos Polivalentes, Centro Hospitalar Universitário do Porto, Portugal

ARTICLE INFO

Article history:

Received 29 August 2019

Received in revised form 5 November 2019

Accepted 5 November 2019

Keywords:

Lemierre's syndrome

Streptococcus anginosus

Deep neck infection

ABSTRACT

Introduction: Deep neck space infections most commonly arise from a septic focus of the mandibular teeth, tonsils, parotid gland, middle ear or sinuses, usually with a rapid onset and frequently with progression to life-threatening complications. Lemierre's syndrome is classically defined by an oropharyngeal infection with internal jugular vein thrombosis followed by metastatic infections in other organs.

Case presentation: A 32-year-old female patient, with no significant past medical history, was diagnosed with a dental abscess on her left inferior 3rd molar. Six days later, the condition complicated with severe upper respiratory distress, odynophagia and trismus, and extension of the inflammatory signs to the anterior cervical region, involving the upper airway. Computed tomography scan confirmed extension to submandibular, parapharyngeal and retrosternal spaces), which required nasotracheal intubation due to compromised airway. Urgent and subsequent surgical drainages were performed, alongside with concomitant antibiotic therapy. Additionally, left internal jugular vein thrombosis was described - with later extension to the brachiocephalic vein, without other complications, consistent with Lemierre's syndrome, although without full features. *Streptococcus anginosus* was identified in the drained pus specimens. The patient made a satisfactory clinical progress and was discharged after 25 days, still under therapeutic hypocoagulation.

Conclusion: As deep neck space infections can be life-threatening, clinicians must be aware and not underestimate their potential severity. Lemierre's syndrome is a complication difficult to recognize, which requires additional awareness of the many possible presentations, for appropriate diagnostic studies and therapeutic plan.

© 2019 The Authors. Published by Elsevier Ltd. This is an open access article under the CC BY-NC-ND license (<http://creativecommons.org/licenses/by-nc-nd/4.0/>).

Introduction

Dentoalveolar infections are one of the most common diseases in the oral and maxillofacial region, with acute dental abscess usually occurring secondary to dental caries, trauma or failed root treatment [1,2]. Deep neck space infections (DNSI) most commonly arise from a septic focus of the mandibular teeth, tonsils, parotid gland, middle ear or sinuses, usually with a rapid onset and frequently with progression to life-threatening complications,

particularly the risk of compromised airway [3]. Complications are associated with a mortality rate up to 40 %, mainly in the presence of mediastinal extension; however, with the rise of modern antibiotics, mortality rates have significantly diminished [1,3,4]. Although most oropharyngeal infections are self-contained, they still can spread through the fascia and deep neck spaces while progressing inferiorly into the mediastinum. Multiple severe complications of dentoalveolar infection have been reported, such as airway obstruction, Ludwig's angina, descending mediastinitis, necrotizing fasciitis and any site typical of septic embolic spread may be involved [4–8].

Systematically described for the first time in *The Lancet* (1936), by the French professor of bacteriology André Lemierre, while working in the Claude Bernard Hospital in Paris, Lemierre's

* Corresponding author at: Serviço de Doenças Infecciosas do Centro Hospitalar Universitário do Porto, Largo Prof. Abel Salazar, 4099-001, Porto, Portugal.
E-mail address: fabio.videira@chporto.min-saude.pt (F.V. Santos).

syndrome (LS) is classically defined by a pharyngeal or odontogenic infection, complicated by bacteraemia and internal jugular vein thrombosis followed by septic emboli, usually occurring in otherwise healthy adults [9–12]. Other known historical names are postanginal anaerobic septicaemia or necrobacillosis [10]. Due to the introduction of antibiotics and because of its presumptive very low prevalence, LS has been referred to as “the forgotten disease” [10,12–14]. The most commonly involved and described bacteria is *Fusobacterium necrophorum* but others, such as *Streptococcus* spp., *Staphylococcus* spp. and *Enterococcus* spp. are also found in cultures [10,14,15].

We present a case of deep neck space infection and LS caused by *Streptococcus anginosus*. We consider this case to be relevant because it represents an incomplete LS, caused by a microbial agent that is not the most commonly identified in this entity, although it is already described in the medical literature. In addition, we aim to describe and discuss in detail our clinical approach, in order to increase available data and knowledge about this particular disease.

Case presentation

A 32-year-old female patient with no significant past medical history and no known allergies was diagnosed with a dental abscess on her left inferior 3rd molar, in a countryside hospital, in early May 2019. She was initially treated, in the ambulatory setting, with oral amoxicillin/clavulanate 875 mg/125 mg every 12 h, that she was taking correctly.

On the 5th to 6th day of treatment she noticed odynophagia and a painful left submandibular oedema, which led her to return to the emergency department. On medical examination the patient already presented severe upper airway respiratory distress,

trismus and extension of the inflammatory signs to the anterior cervical region. Her vitals were stable, with oxygen saturation (FiO₂ 21 %) of 97 %, and no fever was documented. The initial laboratory results revealed a leukocytosis of 14.760/ μ L, and a C-reactive protein of 33.36 mg/dL, with no other analytical values significantly altered. Cervical and thoracic computed tomography (CT) scan with contrast showed a diffuse thickening of the soft tissues with phlegmon and emphysema from the oral cavity to the anterior mediastinum, near the aortic arch. Abscess extension was confirmed to submandibular, parapharyngeal and retrosternal spaces, with secondary bulging of the walls of the airway at the base of the tongue, associated with left internal jugular vein thrombosis (Fig. 1).

The patient was readily transferred to our tertiary referral centre, to be evaluated by Maxillofacial Surgery. Due to predictably difficult airway, after proper sedation, fiberoptic nasotracheal intubation was performed in the operating room. The patient underwent surgical drainage of the abscesses and was later admitted to the Intensive Care Unit for airway management.

Daily bedside drainage of the submandibular region was performed, and the patient was started on intravenous corticosteroids (10 mg of dexamethasone every 12 h for 3 days) and empiric antibiotic therapy with ceftriaxone 2 g every 24 h and metronidazole 500 mg every 6 h. Because of extension of vein thrombosis to the brachiocephalic vein in the 48 h-reassessment CT-scan, intravenous non-fractionated heparin was also initiated.

The direct examination of surgical drained pus through Gram staining demonstrated polymicrobial flora with a predominance of gram positive cocci and gram negative bacilli. Later, abscess cultures grew *Streptococcus anginosus*, susceptible to amoxicillin/clavulanate, carbapenems and metronidazole. The 2 sets of blood cultures collected after the first administration of the intravenous

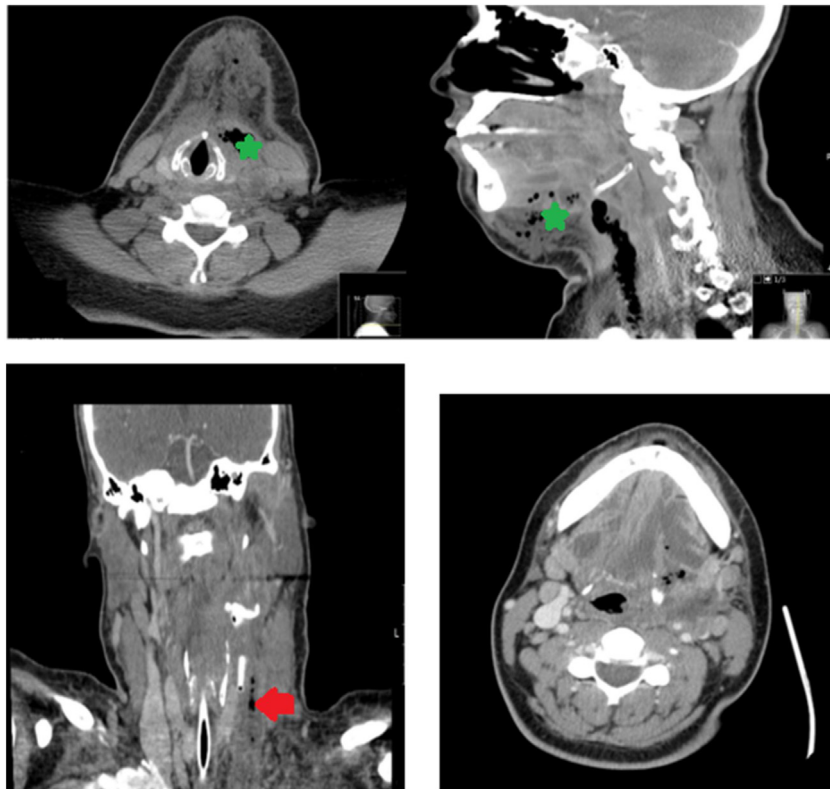


Fig. 1. [Upper left corner and upper right corner]: diffuse thickening with phlegmon and emphysema of the soft tissues (green star), from the oral cavity to the anterior mediastinum, near the aortic arch, confirming abscess extension to submandibular, parapharyngeal and retrosternal spaces, associated with bulging of the walls of the airway at the base of the tongue; [Lower left corner and lower right corner]: there is a filling defect in the left internal jugular vein, inferior to C3 - this is consistent with thrombus (red arrow). No extension above the jugular foramen.

antimicrobials, were sterile. HIV 1/2 antibodies/antigen assay was negative. All serum immunoglobulins were also normal.

The patient showed clinical and imaging improvement, with successful extubation 8 days after the surgery and was transferred to the infirmary for postoperative care. Although CT reevaluation demonstrated persistence of left internal jugular vein thrombosis, she underwent favourable clinical progress with defervescence and neck tenderness resolution, and recovered without any sequelae, new infectious or thrombotic complications, having completed a total of 24 days of ceftriaxone and metronidazole. The patient was discharged 25 days after admission, under anticoagulation with enoxaparin 80 mg every 12 h for an expected 3 months duration, with reassessments in the Vascular and Maxillofacial Surgery clinics.

Discussion

Odontogenic infections, such as abscesses of the 3rd molar tooth, are classified according to the morphological location as peritonsillar, pharyngeal or submandibular infections. The severity of these infections increases with lack of adequate treatment, mainly when there is no effective septic focus control, potentially evolving into severe DNSI, a complication of which this case is an example [1,4,5].

Because of its good sensitivity to characterize soft tissues (varying between 60%–100%), contrast-enhanced cervical CT is often used as the gold standard method to assess the extent of DNSI [3]. Ultrasonography is easily available and free of ionizing radiation, but it is less sensitive for deeper cervical tissues and for recently formed thrombi in case of thrombotic complications [11]. Concerning airway management, these lesions most frequently affect the airway at the level of the epiglottis or aryepiglottic fold. When performed by experienced physicians, fiberoptic intubation might be the first choice to secure the airway in these patients, providing a safe and atraumatic procedure [1,3].

Although without all the classical features, we consider that this clinical case may be interpreted as LS. No bacteraemia or metastatic infectious lesions were identified, but the patient was previously under broad spectrum antibiotic therapy, and the first blood cultures were collected after the first administration of intravenous antibiotics. Some reports have noticed a resurgence of LS in the recent years, sometimes without the full traditional presentation. One of the proposed hypotheses for that are the educational campaigns and trends against prescribing antibiotics for sore throats or upper airways infections that may lead to more cases developing complications that would potentially have been prevented otherwise [16].

The causative organisms of internal jugular vein thrombophlebitis are usually members of the normal oropharyngeal flora. The most commonly and historically described pathogen is the anaerobe *Fusobacterium necrophorum*. Other pathogens include other *Fusobacterium* species and also other organisms such as *Eikenella corrodens*, *Porphyromonas asaccharolytica*, *Bacteroides* spp., as well as streptococci, including *Streptococcus pyogenes* or *Streptococcus anginosus*-group (also known as the *S. milleri* group: *S. anginosus*, *S. intermedius* and *S. constellatus*). Even *Klebsiella pneumoniae* has been described [11,12,14].

Regarding septic focus control, it is evident from the literature review that the priority in treatment of LS involves immediate intravenous broad spectrum antibiotic therapy with anaerobic coverage until the organism and its susceptibility has been determined, alongside surgical drainage of the infected site. Most microbiologists recommend beta-lactamase-resistant antibiotics with anaerobic activity. Once the microbial agent is confirmed by the laboratory, therapy should be targeted [10,11]. *F. necrophorum* is usually susceptible to penicillin, clindamycin, metronidazole and

chloramphenicol. Resistance to penicillin is not found at a relevant frequency. Mean described duration of antibiotic treatment is 4 weeks, but it ranges from 10 days to 8 weeks [11,17]. Given the Gram stain results and evidence of soft tissue emphysema, we continued the empiric antibiotic coverage. After nearly 3 weeks of almost daily surgical drainage and monitoring for clinical resolution and control of septic focus, antibiotics were discontinued.

The role of corticosteroids in the management of deep cervicofacial infections still lacks consensus [11,16]. However, optimal management has been studied as new evidence and reports emerge, and it seems that short-term use of high-dose corticosteroids, as an adjunctive therapy to intravenous antibiotics with proper incision and drainage as clinically needed, is safe and effective in the management of various cervicofacial infections. In several retrospective studies, no negative side effects from the acute use of corticosteroids were reported, but their type and dosage regimens were not recorded in detail [18]. Further investigation is needed to determine the role of corticosteroids in the treatment of patients with DNSI.

Currently, the most controversial role in LS management is the use of anticoagulation, due to its rarity and subsequent lack of controlled studies [12]. The most pertinent questions to answer when anticoagulation is initiated are why and for how long to maintain it. It has been argued that thrombosis associated with LS will spontaneously resolve, but it is also unclear if anticoagulation will hasten the resolution of thrombosis [19]. Successful treatment has been described in patients with or without anticoagulation, in conjunction with antimicrobial therapy [11,12,17]. The American College of Chest Physicians 2012 guidelines recommend anticoagulation for 3 months, with associated reduction in recurrent thromboembolism in patients with bland internal jugular vein thrombosis [19]. Some authors strongly recommend anticoagulation for a select group of patients with: a) lack of response despite 48–72 hours of adequate antimicrobial therapy, b) persistent bacteremia, c) underlying thrombophilia and/or d) progression to intracranial thrombosis [12,17,20]. In patients where anticoagulation has been initiated, optimal duration is unclear and may range from 2 weeks to 6 months [20]. In some cases, internal jugular venous thrombosis may persist after infection has been resolved and even despite anticoagulation, while others have reported resolution just after 2 weeks [20,21].

Considering all these aspects, LS should be considered in the differential diagnosis in patients presenting with persistent sore throat, mastoiditis or recent history of a dental procedure, accompanied with neck pain and swelling, potentially involving the airway. Blood cultures should be obtained prior to antibiotic therapy and CT imaging of the neck with intravenous contrast should be performed. The treatment in DNSI and LS involves proper antibiotic therapy and surgical drainage of the infected site, while anticoagulation therapy in the latter, although controversial, should probably be considered in selected cases. The benefits of adjunctive corticotherapy are yet to be proven. These interventions will enable timely diagnosis and treatment, with improved outcome.

Sources of funding

The authors did not receive any specific grant from funding agencies in the public, commercial or not-for-profit sectors.

Informed consent

Written informed consent was obtained from the patient for publication of this case report and accompanying images. A copy of the written consent is available for review by the Editor-in-Chief of this journal on request.

CRedit authorship contribution statement

Fábio Videira Santos: Conceptualization, Methodology, Writing - original draft, Writing - review & editing. **Sara Xavier Pires:** Writing - original draft, Writing - review & editing. **Cristina Pereira:** Writing - original draft, Writing - review & editing. **Lúcia Gonçalves:** Writing - original draft, Writing - review & editing. **Sara Martins:** Writing - original draft, Writing - review & editing. **Irene Aragão:** Supervision, Visualization, Writing - review & editing.

Declaration of Competing Interest

The authors declare that they have no conflict of interest.

References

- [1] Boscolo-Rizzo P, Stellin M, Muzzi E, Mantovani M, Fuson R, Lupato V, et al. Deep neck infections: a study of 365 cases highlighting recommendations for management and treatment. *Eur Arch Otorhinolaryngol* 2012;269(4):1241–9, doi:http://dx.doi.org/10.1007/s00405-011-1761-1.
- [2] Chow A. In: Durand M, Sullivan M, editors. *Deep neck space infections in adults*. UpToDate; 2009. . [Accessed 5 June 2019] <https://www.uptodate.com/contents/deep-neck-space-infections-in-adults>.
- [3] Cho SY, Woo JH, Kim YJ, Chun EH, Han JI, Kim DY, et al. Airway management in patients with deep neck infections: a retrospective analysis. *Medicine* 2016;95(27):e4125, doi:http://dx.doi.org/10.1097/md.0000000000004125.
- [4] Huang TT, Liu TC, Chen PR, Tseng FY, Yeh TH, Chen YS. Deep neck infection: analysis of 185 cases. *Head Neck* 2004;26(10):854–60, doi:http://dx.doi.org/10.1002/hed.20014.
- [5] Alegbeleye BJ. Deep neck infection and descending mediastinitis as lethal complications of dentoalveolar infection: two rare case reports. *J Med Case Rep* 2018;12(1):195, doi:http://dx.doi.org/10.1186/s13256-018-1724-x.
- [6] Russell MD, Russell MS. Urgent infections of the head and neck. *Med Clin North Am* 2018;102(6):1109–20, doi:http://dx.doi.org/10.1016/j.mcna.2018.06.015.
- [7] Bakir S, Tanriverdi MH, Gun R, Yorgancilar AE, Yildirim M, Tekbas G, et al. Deep neck space infections: a retrospective review of 173 cases. *Am J Otolaryngol* 2012;33(1):56–63, doi:http://dx.doi.org/10.1016/j.amjoto.2011.01.003.
- [8] Wei D, Bi L, Zhu H, He J, Wang H. Less invasive management of deep neck infection and descending necrotizing mediastinitis: a single-center retrospective study. *Medicine* 2017;96(15):e6590, doi:http://dx.doi.org/10.1097/md.0000000000006590.
- [9] Lemierre A. On certain septicemias due to anaerobic organisms. *Lancet* 1936;227(5874):701–3, doi:http://dx.doi.org/10.1016/S0140-6736(00)57035-4.
- [10] Alves S, Stella L, Carvalho I, Moreira D. Lemierre's syndrome: a disguised threat. *BMJ Case Rep* 2019;12(4):e228397, doi:http://dx.doi.org/10.1136/bcr-2018-228397.
- [11] Johannesen KM, Bodtger U. Lemierre's syndrome: current perspectives on diagnosis and management. *Infect Drug Resist* 2016;9:221–7, doi:http://dx.doi.org/10.2147/IDR.S95050.
- [12] Karkos PD, Asrani S, Karkos CD, Leong SC, Theochari EG, Alexopoulou TD, et al. Lemierre's syndrome: a systematic review. *Laryngoscope* 2009;119(8):1552–9, doi:http://dx.doi.org/10.1002/lary.20542.
- [13] Gupta S, Merchant SS. Lemierre's syndrome: rare, but life threatening - a case report with *Streptococcus intermedius*. *Case Rep Med* 2012;2012:4, doi:http://dx.doi.org/10.1155/2012/624065.
- [14] Gupta N, Kralovic SM, McGraw D. Lemierre syndrome: not so forgotten!. *Am J Crit Care* 2014;23(2):176–9, doi:http://dx.doi.org/10.4037/ajcc2014975.
- [15] Rii JC, Citronberg RJ. *Streptococcus anginosus* isolated in a case of Lemierre syndrome. *Infect Dis Clin Pract* 2008;16(1):57–9, doi:http://dx.doi.org/10.1097/IPC.0b013e31809fe644.
- [16] Zhao A, Samannodi M, Tahir M, Bensman S, Hocko M. Lemierre's syndrome: case report and brief literature review. *IDCases* 2017;10:15–7, doi:http://dx.doi.org/10.1016/j.idcr.2017.07.009.
- [17] Campo F, Fusconi M, Ciotti M, Diso D, Greco A, Cattaneo CG, et al. Antibiotic and anticoagulation therapy in Lemierre's syndrome: case report and review. *J Chemother* 2019;31(1):42–8, doi:http://dx.doi.org/10.1080/1120009X.2018.1554992.
- [18] Kent S, Henneidge A, McDonald C, Henry A, Dawoud B, Kulkarni R, et al. Systematic review of the role of corticosteroids in cervicofacial infections. *Br J Oral Maxillofac Surg* 2019;57(3):196–206, doi:http://dx.doi.org/10.1016/j.bjoms.2019.01.010.
- [19] Kearon C, Akl EA, Comerota AJ, Prandoni P, Bounameaux H, Goldhaber SZ, et al. Antithrombotic therapy for VTE disease: antithrombotic therapy and prevention of thrombosis, 9th ed: American College of Chest physicians evidence-based clinical practice guidelines. *Chest* 2012;141(Suppl. 2):e419S–96S, doi:http://dx.doi.org/10.1378/chest.11-2301.
- [20] Phua CK, Chadachan VM, Acharya R. Lemierre syndrome-should we anticoagulate? A case report and review of the literature. *Int J Angiol* 2013;22(2):137–42, doi:http://dx.doi.org/10.1055/s-0033-1336828.
- [21] Bondy P, Grant T. Lemierre's syndrome: what are the roles for anticoagulation and long-term antibiotic therapy? *Ann Otol Rhinol Laryngol* 2008;117(9):679–83, doi:http://dx.doi.org/10.1177/000348940811700909.