

Received: 2017.01.25
Accepted: 2017.04.17
Published: 2017.08.15

Off-Label Use of Crizotinib as a Neoadjuvant Treatment for a Young Patient When Conventional Chemotherapy Gave No Benefits in Stage IIIA Non-Small Cell Lung Cancer

Authors' Contribution:
Study Design A
Data Collection B
Statistical Analysis C
Data Interpretation D
Manuscript Preparation E
Literature Search F
Funds Collection G

BCDEF 1 **Delphine Dumont**
B 2 **Pascal Dô**
DE 1 **Delphine Lerouge**
D 3 **Gaëtane Planchard**
BE 3 **Marc Riffet**
D 4 **Catherine Dubos-Arvis**
E 1 **Serge Danhier**
BCDEF 2 **Radj Gervais**

1 Department of Radiotherapy, Centre François Baclesse, Caen, France
2 Department of Medicine, Centre François Baclesse, Caen, France
3 Department of Anatomy, Hospital Center University (CHU) Caen, Caen, France
4 Department of Medicine, Centre François Baclesse, Caen, France

Corresponding Author: Delphine Dumont, e-mail: delphine.dumont.27@gmail.com
Conflict of interest: None declared

Patient: **Male, 37**
Final Diagnosis: **Lung adenocarcinoma**
Symptoms: **Cough**
Medication: —
Clinical Procedure: —
Specialty: **Oncology**

Objective: **Unusual setting of medical care**





Background: The treatment of locally advanced non-small cell lung cancer involves a combination of chemotherapy, surgery, and radiotherapy. Each case is discussed and the best strategy is chosen individually, following international guidelines.

Case Report: A 37-year-old man was diagnosed with locally advanced broncho-pulmonary adenocarcinoma (stage IIIA). The disease was stable after 2 cycles of cisplatin plus Navelbine used as neoadjuvant therapy. FISH analysis revealed an ALK rearrangement. The patient then received unlicensed crizotinib as second-line neoadjuvant treatment, which led to an almost complete radiological and metabolic response. A left upper lobectomy was performed, followed by post-operative chemotherapy and radiotherapy. At 18 months post-surgery, the patient is still disease-free according to the last CT scan.

Conclusions: Targeted therapy was an alternative solution when chemotherapy was not helping. Randomized studies are needed to define its precise role in the neoadjuvant scheme.

MeSH Keywords: **Lung Neoplasms • Molecular Targeted Therapy • Neoadjuvant Therapy**

Full-text PDF: <https://www.amjcaserep.com/abstract/index/idArt/903528>

 992  —  2  15



Background

ALK rearrangements were first described 10 years ago, and are present in 3–5% of non-small-cell lung cancers (NSCLC). These rearrangements are more frequent in a subgroup of young NSCLC patients, with a history of smoking, and a histology of adenocarcinoma [1]. Crizotinib is a tyrosine-kinase inhibitor that targets the ALK pathway. Two randomized phase-3 studies have confirmed its superiority over chemotherapy in terms of progression-free survival. In the PROFILE 1007 study, crizotinib was compared to single-agent chemotherapy (either pemetrexed or docetaxel) as a second-line treatment [2]. In the PROFILE 1014 study, in a first-line setting, crizotinib was compared to cisplatin plus pemetrexed chemotherapy [3]. Crizotinib has approval from the European Medicines Agency for use in Europe since 2012, as a first-line treatment for advanced (metastatic or inoperable) NSLCC in adults. In the early stages (I–III) of NSCLC, the use of crizotinib needs to be defined in randomized controlled trials.

Herein, we report on the off-label use of crizotinib as a salvage therapy within a neoadjuvant scheme after failure of standard chemotherapy.

Case Report

A 37-year-old man was diagnosed with locally advanced broncho-pulmonary adenocarcinoma of the left upper lobe in February 2015. He was a former smoker of 15 pack-years, but had stopped smoking at the age of 29. He had no other medical history, except for being overweight (body-mass index >35).

The adenocarcinoma mass was poly-lobed, measured 37×28 mm, with 3 supra centimetric nodes: 1 in the hilar zone and 2 in the homolateral mediastinal zone (6 and 4L areas). All nodes were hypermetabolic on PET scan.

We treated our patient with a curative intent by neoadjuvant chemotherapy of cisplatin plus Navelbine. The disease became stable, according to a CT scan, after 2 cycles of chemotherapy.

We performed off-label molecular analysis on the pre-therapeutic biopsy sample, as the patient was young and a former light smoker. Immunohistochemistry (IHC) and fluorescent *in-situ* hybridization (FISH) revealed that the tumor had an ALK rearrangement (Figure 1) and no *HER2/EGFR/KRAS/BRAF* mutations.

With the patient's informed consent regarding the potential benefits and risks, a switch was made to crizotinib at 250 mg twice daily. This treatment displayed good tolerance, with no visual disturbances, cardiac effects, or elevated transaminases. Early assessment after 4 weeks of treatment, using CT and PET scans, showed a partial response according to RECIST 1.1 criteria, and a significant decrease in hypermetabolism (SUV=2.86 vs. 12.9 on the mass, SUV=2.86 vs. 5.9 on the hilar left node, and no more hypermetabolism in the other lymphatic area) (Figure 2).

Crizotinib was maintained until surgery, for 3 more weeks, and was stopped 48 h before surgery. A left upper lobectomy with node dissection was performed on 29 June, without complications.

Pathological stage was ypT1a N2 MX. The residual mass measured 18×10 mm. The 3 lymph nodes were tumoral with extracapsular spread.

Carboplatin plus pemetrexed was chosen as the adjuvant chemotherapy. Adjuvant radiotherapy was performed according to the LUNG ART study. A dose of 66Gy was delivered in 33 fractions to the primary tumor bed and the involved nodal territory using a 3D conformal technique, with good tolerance [4]. At 18 months post-surgery, on the last evaluation in November 2016, there was no sign of the disease.

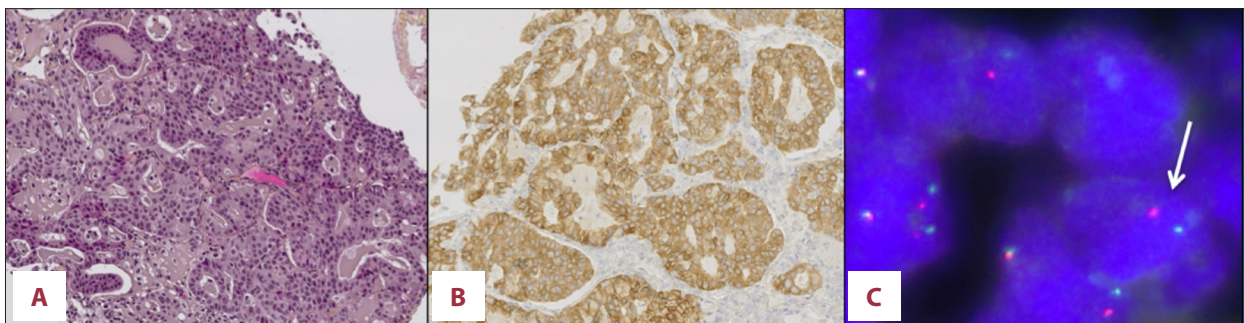


Figure 1. Pre-therapeutic biopsy. (A) Histological aspect of lung adenocarcinoma, in HE staining. (B) Intense cytoplasmic ALK protein expression on immunohistochemistry using 5A4 antibody. (C) FISH aspect with classical ALK rearrangement: split of green and red spots (white arrow), showing ALK and EML4 breaking point on exon 20 (ALK kinase domain).

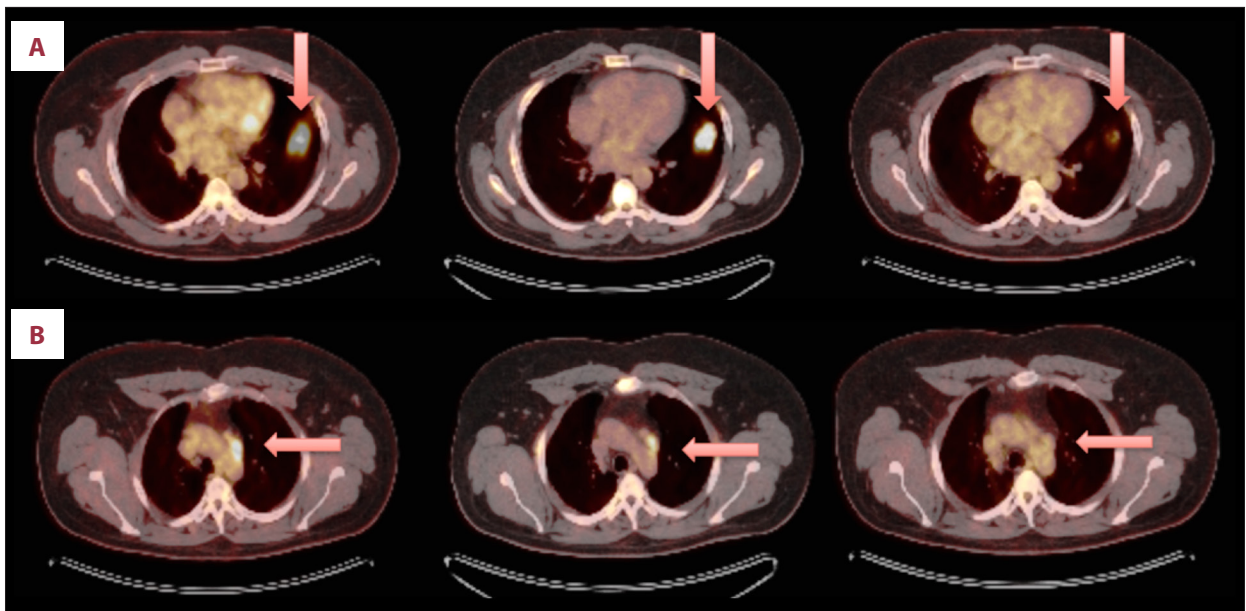


Figure 2. Chest PET scan images before and after each treatment. (A) Shows the hypermetabolism of the mass, (B) shows one of the mediastinal node. In the **left column**: PET scan image at diagnosis; in the **middle column**: after 2 cycles of Cisplatin-Navelbine; on the **right column**: after 4 weeks of Crizotinib.

Discussion

Treatment of each case of stage IIIA NSCLC is chosen individually, with discussion and following guidelines. We are used to associating systemic and local treatment. We do not know if surgery should be preferred to radiotherapy as local treatment, and patients often receive multimodality therapy [5,6]. Systemic treatment has so far consisted of chemotherapy. Recently, targeted therapy has demonstrated a higher response rate for stage IV NSCLC with molecular alteration. As the main purpose of systemic treatment in this setting is to achieve the best downstaging [7], we think that targeted therapy should be considered as an alternative option when conventional chemotherapy fails. Our patient was treated according to this approach.

However, severe adverse events have been reported with crizotinib, even those of grade 4 or 5; thus, this treatment must only be proposed in very specific cases and given to fully informed patients [8].

Despite the subtotal metabolic response seen on the earlier PET scan, the lymph nodes remained tumoral in pathological analyses and ALK status was confirmed on the resected specimen. Because an active ALK tumor was found after 7 weeks of treatment (same histological aspect in the initial tumor site), we do not yet know the perfect timing for surgery, and a longer duration of neoadjuvant treatment might be more beneficial.

After surgery, adjuvant treatment was discussed: there were 2 main options. One was to pursue treatment with a

tyrosine-kinase inhibitor (TKI), but there is no data on its potential benefits or the most appropriate duration of treatment. Because cisplatin plus Navelbine have not been shown to be as effective as neoadjuvant, we chose to use 2 cycles of carboplatin plus pemetrexed because some data suggest that pemetrexed has better efficacy on ALK-positive tumors [2,9].

Data have been published on the use of EGFR TKIs as a neoadjuvant and/or an adjuvant treatment, with or without chemotherapy, in patients with a curable disease, and have shown encouraging results [10]. Comparative trials are ongoing in Asia [11,12].

This is the second case, to our knowledge, reported in the English literature of a patient treated with crizotinib in a neoadjuvant setting for bronchial cancer showing a good tumoral downstaging [13]. An Irish team also used crizotinib with success as a salvage second-line neoadjuvant treatment on a patient with an advanced inflammatory myofibroblastic tumor, a rare sarcoma with an ALK gene rearrangement, when ifosfamide and doxorubicin had failed [14].

Conclusions

We think that crizotinib, as with other targeted therapies, can be an option in neoadjuvant schemes, especially when conventional chemotherapy gives no benefits. Controlled studies are needed to establish the role of crizotinib in patients with locally advanced disease, and work is already ongoing to identify early mechanisms of resistance [15].

Acknowledgements

Lilly's team helped us with translation.

References:

1. Shaw AT, Yeap BY, Mino-Kenudson M et al: Clinical features and outcome of patients with non-small-cell lung cancer who harbor EML4-ALK. *J Clin Oncol*, 2009; 27: 4247–53
2. Shaw AT, Kim DW, Nakagawa K et al: Crizotinib versus chemotherapy in advanced ALK-positive lung cancer. *N Engl J Med*, 2013; 368(25): 2385–94
3. Solomon BJ, Mok T, Kim DW et al: First-line crizotinib versus chemotherapy in ALK-positive lung cancer. *N Engl J Med*, 2014; 371(23): 2167–77
4. Le Pêchoux C: Role of postoperative radiotherapy in resected non-small cell lung cancer: A reassessment based on new data. *Oncologist*, 2011; 16(5): 672–81
5. Albain KS, Swann RS, Rusch VW et al: Radiotherapy plus chemotherapy with or without surgical resection for stage III non-small-cell lung cancer: A phase III randomised controlled trial. *Lancet*, 2009; 374: 379–86
6. Betticher DC, Hsu Schmitz SF, Tötsch M et al: Swiss Group for Clinical Cancer Research (SAKK). Prognostic factors affecting long-term outcomes in patients with resected stage IIIA pN2 non-small-cell lung cancer: 5-year follow-up of a phase II study. *Br J Cancer*, 2006; 94(8): 1099–106
7. Decaluwé H, De Leyn P, Vansteenkiste J et al: Surgical multimodality treatment for baseline resectable stage IIIA-N2 non-small cell lung cancer. Degree of mediastinal lymph node involvement and impact on survival. *Eur J Cardiothorac Surg*, 2009; 36(3): 433–39
8. Sato Y, Fujimoto D, Shibata Y et al: Fulminant hepatitis following crizotinib administration for ALK-positive non-small-cell lung carcinoma. *Jpn J Clin Oncol*, 2014; 44(9): 872–75
9. Camidge DR, Kono SA, Lu X et al: Anaplastic lymphoma kinase gene rearrangements in non-small cell lung cancer are associated with prolonged progression-free survival on pemetrexed. *J Thorac Oncol*, 2011; 6(4): 774–80
10. Zhai H, Zhong W, Yang X, Wu YL: Neoadjuvant and adjuvant epidermal growth factor receptor tyrosine kinase inhibitor (EGFR-TKI) therapy for lung cancer. *Transl Lung Cancer Res*, 2015; 4(1): 82–93
11. Sun Yat-sen University. A Multicenter Phase II Trial of Neoadjuvant Gefitinib Followed by Surgery, Followed by Adjuvant Gefitinib in Patients With Unresectable Stage III Non-Small Cell Lung Cancer Harboring Activating Epidermal Growth Factor Receptor Mutations. *ClinicalTrials.gov* [Internet]. Bethesda (MD): National Library of Medicine (US). 2000. Available from: <https://clinicaltrials.gov/show/NCT02347839>. NLM identifier: NCT02347839
12. AIO-Studien-gmbH, AstraZeneca. Induction Therapy With Gefitinib Followed by Taxane Platinum Chemotherapy and Intercalated Gefitinib in NSCLC Stages II-IIIb With Activating EGFR Mutation – A Single Arm Phase II Trial. *ClinicalTrials.gov* [Internet]. Bethesda (MD): National Library of Medicine (US). 2000. Available from: <https://clinicaltrials.gov/show/NCT02326285>. NLM identifier: NCT02326285.
13. Kaseda K, Watanabe K, Asakura K, Kazama A: Surgical resection of lung adenocarcinoma after crizotinib treatment: Report of a case. *World J Surg Oncol*, 2015; 13: 74
14. Rafee S, Elamin YY, Joyce E et al: Neoadjuvant crizotinib in advanced inflammatory myofibroblastic tumour with ALK gene rearrangement. *Tumori*, 2015; 101(2): e35–39
15. McCoach CE, Bivona TG, Blakely CM, Doebele RC: Neoadjuvant oncogene-targeted therapy in early stage non-small-cell lung cancer as a strategy to improve clinical outcome and identify early mechanisms of resistance. *Clin Lung Cancer*, 2016; 17(5): 466–69