


CASE REPORT

Open Access



Recurrent mantle cell lymphoma in the uterine cervix: a case report

Giusi Santangelo^{*} , Innocenza Palaia, Giorgia Perniola, Anna Di Pinto, Angela Musella, Federica Tomao, Margherita Fischetti, Carolina Sassu, Mariagrazia Piccioni, Violante Di Donato and Pierluigi Benedetti Panici

Abstract

Background: Mantle cell lymphoma is one of several subtypes of non-Hodgkin lymphoma. Cervical relapse of non-Hodgkin lymphoma is a very rare condition that has a variable and nonspecific presentation and may resemble other neoplastic or inflammatory conditions.

Case presentation: Our patient was a 58-year-old Caucasian woman who experienced relapse of mantle cell lymphoma with cervical localization. She complained of postmenopausal vaginal bleeding, bladder pressure, and rapid growth of a cervical lesion. An irregular tumor mass of the cervix was visualized during gynecological examination, with findings highly suggestive of locally advanced cervical cancer. Surprisingly, the biopsies showed an extra nodal relapse of mantle cell lymphoma in the cervix. The rarity of this presentation and the scarcity of clinical studies make this type of recurrence very aggressive and difficult to treat.

Conclusions: Obtaining a definitive histological diagnosis by biopsy or surgical resection and starting appropriate therapy are essential for recovery and treatment of these patients, even if the prognosis is poor.

Keywords: Aggressive non-Hodgkin lymphoma, Cervix, Mantle cell lymphoma, Quality of life, Relapse, Postmenopausal vaginal bleeding

Introduction

Mantle cell lymphoma (MCL) is one of several subtypes of non-Hodgkin lymphoma (NHL). MCL is the rarest of the subtypes, accounting for about 6% of all NHL cases in the United States and Europe. It is the result of a malignant transformation of a B lymphocyte in the outer edge of a lymph node follicle, called the “mantle zone.” Those cells can spread through the lymphatics and blood to other lymph nodes or tissues, such as the bone marrow, liver, and gastrointestinal tract. MCL has the worst prognosis among lymphomas, with a median survival of approximately 3–4 years [1].

Lymphoid neoplasms of the female genital organs are relatively rare, accounting for less than 5% of extranodal

lymphomas. We conducted a literature search of PubMed and MEDLINE using the keywords “cervix,” “mantle cell lymphoma,” and “lymphoma.” We found no reports of MCL involving the uterine cervix. We present a case of a patient with a cervical relapse of NHL with a rare presentation. This condition is very rare and, to our knowledge, has never been described in the literature. The aim of this case report is to remind clinicians to think of cervical relapse of NHL in cases of vaginal bleeding in women with a history of NHL.

Case presentation

A 58-year-old Caucasian woman complaining vaginal bleeding and a cervical mass was admitted to our hospital. She reported menopause at 52 years. She had a history of mantle cell NHL. She had no comorbidity, did not take drugs, denied smoking and the use of alcohol, and denied any family history of cardiovascular diseases

* Correspondence: giusi.santangelo@uniroma1.it
Department of Maternal and Child Health and Urological Sciences, Policlinico “Umberto I”, University “Sapienza”, Viale del Policlinico, 155, 00161 Rome, Italy



© The Author(s). 2020 **Open Access** This article is licensed under a Creative Commons Attribution 4.0 International License, which permits use, sharing, adaptation, distribution and reproduction in any medium or format, as long as you give appropriate credit to the original author(s) and the source, provide a link to the Creative Commons licence, and indicate if changes were made. The images or other third party material in this article are included in the article's Creative Commons licence, unless indicated otherwise in a credit line to the material. If material is not included in the article's Creative Commons licence and your intended use is not permitted by statutory regulation or exceeds the permitted use, you will need to obtain permission directly from the copyright holder. To view a copy of this licence, visit <http://creativecommons.org/licenses/by/4.0/>. The Creative Commons Public Domain Dedication waiver (<http://creativecommons.org/publicdomain/zero/1.0/>) applies to the data made available in this article, unless otherwise stated in a credit line to the data.

and neoplasia. The result of her neurological examination was negative. Clinically, the patient was in good general condition and reported weight loss in the last year following her diagnosis of NHL. At admission, her vital signs were good; her pulse was 76 beats/minute, her blood pressure was 120/80 mmHg, and her body temperature was 36.5 °C.

Briefly, in March 2018, she presented with right groin and thoracic lymph node involvement (stage IIIa). Treatment consisted of chemotherapy with R-CHOP (rituximab, cyclophosphamide, doxorubicin, vincristine, prednisone) and R-DHAP (rituximab, cisplatin, cytarabine, dexamethasone) for six cycles, alternating. For central nervous system prophylaxis, four lumbar punctures with methotrexate were performed. In October 2018, she received chemotherapy with FEAM (fotemustine, cytarabine, etoposide, melphalan) sequenced by infusion of autologous peripheral stem cells. The transplant was complicated by septic shock and atrial fibrillation. In November 2018, the patient was discharged in good general condition. She had regular negative follow-up results until January 2019, when positron emission tomography–computed tomography (CT) showed a hypercapitation at the level of the uterine cervix (maximum standardized uptake value 11.8) (Figs. 1 and 2).

In April 2019, the patient was admitted to our department for a gynecological examination. She complained of postmenopausal vaginal bleeding in the last 2 months, bladder pressure, and rapid growth of a cervical lesion.

An irregular tumor mass of the cervix was visualized during gynecological examination, highly suggestive of locally advanced cervical cancer. However, the surface appeared smooth with no exophytic or erosive components, and the lesion was measured as 5 cm in diameter. The disease extended into the right paracervical and parametrial tissue, invading the proximal two-thirds of the vaginal submucosa. Ultrasound examination showed a 5-cm highly vascularized cervical tumor extending into the right parametrium and bladder without mucosal infiltration. Magnetic resonance imaging (MRI) was performed, showing a locally invasive tumor with

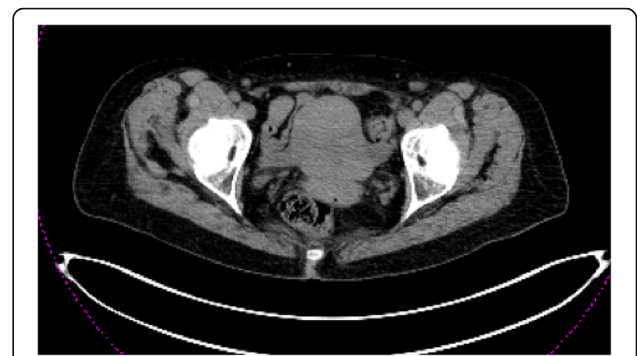

Fig. 2 Computed tomographic scan

heterogeneous high-intensity signaling on T2-weighted images, most likely originating from the cervix, measuring 50 × 33 mm (Fig. 3). Invasion into one-third superior of the vagina, bladder, and bilateral parametria was visualized. The CT scan showed a similar extent of cervical tumor. No enlarged lymph nodes or lesions in the liver, lung, or bone were visualized.

Surprisingly, the biopsies revealed a neoplastic cell with a positive test result for CD20 and Ki67 100% and negative test results for CD3, CD5, CD10, BCL2, S100, and cytokeratin. These findings confirmed the diagnosis of a relapse of MCL with cervical localization.

She was referred to the hematology department and was started on ibrutinib 560 mg/day from July 2019 to October 2019. Transvaginal ultrasound in September 2019 documented persistence and augmented volume (41 × 30 × 33 mm) of the cervical lesion.

The patient is still under treatment with ibrutinib, but a whole-body CT scan showed persistence of disease, and her general condition is poor, with severe asthenia and loss of hearing.

Discussion

Our patient presented with vaginal bleeding; in menopause, this sign is suspicious for uterine (endometrial and cervical) neoplasia. At admission, the first suspicion

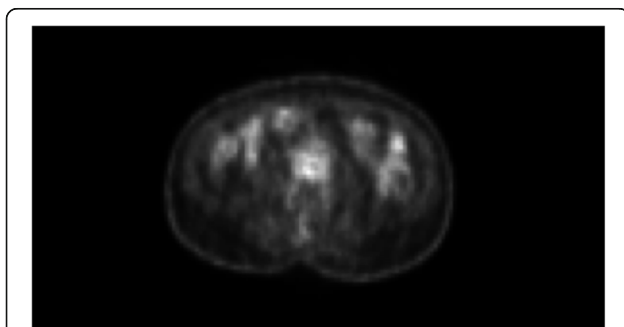


Fig. 1 Positron emission tomographic images

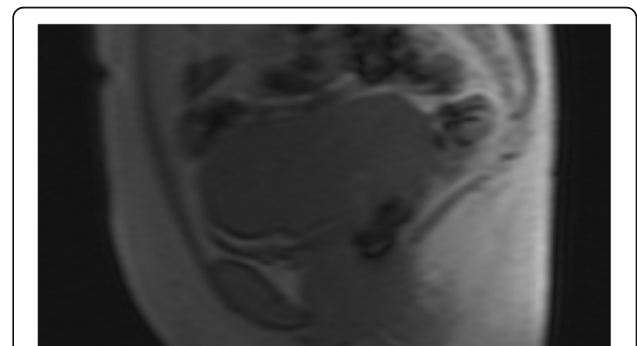


Fig. 3 Magnetic resonance imaging studies

was of cervical neoplasia, despite the NHL history of our patient. The clinical examination did not drive the clinicians through the differential diagnosis, because the follow-up results had been negative until that moment. In the literature, there are no studies that have described cervical relapse of NHL, so clinicians must keep cervical relapse of NHL in mind in cases of vaginal bleeding in women with a history of NHL.

MCL is a relatively uncommon subtype of lymphoid malignancy and represents 5–7% of malignant lymphoma in Western Europe. The annual incidence of this disease has increased during recent decades to 1–2 per 100,000.

MCL is more common in men than in women, with a 3:1 ratio [2]. Extranodal involvement of NHL is a common finding. However, only 10–35% of NHL cases present with primary extranodal NHL. Female genital tract involvement can in rare cases be a site of origin [3]. Extranodal lymphoma occurs in approximately 40% of all patients with lymphoma; extranodal disease is more common with NHL. It causes many deaths worldwide, and its incidence is increasing. It represents a heterogeneous group of neoplasms originating from lymphocytes. Diffuse large B-cell lymphoma is the most common histological NHL subtype in adult patients [4].

The majority of relapses in NHL occur in the first 2 years after the completion of treatment. The majority of relapses are symptomatic, and they are rarely identified by surveillance imaging alone. Extranodal involvement often appears in the gastrointestinal system, followed by skin (10% of cases) [5].

In 1972, Freeman *et al.* reported a case series of 1467 extranodal lymphomas, of which only 3 (0.2%) were found to originate in the cervix [6]. A publication in 1995 stated that 18 (0.6%) of 2733 NHL cases originated from the uterus, cervix, or paracolpos [7]. Lymphoma accounts for only 0.3% of all cervical cancers, making it a rare malignancy. In recent decades, the incidence of extranodal NHL has increased. The hypothesized etiology of the increase includes immunosuppressive treatments, human immunodeficiency virus/acquired immunodeficiency syndrome-related immunosuppression, environmental exposure to pesticides, and improved diagnostic techniques [8].

Due to the rarity of extranodal cervical NHL, no prospective randomized trials exist to evaluate diagnostic tools or treatment options. The review below is therefore based mostly on case reports and small case series. Pelvic ultrasound and CT are useful in the diagnosis and staging of cervical malignancies. However, MRI is the most effective method for imaging evaluation of the cervix. MRI could possibly be used to differentiate cervical and uterine lymphomas from other entities. Cervical NHL is best defined on the basis of T2-weighted images or contrast-enhanced T1-weighted images. Suggestive

MRI findings for lymphomas include an isointense or hypointense signal relative to the myometrium on T1-weighted images, relatively homogeneous high-intensity signaling on T2-weighted images, and lack of clear margination with moderate uniform enhancement [9].

For the same reason, there is no consensus in the literature concerning the optimal management of cervical extranodal NHL. Treatment regimens of cervical extranodal NHL have been reported in several case reports and case series, including surgery, chemotherapy, radiotherapy, or a combination of two or three treatments.

Conclusion

Cervical relapse of NHL is a very rare condition and has a variable and nonspecific presentation, and it may resemble other neoplastic or inflammatory conditions. Obtaining a definitive histological diagnosis by biopsy or surgical resection and starting appropriate therapy are essential for recovery and long-term survival of these patients, in whom the prognosis is poor.

Acknowledgements

Not applicable.

Authors' contributions

IP and PBP conceived, designed, and coordinated the project. GS, ADP, and CS collected and assembled data. AM, MF, and MP, drafted the manuscript. VDD and FT edited the manuscript. GP and IP critically revised the manuscript. IP and PBP gave final approval of the manuscript. The author(s) read and approved the final manuscript.

Funding

The authors declare that they have no competing interests.

Availability of data and materials

Not applicable.

Ethics approval and consent to participate

Not applicable.

Consent for publication

Written informed consent was obtained from the patient for publication of this case report and any accompanying images. A copy of the written consent is available for review by the Editor-in-Chief of this journal.

Competing interests

The authors declare that they have no competing interests.

Received: 29 May 2020 Accepted: 7 August 2020

Published online: 02 September 2020

References

- Zheng XD, Zhang YL, Xie JL, Zhou XG. Primary cutaneous mantle cell lymphoma: report of a rare case. *World J Clin Cases*. 2020;8(8):1507–14.
- Dreyling M, Campo E, Hermine O, Jerkeman M, Le Gouill S, Rule S, *et al.* Newly diagnosed and relapsed mantle cell lymphoma: ESMO clinical practice guidelines for diagnosis, treatment and follow-up. *Ann Oncol*. 2017; 28(Suppl 4):iv62–71.
- De Greve T, Vanwalleghem L, Van Hoof A, *et al.* An unusual cervical tumor as presentation of a non-Hodgkin lymphoma. *Case Rep Obstet Gynecol*. 2014;2014:549619.
- D'Amore F, Christensen BE, Brincker H, Pedersen NT, Thorling K, Hastrup J, *et al.* Clinicopathological features and prognostic factors in extranodal non-Hodgkin lymphomas. *Eur J Cancer*. 1991;27(10):1201–8.

5. Malkan UY, Gunes G, Yayar O, Demiroglu H. Diffuse large B cell lymphoma with extensive cutaneous relapse. *Case Rep Med.* 2015;2015:137682.
6. Freeman C, Berg JW, Cutler SJ. Occurrence and prognosis of extranodal lymphomas. *Cancer.* 1972;29(1):252–60.
7. Sfroh EL, Besa PC, Cox JD, Fuller LM, Cabanillas FF. Treatment of patients with lymphomas of the uterus or cervix with combination chemotherapy and radiation therapy. *Cancer.* 1995;75(9):2392–9.
8. Trenhaile T, Killackey M. Primary pelvic non-Hodgkin's lymphoma. *Obstet Gynecol.* 2001;97:717–20.
9. Marín C, Seoane JM, Sánchez M, Ruiz Y, García JA. Magnetic resonance imaging of primary lymphoma of the cervix. *Eur Radiol.* 2002;12(6):1541–5.

Publisher's Note

Springer Nature remains neutral with regard to jurisdictional claims in published maps and institutional affiliations.

Ready to submit your research? Choose BMC and benefit from:

- fast, convenient online submission
- thorough peer review by experienced researchers in your field
- rapid publication on acceptance
- support for research data, including large and complex data types
- gold Open Access which fosters wider collaboration and increased citations
- maximum visibility for your research: over 100M website views per year

At BMC, research is always in progress.

Learn more biomedcentral.com/submissions

