

# Intracranial Hemorrhage Caused by Bacterial Meningitis: Case Report and Review of the Literature

## Abstract

Hemorrhagic stroke is an extremely rare complication in bacterial meningitis. Therefore, the incidence and prognosis have not been fully clarified. In this case report, we describe a case of intracranial hemorrhage caused by bacterial meningitis, which originated from paranasal sinusitis. A man visited the hospital due to fever, nonproductive cough, and oppressive pain of cheek. He was diagnosed with purulent sinusitis and received antibiotics. However, he suddenly developed a severe headache and came to our department. Computed tomography scan revealed right subcortical hematoma. We performed hematoma evacuation, but headache and fever did not cease. From the analysis of the cerebrospinal fluid, he was diagnosed with cerebral hemorrhage caused by meningitis and treated with broad-spectrum antibiotics. Through this treatment, his condition rapidly improved. Hemorrhagic stroke is a rare complication of bacterial meningitis, but if this condition develops, then, there is a high risk of mortality and morbidity.

**Keywords:** Bacterial meningitis, hemorrhagic stroke, intracranial hemorrhage

## Introduction

Mortality and morbidity of bacterial meningitis continue to be substantial. The important complication is cerebrovascular disorder that arises during the acute phase of the disease, and it eventually causes secondary brain damage.<sup>[1]</sup>

Several studies on bacterial meningitis with ischemic stroke have been published,<sup>[2-4]</sup> however, hemorrhagic stroke is an exceedingly rare. Various developmental mechanisms, such as local hyperperfusion and microaneurysm are proposed,<sup>[5]</sup> but the detailed incidences and prognoses have not been fully clarified.<sup>[4]</sup> We herein report a rare case of intracranial hemorrhage. It is thought to have been caused by bacterial meningitis, which originated from paranasal sinusitis. In addition, we summarize and review on this subject.<sup>[6]</sup> Regarding publication, the consent of the patient has been obtained in this case.

## Case Report

A 36-year-old male visited a hospital (Department of Internal Medicine) because of fever. He had no history of hypertension, diabetes, heart disease, and malignant tumor. Computed tomography (CT) scan

revealed fluid collection in the right maxillary paranasal sinus [Figure 1a].<sup>[3]</sup> However, there were no abnormal findings in the cranium [Figure 1b and c].<sup>[3]</sup> On physical examination, he had a low-grade fever, a nonproductive cough, and an oppressive pain of cheek. He was diagnosed with purulent sinusitis and received antibiotics (CAM 400 mg/day). However, his physical condition did not improve after the treatment. Suddenly, he developed a severe headache and came to our department after 9 days from the first consultation. A cranial CT scan performed immediately revealed right subcortical hematoma from right temporal to parietal lobe. Size of hematoma was 40 mm × 50 mm × 60 mm, and its volume was approximately 60 cc [Figure 2a and b].<sup>[3]</sup>

At the time of our first medical check-up, his consciousness was clear (Glasgow coma scale [GCS] 15), and did not recognize neurological deficit. However, his state of consciousness continued to worsen gradually (GCS 10), and left hemiparesis was noted. Secondary CT scan conducted after 3 h did not illustrate the expansion of hematoma but showed slight aggravation of midline-shift caused by brain edema [Figure 2c].<sup>[3]</sup> We performed hematoma evacuation by

**Atsushi Matsumoto,  
Shogo Mino,  
Tadashi Nishiyama**

*Nishiyama Neurosurgery  
Hospital, 593-1, Kamo-cho,  
Sakaide-shi, Kagawa, Japan*

**Address for correspondence:**  
Dr. Atsushi Matsumoto,  
593-1, Kamo-Cho, Sakaide-Shi,  
Kagawa 762-0023, Japan.  
E-mail: a\_met@med.kagawa-u.  
ac.jp

Access this article online

Website: [www.asianjns.org](http://www.asianjns.org)

DOI: 10.4103/ajns.AJNS\_239\_17

Quick Response Code:



**How to cite this article:** Matsumoto A, Mino S, Nishiyama T. Intracranial hemorrhage caused by bacterial meningitis: Case report and review of the literature. *Asian J Neurosurg* 2019;14:234-6.

This is an open access journal, and articles are distributed under the terms of the Creative Commons Attribution-NonCommercial-ShareAlike 4.0 License, which allows others to remix, tweak, and build upon the work non-commercially, as long as appropriate credit is given and the new creations are licensed under the identical terms.

For reprints contact: [reprints@medknow.com](mailto:reprints@medknow.com)

the frontotemporal craniotomy. Postoperative CT scan revealed complete removal of hematoma and improvement of midline-shift [Figure 2d].<sup>[3]</sup> On the other hand, for the purpose of evaluating cerebral vessel closely, digital subtraction angiography (DSA) was performed before the operation, but obvious abnormalities were not found in the four-vessel study.<sup>[3]</sup>

After the operation, his consciousness became clear, and left hemiparesis was completely improved. Intravenous antibiotics therapy (CEZ 2 g/day) was performed to prevent postoperative infection due to craniotomy. However, headache and fever were not alleviated. We suspected bacterial meningitis and performed lumbar puncture on postoperative day 3.

Analysis of the cerebrospinal fluid (CSF) revealed colorless and transparent fluid, and the pressure was approximately 300 mmH<sub>2</sub>O. Laboratory analysis indicated the following results: white blood cell count of 592 cells/ $\mu$ L with 90% polymorphonuclear leukocytes, protein at 155 mg/dL, glucose at 68 mg/dL, and CSF/blood ratio of 0.56. In addition, Nonne-Apelt and Pandy reactions were positive. From the above, he was diagnosed with cerebral hemorrhage caused by meningitis, which spread from sinusitis. We changed antibiotics to MEPM 3 g/day, and rapid alleviation of a headache and fever was observed. While unilateral spatial neglect and homonymous lower quadrantanopia remained, he could be discharged on foot.

## Discussion

Cerebrovascular disorder is a determinant of unfavorable outcome in bacterial meningitis, and it manifests clinically as a focal neurological deficit or as a decrease in consciousness.<sup>[6]</sup> Ischemic stroke is the most common complication while hemorrhagic stroke such as subarachnoid hemorrhage (SAH) or intracranial hemorrhage (ICH) is extremely rare.<sup>[1]</sup>

In our extensive literature search, only five articles on the complications of cerebral hemorrhage related to bacterial meningitis have been disclosed except for case report and case series [Table 1].<sup>[3]</sup>

According to them, the incidences of cerebrovascular disorder were 4.6%–19.9%,<sup>[7-9]</sup> and most of them were ischemic diseases (68.2%–100%).<sup>[2,7-9]</sup> On the other hand, the incidences of pure-hemorrhagic complication were 0%–3.3%.<sup>[5,7-10]</sup> In these reviews, we excluded cases of hemorrhagic infarction from pure-hemorrhagic complication.<sup>[7-10]</sup> Furthermore, micro-bleeding in T2\* and hematoma with abscess were also excluded.<sup>[10]</sup> In cerebral hemorrhage, ICH and SAH were included. ICH was found in various parts of basal ganglia or subcortical. Several articles clarified that once hemorrhagic stroke occurred, the mortality rate was extremely high (63%–66.6%).<sup>[5,10]</sup>

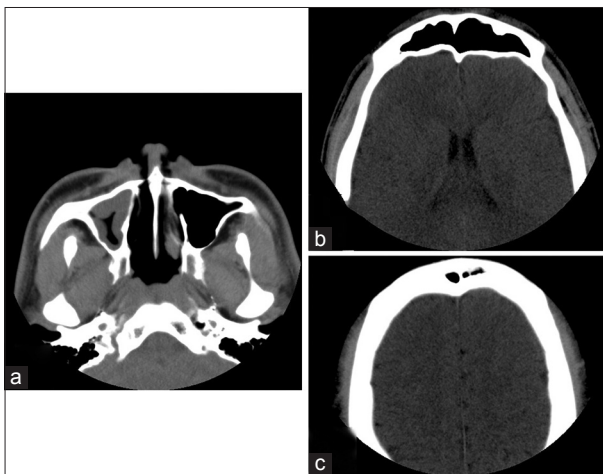

Figure 1: Computed tomography taken at the first consultation. (a) There was a fluid collection in the right maxillary paranasal sinus. (b and c) There were no abnormal findings in the cranium

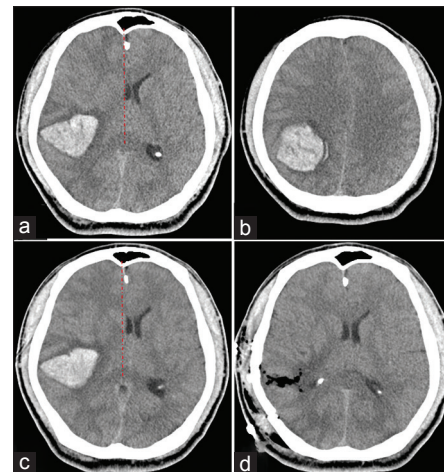


Figure 2: (a and b) First, computed tomography scan revealed right subcortical hematoma. (c) Second, computed tomography scan revealed that hematoma did not expand; however, midline-shift caused by brain edema was slightly worsened. Red dotted lines indicate the median. (d) Postoperative computed tomography revealed complete removal of hematoma

Table 1: Incidence and prognosis of stroke as a complication in bacterial meningitis

	Stroke	Ischemic	Pure-hemorrhagic	ICH	SAH	Combination	Others	Mortality (%)
Gironell <i>et al.</i> <sup>[5]</sup>	NR	NR	3/92	2	1	NR		66.6
Bodilsen <i>et al.</i> <sup>[7]</sup>	22/111	15	3/111	2	1	4		NR
Klein <i>et al.</i> <sup>[8]</sup>	16/94	13	0/94	0	0	3		NR
Durand <i>et al.</i> <sup>[9]</sup>	4/87	4	0/87	0	0	0		NR
Mook-Kanamori <i>et al.</i> <sup>[10]</sup>	NR	NR	15/860	10	5	4	5	63.0

NR – Not reported; ICH – Intracranial hemorrhage; SAH – Subarachnoid hemorrhage

The pathogenetic mechanisms involved in the development of cerebral hemorrhage likely include a destructive process against the blood vessels, and inflammatory response generated in the subarachnoid space. This process may eventually lead to the formation of microaneurysms with fatal rupture resulting in a cerebral hematoma or subarachnoid hemorrhage.<sup>[5]</sup> In addition, other mechanisms that are mainly suggested in ischemic stroke such as focal hyperperfusion, vasospasms, septic embolization, thrombosis, and diffuse cerebral intravascular coagulation may also contribute to this condition.<sup>[5,11-13]</sup>

Since subcortical hematoma is extremely rare for young people who do not have a medical history, initially, we searched for other underlying diseases. At first, we thought of hypertensive cerebral hemorrhage, but there was no history of hypertension, and he had kept his blood pressure within the normal range even in the acute phase of hemorrhage. Second, we performed DSA before the operation because of the strong suspiciousness for vascular abnormality such as cerebral arteriovenous malformation. However, no obvious findings were observed in the four-vessel study. Based on the laboratory findings, inflammation was mild, and coagulation disorder was not observed. Thus, the possibility of cerebral hemorrhage due to sepsis was also unlikely.

In bacterial meningitis, identification rate of bacteria decreases when antibiotics are used before lumbar puncture.<sup>[14]</sup> Because we used antibiotics at the time of treatment for sinusitis and after craniotomy, causative bacteria were not identified. In addition, the decline of glucose in the CSF was not particularly pronounced, and neck stiffness and meningeal irritation symptom were not observed. Normally, stroke as a complication is often observed in severe bacterial meningitis. However, as with this case, relatively mild meningitis rarely causes severe hemorrhagic complications. Thus, we should pay attention to the clinical course of such mild or moderate cases, too.<sup>[5]</sup>

In this case, based on symptoms before the onset of illness and post-surgical examination of cerebrospinal fluid, we have concluded that the cerebral hemorrhage was caused by meningitis. However, there is no clear evidence of a connection between the sinusitis and the meningitis, and an examination of CSF should have been performed before the cerebral hemorrhage occurred.

## Conclusion

Hemorrhagic stroke is a rare complication in bacterial meningitis. However, if this condition develops, there is a high risk of mortality and morbidity. In this case, we could obtain a good outcome with appropriate antibiotic therapy.

## Declaration of patient consent

The authors certify that they have obtained all appropriate patient consent forms. In the form the patient(s) has/have given his/her/their consent for his/her/their images and other clinical information to be reported in the journal. The patients understand that their names and initials will not be published and due efforts will be made to conceal their identity, but anonymity cannot be guaranteed.

## Financial support and sponsorship

Nil.

## Conflicts of interest

There are no conflicts of interest.

## References

- Swartz MN. Bacterial meningitis: More involved than just the meninges. *N Engl J Med* 1984;311:912-4.
- Schut ES, Lucas MJ, Brouwer MC, Vergouwen MD, van der Ende A, van de Beek D, *et al.* Cerebral infarction in adults with bacterial meningitis. *Neurocrit Care* 2012;16:421-7.
- Vergouwen MD, Schut ES, Troost D, van de Beek D. Diffuse cerebral intravascular coagulation and cerebral infarction in pneumococcal meningitis. *Neurocrit Care* 2010;13:217-27.
- Katchanov J, Heuschmann PU, Endres M, Weber JR. Cerebral infarction in bacterial meningitis: Predictive factors and outcome. *J Neurol* 2010;257:716-20.
- Gironell A, Domingo P, Mancebo J, Coll P, Martí-Vilalta JL. Hemorrhagic stroke as a complication of bacterial meningitis in adults: Report of three cases and review. *Clin Infect Dis* 1995;21:1488-91.
- de Souza AL, Sztajnbock J, Seguro AC. Cerebellar hemorrhage as an atypical complication of meningococcal meningitis. *Int J Infect Dis* 2008;12:558-9.
- Bodilsen J, Dalager-Pedersen M, Schönheyder HC, Nielsen H. Stroke in community-acquired bacterial meningitis: A Danish population-based study. *Int J Infect Dis* 2014;20:18-22.
- Klein M, Koedel U, Pfefferkorn T, Zeller G, Woehrl B, Pfister HW, *et al.* Arterial cerebrovascular complications in 94 adults with acute bacterial meningitis. *Crit Care* 2011;15:R281.
- Durand ML, Calderwood SB, Weber DJ, Miller SI, Southwick FS, Caviness VS Jr., *et al.* Acute bacterial meningitis in adults. A review of 493 episodes. *N Engl J Med* 1993;328:21-8.
- Mook-Kanamori BB, Fritz D, Brouwer MC, van der Ende A, van de Beek D. Intracerebral hemorrhages in adults with community associated bacterial meningitis in adults: Should we reconsider anticoagulant therapy? *PLoS One* 2012;7:e45271.
- Boehme AK, Ranawat P, Luna J, Kamel H, Elkind MS. Risk of acute stroke after hospitalization for sepsis: A case-crossover study. *Stroke* 2017;48:574-80.
- Brouwer MC, Heckenberg SG, de Gans J, Spanjaard L, Reitsma JB, van de Beek D, *et al.* Nationwide implementation of adjunctive dexamethasone therapy for pneumococcal meningitis. *Neurology* 2010;75:1533-9.
- Chow FC, Marra CM, Cho TA. Cerebrovascular disease in central nervous system infections. *Semin Neurol* 2011;31:286-306.
- Sáez-Llorens X, McCracken GH Jr. Bacterial meningitis in children. *Lancet* 2003;361:2139-48.