

# Squamous cell carcinoma arising from a thyroglossal duct cyst: A case report and review of the literature

SAGE Open Medical Case Reports  
Volume 6: 1–8  
© The Author(s) 2018  
Reprints and permissions:  
sagepub.co.uk/journalsPermissions.nav  
DOI: 10.1177/2050313X18767050  
journals.sagepub.com/home/sco



Qi Huang<sup>1</sup> , Yi Shen<sup>2,3,4</sup>, Allen Y Wang<sup>2,3,5</sup>, Shijie Qiu<sup>4</sup>, Qun Li<sup>4</sup>, Jian Wang<sup>4</sup> and Zhenhua Wu<sup>1</sup>

## Abstract

**Objectives:** Squamous cell carcinoma in a thyroglossal duct cyst is exceedingly rare with only 26 reported cases in the literature so far, which only account for 6% of the patients.

**Methods:** We report a unique case of squamous cell carcinoma arising from a thyroglossal duct cyst in a 49-year-old male who was primarily diagnosed as a thyroglossal duct cyst with inflammation. The patient underwent Sistrunk procedure with wide local excision and radiation therapy as well as chemotherapy post-operatively and had no evidence of recurrence or metastasis for 24 months. In addition, we reviewed the relevant literatures.

**Results:** Whether squamous cell carcinoma actually arises from thyroglossal duct cyst is still controversial; however, carcinoma originating from metaplasia of columnar and squamous epithelium in thyroglossal duct cyst has been well accepted. The gold-standard diagnostic method is fine needle aspiration biopsy with ultrasound guidance. Sistrunk procedure alone or with wide excision is likely to be beneficial. Neck dissection is necessary in patients with positive cervical lymphadenopathy. Radiation therapy and chemotherapy have not yet been clearly defined.

**Conclusion:** Squamous cell carcinoma arising from thyroglossal duct cyst is really a rare disease, whose origin, treatments and prognosis still remain uncertain. These are solely based on case reports, case series and expert opinions. Hence, more investigations about squamous cell carcinoma will be conducted in the near future.

## Keywords

Thyroglossal duct cyst, squamous cell carcinoma, Sistrunk procedure, radiation therapy, prognosis

Date received: 4 October 2017; accepted: 5 March 2018

## Introduction

Malignancy of the thyroglossal duct cyst (TGDC) is rarely seen, occurring only in approximately 1% of cases. To date, approximately 250 cases have been reported, among which a majority of these cases were diagnosed either as papillary carcinomas (PC) or follicular carcinomas (FC), while only around 5% were squamous cell carcinomas (SCC).<sup>1</sup> As far as we know, there have been 26 cases of SCC reported so far, including 21 cases of SCC, three cases of SCC with PC, and two cases of adenosquamous carcinoma (ASC) (Table 1).<sup>2–7</sup> Here, we report a case in which the patient had SCC arising from the TGDC, and a review of the literature to shed light on the current SCC diagnosis and treatment.

<sup>1</sup>Department of Otolaryngology, Head and Neck Surgery, Ningbo Medical Centre Lihuili Eastern Hospital, Ningbo, China

<sup>2</sup>Ear Sciences Centre, School of Surgery, The University of Western Australia, Perth, WA, Australia

<sup>3</sup>Ear Science Institute Australia, Perth, WA, Australia

<sup>4</sup>Department of Otolaryngology, Head and Neck Surgery, Ningbo Medical Centre Lihuili Hospital, Ningbo University, Ningbo, Zhejiang, China.

<sup>5</sup>Department of Otolaryngology, Head and Neck, Skull Base Surgery, Sir Charles Gairdner Hospital, Perth, WA, Australia

### Corresponding Author:

Zhenhua Wu, Department of Otolaryngology, Head and Neck Surgery, Ningbo Medical Centre Lihuili Eastern Hospital, No.1111, Jiangnan Road, Ningbo 315050, Zhejiang, China.  
Email: 290141049@qq.com



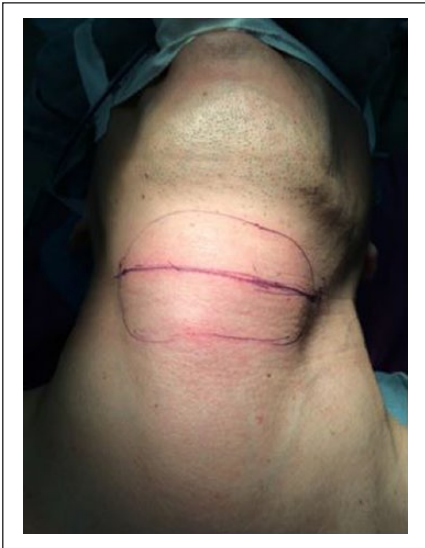**Table 1.** Summary of detailed literature on patients with squamous cell carcinoma of thyroglossal duct cyst.

Author	Age (years)	Gender	Histology	Surgery	Radiotherapy	Outcome
Smith and Clute <sup>8</sup>	56	M	SCC	Excised	Yes, post-op	Deceased 15 months after diagnosis
Dalgaard and Wetteland <sup>9</sup>	44	F	SCC of recurrence	Excised, recurrence 13 years later	Unknown	No evidence of disease 15 years after second surgery
Ruppman and Georgsson <sup>10</sup>	51	F	SCC of last resection	Recurrent drainage 5 resections were carried out	Unknown	No evidence of disease 1 year after last resection
Shepard and Rosenfeld <sup>11</sup>	28	F	SCC	Excised	Yes, post-op	Recurred locally, died 4 years after diagnosis
Mobini et al. <sup>12</sup>	50	F	SCC	Mass, right lobe and isthmus excised	Yes, post-op	No evidence of disease 2 years after treatment
Saharia <sup>13</sup>	81	F	SCC	Cyst, left side of hyoid, strap muscles excised and neck exploration (-)	No	No evidence of disease 3 years after treatment
Benveniste et al. <sup>14</sup>	75	M	SCC	Mass and overlying skin excised	Yes, post-op	Alive 7 months after presentation
White and Talbert <sup>15</sup>	61	M	SCC	Excised	No	No evidence of disease
Ronan et al. <sup>3</sup>	19	F	Mixed PC and SCC	Thyroidectomy and excision of mass	No	Unknown
Bosch et al. <sup>16</sup>	54	M	SCC	Only partial excision	Yes, post-op	Local recurrence after 6 months.
Lustmann et al. <sup>17</sup>	80	F	SCC, two lymph nodes positive	Radical neck dissection and removal of thyroglossal sinus tract and excision of mid-hyoid bone	Yes, post-op	Deceased 7 months after surgery
Yanagisawa et al. <sup>18</sup>	65	M	SCC	Sistrunk procedure	Yes, post-op	Recurred 5 months later. Deceased 2 weeks after readministration of radiotherapy
Kwan et al. <sup>5</sup>	38	M	Mixed PC and SCC	Sistrunk procedure and a near-total thyroidectomy	Yes, post-op	No evidence of disease 18 months after treatment
Hama et al. <sup>19</sup>	57	M	SCC	Sistrunk procedure and bilateral neck dissection	Yes, ablative radioactive iodine and adjuvant external radiation therapy	No evidence of disease 3 years after treatment
El Bakkouri et al. <sup>20</sup>	55	F	SCC	Surgery is incomplete	Yes, pre-op	No evidence of disease 7 years after surgery
Gomi et al. <sup>4</sup>	11	F	Mixed PC and SCC, PC metastasis to the medial submandibular lymph node	Sistrunk procedure and cervical lymph node dissection	Yes, post-op radiotherapy, thyroid hormone suppression therapy	Local progression was controlled by chemotherapy 2 years after treatment
Iakovou et al. <sup>21</sup>	78	M	SCC	Wide Sistrunk procedure	Unknown	No evidence of disease 10 months after treatment

**Table 1.** (Continued)

Author	Age (years)	Gender	Histology	Surgery	Radiotherapy	Outcome
Kinoshita et al. <sup>6</sup>	61	F	ASC	Sistrunk procedure	No	No evidence of disease 8 months after surgery
Chang et al. <sup>7</sup>	77	M	ASC	Sistrunk procedure and total thyroidectomy	No	No evidence of disease after surgery (time was demonstrated)
Shah et al. <sup>2</sup>	47	M	SCC	Sistrunk procedure	Yes, post-op	No evidence of disease 3 months after surgery
Ferrer et al. <sup>22</sup>	49	M	SCC	Surgery (details were unknown)	Yes, post-op	No evidence of disease 52 months after treatment
Ranieri et al. <sup>23</sup>	68	M	SCC	Sistrunk procedure and left neck dissection	Yes, post-op	No evidence of disease 22 months after treatment
Colloby et al. <sup>24</sup>	67	M	SCC	Surgery (details were unknown)	No	No evidence of disease 6 months after surgery
Virno et al. <sup>25</sup>	68	M	SCC	Surgery (details were unknown)	Yes, post-op	No evidence of disease 12 months after treatment
Boswell et al. <sup>26</sup>	65	F	SCC	Sistrunk procedure	No	No evidence of disease 11 years after surgery
Bardales et al. <sup>27</sup>	50	M	SCC	Surgery (details were unknown)	Yes, post-op	No evidence of disease 36 months after treatment

M: male; F: female; SCC: squamous cell carcinomas; PC: papillary carcinomas; ASC: adenosquamous carcinoma; post-op: post-operation.



**Figure 1.** A tender, hard, midline anterior neck mass (circle) at the level of the hyoid bone.

## Case report

A 49-year-old male with a background of infantile paralysis presented with a midline anterior neck mass with associated pain, inarticulacy and swallowing discomfort. Despite a 2-week course of oral antibiotics, there was no significant improvement in the clinical symptoms. The patient was originally diagnosed with TGDC 4 years prior, but he declined for surgery at that stage. On examination, he had a tender, hard midline anterior neck mass (6.0×4.0×4.0 cm) at the level of hyoid bone that elevated on swallowing (Figure 1). On nasal endoscopy, no abnormality was found in his nasal, oral, pharyngeal or laryngeal areas. Ultrasonography demonstrated a solid-cystic multilocular mass (5.8×3.6 cm) with irregular shape and well blood supply connecting with hyoid bone. Magnetic resonance imaging (MRI) without contrast was guided for inspection due to iodine allergy. MRI showed a 5.6×3.2×3.6 cm lesion with mixed signals and unclear margins. The lesion appeared to arise from notch thyroid and extend to midline tongue base (Figure 2). There was no evidence of abnormal thyroid gland and cervical lymphadenopathy. Based on these findings, a TGDC with inflammation was suspected, and Sistrunk procedure was consented. However, intra-operatively, the mass was found to adhere densely with surrounding tissues. Thus, Sistrunk procedure with additional wide local excision was performed. In view of the large open wound cavity in proximity to the floor of mouth and potential laryngemphaxis post-operatively, tracheotomy was performed following surgery, with nasogastric tube inserted. The tracheotomy and nasogastric tubes were removed 1 week after surgery without any complications. The mass specimen was sent for histopathological review. Grossly, the mass (6.0×4.0×4.0 cm) composed of chief solid lesion with partial cystic lesion adhering to hyoid bone and surrounding muscles (Figure 3). Microscopically, the mass presented

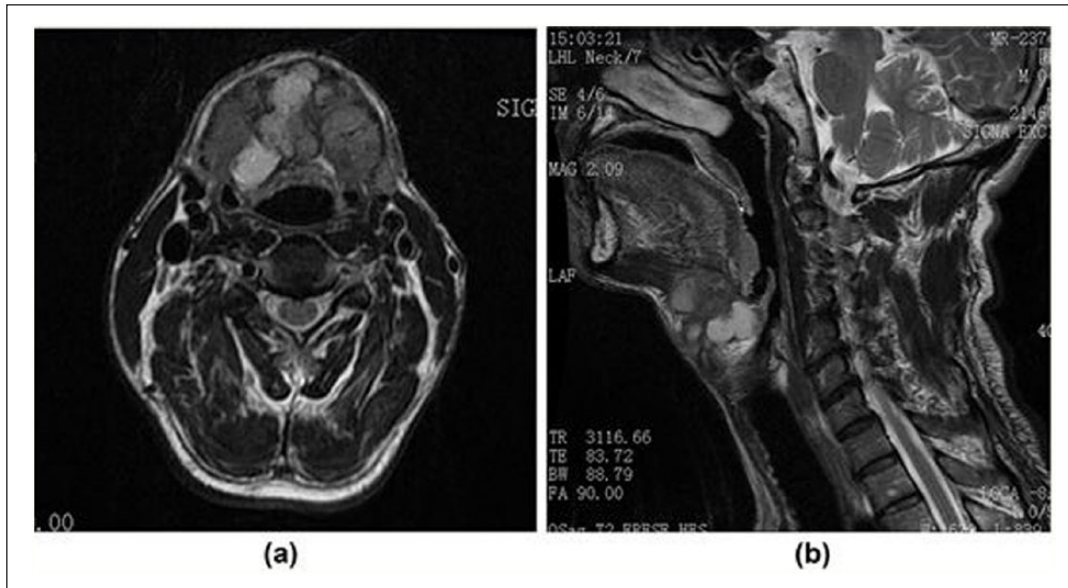
numerous differentiated malignant squamous cells (Figure 4). Whole body positron emission tomography (PET) scanning did not reveal any regional or distant metastatic diseases (Figure 5). Based on these findings, this mass was diagnosed as SCC arising from a TGDC. The patient made an unremarkable post-operative recovery and underwent further chemotherapy (docetaxel, 75 mg/m<sup>2</sup> (Day 1) and cis-platinum, 70 mg/m<sup>2</sup> (average Days 1–3), every 3 weeks, total twice) and radiotherapy with 60 Gy of intensity dividing into 30 fractions. Following radiotherapy, the patient had no evidence of recurrence or metastasis for 24 months.

## Discussion

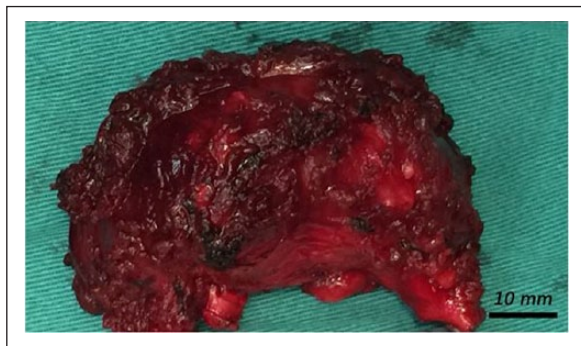
During the third week of fetal life, thyroid gland arises embryologically from a midline endodermal invagination of the foregut at the level of the foramen cecum. Its tract of descent from the base of the tongue to the final resting place in the anterior neck involutes in the ninth week of gestation. However, when the tract fails to involute, thyroglossal duct remnant forms and mainly presents as a cyst named TGDC which accounts for over 70% of anterior neck masses in children and 7% in adults.<sup>28,29</sup> However, carcinoma arising within TGDC is exceedingly rare, with a low morbidity of 1% and only approximately 250 cases reported.<sup>1</sup> A majority (over 50%) of these TGDCs contain ectopic functional thyroid tissue.<sup>29,30</sup> Hence, more than 90% of these patients have been described as well-differentiated PC,<sup>1</sup> and only 6% have been indicated as SCC.<sup>31</sup>

More than 50% of TGDCs have normal thyroid cells, thus PC arise de novo from the TGDC rather than metastatic spread from the main gland. The lack of parafollicular cells in ectopic thyroid tissue of these malignancies provides further evidence for this theory.<sup>32,33</sup> However, whether the SCC actually arise from TGDC is still controversial. Thus far, two theories have been put forward. Numerous reports have revealed that SCC combining with PC arises from TGDC.<sup>3–5</sup> Ronan et al.<sup>3</sup> even reported a transition between the two components. Therefore, one theory indicates that SCC is possibly a metaplastic component of PC.<sup>5</sup> In contrast, another theory states that metaplasia of columnar and squamous epithelium in TGDCs plays a key role in carcinogenesis since TGDCs consist of columnar and squamous epithelial cells and previous reports indicated only SCC in TGDCs.<sup>19</sup> It is most likely that tumor originated from metaplasia of columnar and squamous epithelium rather than metaplasia of PC.<sup>6</sup>

Generally, TGDC presents as an asymptomatic midline neck lump in the region of hyoid bone. Symptoms predominantly include dyspnoea, dysphagia or dyspepsia, especially when the mass becomes larger in size although extremely rare. When a patient has a history of hoarseness, weight loss or airway compromise, he or she should be suspected for malignancy. In addition, if the lump is hard, fixed, irregular or associated with lymphadenopathy, there should be a high index of suspicion for malignancy.<sup>28</sup> SCC arising from TGDC is best evaluated by cross-sectional imaging modalities such as



**Figure 2.** (a) MRI T2-weighted sections in axial plane and (b) sagittal plane shows a lesion with mixed signals and no clear margins arising from notch thyroid and extend to midline tongue base.



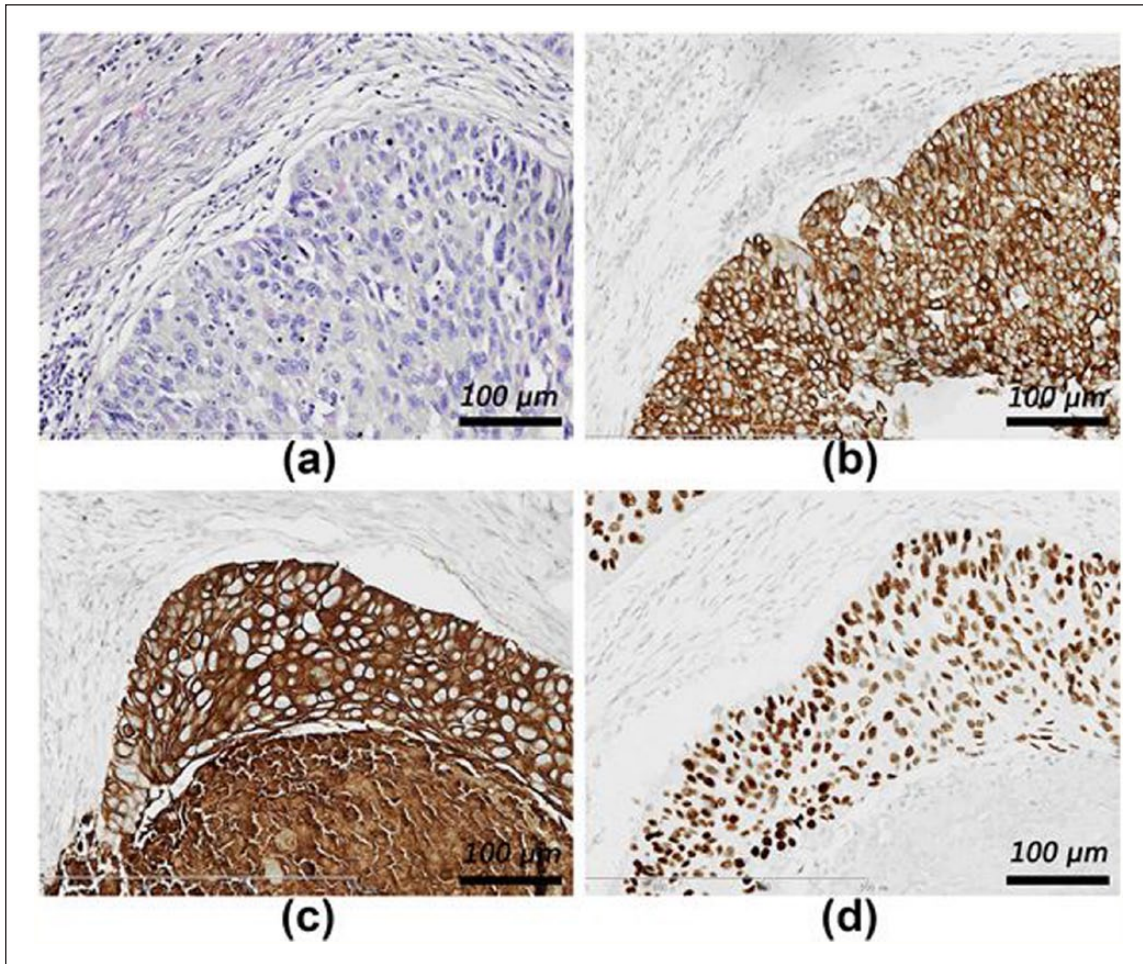
**Figure 3.** The excised mass that was found to adhere to the hyoid bone and surrounding muscles.

computed tomography (CT) and MRI. The gold-standard diagnostic method is fine needle aspiration biopsy (FNAB) with ultrasound guidance. Moreover, intra-operative frozen section is beneficial to minimize the necessity for neck re-exploration and to determine the diagnosis during initial surgery.<sup>28</sup> Although reports in the literature are rare, strict criteria for primary diagnosis of SCC in TGDC have been defined as follow: (1) the carcinoma locates in the wall of TGDC, (2) a transition between epithelium of the cyst and the carcinoma and (3) excluding diseases which could mimic diagnosis such as carcinoma in tongue base and mouth floor.<sup>2,12</sup>

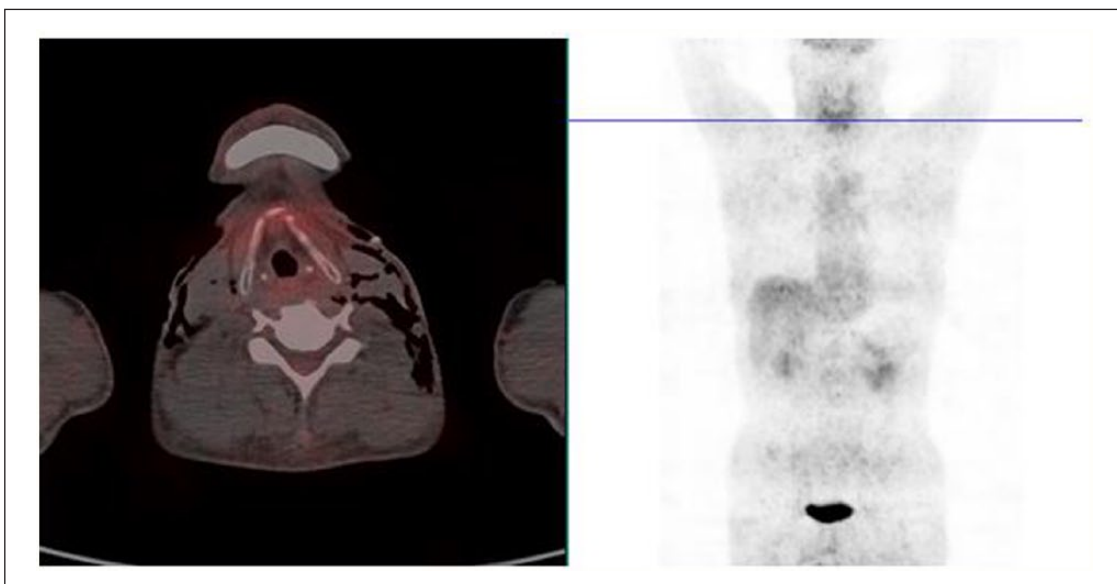
To date, there have been only several cases reported with varied operative procedures. Therefore, evidence-based management protocol is difficult to be established. Management for patients with TGDC SCCs is Grade C, since it is solely based on case reports, case series and expert opinion.<sup>34</sup> Thus, the standard management protocol for SCC from TGDC is still not yet clear. However, Sistrunk

procedure alone or together with wide excision is likely to be beneficial. Patients with clinically positive cervical lymphadenopathy may require neck dissection intra-operative, while the strategy of dealing with thyroid gland is controversial. Since Kwan and colleagues' review, there have been 12 published cases summarized in Table 1 (the present case is the 13th). In brief, eight patients underwent Sistrunk procedure alone, and three patients experienced Sistrunk procedure with wide excision. Two patients underwent partial excision, four patients experienced Sistrunk procedure with cervical lymph node dissection, one patient had Sistrunk procedure with lobe and isthmus excised, one patient had Sistrunk procedure with thyroidectomy and four patients' details of their surgeries were unknown. SCCs involving PC in TGDCs have been reported by three cases (Table 1), and thyroidectomy or near-total thyroidectomy of thyroid gland is carried out in two cases except the 11-year-old child who has no obvious pathology in thyroid gland.

In literatures, it has been indicated that staging systems for the differentiated thyroid cancer of the main gland can be applied to TGDC carcinomas. Moreover, the TNM (tumor, nodes, metastasis) staging system is recommended for uniformity.<sup>28</sup> Furthermore, the adjuvant therapies have been introduced including total or near-total thyroidectomy, radioactive iodine (RAI) and thyroid-stimulating hormone (TSH) suppression.<sup>35</sup> Nevertheless, these treatments may be unsuitable for the treatment of TGDCs with SCC specifically. Post-operative radiotherapy has been indicated for larger lesions, but this treatment has not yet been clearly defined. Several reports have demonstrated recommendations of radiation for patients who have not had an oncologic resection and for those with positive margins.<sup>2</sup> No clear guidelines exist regarding criteria for



**Figure 4.** (a) Histopathological image of the mass specimen demonstrating the fibrous stroma with invasive nests of atypical squamous cells (H&E, ×20). Immunohistochemically, positivity for (b) CKpan, (c) 34bE12 and (d) p40 was observed in the invasive tumor nests confirming squamous cell carcinoma (×20).



**Figure 5.** No regional or distant metastasis was revealed by PET scan.

post-operative chemotherapy when surgery and radiotherapy are both not effective.<sup>20</sup> In the literatures, 15 patients of SCC in TGDC underwent post-operative radiotherapy, while one patient was treated by radiotherapy preoperatively. By contrast, seven patients have no radiotherapy, and another three patients lack the relevant records. Only one patient underwent post-operative chemotherapy attributing to the failure of surgery and post-operative radiotherapy.

The prognosis of TGDC malignancy is based on several factors, including extent of surgery, tumor stage and histology. The more common PC has a good prognosis owing to complete excision, RAI and TSH suppression. In comparison, the prognosis of SCC is harder than PC and remains uncertain due to its small case number. In the literature, the best outcome reported is of a patient without evidence of recurrence over 15 years post surgery. While the worst outcome reported is that of a patient with TGDC SCC recurred 5 months post-operatively, and passed away 2 weeks after radiotherapy. Hence, clinicians should be aware of these issues, and long-term follow-up is paramount for patients with TGDC SCC.<sup>19</sup>

## Conclusion

SCC arising from TGDC is really a rare disease, whose origin, treatments and prognosis still remain uncertain. These are solely based on case reports, case series and expert opinions. Hence, further researches are required to better delineate management guidelines for this rare and controversial malignancy.

## Acknowledgements

Q.H. and Y.S. contributed equally to this work.

## Declaration of conflicting interests

The author(s) declared no potential conflicts of interest with respect to the research, authorship and/or publication of this article.

## Funding

The author(s) received no financial support for the research, authorship and/or publication of this article.

## Ethical approval

Ethical approval to report this case was obtained from the institutional review board and ethics committee of Ningbo Medical Center Lihuili Eastern Hospital (approval number: 2017-33)\*.

## Informed consent

Written informed consent was obtained from the patient(s) for their anonymized information to be published in this article.

## ORCID iD

Qi Huang  <https://orcid.org/0000-0002-2511-822X>

## References

- Chrisoulidou A, Iliadou P, Doumala E, et al. Thyroglossal duct cyst carcinomas: is there a need for thyroidectomy? *Hormones* 2013; 12(4): 522–528.
- Shah S, Kadakia S, Khorsandi A, et al. Squamous cell carcinoma in a thyroglossal duct cyst: A case report with review of the literature. *Am J Otolaryngol* 2015; 36(3): 460–462.
- Ronan SG, Deutsch E and Ghosh L. Thyroglossal duct carcinomas: light and electron microscopic studies. *Head Neck Surg* 1986; 8(3): 222–225.
- Gomi K, Kitagawa N, Usui Y, et al. Papillary carcinoma with extensive squamous metaplasia arising from thyroglossal duct cyst in an 11-year-old girl: significance of differentiation from squamous cell carcinoma: a case report. *J Pediatr Surg* 2011; 46(4): e1–4.
- Kwan WB, Liu FF, Banerjee D, et al. Concurrent papillary and squamous carcinoma in a thyroglossal duct cyst: a case report. *Can J Surg* 1996; 39(4): 328–332.
- Kinoshita N, Abe K, Sainoo Y, et al. Adenosquamous carcinoma arising in a thyroglossal duct cyst: report of a case. *Surg Today* 2011; 41(4): 533–536.
- Chang YS, Su HH and Ho SP. Adenosquamous carcinoma arising from a thyroglossal duct cyst: a case report. *Oncol Lett* 2016; 11(4): 2668–2672.
- Smith LW and Clute HM. Cancer of the thyroid gland. *Arch Surg* 1929; 18: 1–20.
- Dalgaard JB and Wetteland P. Aberrant thyroid tissue. II. thyroglossal anomalies; a follow-up study of 58 cases. *Acta Chir Scand* 1956; 111(6): 444–455.
- Ruppman E and Georgsson G. Squamous carcinoma of the thyroglossal duct. *Ger Med Mon* 1966; 11(11): 442–447.
- Shepard GH and Rosenfeld L. Carcinoma of thyroglossal duct remnants: review of the literature and addition of two cases. *Am J Surg* 1968; 116(1): 125–129.
- Mobini J, Krouse TB and Klinghoffer JF. Squamous cell carcinoma arising in a thyroglossal duct cyst. *Am Surg* 1974; 40(5): 290–294.
- Saharia PC. Carcinoma arising in thyroglossal duct remnant: case reports and review of the literature. *Br J Surg* 1975; 62(9): 689–691.
- Benveniste GL, Hunter R and Cook MG. Squamous carcinoma of thyroglossal duct remnants: a case report and review of the literature. *Aust N Z J Surg* 1980; 50(1): 53–55.
- White IL and Talbert WM. Squamous cell carcinoma arising in thyroglossal duct remnant cyst epithelium. *Otolaryngol Head Neck Surg* 1982; 90(1): 25–31.
- Bosch JL, Kummer EW and Hohmann FR. Carcinoma of the thyroglossal duct. *Neth J Surg* 1986; 38(2): 36–40.
- Lustmann J, Benoliel R and Zeltser R. Squamous cell carcinoma arising in a thyroglossal duct cyst in the tongue. *J Oral Maxillofac Surg* 1989; 47(1): 81–85.
- Yanagisawa K, Eisen RN and Sasaki CT. Squamous cell carcinoma arising in a thyroglossal duct cyst. *Arch Otolaryngol Head Neck Surg* 1992; 118(5): 538–541.
- Hama Y, Sugeno A, Kobayashi S, et al. Squamous cell carcinoma arising from thyroglossal duct remnants: report of a case and results of immunohistochemical studies. *Surg Today* 1997; 27(11): 1077–1081.
- El Bakkouri W, Racy E, Verecke A, et al. Squamous cell carcinoma in a thyroglossal duct cyst. *Ann Otolaryngol Chir Cervicofac* 2004; 121(5): 303–305.

21. Iakovou I, Konstantinidis I, Doumas A, et al. Squamous cell carcinoma in a thyroglossal duct cyst and <sup>99m</sup>Tc-MIBI findings. *Hell J Nucl Med* 2011; 14(1): 62–64.
22. Ferrer C, Ferrández A, Dualde D, et al. Squamous cell carcinoma of the thyroglossal duct cyst: report of a new case and literature review. *J Otolaryngol* 2000; 29(5): 311–314.
23. Ranieri E, D'Andrea MR and Vecchione A. Fine needle aspiration cytology of squamous cell carcinoma arising in a thyroglossal duct cyst. A case report. *Acta Cytol* 1996; 40: 747–750.
24. Colloby PS, Sinha M, Holl-Allen RT, et al. Squamous cell carcinoma in a thyroglossal cyst remnant: a case report and review of the literature. *World J Surg* 1989; 13(1): 137–139.
25. Virno VA, Mazzoconi G, Caprio G, et al. Squamous-cell carcinoma of the thyroglossal duct. A clinical case. *G Chir* 1993; 14(7): 351–353.
26. Boswell WC, Zoller M, Williams JS, et al. Thyroglossal duct carcinoma. *Am Surg* 1994; 60(9): 650–655.
27. Bardales RH, Suhrland MJ, Korourian S, et al. Cytologic findings in thyroglossal duct carcinoma. *Am J Clin Pathol* 1996; 106(5): 615–619.
28. Carter Y, Yeutter N and Mazeh H. Thyroglossal duct remnant carcinoma: beyond the Sistrunk procedure. *Surg Oncol* 2014; 23(3): 161–166.
29. Plaza CP, Lopez ME, Carrasco CE, et al. Management of well-differentiated thyroglossal remnant thyroid carcinoma: time to close the debate? Report of five new cases and proposal of a definitive algorithm for treatment. *Ann Surg Oncol* 2006; 13(5): 745–752.
30. LiVolsi VA, Perzin KH and Savetsky L. Carcinoma arising in median ectopic thyroid (including thyroglossal duct tissue). *Cancer* 1974; 34(4): 1303–1315.
31. Motamed M and McGlashan JA. Thyroglossal duct carcinoma. *Curr Opin Otolaryngol Head Neck Surg* 2004; 12(2): 106–109.
32. Mazzaferri EL. Thyroid cancer in thyroglossal duct remnants: a diagnostic and therapeutic dilemma. *Thyroid* 2004; 14(5): 335–336.
33. Luna-Ortiz K, Hurtado-Lopez LM, Valderrama-Landaeta JL, et al. Thyroglossal duct cyst with papillary carcinoma: what must be done? *Thyroid* 2004; 14(5): 363–366.
34. Guirguis-Blake J, Calonge N, Miller T, et al. Current processes of the U.S. preventive services task force: refining evidence-based recommendation development. *Ann Intern Med* 2007; 147(2): 117–122.
35. Cooper DS, Doherty GM, Haugen BR, et al. Revised American Thyroid Association management guidelines for patients with thyroid nodules and differentiated thyroid cancer. *Thyroid* 2009; 19(1): 1167–1214.