

**Keywords:** mammalian target of rapamycin inhibitor; ridaforolimus; endometrial cancer; clinical benefit response; stable disease

# Ridaforolimus as a single agent in advanced endometrial cancer: results of a single-arm, phase 2 trial

N Colombo<sup>\*1</sup>, D S McMeekin<sup>2</sup>, P E Schwartz<sup>3</sup>, C Sessa<sup>4</sup>, P A Gehrig<sup>5</sup>, R Holloway<sup>6</sup>, P Braly<sup>7</sup>, D Matei<sup>8</sup>, A Morosky<sup>9</sup>, P F Dodion<sup>10</sup>, M H Einstein<sup>11</sup> and F Haluska<sup>10</sup>

<sup>1</sup>Division of Gynecology, University of Milan-Bicocca and Istituto Europeo di Oncologia, Via Ripamonti 435, 20141 Milano, Italy;

<sup>2</sup>University of Oklahoma Health Sciences Center, 800 NE 10th Street, Oklahoma City, OK 73104, USA; <sup>3</sup>Yale New Haven Hospital,

20 York Street, New Haven, CT 06510, USA; <sup>4</sup>Istituto Oncologico della Svizzera Italiana, 6500 Bellinzona, Switzerland; <sup>5</sup>University of

North Carolina, 101 Manning Drive, Chapel Hill, NC 27514, USA; <sup>6</sup>Florida Hospital Cancer Institute, 2501 North Orange Avenue,

Orlando, FL 32804, USA; <sup>7</sup>Women's Cancer Care, 606 West 12th Avenue, Covington, LA 70433, USA; <sup>8</sup>Indiana University, 107 South

Indiana Avenue, Indianapolis, IN 47405, USA; <sup>9</sup>Merck Sharp & Dohme Corp., 1 Merck Drive, Whitehouse Station, NJ 08889, USA;

<sup>10</sup>ARIAD Pharmaceuticals, Inc., 26 Landsdowne Street, Cambridge, MA 02139, USA and <sup>11</sup>Montefiore Medical Center and Albert

Einstein College of Medicine, 111 East 210th Street, Bronx, NY 10467, USA

**Background:** This open-label, multicentre, phase 2 trial evaluated the efficacy and tolerability of the mammalian target of rapamycin inhibitor ridaforolimus in women with advanced endometrial cancer.

**Methods:** Women with measurable recurrent or persistent endometrial cancer and documented disease progression were treated with ridaforolimus 12.5 mg intravenously once daily for 5 consecutive days every 2 weeks in a 4-week cycle. The primary end point was clinical benefit response, defined as an objective response or prolonged stable disease of 16 weeks or more.

**Results:** In all, 45 patients were treated with single-agent ridaforolimus. Clinical benefit was achieved by 13 patients (29%), including 5 (11%) with confirmed partial responses and 8 (18%) with prolonged stable disease. All patients with clinical benefit response received ridaforolimus for more than 4 months. In this heavily pretreated population, the 6-month progression-free survival was 18%. Ridaforolimus was generally well tolerated: adverse events were predictable and manageable, consistent with prior studies in other malignancies. Overall, the most common adverse events were diarrhoea (58%) and mouth sores (56%); most common grade 3 or higher adverse events were anaemia (27%) and hyperglycaemia (11%).

**Conclusion:** Single-agent ridaforolimus has antitumor activity and acceptable tolerability in advanced endometrial cancer patients. Further clinical evaluation of ridaforolimus is warranted.

More than 46 000 new cases of endometrial cancer were diagnosed in the United States in 2011, with nearly 8100 deaths (Siegel *et al*, 2011). Deaths due to endometrial cancer have been on the rise, with the rate doubling over the past 20 years (Sorosky, 2008). Most deaths are due to metastatic or recurrent disease, where survival is poor even with current standard chemotherapy (Pectasides *et al*, 2007). Response rates with first-line chemotherapy in women with

advanced or recurrent endometrial cancer are low, ranging from 20 to 30% for single agents and up to 40 to 60% for combination regimens (Fleming, 2007; Pectasides *et al*, 2007; Dellinger and Monk, 2009). For women with advanced disease, efficacy after first-line taxane-based regimens is extremely poor (Dellinger and Monk, 2009; Dizon, 2010). Improved treatment options are needed with an increased emphasis on improving the therapeutic index.

\*Correspondence: Dr N Colombo; E-mail: nicoletta.colombo@ieo.it

Received 8 October 2012; revised 17 January 2013; accepted 19 January 2013; published online 12 February 2013

© 2013 Cancer Research UK. All rights reserved 0007–0920/13

The mammalian target of rapamycin (mTOR) is a downstream effector of the phosphoinositide 3-kinase (PI3K)/AKT pathway and thereby serves as a key regulator of cell growth and division (Dancey, 2010; Shorning *et al*, 2011). Many tumours, including endometrial cancer, have dysregulated PI3K/AKT function (Dedes *et al*, 2011). Loss of function of the tumour suppressor phosphatase and tensin homologue (PTEN) and gain-of-function mutations of the *PIK3CA* gene, both of which increase activity of the PI3K/AKT pathway, have been reported in endometrial cancer patients (Salvesen *et al*, 2004; Hayes *et al*, 2006; Janku *et al*, 2011). Moreover, activation of the PI3K pathway in uterine epithelium via biallelic loss of PTEN or selective AKT activation appears to be sufficient for initiating endometrial cancer in preclinical models (Daikoku *et al*, 2008; Memarzadeh *et al*, 2010). On the basis of these observations, mTOR inhibition may provide a rational approach to treatment of endometrial cancer.

Several mTOR inhibitors, including rapamycin and its analogues everolimus, temsirolimus, and ridaforolimus, have been evaluated in cancer patients (Choi *et al*, 2010). Both everolimus and temsirolimus have shown promising results in patients with advanced or recurrent endometrial cancer (Slomovitz *et al*, 2010; Temkin *et al*, 2010; Oza *et al*, 2011a). Ridaforolimus has also been evaluated in multiple clinical trials, with antitumor activity seen in a variety of solid and haematologic malignancies (Mita *et al*, 2008; Rizzieri *et al*, 2008; Chawla *et al*, 2012; Seki *et al*, 2012). Preclinical studies with ridaforolimus demonstrated antiproliferative activity in endometrial tumour cell lines AN3CA and HEC-1B (Squillace *et al*, 2011). In a phase 1 clinical trial, treatment with ridaforolimus resulted in prolonged partial response (PR) in a patient with mixed Müllerian uterine cancer (Mita *et al*, 2008). Here we describe results from a phase 2 trial designed to assess the efficacy and safety of intravenously administered single-agent ridaforolimus in patients with recurrent or persistent endometrial cancer.

## MATERIALS AND METHODS

**Study design.** This was a phase 2, open-label, single-arm, multicentre study with planned enrolment of approximately 44 patients at nine centres in the United States and Europe (<http://clinicaltrials.gov/ct2/show/NCT00122343>; Protocol 019). Intravenous ridaforolimus was administered at a fixed dose of 12.5 mg over 30 min once daily for 5 consecutive days every 2 weeks, with each treatment cycle defined as a 4-week period (i.e., two courses of ridaforolimus). This intravenous dose was identified as the recommended phase 2 dose in a previous phase 1 trial of ridaforolimus in patients with advanced malignancies (Mita *et al*, 2008). Patients were scheduled to receive 2–6 cycles of treatment, but were allowed to continue treatment with ridaforolimus if they maintained at least stable disease (SD) and acceptable tolerability. Consistent with other phase 2 trials in this clinical setting, palliative and supportive care were permitted during the study, but concurrent treatment with other anticancer modalities was prohibited. Other investigational drugs or devices were also prohibited, as were herbal preparations or related over-the-counter preparations containing herbal ingredients known to affect cytochrome P450-3A isoenzymes (e.g., St John's wort). Patients were followed on study for 24 months after their last dose of ridaforolimus.

The study protocol and patient informed consent forms were approved by each local institutional review board or independent ethics committee before patients were enrolled. The study was conducted in accordance with the ethical principles originating in the Declaration of Helsinki, and in compliance with International Conference on Harmonisation, Good Clinical Practices, and regulatory guidelines.

**Patients.** Women aged 18 years or older with histologically confirmed endometrial cancer who had recurrent or persistent disease and documented disease progression (within 3 months before entry) were eligible if they had at least one measurable lesion based on Response Evaluation Criteria in Solid Tumours (RECIST) guidelines (Eisenhauer *et al*, 2009); Eastern Cooperative Oncology Group performance status 0–2; minimum expected life expectancy of 3 months; and adequate renal, hepatic, and bone marrow function. Patients were to be excluded if they had received more than two prior regimens of cytotoxic chemotherapy or targeted therapy – patients could have undergone surgery and/or received prior radiotherapy and still be included in the study. Patients who had received any therapy with rapamycin or a rapamycin analogue were also excluded. Other exclusion criteria were the presence of brain metastases, anticancer treatment within 4 weeks before the first dose of ridaforolimus ( $\geq 6$  weeks for nitrosourea or mitomycin), ongoing toxicity associated with prior anticancer therapy, another primary malignancy within 3 years of the trial (except for non-melanoma skin cancer), uncontrolled cardiovascular disease, or active infection requiring systemic therapy. Pregnant or lactating women were also excluded.

**Trial end points and assessments.** The primary end point was the clinical benefit response (CBR), defined as a complete response or PR or prolonged SD lasting at least 16 weeks as assessed by modified the RECIST 1.0 criteria. Secondary end points of the trial included progression-free survival (PFS), safety, and tolerability. Time to disease progression, overall survival, and duration of response were planned secondary analyses but were not performed in the trial. Target and non-target lesions were assessed at baseline and after every two cycles (8 weeks) of ridaforolimus therapy. Patients received treatment with ridaforolimus until disease progression or other discontinuation criteria were met. Safety was assessed by routine physical and laboratory evaluations. Patients were monitored for adverse events (AEs) and disease progression throughout the study and at follow-up visits up to 24 months after the last dose of ridaforolimus. All study drug-related AEs were followed until resolution or until administration of another anticancer therapy.

**Statistical analyses.** This study used Simon's optimal two-stage design, which was formulated to distinguish a favourable true CBR rate of  $\geq 35\%$  from a null rate of  $\leq 15\%$  with 90% power, at a significance level of 0.05. In total, 19 patients were to be enrolled in the first stage. Further enrolment was to be discontinued if CBRs were observed in three or fewer of the first 19 patients. However, if four or more patients achieved CBRs, 25 additional patients were to be enrolled. The regimen was to be considered effective if a CBR rate of 25% or greater was observed (i.e., 11 or more CBRs among 44 patients).

All patients receiving at least one dose of ridaforolimus comprised the intent-to-treat (ITT) population, and all were assessed for safety. The severity of AEs was graded according to the National Cancer Institute Common Terminology Criteria for Adverse Events (NCI CTCAE, version 3.0). The frequency of AEs categorised by severity grades and changes in laboratory tests were evaluated using descriptive statistics.

## RESULTS

**Patient baseline characteristics and disposition.** A total of 45 patients, with a median age of 66.7 (range: 28–89) years, were enrolled in the trial and received at least one dose of ridaforolimus (Table 1). The majority of patients had endometrioid adenocarcinoma (64%); 22% had serous tumours, and 11% had carcinosarcomas. Most patients had metastatic disease in lymph nodes (56%) or in the lung (51%). The study population was heavily pretreated,

Table 1. Baseline patient demographics and disease characteristics

Baseline characteristic	Ridaforolimus (N = 45)
<b>Age (years)</b>	
Mean (s.d.)	66.1 (10.4)
Median	66.7
Range	28–89
<b>ECOG performance status, n (%)</b>	
0	30 (67)
1	13 (29)
2	2 (4)
<b>Tumour histology, n (%)</b>	
Endometrioid	28 (62)
Papillary serous	10 (22)
Mixed epithelial	1 (2)
Carcinosarcoma or MMMT	5 (11)
<b>Location or organ with metastatic disease, n (%)<sup>a</sup></b>	
Lymph nodes	25 (56)
Lung	23 (51)
Liver	13 (29)
Other	13 (29)
Vagina	6 (13)
Ascites (non-measurable)	6 (13)
Peritoneum	5 (11)
<b>Prior treatment, n (%)</b>	
Chemotherapy regimens	
1	14 (31)
2	26 (58)
3 or more	3 (7)
Missing	2 (4)
Radiotherapy	30 (67)
Surgical therapy	44 (98)
Abbreviations: ECOG = Eastern Cooperative Oncology Group; MMMT = malignant mixed Müllerian tumour; s.d. = standard deviation.	
<sup>a</sup> Percentages may add up to more than 100%, as a patient may have more than one site of disease.	

with 26 patients (56%) having received two prior systemic regimens. In addition, a protocol violation occurred (as patients with two or more prior cytotoxic chemotherapy or targeted therapy regimens were excluded from the study): three patients (7%) received three or more prior systemic regimens. Ridaforolimus was administered for a median duration of 61 days (range: 1–425 days) and at a median cumulative dose of 250 mg (range: 12.5–1750 mg). All patients had discontinued ridaforolimus by the time of the analysis. In all, 33 patients (73%) were taken off this protocol owing to documented progressive disease, four patients (8%) were taken off this protocol owing to AEs (of which one was considered by the investigator to be related study treatment), four patients (8%) made a voluntary decision to stop treatment (i.e., withdrew consent), and the remaining four patients (8%) discontinued at the discretion of the investigator.

**Efficacy.** Of the 45 patients in the ITT population, 13 (29%) achieved CBR, including 5 (11%) with confirmed PR and 8 (18%) with SD lasting 16 weeks or longer (Table 2). Clinical benefit response was achieved in 10 of 29 patients (34%) with endometrioid tumours, in 2 of 10 patients (20%) with papillary

Table 2. Tumour response rates based on RECIST guidelines

Tumour histology	Best response with ridaforolimus, n (N = 45)		
	CR	PR	SD <sup>a</sup>
Endometrioid (n = 28)	0	3	7
Papillary serous (n = 10)	0	1	1
Mixed epithelial (n = 1)	0	1	0
Carcinosarcoma or MMMT (n = 5)	0	0	0
Total, n (%)	0	5 (11)	8 (18)
Abbreviations: CR = complete response; MMMT = malignant mixed Müllerian tumour; PR = partial response; RECIST = Response Evaluation Criteria in Solid Tumours; SD = stable disease.			
<sup>a</sup> SD for a duration of at least 16 weeks.			

serous carcinomas, and in the lone patient with mixed epithelial histology. None of the five patients with carcinosarcomas had a CBR. Overall, the 13 patients who achieved a CBR received ridaforolimus for more than 4 months (Figure 1). The efficacy of ridaforolimus is illustrated by the case of a 59-year-old woman diagnosed with papillary serous endometrial cancer with multiple metastases, who achieved a confirmed PR after four cycles of therapy (Figure 2). A waterfall plot of the best overall response from baseline for each patient is shown in Figure 3. The 6-month PFS was determined to be 18% following treatment with ridaforolimus.

**Safety.** All patients had at least one AE regardless of relationship to study treatment. The most common AEs were mouth sores (stomatitis and mucosal inflammation), anaemia, fatigue, diarrhoea, nausea, and vomiting (Table 3). Treatment-related AEs occurred in 42 patients (93%); the most common were mouth sores (56%), anaemia (42%), fatigue (40%), diarrhoea (31%), nausea (29%), vomiting (27%), asthenia (24%), and anorexia (22%). In total, 23 patients (51%) experienced serious AEs (SAEs), with seven patients (16%) having SAEs attributable, by the investigator, to treatment. These included three patients with anaemia (two with grade 3 and one with grade 2) and individual patients with deep vein thrombosis (grade 3), vomiting (grade 2), dehydration (grade 3), and stomatitis (grade 2). Each of these events was self-limiting except for one case of anaemia that led to clinical sequelae. A total of 15 patients (33%) experienced at least one treatment-related AE that led to a dose modification. One patient (2%) discontinued treatment with ridaforolimus owing to a treatment-related AE (grade 3 worsening of interstitial lung disease) and three additional patients (7%) discontinued treatment owing to AEs not attributed to study drug (grade 2 infection; grade 3 sepsis; and grade 3 mood alteration, respectively).

None of the patients died during treatment with ridaforolimus. In all, 24 patients (53%) died during the follow-up period after ridaforolimus was discontinued, including four patients (17%) who died within 30 days of receiving the last dose of ridaforolimus. All four of these deaths were due to progressive disease.

## DISCUSSION

Patients with endometrial cancers in the second-line setting or beyond have few effective treatment options. This phase 2 clinical trial demonstrates that single-agent ridaforolimus has antitumor activity in women with advanced endometrial cancer, most of whom had received two prior chemotherapy regimens. The study

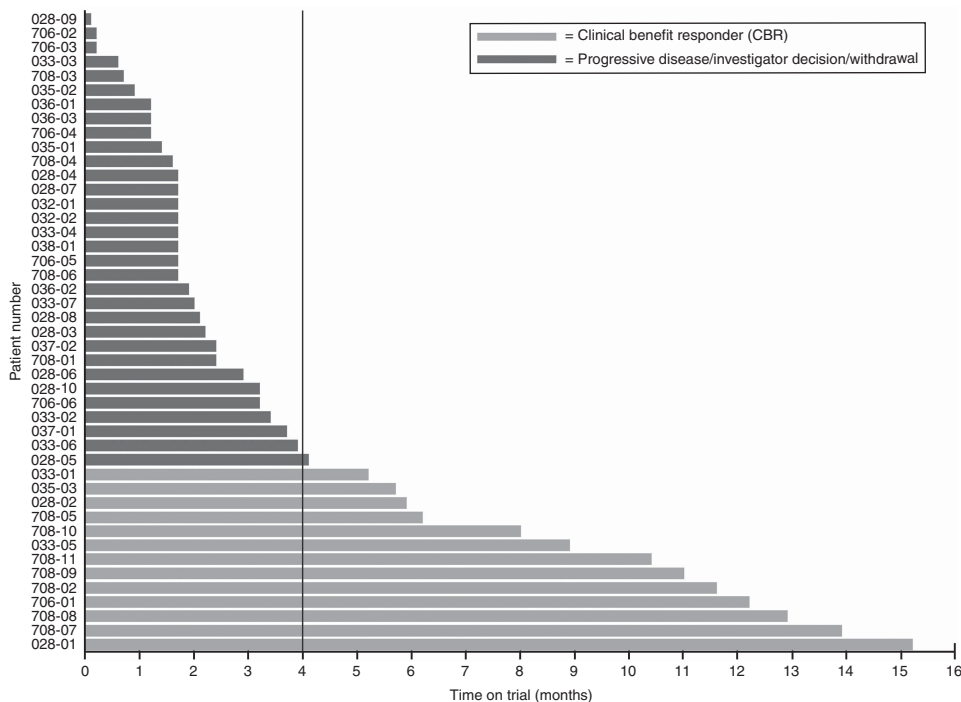


Figure 1. Time on trial with ridaforolimus.

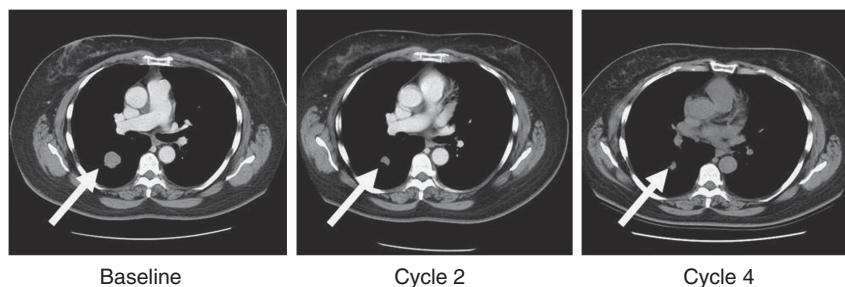


Figure 2. Patient aged 59 years with papillary serous endometrial cancer with multiple metastases treated with ridaforolimus. Baseline scan revealed a 25 × 23 mm mass in the right lung, which decreased to 14 × 13 mm after cycle 2 of therapy, and by cycle 4 was confirmed as a PR by RECIST guidelines.

met its primary end point, as 29% of patients achieved a CBR (11% confirmed PR, 18% SD lasting 16 weeks or longer), thereby exceeding the Simon 2-stage criteria (i.e., CBR rate  $\geq 25\%$ ) established for efficacy. Ridaforolimus also showed an acceptable toxicity profile with the most common AEs (e.g., mouth sores, anaemia, and fatigue) being predictable, manageable, and consistent with those observed in previous trials with ridaforolimus and in studies with other mTOR inhibitors (Dancey and Monzon, 2011; Pilotte *et al*, 2011). One-third of the patients had treatment-related AEs that led to dose delay or reduction. Four patients were taken off protocol owing to AEs, but in only one case the AE was considered by the investigator to be treatment related.

Several other mTOR inhibitors have been investigated in women with advanced endometrial cancer. In a recently published phase 2 study among patients with recurrent endometrial carcinoma treated with a 10-mg oral daily dose of everolimus, 6 of 28 evaluable patients (21%) achieved a CBR; fatigue, anaemia, pain, lymphopenia, and nausea were reported as the most common AEs (Slomovitz *et al*, 2010). In another phase 2 trial, treatment with 25 mg intravenous temsirolimus administered weekly as monotherapy to patients with recurrent or metastatic endometrial cancer produced confirmed PRs in 4 of 29 chemotherapy-naïve evaluable patients (14%) and 1 of 25 evaluable patients (4%) who

had been previously treated with chemotherapy (Oza *et al*, 2011a). The chemotherapy-naïve subset also had higher SD rates with longer median response duration than the chemotherapy-treated subset. Median PFS was 7.3 months in the chemotherapy-naïve group compared with 3.3 months in the chemotherapy-treated group. The most common AEs reported with temsirolimus were pneumonitis, mucositis, fatigue, gastrointestinal disorders, and pain.

The results of this study with ridaforolimus combined with the findings of the earlier phase 2 studies with everolimus and temsirolimus suggest that mTOR inhibitors have single-agent clinical benefit in advanced and recurrent endometrial cancer. Unfortunately, predictive factors have not yet been identified to select patients most likely to benefit from mTOR inhibitor therapy. For example, in a phase 2 trial with temsirolimus, loss of PTEN and other molecular markers of the PI3K/AKT/mTOR pathway did not appear to correlate with clinical outcomes (Oza *et al*, 2011a). Similarly, in a preclinical setting (i.e., fresh endometrial cancer tumour explants), PTEN and AKT status did not predict the antiproliferative effects of rapamycin (Bae-Jump *et al*, 2010). Predictive markers were not evaluated in this study owing to the limited availability of archival and biopsy tumour specimens in the study cohort.

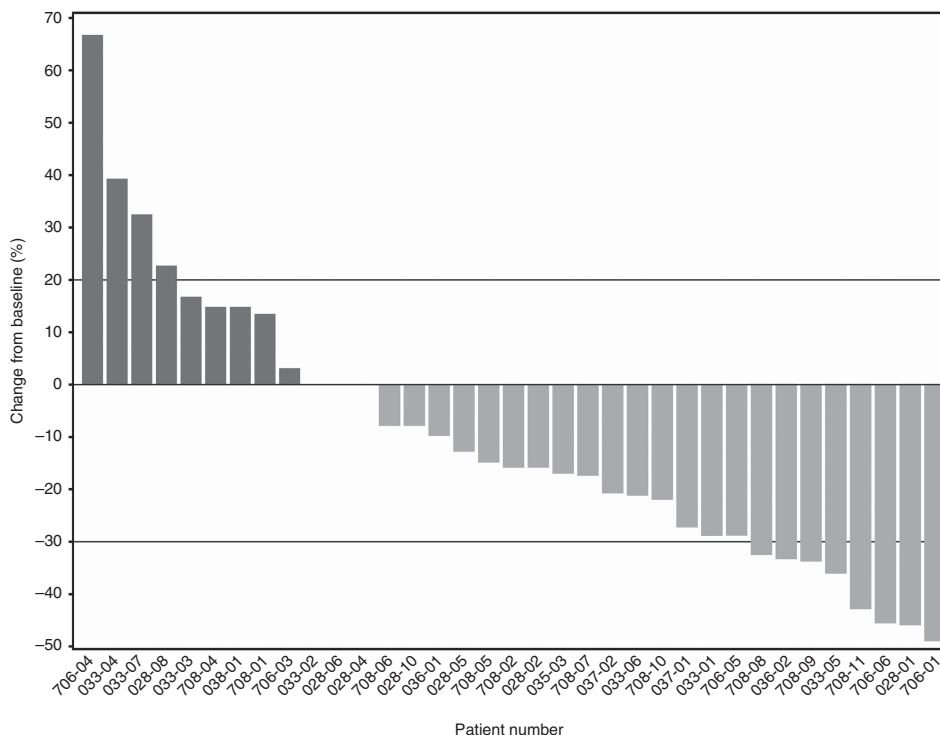


Figure 3. Waterfall plot showing distribution of the best percentage change in target lesion size from baseline for an individual patient (n = 35; not evaluable, n = 10). The lines (-30 and +20%) indicate the region with change from baseline that typically represent SD based on RECIST guidelines.

Table 3. Treatment-related adverse events experienced by eight or more patients, and all grade 3/4 events reported following treatment with ridaforolimus

Adverse event, n (%) <sup>a</sup>	Ridaforolimus (N = 45)	
	All grades	Grade 3/4
Mouth sores <sup>b</sup>	25 (56)	4 (9)
Anaemia	19 (42)	10 (22)
Fatigue	18 (40)	2 (4)
Diarrhoea	14 (31)	0
Nausea	13 (29)	2 (4)
Vomiting	12 (27)	1 (2)
Asthenia	11 (24)	2 (4)
Anorexia	10 (22)	1 (2)
Dysgeusia	8 (18)	0
Anorexia	10 (22)	1 (2)
Hyperglycaemia	5 (11)	4 (9)
Hypertriglyceridaemia	5 (11)	2 (4)
Hypokalaemia	5 (11)	1 (2)

<sup>a</sup>If multiple episodes of an event are experienced by one patient, the patient/event is presented once at the highest grade reported.  
<sup>b</sup>Includes stomatitis and mucosal inflammation.

Shafer *et al*, 2010). The clinical significance of these findings remains to be determined, along with careful evaluation of the tolerability of mTOR inhibitor–chemotherapy combinations. Temsirolimus was evaluated in combination with topotecan in women with advanced gynaecologic tumours, including endometrial cancer, in a phase 1 study; the combination was successful in treating a subset of patients without prior pelvic radiotherapy, but it was not tolerated in patients with prior pelvic radiotherapy (Temkin *et al*, 2010).

The results of this study indicate that ridaforolimus has antitumor activity in women with advanced or recurrent endometrial cancer. Studies with both intravenous (ridaforolimus and temsirolimus) and oral (everolimus) formulations of mTOR inhibitors have demonstrated clinical benefit in this patient population. No differences in treatment outcomes have been formally investigated between intravenous and oral formulations. Therefore, with similar clinical benefits and safety profiles observed across the mTOR studies, administration of an oral formulation would most likely be preferred by patients and their treating physicians. Preliminary results of a phase 2 trial testing the oral formulation of ridaforolimus, administered at 40 mg per day once daily for 5 days followed by a 2-day rest period, suggest that orally administered ridaforolimus is also effective in women with advanced endometrial cancer (Oza *et al*, 2011b). On the basis of these findings, mTOR inhibition with ridaforolimus is a potential therapeutic option in endometrial cancer and warrants further study as a single agent or in combination with other agents. Future studies evaluating predictive biomarkers will also provide critical data to help identify patients who may benefit from treatment with mTOR inhibitors.

ACKNOWLEDGEMENTS

Medical writing and editorial assistance was provided by Joseph J Abrajano, PhD, and Kakuri M Omari, PhD, of Integrus Scientific,

a division of Medicus International New York (New York, NY, USA). This assistance was funded by Merck Sharp & Dohme Corp., a subsidiary of Merck & Co., Inc. (Whitehouse Station, NJ, USA). The authors were fully responsible for all content and editorial decisions and received no financial support or other compensation related to the development of the manuscript.

## REFERENCES

- Bae-Jump VL, Zhou C, Boggess JF, Gehrig PA (2009) Synergistic effect of rapamycin and cisplatin in endometrial cancer cells. *Cancer* **115**: 3887–3896.
- Bae-Jump VL, Zhou C, Boggess JF, Whang YE, Barroilhet L, Gehrig PA (2010) Rapamycin inhibits cell proliferation in type I and type II endometrial carcinomas: a search for biomarkers of sensitivity to treatment. *Gynecol Oncol* **119**: 579–585.
- Chawla SP, Staddon AP, Baker LH, Schuetze SM, Tolcher AW, D'Amato GZ, Blay JY, Mita MM, Sankhala KK, Berk L, Rivera VM, Clackson T, Loewy JW, Haluska FG, Demetri GD (2012) Phase II study of the mammalian target of rapamycin inhibitor ridaforolimus in patients with advanced bone and soft tissue sarcomas. *J Clin Oncol* **30**: 78–84.
- Choi CH, Lee JS, Kim SR, Kim TJ, Lee JW, Kim BG, Bae DS (2010) Clinical significance of pmTOR expression in endometrioid endometrial carcinoma. *Eur J Obstet Gynecol Reprod Biol* **153**: 207–210.
- Daikoku T, Hirota Y, Tranguch S, Joshi AR, DeMayo FJ, Lydon JP, Ellenson LH, Dey SK (2008) Conditional loss of uterine Pten unfaithfully and rapidly induces endometrial cancer in mice. *Cancer Res* **68**: 5619–5627.
- Dancey J (2010) mTOR signaling and drug development in cancer. *Nat Rev Clin Oncol* **7**: 209–219.
- Dancey JE, Monzon J (2011) Ridaforolimus: a promising drug in the treatment of soft-tissue sarcoma and other malignancies. *Fut Oncol* **7**: 827–839.
- Dedes KJ, Wetterskog D, Ashworth A, Kaye SB, Reis-Filho JS (2011) Emerging therapeutic targets in endometrial cancer. *Nat Rev Clin Oncol* **8**: 261–271.
- Dellinger TH, Monk BJ (2009) Systemic therapy for recurrent endometrial cancer: a review of North American trials. *Expert Rev Anticancer Ther* **9**: 905–916.
- Dizon DS (2010) Treatment options for advanced endometrial carcinoma. *Gynecol Oncol* **117**: 373–381.
- Eisenhauer EA, Therasse P, Bogaerts J, Schwartz LH, Sargent D, Ford R, Dancey J, Arbuck S, Gwyther S, Mooney M, Rubinstein L, Shankar L, Dodd L, Kaplan R, Lacombe D, Verweij J (2009) New Response Evaluation Criteria in Solid Tumours: revised RECIST guideline (version 1.1). *Eur J Cancer* **45**: 228–247.
- Fleming GF (2007) Systemic chemotherapy for uterine carcinoma: metastatic and adjuvant. *J Clin Oncol* **25**: 2983–2990.
- Hayes MP, Wang H, Espinal-Witter R, Douglas W, Solomon GJ, Baker SJ, Ellenson LH (2006) PIK3CA and PTEN mutations in uterine endometrioid carcinoma and complex atypical hyperplasia. *Clin Cancer Res* **12**: 5932–5935.
- Janku F, Tsimberidou AM, Garrido-Laguna I, Wang X, Luthra R, Hong DS, Naing A, Falchook GS, Moroney JW, Piha-Paul SA, Wheler JJ, Moulder SL, Fu S, Kurzrock R (2011) PIK3CA mutations in patients with advanced cancers treated with PI3K/AKT/mTOR axis inhibitors. *Mol Cancer Ther* **10**: 558–565.
- Memarzadeh S, Zong Y, Janzen DM, Goldstein AS, Cheng D, Kurita T, Schafenacker AM, Huang J, Witte ON (2010) Cell-autonomous activation of the PI3-kinase pathway initiates endometrial cancer from adult uterine epithelium. *Proc Natl Acad Sci USA* **107**: 17298–17303.
- Mita MM, Mita AC, Chu QS, Rowinsky EK, Fetterly GJ, Goldston M, Patnaik A, Mathews L, Ricart AD, Mays T, Knowles H, Rivera VM, Kreisberg J, Bedrosian CL, Tolcher AW (2008) Phase I trial of the novel mammalian target of rapamycin inhibitor deforolimus (AP23573; MK-8669) administered intravenously daily for 5 days every 2 weeks to patients with advanced malignancies. *J Clin Oncol* **26**: 361–367.
- Oza AM, Elit L, Tsao MS, Kamel-Reid S, Biagi J, Provencher DM, Gotlieb WH, Hoskins PJ, Ghatage P, Tonkin KS, Mackay HJ, Mazurka J, Sederias J, Ivy P, Dancey JE, Eisenhauer EA (2011a) Phase II study of temsirolimus in women with recurrent or metastatic endometrial cancer: a trial of the NCIC Clinical Trials Group. *J Clin Oncol* **29**: 3278–3285.
- Oza AM, Poveda A, Del Campo JM, Richard A, Dorer DJ, Haluska F (2011b) A randomized phase II trial of ridaforolimus compared with progestin or chemotherapy in female adult patients with advanced endometrial carcinoma. Presented at the 47th Annual Meeting of the American Society of Clinical Oncology Chicago, IL, USA, 3–7 June.
- Pectasides D, Pectasides E, Economopoulos T (2007) Systemic therapy in metastatic or recurrent endometrial cancer. *Cancer Treat Rev* **33**: 177–190.
- Pilote AP, Hohos MB, Polson KM, Huftalen TM, Treister N (2011) Managing stomatitis in patients treated with mammalian target of rapamycin inhibitors. *Clin J Oncol Nurs* **15**: E83–E89.
- Rizzieri DA, Feldman E, Dipersio JF, Gabrail N, Stock W, Strair R, Rivera VM, Albitar M, Bedrosian CL, Giles FJ (2008) A phase 2 clinical trial of deforolimus (AP23573, MK-8669), a novel mammalian target of rapamycin inhibitor, in patients with relapsed or refractory hematologic malignancies. *Clin Cancer Res* **14**: 2756–2762.
- Salvesen HB, Stefansson I, Kretzschmar EI, Gruber P, MacDonald ND, Ryan A, Jacobs JJ, Akslen LA, Das S (2004) Significance of PTEN alterations in endometrial carcinoma: a population-based study of mutations, promoter methylation and PTEN protein expression. *Int J Oncol* **25**: 1615–1623.
- Seki Y, Yamamoto N, Tamura Y, Goto Y, Shibata T, Tanioka M, Asahina H, Nokihara H, Yamada Y, Shimamoto T, Noguchi K, Tamura T (2012) Phase I study for ridaforolimus, an oral mTOR inhibitor, in Japanese patients with advanced solid tumors. *Cancer Chemother Pharmacol* **69**: 1099–1105.
- Shafer A, Zhou C, Gehrig PA, Boggess JF, Bae-Jump VL (2010) Rapamycin potentiates the effects of paclitaxel in endometrial cancer cells through inhibition of cell proliferation and induction of apoptosis. *Int J Cancer* **126**: 1144–1154.
- Shorning BY, Griffiths D, Clarke AR (2011) Lkb1 and Pten synergise to suppress mTOR-mediated tumorigenesis and epithelial-mesenchymal transition in the mouse bladder. *PLoS One* **6**: e16209.
- Siegel R, Ward E, Brawley O, Jemal A (2011) Cancer statistics, 2011: the impact of eliminating socioeconomic and racial disparities on premature cancer deaths. *CA Cancer J Clin* **61**: 212–236.
- Slomovitz BM, Lu KH, Johnston T, Coleman RL, Munsell M, Broadus RR, Walker C, Ramondetta LM, Burke TW, Gershenson DM, Wolf J (2010) A phase 2 study of the oral mammalian target of rapamycin inhibitor, everolimus, in patients with recurrent endometrial carcinoma. *Cancer* **116**: 5415–5419.
- Sorosky JI (2008) Endometrial cancer. *Obstet Gynecol* **111**: 436–447.
- Squillace RM, Miller D, Cookson M, Wardwell SD, Moran L, Clapham D, Wang F, Clackson T, Rivera VM (2011) Antitumor activity of ridaforolimus and potential cell-cycle determinants of sensitivity in sarcoma and endometrial cancer models. *Mol Cancer Ther* **10**: 1959–1968.
- Temkin SM, Yamada SD, Fleming GF (2010) A phase I study of weekly temsirolimus and topotecan in the treatment of advanced and/or recurrent gynaecologic malignancies. *Gynecol Oncol* **117**: 473–476.

This work is published under the standard license to publish agreement. After 12 months the work will become freely available and the license terms will switch to a Creative Commons Attribution-NonCommercial-Share Alike 3.0 Unported License.