

Intestinal myiasis in a very elderly patient with inappropriate home care

Junki Mizumoto MD  | Minako Yamamoto MD

Department of Family Practice, Ehime Seikyoku Hospital, Ehime, Japan

Correspondence

Junki Mizumoto, Department of Family Practice, Ehime Seikyoku Hospital, Ehime, Japan.
Email: jnk_mizu@yahoo.co.jp

Abstract

An 83-year-old Japanese woman with dementia presented with multiple pressure ulcers and cellulitis. At presentation, numerous white maggots were wriggling in the stool on the diaper. Interview to the family revealed that the patient received inappropriate home care due to her dementia and her primary caregiver's developmental disability. No further maggots were omitted after admission, and she was diagnosed with intestinal myiasis. Intestinal myiasis has become rare in developed countries especially in adults. However, elderly bedridden patients living in poor hygiene conditions are at a greater risk of developing intestinal myiasis.

KEYWORDS

elderly, gastrointestinal medicine, home care, housefly, intestinal myiasis, maggot

1 | INTRODUCTION

Intestinal myiasis (IM) is a condition in which housefly larvae are resident in the intestine. Ingestion of housefly eggs or larvae via contaminated food or water may cause IM.¹ Its clinical presentation ranges from asymptomatic cases to abdominal discomfort to rectal bleeding.² It is considered as complete recovery from IM when no maggots are in the stool, which typically requires no specific treatments other than removal of causes.^{3,4}

Intestinal myiasis can be found throughout the world and is more common in regions with low socioeconomic conditions and poor hygiene.¹ In addition, most patients are children.¹ However, IM can occur even in elderly patients and in developed countries if poor hygiene conditions are present. Herein we report a case of an elderly patient with dementia, who developed IM due to lousy sanitation associated with inappropriate home care.

2 | CASE

An 83-year-old Japanese woman presented to our hospital with fever. She denied any pain. Her medical history included cerebral hemorrhage,

but she was not regularly taking any medication. The patient appeared disheveled and uncommunicative. The body temperature was 37.9°C, the blood pressure 94/18 mm Hg, the pulse 120 beats per minute, and the oxygen saturation 96% while breathing ambient air. Because her body was severely soiled and had an offensive odor, we cleaned it, which revealed numerous white maggots wriggling in the stool on her diaper. Some staff exclaimed in surprise, causing some of the maggots to turn back into the patient's anus (Figure 1).

Upon physical examination after decontamination, no maggots were observed in the patient's mouth. Cardiorespiratory and abdominal examinations were unremarkable. Multiple pressure ulcers with severe inflammation as well as flexion contracture of the bilateral hip and knee joints were noted. Laboratory tests revealed a white blood cell count of 19 090/μL, C-reactive protein level of 15.72 mg/dL, blood urine nitrogen level of 49.0 mg/dL, and creatinine level of 0.77 IU/L. The aminotransferases, creatinine kinase, and electrolyte levels were normal. Chest, abdominal, and pelvic computed tomography without contrast showed no abnormal findings. We diagnosed the patient with cellulitis, dehydration, and possible IM. The patient was treated with fluid repletion and administered antibiotics. Her condition improved in a few days, and no further maggots were observed after the initial admission.

This is an open access article under the terms of the Creative Commons Attribution-NonCommercial License, which permits use, distribution and reproduction in any medium, provided the original work is properly cited and is not used for commercial purposes.

© 2019 The Authors. *Journal of General and Family Medicine* published by John Wiley & Sons Australia, Ltd on behalf of Japan Primary Care Association.

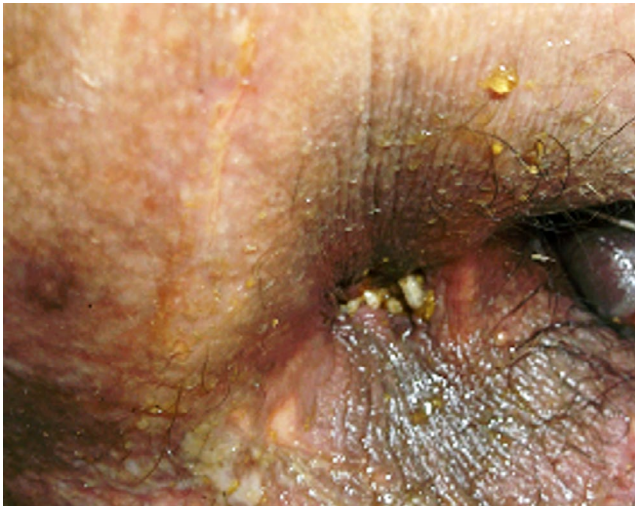


FIGURE 1 White maggots around the patient's anus

A detailed family interview revealed her living circumstances. She had been almost bedridden for over a year since discharge from another hospital following acute management of cerebral hemorrhage. Her cognitive function had gradually been impaired. She was unable to afford to use an official nursing service although she had a certification to receive it. In addition, her dementia and delusional disorder made it difficult for her family to care for her. Her main diet was bread, which her family members left beside the door of her room. There were breadcrumbs scattered around her bed, and her room was infested with numerous houseflies. Despite these poor living conditions, her son, who was her primary caregiver and was presumed to have an undiagnosed developmental disability, reported that he thought that the family's care was adequate. After consideration of the contents of the interview and the lack of any further emergence of maggots after hospitalization, we made a definitive diagnosis of IM.

During the patient's hospitalization, we set up many opportunities to converse with her family. They finally accepted to receive

TABLE 1 Features of intestinal myiasis in developed countries since 2000

Age (years), gender	Country	Environment	Outcome	Note
85, male ³	Japan	At home with elderly wife with dementia.	No further emission of maggots. The patient died on day 4 in the hospital.	The patient was severely ill with cerebral infarction.
89, female ⁵	France	In a hospital.	Not described.	-
47, male ²	Russia	Drinking a liter of water in the barrel for organic fertilizers.	Abdominal pain, nausea, and malaise had lasted for 10 d until he was administered an enema.	The patient was drunken when drinking the water.
36, male ⁴	Belgium	At home. The patient engaged in cleaning of septic tanks, and his favorite food was filet americain.	No further emission of maggots after 3-4 d.	In August 2003, when whether is hot.
81, male ⁶	Japan	At home with elderly wife.	Not described.	The patient was bedridden with dementia and hemiplegia due to cerebral hemorrhage.
21, male ⁷	Taiwan	Duck was reared near the house. There were flies in the kitchen, and food was never covered.	Symptoms disappeared after administration of mebendazole.	-
36, female ⁸	Spain	Living in a city with good sanitation.	No further emission of maggots without any administration.	The patient had Crohn's disease and was taking adalimumab.
51, female ⁹	Spain	Living in a suburb. The frequency of cleaning a fountain, where larvae were found previously, was twice a year.	No further emission of maggots after administration of cotrimoxazole.	-
53, female ¹⁰	French	At home with a domestic garden, where a septic tank was located.	No further emission of maggots without any administration.	-
42, female ¹¹	French	A recent trip to a small fishing village in Colombia.	Three other larvae were emitted over the following 2 d.	-
44, male ¹²	UK	A trip to a rural area in southern France. The cottage was near a number of farms.	Spontaneous resolution of symptoms following the expulsion of the larvae.	-
61, male ¹³	Japan	Having raw lettuce 2 d before the presentation.	No further emission of maggots a few days after administration of levofloxacin.	The patient was healthy except for having type 2 diabetes mellitus and high blood pressure.

some medical and nursing services for the patient at home. After she was discharged, her living conditions were improved, and she was well at a 15-month follow-up.

3 | DISCUSSION

We report an elderly bedridden patient with intestinal myiasis due to the lack of appropriate home care. This case underscores the importance of consideration of the living conditions of patients with dementia or significant disability, as well as the mental, physical, or social condition of the primary caregiver.

Various species of maggots can cause myiasis worldwide. Although *Dermatobia hominis* and *Cordylobia anthropophaga* are obligately parasitic, they do not live in Japan.¹ Pathogens of IM in Japan include *Sarcophagidae*, *Phoridae*, and *Calliphoridae* in order of frequency.¹ We did not identify the species of maggot in the present case, however, considering all cases of domestic myiasis reported in Japan are due to occasional parasitism and there are no significant differences in clinical presentation.¹

Patients' background and cause of IM have been changed recently. In the past, IM was mostly seen in children living in the area with poor hygiene in developing countries; however, recent cases of IM have also occurred in the area with good hygiene in developed countries. Table 1 shows the summary of case reports of IM in developed countries since 2000. Based on this summary, several factors seem to be related to IM in developed countries: Firstly, there tended to be an organic farm or stock farm in or near the dwelling houses; secondly, IM can present as a travelers' disease; and thirdly, even bedridden elderly patients can develop IM. In particular, the fact that recent IM cases in Japan occurred mostly in the elderly, like the present case, is of great concern considering the aging in developed countries including Japan. Risk factors of elderly IM seem to be following: firstly, comorbidity with severe neurological diseases renders them unable to eat or move by themselves; and secondly, the living conditions tend to be disordered and lacking in proper hygiene measures, to the degree that the patient's food is contaminated by housefly eggs or larvae. These findings indicate that elderly bedridden patients who are not given appropriate nursing care are at a greater risk of developing IM.

4 | CONCLUSION

We report a very elderly case of IM receiving inappropriate home care. Severe neurological underlying diseases, lousy sanitation, and bad care environment seem to be risk factors of elderly IM. We should consider multilaterally the conditions of patients with significant disability and the primary caregiver.

ACKNOWLEDGEMENTS

The authors would like to thank Dr. Yukinori Harada for useful discussion.

CONFLICT OF INTEREST

The authors have stated explicitly that there are no conflicts of interest in connection with this article.

ORCID

Junki Mizumoto  <https://orcid.org/0000-0002-0783-7351>

REFERENCES

1. Sueyoshi M. Review of the human myiasis in Japan. *Med Entomol Zool.* 2015;66(3):91–120. (In Japanese).
2. Bronshtein AM, Malyshev NA. Advanced intestinal myiasis. *Klin Med (Mosk).* 2004;82(6):69–70. (In Russian).
3. Tanaka N, Otomo S, Misawa R, Hasizume S. A case of intestinal myiasis caused by the larvae of genus sarcophaga. *Annu Rep Gunma Prefectural Inst Pub Health Environ Sci.* 2001;33:163–4. (In Japanese).
4. Dubois E, Durieux M, Franchimont MM, Hermant P. An unusual case in Belgium of intestinal myiasis due to *Eristalis tenax*. *Acta Clin Belg.* 2004;59(3):168–70. (In French)
5. Soliman RS, Phillips G, Spence G. 'I know an old lady who swallowed a fly': a case of (hospital-acquired) human intestinal myiasis. *J Hosp Infect.* 2003;53(2):157–8.
6. Haruki K, Aoyama K, Katagiri T, Yamamoto T, Sakurai H, Kobayashi M, et al. Guuhatusei Gisei Tyoukan Hae Syou no 1 Rei (A Case of Contingent Intestinal Pseudo-Myiasis). *Jpn J Hyg.* 2005; 60(2):240. (In Japanese)
7. Tu WC, Chen HC, Chen KM, Tang LC, Lai SC. Intestinal myiasis caused by larvae of *Telmatoscopus albipunctatus* in a Taiwanese man. *J Clin Gastroenterol.* 2007;41(4):400–2.
8. Ferrer Bradley I, Navarro Pérez L, Maroto Arce N. Myiasis caused by *Eristalis tenax* in Crohn's disease. *Gastroenterol Hepatol.* 2010;33(8):616–7. (In Spanish).
9. Clavel A, Toledo M, Goñi P, Aspiroz C. Intestinal myiasis due to *Eristalis tenax*: report of a new case in Spain. *New Microbiol.* 2011;34(3):335–6.
10. Raffray L, Malvy D. Accidental intestinal myiasis caused by *Eristalis tenax* in France. *Travel Med Infect Dis.* 2014;12(1):109–10.
11. Desoubreux G, Gaillard J, Borée-Moreau D, Bailly É, Andres CR, Chandenier J. Gastrointestinal symptoms resembling ulcerative proctitis caused by larvae of the drone fly *Eristalis tenax*. *Pathog Glob Health.* 2014;108(3):158–63.
12. Lewis JM, Winslow H, Jones J, Taegtmeier M, O'Dempsey T, Nsutebu E. Cramping and diarrhea in a 44-year-old man. *Clin Infect Dis.* 2015;61(3):432, 480–481.
13. Watanabe N, Kato T, Ichiyonagi Y, Kubota Y, Sugie S, Kadosaka T, et al. A case report of intestinal myiasis in a Japanese man. *Open J Pathol.* 2016;6:171–6.

How to cite this article: Mizumoto J, Yamamoto M. Intestinal myiasis in a very elderly patient with inappropriate home care. *J Gen Fam Med.* 2019;20:154–156. <https://doi.org/10.1002/jgf2.247>