

New insights about suprapatellar cyst

Tomislav Crnković,¹ Drago Gašpar,²
Dražen Đurović,³ Dinko Podsednik,²
Ferdinand Slišurić³

¹Department of Orthopaedic Surgery;

²Department of Traumatology and

³Department of General surgery, General County Hospital of Požega, Požega, Croatia

Abstract

Suprapatellar bursa is located between the quadriceps tendon and femur, and it develops before the birth as a separate synovial compartment proximal to the knee joint. By the fifth month of fetal life there is a suprapatellar septum between the knee joint cavity and suprapatellar bursa which later perforates and involutes in a way that a normal communication between the cavity of bursa and knee is established. A small portion of the embryonic septum can later lag as more or less expressed suprapatellar plica. In case when suprapatellar plica has a small communication with valve mechanism or in case of complete septum, bursa becomes a separate compartment and potential location for the suprapatellar cyst development. Magnetic resonance imaging is recognised as the *gold standard* in diagnosis of knee cysts because of its ability to show cystic nature of the lesion, its relationship with other anatomic structures, as well as to establish whether other knee pathologies are present. Considering treatment possibilities, majority of cysts around the knee resolve spontaneously and should be treated by aspiration and application of corticosteroids. Suprapatellar cyst is a very rare knee pathology and it can in some occasions be treated using open or arthroscopic surgery.

Introduction

Unusually located cysts around knee are clinical challenge for every orthopaedic surgeon in respect of their etiology, diagnosis, and the decision of their adequate treatment. They are usually presented with palpable mass, pain, limited range of movement or they can be asymptomatic, accidentally discovered by magnetic resonance imaging (MRI) after a knee injury.^{1,2} Although cystic masses like popliteal cyst, cyst of the medial and lateral meniscus are very well described in orthopaedic literature, there are few written reports of isolated

suprapatellar bursitis or cyst. In general, bursae are anatomic structures located between the bone surface and tendon and ligaments that reduce the friction between these moving structures. They contain a limited amount of fluid and usually are not visible under MRI. Inflammation of a bursa caused by different systemic and local processes leads to synovial wall thickening and fluid accumulation within the bursa. This can usually be visualized under MRI as a limited fluid clusters.¹

In the knee joint, synovial membrane braids its complete interior and covers intracapsular ligaments and the free surface if infrapatellar fat tissue. However, the joint cavity and the synovial layer of the knee continue above the patella to the cavity located between the quadriceps tendon and femur, which is called the suprapatellar bursa. Despite that anatomy describes and defines the suprapatellar bursa and its communication with the knee joint cavity very well, the fact is that in everyday practice that joint cavity and suprapatellar bursa are still considered as one synovial area, and the line between them is usually more or less expressed synovial fold, also known as suprapatellar plica.³ However, although rarely, suprapatellar bursa can remain completely separated from the knee joint by a complete septum. This can result in the formation of a separated compartment inside which fluids can be accumulated and can lead to the formation of suprapatellar cyst. In medical literature synonyms for this pathology are suprapatellar synovial cyst, suprapatellar bursitis or ante-femoral cyst.^{1,4}

Anatomy and etiology

Suprapatellar bursa develops before the birth as a single synovial area proximal to the knee joint. During the eight week of embryonic development the knee joint is divided into three compartments separated by embryonic synovial membranes: superior femoropatellar compartment (suprapatellar bursa) and two inferior femorotibial compartments (medial and lateral synovia)^{3,4,5} (Figure 1).

Between the third and fifth month of intrauterine development the membranes start to involute and the knee joint becomes a single cavity. In case that synovial membranes do not completely vanish, the remaining part after the birth is called synovial crease or plicae. Synovial plica can be more or less expressed and it can be divided into suprapatellar, medial patellar, lateral patellar and infrapatellar plica, and the incidence rate of these structures in adult knee is around 20%.⁶⁻⁸

By the fifth month of fetal life there is a suprapatellar septum between the knee joint

Correspondence: Tomislav Crnković, General County Hospital of Požega, Department of Orthopaedic Surgery, Osječka 107, 34 000 Požega, Croatia.
Tel. +385.34.254.461 - Fax: +385.34.271.713.
E-mail: tomislav_crnkovic@inet.hr

Key words: suprapatellar cyst, bursitis, knee, diagnostic, therapy.

Received for publication: 6 September 2011.

Accepted for publication: 3 December 2011.

This work is licensed under a Creative Commons Attribution NonCommercial 3.0 License (CC BY-NC 3.0).

©Copyright T. Crnković et al., 2012
Licensee PAGEPress srl, Italy
Orthopedic Reviews 2012; 4:e9
doi:10.4081/or.2012.e9

cavity and suprapatellar bursa that later perforates and involutes so that it established a normal communication between the knee and bursa cavity. A small part of embryonic remnants can later persist as a suprapatellar plica and Pipkin states that it can be found in 78% of adult knees.⁹ Zidorn¹⁰ has made an anatomical study on 233 knees and classified adult suprapatellar septum into four groups.

The first group is a complete septum where the suprapatellar bursae completely separated from the knee joint, and the second group is perforated septum with one or more septum openings of different sizes. The third group is the most common and it appears as a residual septum or synovial plica, and the fourth group is completely involuted septum. Suprapatellar bursa can very rarely remain completely separated from the knee joint cavity by an intact septum. In literature, complete suprapatellar membrane can be found in 7% of knees, while in 9% of knees it can be found a small central opening called *porta*.^{3,7} In such cases the formation of separate compartment occurs inside of which, under certain circumstances, fluids can be accumulated.

Accordingly, suprapatellar cyst appears due to the widening and fluid accumulation within separated bursa as a result of the following causes: synovitis, infection and hemorrhage, trauma or overuse syndrome^{1,11} (Figures 2 and 3). Although according to the data which Pipkin⁹ and Shetty¹² state, suprapatellar cyst shows certain similarities with the Baker cyst. They assume that there is a communication between the joint and cyst and that during motions knee acts as a pump which through valvular mechanism enables one-way flow of the synovial fluid from the joint into the cyst.

Crnkovic et al.² have described an isolated

suprapatellar cyst in a 12-year-old girl that showed similarities with Baker's cyst just because of the existence of valve communication between the joint and the cyst (Figure 4A, B).

Clinical presentation and imaging findings

Suprapatellar cyst is manifested by the appearance of the soft tissue formation above the patella which may also resemble a solitary tumor above the knee. Anterior knee pain or limited flexion with tension and snapping in the front of the joint may appear. Activities such as longer standing, squatting and stair climbing may be painful and difficult.^{7,13} Furthermore, the appearance of sudden pain with diffuse swelling or hemathoma in the thigh and the knee, without trauma in anamnesis may indicate a spontaneous rupture of bursa which may imitate a deep venous thrombosis and may therefore lead to a diagnostic dilemma.¹⁴ Conventional radiography, although very quick and simple test, which is frequently being used in an initial evaluation of the knee, in most of the situations has limited value in soft tissues pathology, and in rare cases can eventually show osteocartilaginous bodies inside the detached cyst.^{3,15} As a diagnostic means, some authors use ultrasound, arthrography, scintigraphy and computerized tomography. Coperberg *et al.*¹⁶ described the suprapatellar swelling which in ultrasound seems as a defined cavity filled with fluid above the patella, under the distal femur and behind the quadriceps tendon. If contrast arthrography is performed, suprapatellar cyst can be recognized as a decreased suprapatel-

lar space, or as outer compression to the suprapatellar space.^{5,17} Yamamoto *et al.*¹⁸ found an increased isotope activity above the patella with an early scintigraphs with a Thallium.

Lee *et al.*⁴ diagnosed a suprapatellar cyst in two cases by using the computerised tomography in a form a semilunar cystic formation surrounded by a wall which is 0.8-1.2 mm thick with irregular exterior surface. The content of the cysts varied from a transudat to a mucous fluid with high density. However, in the literature MRI is recognized as the *gold standard* in

the diagnostics of knee cysts because of its ability to show the cystic nature of the lesion, its relationship with other anatomic structures, as well as to establish whether other knee pathologies are present.^{11,15,19-22}

Management

Seidl *et al.*²³ successfully conservatively treated four antefemoral cysts by patients with rheumatoid arthritis using corticosis-

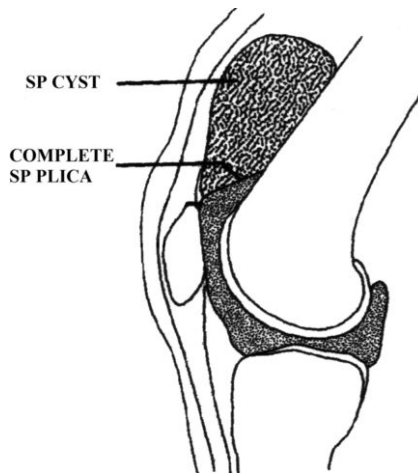


Figure 2. Complete suprapatellar membrane with suprapatellar cyst (schematic view).

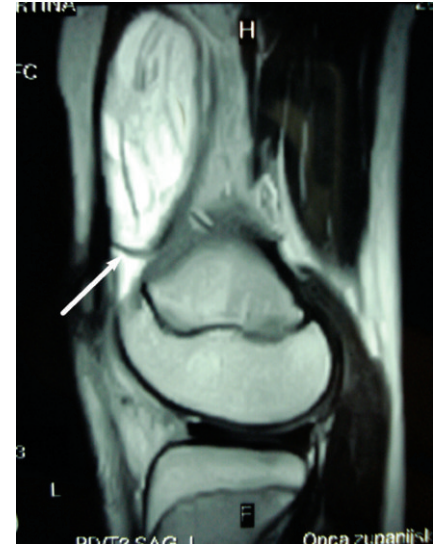


Figure 3. Sagittal magnetic resonance image of knee showing suprapatellar cyst between quadriceps tendon and femur with intact suprapatellar septum (arrow).

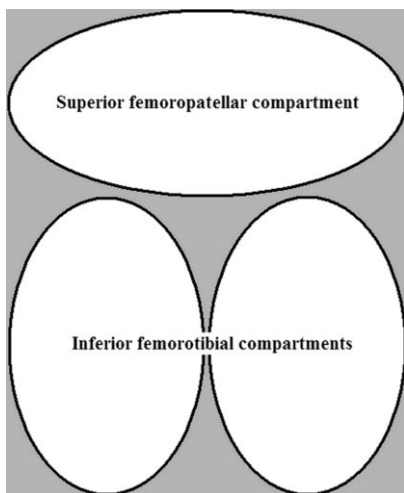


Figure 1. Embryonic development of knee joint cavity.

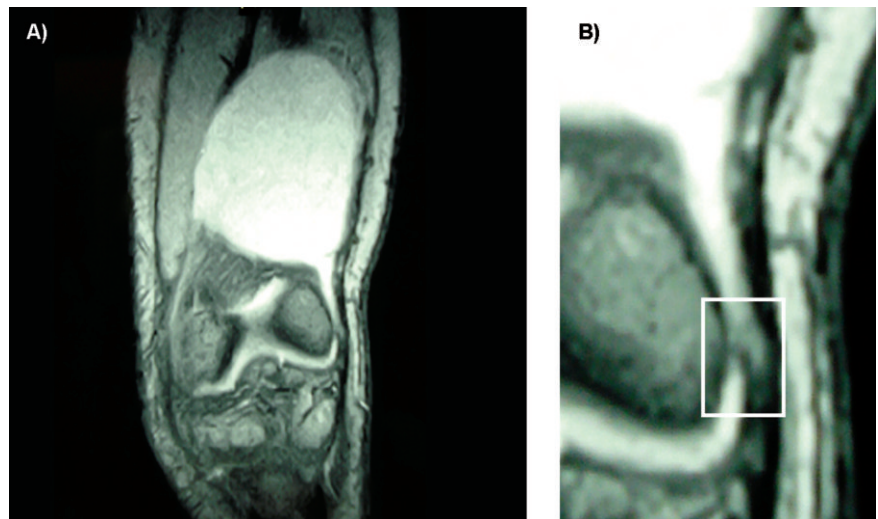


Figure 4. A) Coronal magnetic resonance image of knee showing suprapatellar cyst which communicates with a knee joint; B) valvular mechanism which enables one-way flow of the synovial fluid from the joint into the cyst.

teroids, while it has been resistant to conservative therapy in only one case where it was removed surgically. McCabe¹⁴ described a spontaneous rupture of the suprapatellar bursa which was resembling a deep venous thrombosis of the lower extremity and was treated with anticoagulants. Deep venous thrombosis was later excluded with a normal venograph, and the rupture of the bursa was diagnosed with a knee arthrography, and was successfully cured by resting and bandage of the extremities.

Pipkin,³ Lee et al.⁴ and Duncan¹⁷ treated the suprapatellar cysts by open extirpation, while Yamamoto et al.¹⁸ also made an open excision after a diagnostic arthroscopy of knee.

Crnkovic et al.² and Ziswiler et al.⁶ described the arthroscopic decompression of the suprapatellar cysts by making a defect in the suprapatellar membrane by an anterolateral portal, and Ziswiler made an additional superolateral portal for a better inspection of the cyst.

Boya et al.²⁴ described a rare case of a synovial osteochondromatosis in an isolated suprapatellar bursa with loose bodies within the bursa which they handled arthroscopically. With a medial suprapatellar portal and a defect which they did in the membrane, they visualised loose bodies and extracted them from the bursa. Authors who treated the suprapatellar cyst with an open extirpation report a complication of postoperative hemathoma, which was surgically evacuated, whereas there were not any postoperative complications after arthroscopically operated cysts. There were not any recidives in either case.

It is obvious that with the development of the arthroscopic technique new perspectives in the treatment of the suprapatellar cyst appear.²⁵ However, although surgeon may show the presence of a complete suprapatellar septum during arthroscopy, without a proper clinical and radiological evaluation, the diagnosis of a suprapatellar cyst can be missed.¹⁸ Special care should be taken with regard to eventual existence of osteocartilaginous bodies inside the suprapatellar cyst, because it is not possible to visualize them by standard arthroscopic anterolateral approach, in case, when completely separated cyst from a knee joint is not diagnosed.³ In that case, Boya²⁴ recommends not rupturing the suprapatellar membrane so that loose bodies would not fall into the knee cavity and make their removal extremely difficult, he suggest that the arthroscope and the instruments should be inducted directly into the bursa, in other words making bursoscopy which is much safer in these cases.

Discussion

The embryonic development of the knee joint cavity is still an object of many researches. Although a consensus has not been reached yet, the three cavitation theory is widely accepted. However, although the three cavitation theory in the development of the knee may explain the finding of a suprapatellar and infrapatellar plica, the origin of the medial and lateral patellar plica remains disputable.⁸ Although, theory cannot explain the great variability in the size and shape of the synovial plicae which is an additional argument which supports the multiple cavitation theory suggested by Gray and Gardner²⁶ and Ogata.²⁷ Regardless of the noted facts, the suprapatellar cavity contains many variations in the communication between suprapatellar bursa and the knee joint cavity. In the cases where the suprapatellar plica has a small central opening with valve mechanism or in case of a complete membrane, the bursa becomes a separate compartment and a potential place for the development of a cystic formation.^{4,7}

Furthermore, a correct imaging diagnostic gives important information for the choice of an adequate treatment. According to Steiner²² the main determinates in the evaluation of the cystic formations should be: the confirmation of a cystic lesion, relation between cyst and knee joint and its structures, and evaluation of associated intra-articular pathology.

Most of the cysts around the knee in children resolve spontaneously and should be treated conservatively, which include aspiration and application of corticosteroids.^{23,28} Indication for arthroscopic intra-articular decompression would be a large cyst with non-specific synovitis or hemorrhage inside the cyst, with pain and limited range of motion, or, with associated intra-articular pathology. Intra-articular decompression should not be applied in cases of suppurative bursitis, because of possible unnecessary knee joint contamination.²

References

1. McCarthy CL, McNally EG. The MRI appearance of cystic lesions around the knee. *Skeletal Radiol* 2004;33:187-209.
2. Crnkovic T, Matijasevic B, Matokovic D. Large suprapatellar synovial cyst in a 12-year-old girl: arthroscopic decompression. *J Pediatr Orthop B* 2010;19:114-7.
3. Pipkin G. Knee injuries: the role of the suprapatellar plica and suprapatellar bursa in simulating internal derangements. *Clin Orthop* 1971;74:161-76.
4. Lee KR, Tines SC, Yoon JW. CT findings of suprapatellar synovial cysts. *J Comput Assist Tomogr* 1984;8:296-9.
5. Deutsch AL, Resnick D, Dalinka MK, et al. Synovial plicae of the knee. *Radiology* 1981; 141:627-34.
6. Ziswiler M, Radu EW, Romero J. Chondrocalcinosis in an isolated suprapatellar pouch with recurrent effusion. *Arthroscopy* 2002;18:E14.
7. Bae DK, Nam GU, Sun SD, Kim YH. The clinical significance of the complete type of suprapatellar membrane. *Arthroscopy* 1998;14:830-5.
8. Kim SJ, Choe WS. Arthroscopic findings of the synovial plicae of the knee. *Arthroscopy* 1997;13:33-41.
9. Pipkin G. Lesions of the suprapatellar plica. *J Bone Joint Surg Am* 1950;32:363-9.
10. Zidorn T. Classification of the suprapatellar septum considering ontogenetic development. *Arthroscopy* 1992;8:459-64.
11. Beaman FD, Peterson JJ. MR imaging of cysts, ganglia, and bursae about the knee. *Magn Reson Imaging Clin N Am* 2007;15:39-52.
12. Shetty GM, Wang JH, Ahn JH, et al. Giant synovial cyst of knee treated arthroscopically through a cystic portal. *Knee Surg Sports Traumatol Arthrosc* 2008;16:175-8.
13. Palmer DG. Antero-medial synovial cysts at the knee joint in rheumatoid disease. *Aust Radiol* 1972;16:79-83.
14. McCabe JP, Gilmore MF. Spontaneous rupture of the suprapatellar bursa. *J Bone Joint Surg Br* 1990;72:927.
15. Beall DP, Ly JQ, Wolff JD, et al. Cystic masses of the knee: magnetic resonance imaging findings. *Curr Probl Diagn Radiol* 2005;34:143-59.
16. Cooperberg PL, Tsang L, Truelove L, Knickerbocker WJ. Gray scale ultrasound in the evaluation of rheumatoid arthritis of the knee. *Radiology* 1978;126:759-63.
17. Duncan AM. Arthrography in rupture of the suprapatellar bursa with pseudocyst formation. *Am J Roentgenol Radium Ther Nucl Med* 1974;121:89-93.
18. Yamamoto T, Akisue T, Marui T, et al. Isolated suprapatellar bursitis: computed tomographic and arthroscopic findings. *Arthroscopy* 2003;19:E10.
19. Solanki KK, Sawyers S. An unusual presentation of synovial cyst of the right knee. *Intern Med J* 2003;33:387-8.
20. Siebert CH, Kaufmann A, Niedhart C, Heller KD. The quadriceps tendon cyst: an uncommon cause of chronic anterior knee pain. *Knee Surg Sports Traumatol Arthrosc* 1999;7:349-51.
21. Marra MD, Crema MD, Chung M i sur. MRI features of cystic lesions around the knee. *Knee* 2008;15:423-38.
22. Steiner E, Steinbach LS, Schnarkowski P, et al. Ganglia and cysts around joints.

- Radiol Clin North Am 1996;34:395-425.
23. Seidl G, Scherak O, Hofner W. Antefemoral dissecting cysts in rheumatoid arthritis. *Radiology* 1979;133:343-7.
 24. Boya H, Pinar H, Ozcan O. Synovial osteochondromatosis of the suprapatellar bursa with an imperforate suprapatellar plica. *Arthroscopy* 2002;18:E17.
 25. Hammer DS, Dienst M, Kohn DM. Arthroscopic treatment of tumor-like lesions of the knee joint: localized pigmented villonodular synovitis and ganglion cyst of the anterior cruciate ligament. *Arthroscopy* 2001;17: 320-3.
 26. Gray DJ, Gardner E. Prenatal development of the human knee and superior tibiofibular joints. *Am J Anat* 1950;86:235-87.
 27. Ogata S, Uthoff HK. The development of synovial plicae in human knee joints: an embryologic study. *Arthroscopy* 1990;6: 315-21.
 28. Roth J, Scheer I, Kraft S, et al. Uncommon synovial cysts in children. *Eur J Pediatr* 2006;165:178-81.