

Postoperative Sequelae Following Surgical Extraction of Impacted Mandibular Third-Molar Extraction Using the Complete Closure Versus the Sutureless Techniques

Abstract

Background: Wound closure techniques affect the severity of inflammatory complications that ensue following surgical extraction of the impacted mandibular third molar (M3). The choice of the technique remains a topic for discussion because reports regarding their associated sequelae are split. This study therefore compares the pain, swelling and trismus in the complete closure and the sutureless/non-closure techniques. **Materials and Methods:** This was a prospective, randomised clinical study carried out at the Dental and Maxillofacial Surgery department of a tertiary hospital. A total of 74 participants requiring impacted mandibular M3 extractions were randomised into a complete closure group and a sutureless technique group. They were subjected to the procedure under similar technique and conditions and followed up for a week to assess their experiences of pain, swelling and trismus. Variables were recorded and analysed using the Statistical Package for the Social Sciences (SPSS) software program, version 25.0. The critical level of significance was set at $P < 0.05$. **Results:** The sutureless group had statistically significantly higher postoperative pain on days 1, 3, 4 and 5 ($P < 0.05$) and lesser severity of trismus on day 7 ($P < 0.05$) than the complete closure group. There was no significant difference in swelling. **Conclusion:** Compared with the complete closure group, the sutureless group had similar severity of swelling, less trismus but had higher pain severity in the week following M3 surgery.

Keywords: Complete closure, postoperative sequelae, sutureless, third-molar extraction

Introduction

Tooth impaction is a pathologic condition due to the failure of the tooth to attain its normal functional position and is prevented from doing so by lack of space, poor positioning, an abnormal eruption path or an obstruction by another tooth, or by an anomaly.^[1,2] Surgical extraction is most commonly indicated for impacted mandibular wisdom teeth with unrestorable caries, recurrent pericoronitis, or prophylactically for these conditions and for cyst and tumour formation.^[3]

Mandibular third-molar (M3) impaction receives much attention not only due to its high prevalence but also because its extraction is associated with significant pain, swelling and trismus in the days following surgery.^[4] Various methods have been suggested to reduce the postoperative sequelae following M3 surgery such as the administration of corticosteroids,^[5] use of ice packs,^[6]

intraoral buccal drains,^[7,8] antibiotics,^[9] analgesics,^[10] reduced temperatures^[11] and low power laser application.^[12] The suturing technique is believed to affect the severity of these postoperative sequelae, and opinions have been divided on which better reduces these events. The primary closure is the traditional and most used technique in our practice, and it promotes rapid healing and prevents wound contamination. However, the sutureless or non-closure technique has been reported to reduce the postoperative sequelae by allowing a bidirectional drainage of inflammatory exudate.^[13-15] This technique is relatively new, and is gaining recognition among practitioners,^[13] but probably not the expected acceptance.^[16] At the moment, there is insufficient evidence that one technique is better than the other in terms of the pain, swelling and trismus. This study aimed to compare the postoperative pain, swelling and trismus in the primary closure and the sutureless technique for impacted lower M3 extraction.

This is an open access journal, and articles are distributed under the terms of the Creative Commons Attribution-NonCommercial-ShareAlike 4.0 License, which allows others to remix, tweak, and build upon the work non-commercially, as long as appropriate credit is given and the new creations are licensed under the identical terms.

For reprints contact: reprints@medknow.com

How to cite this article: Chukwuma BC, Taiwo AO, Akinmoladun VI, Ibikunle AA, Bala M. Postoperative sequelae following surgical extraction of impacted mandibular third-molar extraction using the complete closure versus the sutureless techniques. *J West Afr Coll Surg* 2022;12:12-9.

Benedict Chimezie Chukwuma, Abdurrazaq Olarenwaju Taiwo¹, Victor I. Akinmoladun, Adebayo Aremu Ibikunle¹, Mujtaba Bala¹

University of Abuja Teaching Hospital, Gwagwalada, Abuja, ¹Usmanu Danfodiyo University Teaching Hospital, Sokoto, Nigeria

Received: 13-Sep-2022

Accepted: 04-Oct-2022

Published: 23-Nov-2022

Address for correspondence:

Dr. Benedict Chimezie Chukwuma, University of Abuja Teaching Hospital, Gwagwalada, Abuja, Nigeria.

E-mail: chukwumabenet@gmail.com

Access this article online

Website:

www.jwacs-jcoac.com

DOI: 10.4103/jwas.jwas_191_22

Quick Response Code:



Materials and Methods

This was a randomised controlled study designed to compare the pain, swelling and trismus in primary closure and sutureless groups on days 1, 3 and 7 following surgery. The study was conducted on patients who presented to the Dental and Maxillofacial Surgery department of a tertiary hospital in Nigeria between November 2019 and December 2020 and required the extraction of an impacted lower M3 under local anaesthesia. Approval for the study was obtained from the Health Research and Ethics Committee (ref XXX/HREC/2018/No.746) of the institution.

Participants in this study were consenting ASA I patients at least 18 years of age

Patients with preoperative pain, facial swelling or limited mouth opening from any cause within 10 days preceding surgery, patients who had allergy to the local anaesthetic agent, and to the study drugs, patients with peptic ulcer disease, smokers, pregnant and lactating mothers, patients on steroids, oral contraceptives, other anti-inflammatory drugs for other reasons were excluded. Patients were randomised into two groups; sutureless (1) and complete closure (2) groups using computer generated random binaries. The indications for extraction, type of impaction and location of M3 (left or right) were also recorded in the proforma designed for this study.

Surgical disimpactions were performed by the same surgeon under similar operative conditions. Bone removal was done using buccal guttering technique under copious continuous irrigation with sterile normal saline. At the completion of tooth removal, the flap was then repositioned, and in group 1 no sutures were placed. Direct pressure was applied to the surgical site using sterile rolled gauze moistened with normal saline and patient was asked to clench for 30 min to achieve haemostasis. In group 2, multiple interrupted

sutures were placed over the extraction socket to achieve hermetic seal

After assessing the extraction site for haemostasis, patients were discharged home with Caps Amoxicillin (GlaxoSmithKline) 500 mg orally 8 hourly for 5 days and Tabs Metronidazole (Unigyl from Unique pharmaceuticals) 400 mg orally 8 hourly for 5 days after surgery; and Tabs Ibuprofen 400 mg (Brustan-N from Ranbaxy-Sun pharmaceuticals) immediately after the surgery and then 8 hourly for 3 days. Patients were instructed to do warm saline rinses 8 times daily for 7 days. Pain, swelling and trismus were assessed during the week following surgery.

Pain assessment was done using the Visual Analog Scale, which is a horizontal line, 10cm in length, anchored by word descriptors at each end. The left extreme of the line corresponds to 'no pain', whereas the right extreme corresponds to 'extremely severe pain'. The subjects were asked to mark on the line, the point they felt represented their pain perception. This was done daily using self-administered questionnaires.

Swelling was assessed by facial measurements using a non-distensible measuring tape [Figure 1], and was assessed in the clinics on postoperative days (PODs) 1, 3 and 7

Trismus was calculated as the difference in the inter-incisal distance between the preoperative value and that of the follow-up day (PODs 1, 3 and 7). Inter-incisal distance was obtained using a digital vernier caliper [Figure 2] and the measurement was repeated thrice and subsequently the average was recorded in millimetres. The mesial incisal edges of the upper and lower central incisors were used as reference points.

Data were analysed using the Statistical Package for Social Sciences (SPSS) software program, version 25.0 for Windows.

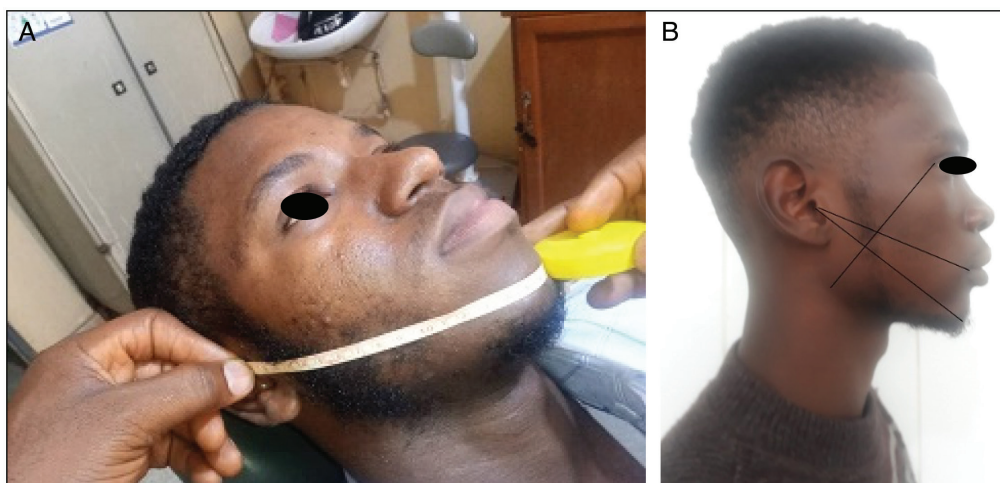

Figure 1: (A) Use of non-distensible measuring tape across the face. Note that tape lies passively on face without compressing the tissues. (B) Facial swelling measurements

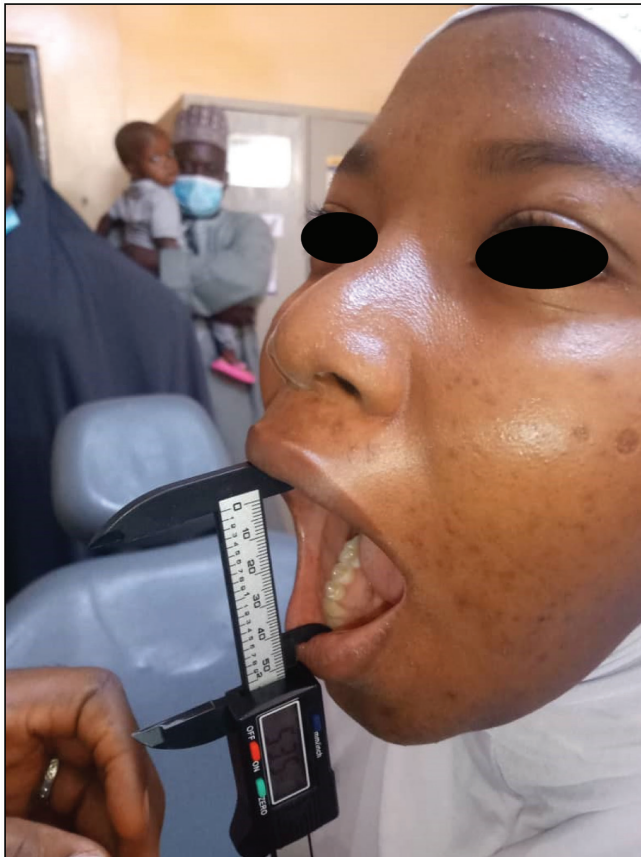

Figure 2: Mouth-opening measurement using a digital veneer calliper

Result

Eighty-six patients satisfied the inclusion criteria and consented to participate in this study. Twelve participants (13.9%) were lost to follow-up, some due to travel costs. Hence, 74 participants completed this study giving a completion rate of 86.1%. Group 1 (sutureless) and Group 2 (complete closure) had 36 and 38 participants, respectively. Participants' age ranged from 18 to 54 years with a mean age (\pm SD) of 30.2(\pm 8.3) years. Of the 74 participants, 35 (47.3%) were females and 39 (52.7%) were males, with a male-to-female ratio was 1.1:1. There were no statistical differences in the mean age, gender distribution, body mass index, impaction type and indications for extraction between the two groups [Table 1].

Pain

: Maximum pain scores were recorded on day 1 after which there was a linear decrease in intensity over the days of review for both groups. Pain score was higher in sutureless group on all PODs, and this difference was statistically significant only on PODs 1, 3, 4 and 5 [Table 2]. However, the rate of decline in pain intensity was higher in sutureless group as seen by the greater steepness of the downward slope [Figure 3].

Swelling:

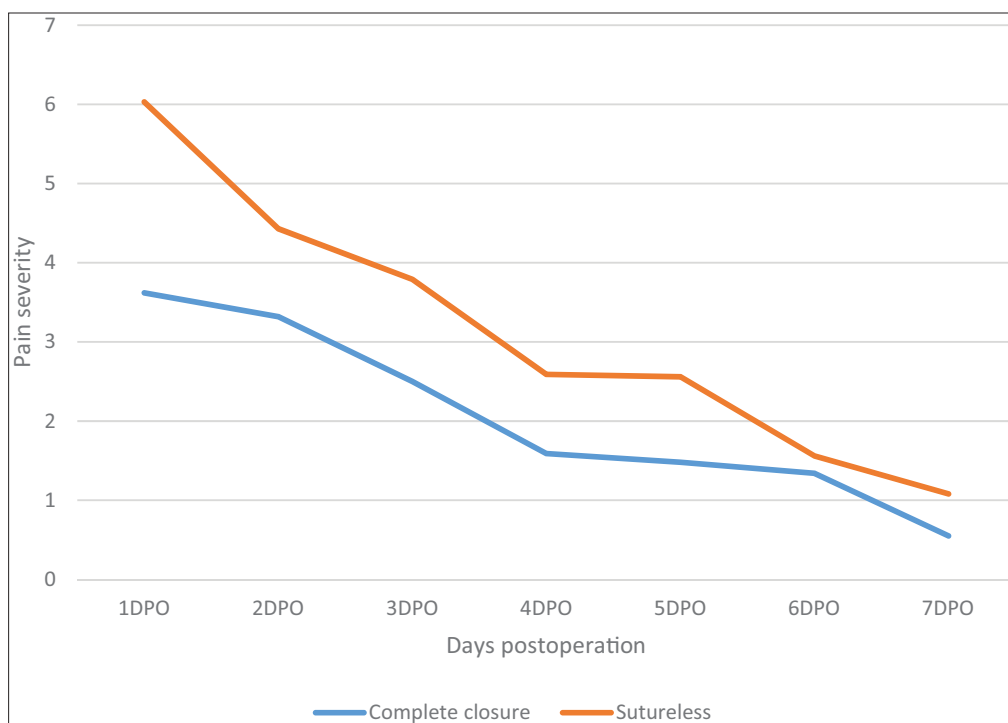
There was significant facial swelling on PODs 1 and 3 in both groups ($P = 0.0$). In both groups, the highest facial

Table 1: Sociodemographic variables in the two groups

		Complete closure	Sutureless	total	χ^2 (P)
		n (%)	n (%)	n (%)	
Age (years)	18–20	2 (5.2)	3 (8.3)	5 (6.7)	3.84 (0.43)
	21–30	19 (50)	22 (61.1)	41 (55.4)	
	31–40	11 (28.9)	8 (22.2)	19 (25.6)	
	41–50	6 (15.7)	2 (5.55)	8 (10.8)	
	51–60	0 (0)	1 (2.78)	1 (1.3)	
Gender	Male	24 (63.16)	15 (41.66)	39 (52.7)	3.42 (.068)
	Female	14 (36.84)	21 (58.33)	35 (47.3)	
BMI (kg/m ²)	Underweight	3 (7.89)	1 (2.77)	4 (5.4)	69.97(0.41)
	Normal	21 (55.26)	26 (72.22)	47 (63.5)	
	Overweight	11 (28.94)	8 (22.22)	19 (25.6)	
	Obese	3 (7.89)	1 (2.77)	4 (5.4)	
Impaction		38 (100)	36 (100)		4.12 (0.39)
	Mesioangular	15 (39.4)	18 (50)	33(44.6)	
	Vertical	11 (28.9)	8 (22.2)	19 (25.7)	
	Horizontal	9 (23.7)	4 (11.1)	13(17.6)	
	Distoangular	3 (7.9)	5 (13.9)	8 (10.8)	
Indication	Lingual	0 (0)	1 (2.7)	1 (1.4)	4.08 (0.13)
		38 (100)	36 (100)		
	Pericoronitis	16 (42.1)	23 (63.9)	39 (52.7)	
	Caries	21 (55.3)	13 (36.1)	34 (45.9)	
	Periodontitis	1 (2.6)	0 (0)	1 (1.4)	
	38 (100)	36 (100)			

Table 2: Comparison of the mean postoperative pain VAS (cm) in the complete closure and sutureless groups

	Complete closure Mean (SD)	Sutureless Mean (SD)	P Value
1POD	3.26 (2.66)	6.03 (2.98)	0.001
2POD	3.27 (2.17)	4.42 (2.83)	0.094
3POD	2.49 (1.95)	3.79 (2.79)	0.044
4POD	1.58 (1.54)	2.59 (2.16)	0.044
5POD	1.48 (1.68)	2.56 (2.29)	0.032
6POD	1.35 (1.62)	1.55 (2.14)	0.64
7POD	0.56 (0.77)	1.08 (1.91)	0.18
Total pain	14.39(8.60)	22.06 (11.93)	0.004

**Figure 3: Graphic representation of the pain severity in the complete closure and sutureless groups**

width measurement values were seen on POD 1. Although the complete closure group had greater facial swelling on PODs 1, 3 and 7 [Figure 4], this difference was not statistically significant [Table 3].

Trismus:

The mean preoperative inter-incisal distance was 44.5 mm and the participants in both groups had significant limitations in mouth opening on all review days. However, the sutureless group had less trismus than the complete closure group on days 1, 3 and 7 [Figure 5], and this was significant only on day 7 [Table 4].

Discussion

In this clinical study, the effect of the complete closure and sutureless technique on post-operative pain, swelling and trismus was compared.

Despite the use of analgesics in its management, postoperative pain is still a common complaint from patients following M3 extraction. Severe postoperative pain could reduce patient quality of life and patient satisfaction, loss of confidence in the practitioner, dental phobia and decreased dental service utilisation. Pain is a subjective feeling, the true severity of which can only be best expressed by the patient.^[17] In this study, the highest pain intensity score was recorded in the first 48 h for both groups. This agrees with previous studies that have reported peak pain severity following M3 surgery to range from the first 6h^[18] to 48 h post-operation^[19] and then gradually decreased in both groups during the course of the immediate postoperative period. This highlights the need for better pain management in M3 surgery. Considering the subjectivity of pain perception, it is clear that a fixed regimen of analgesic for all patients is at best a guide and is insufficient for optimal pain management in the 48 h following M3 surgery. Rather, analgesic regimens

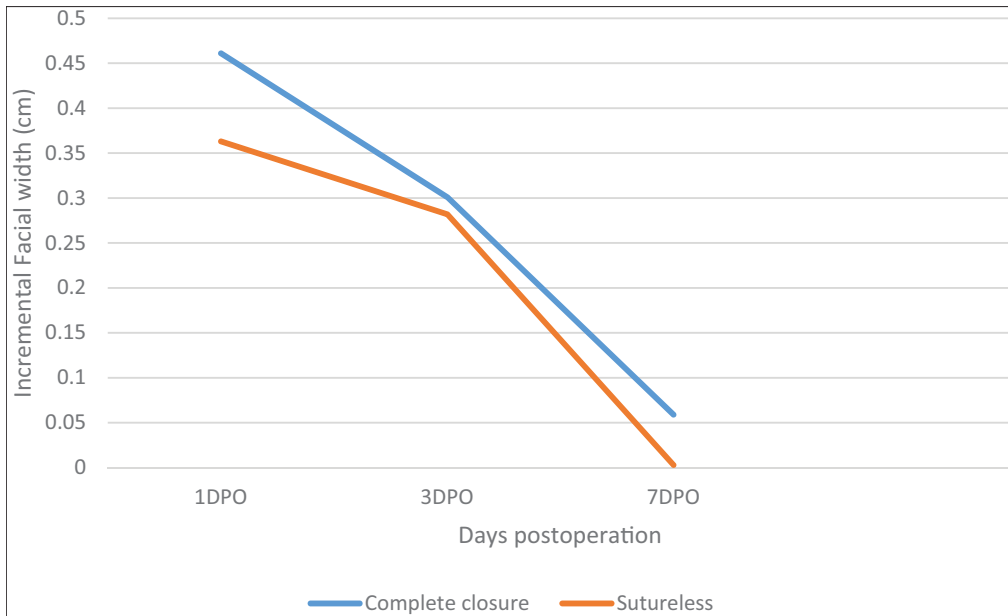


Figure 4: Comparison of facial swelling using facial width measurement in the complete closure and sutureless groups

Table 3: Comparison of mean facial width measurement and swelling (in cm) in the complete closure and sutureless groups

		Complete closure Mean (SD)	Sutureless Mean (SD)	P Value
Preoperative	Facial measurement	12.63(0.96)	11.34(0.75)	0.135
POD 1	Facial measurement	13.26(0.87)	11.8(0.72)	0.268
	Difference (swelling)	0.46(0.32)	0.36(0.35)	
POD 3	Facial measurement	13.01(0.86)	11.63(0.69)	0.812
	Difference (swelling)	0.30(0.28)	0.28(0.34)	
POD 7	Facial measurement	12.69(0.85)	11.35(0.76)	0.423
	Difference (swelling)	0.06(0.17)	0.003(0.39)	
Total swelling		0.817(0.65)	0.528(0.98)	0.194

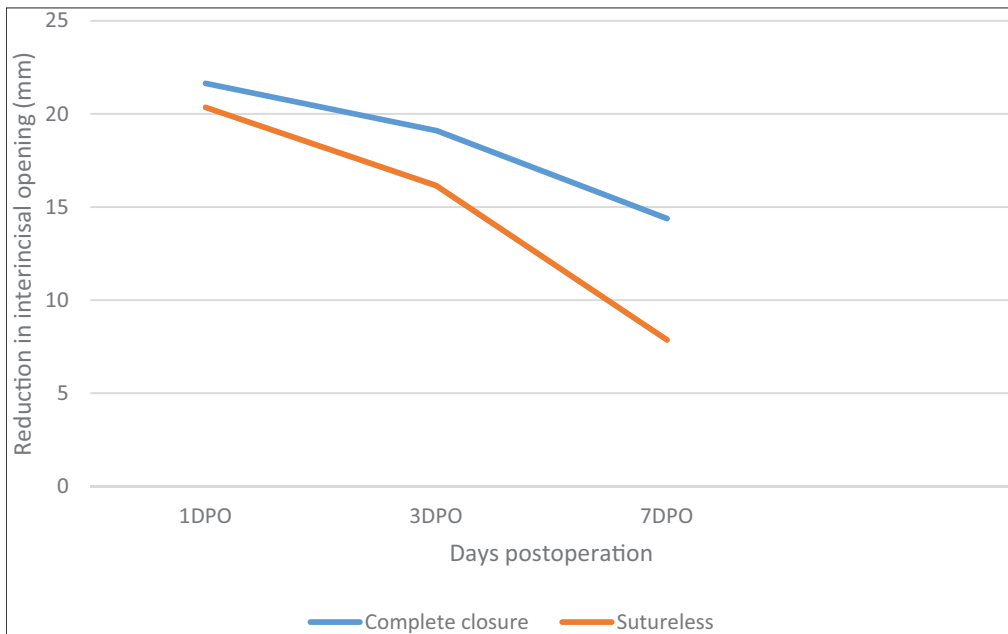


Figure 5: Severity of trismus in the complete closure and sutureless group

Table 4: Comparing trismus in the complete closure and sutureless groups

		Complete closure Mean (SD)	Sutureless Mean (SD)	P Value
Preoperative		43.99(8.12)	45.02(6.09)	0.538
POD 1	IIO (mm)	22.23(8.68)	24.52(10.4)	0.640
	Difference (trismus)	21.64(9.76)	20.35(11.2)	
POD 3	IIO (mm)	24.80(8.54)	28.56(19.8)	0.250
	Difference (trismus)	19.10(9.55)	16.15(10.8)	
POD 7	IIO (mm)	30.11(10.7)	36.66(9.33)	0.007
	Difference (trismus)	14.36(9.41)	7.86(9.03)	
Total Trismus		55.64(27.17)	41.78(27.67)	0.065

IIO = inter-incisal opening

should be individually titrated to the patient's reported pain and desire for additional medication, especially in the 48 h following surgery.

Findings in this study showed that the sutureless group recorded significantly more postoperative pain than the complete closure group. The higher pain scores in the sutureless group could be as a result of exposure of subepithelial tissues to the oral environment which triggers the production of inflammatory cytokines and pain mediators. Also, this finding may result from activation of peripheral pain receptors and their A delta and C nociceptor fibres. However in the complete closure group, the oral mucosa functions as a socket wound barrier to the constant irritation of the oral environment. Therefore, there would be less activation of nociceptors and less production of inflammatory pain mediators and consequently lesser pain than in the sutureless technique group. Alkadi *et al.*^[20] suggested this finding could be due to delayed wound healing and a longer period of discomfort and continuous pain in the sutureless group when he compared it to the partial closure. However, the findings of this study differ from that of Mahat *et al.*^[21] who reported no significant difference in mean pain for primary closure and sutureless groups, some other studies have reported less pain in the sutureless group.^[13-15,22,23] Osunde^[13] and Kazemian^[23] found less pain in the sutureless group and suggested that postoperative pain arises from the pressure effect of the 'locked in' inflammatory exudate from complete closure, and therefore, creating a window for exit of exudate would cause less postoperative pain. The reason for the nonconcordant results is unclear but these authors suggest that swelling caused by build-up of tissue fluid and compression of nerve endings which continuously sends signals to the brain is perceived as pain. The extent to which this happens following M3 surgery is unknown as there has been no reported correlation between postoperative swelling with pain. It is therefore unlikely that mild to moderate swelling following M3 surgery would be associated with increased postoperative pain. Factors such as oral hygiene, socioeconomic factors and compliance with instructions may contribute to this conflicting result. These factors could affect the extent of contamination and inflammatory

response when the sutureless wound is exposed to the oral environment.

Facial swelling following M3 surgery is a common cause of discomfort, moreso to the uninformed patient, and contributes to a diminished well-being in the early recovery period. Highest facial measurements were seen in POD1 in both groups. This diverges from a report by previous studies that reported peak swellings on day 2^[13,24] and day 3.^[25] This variation in result may be due to the different assessment days in the several studies, and also due to variation in individual inflammatory responses.^[13]

The current work showed that the sutureless group showed less swelling than the complete closure group although this difference was not significant statistically. This result mirrors the finding by Mahat *et al.*^[21] and could be because both techniques investigated could, though to a widely different extent, have an exit path for the inflammatory exudates to escape, which results in reduced post-operative facial swelling. Even with complete closure, the gingival crevices could still serve as a window slit in the early inflammatory period. The mechanism of formation of postoperative swelling following M3 surgery is thought to be because the associated tissue injury is characterised by hyperaemia, vasodilatation, increased capillary permeability with liquid accumulation in the interstitial space, due to the increased osmotic pressure in capillaries.^[4] This postoperative swelling and oedema is therefore an expression of exudates or transudation, and in M3 surgery, probably both events could occur. Transudation is secondary to blood flow slowing due to hyperaemia and vasodilatation, whereas a superimposed infection when present is responsible for exudates.^[26] The accumulated fluid gradually exits the site via the open wound in the sutureless technique, or more slowly in the complete closure technique through the gingival crevice before complete reattachment is achieved. The duration for the reattachment of the gingiva to the tooth surface has been reported to be 14 days,^[27] which is sufficient to ensure slow escape of fluid along the tooth-gingiva interface. This implies that suturing techniques do not considerably affect the severity of postoperative swelling as earlier suggested by some other authors. Authors who favoured complete

closure over the sutureless technique^[13-15,22,23,28] explained that the complete closure creates a unidirectional valve that allows oral fluid and fragments of food to reach the socket, but not to leave it easily thereby causing increased swelling.

Limitation of mouth opening following M3 surgery is a result of the local tissue and masticatory muscle inflammation and the resulting postoperative pain and swelling.^[29] In this study, the severity of trismus was higher in the complete closure group than the sutureless group on all the PODs reviewed and this is in accordance with previous reports by Osunde *et al.*^[13] and that of Ricard *et al.*^[15] The difference in the trismus between the groups was less remarkable on the first day, but progressively increased with increasing number of days, and is statistically significant on the seventh day. This indicates that the mouth opening of the patients in the sutureless group improved earlier, nearing the preoperative value, than that in the patients with complete closure. It could also allude to a faster recovery and return to function in the sutureless group. This finding therefore implies that suture techniques affect the severity of postoperative trismus, which has been thought to be a direct and immediate consequence of the inflammatory response associated with the surgical procedure. Going by this notion, a more severe trismus would be expected in the complete closure technique because of the likelihood of greater swelling as earlier reported in this study. Although to a lesser extent, the severity of trismus may also be influenced by the physical restriction of tissues in the retromolar area. In the complete closure, the oral mucosa lingual and buccal to the M3 which were formerly apart by the transverse width of the tooth, are now pulled into contact by suturing. This 'pulling effect' of surrounding mucosa may cause a perception of tightness in the wound site and could physically restrict movement in the area during the early healing period and therefore contribute to the more severe trismus in the complete closure technique. The result of this study however differs from that by Mahat *et al.*^[21] who did not find any significant difference in the trismus between the sutureless and multiple suture technique following M3 surgery.

Ultimately, this study shows similar severity of postoperative inflammatory symptoms using these two widely different suturing techniques following M3 surgery. Practitioners should therefore base their choice of technique on other factors such as preference, costs and convenience to the patient. But considering the subjective nature of self-reported parameters such as pain, findings from this study may be influenced by multiple sociodemographic and emotional factors. Therefore, a multicentre study with a more diverse population is recommended.

Conclusion

These findings question the acclaimed superiority of the increasingly popular sutureless technique over primary

closure. The sutureless technique had less facial swelling compared with suture, but this was not statistically significant. Although the sutureless technique was associated with faster resolution of trismus, it showed higher pain severity than the primary closure.

Declaration of patient consent

The authors certify that they have obtained all appropriate patient consent forms. In the form the patient(s) has/have given his/her/their consent for his/her/their images and other clinical information to be reported in the journal. The patients understand that their names and initials will not be published and due efforts will be made to conceal their identity, but anonymity cannot be guaranteed.

Financial support and sponsorship

Not applicable.

Conflicts of interest

There are no conflicts of interest.

References

1. Santosh P. Impacted mandibular third molars: Review of literature and a proposal of a combined clinical and radiological classification. *Ann Med Health Sci Res* 2015;5:229-34.
2. Hossaini M. Surgical treatment of impacted teeth other than third molars. In: Anderson L, editor. *Oral and Maxillofacial Surgery*. 1st ed. Singapore: Wiley-Blackwell; 2010. p. 259-66.
3. Leif L. Current concepts and strategies for third molar impaction. In: Anderson L, Kahnberg K-E, Pogrel MA, editors. *Oral and Maxillofacial Surgery*. John Wiley & Sons; 2012. p. 195-218.
4. Sortino F, Cicciù M. Strategies used to inhibit postoperative swelling following removal of impacted lower third molar. *Dent Res J (Isfahan)* 2011;8:162-71.
5. Ibikunle AA, Adeyemo WL, Ladeinde AL. Oral health-related quality of life following third molar surgery with either oral administration or submucosal injection of prednisolone. *Oral Maxillofac Surg* 2016;20:343-52.
6. Ibikunle AA, Adeyemo WL. Oral health-related quality of life following third molar surgery with or without application of ice pack therapy. *Oral Maxillofac Surg* 2016;20:239-47.
7. Hu T, Zhang J, Ma JZ, Shao LN, Gu YF, Li DQ, *et al.* A novel method in the removal of impacted mandibular third molar: Buccal drainage. *Sci Rep* 2017;7:12602.
8. Chukwunke FN, Oji C, Saheeb DB. A comparative study of the effect of using a rubber drain on postoperative discomfort following lower third molar surgery. *Int J Oral Maxillofac Surg* 2008;37:341-4.
9. Sekhar CH, Narayanan V, Baig MF. Role of antimicrobials in third molar surgery: Prospective, double blind, randomized, placebo-controlled clinical study. *Br J Oral Maxillofac Surg* 2001;39:134-7.
10. Seymour RA, Meechan JG, Blair GS. An investigation into post-operative pain after third molar surgery under local analgesia. *Br J Oral Maxillofac Surg* 1985;23:410-8.
11. Sortino F, Messina G, Pulvirenti G. [Evaluation of postoperative mucosa and skin temperature after surgery for impacted third molar]. *Minerva Stomatol* 2003;52:393-9.

12. Markovoric A, todovoric LJ. Effectiveness of dexamethasone and low power laser in minimising oedema after third molar surgery: A clinical trial. *Int J Oral Maxillofac Surg* 2007;36:226-9.
13. Osunde OD, Adebola RA, Saheeb BD. A comparative study of the effect of suture-less and multiple suture techniques on inflammatory complications following third molar surgery. *Int J Oral Maxillofac Surg* 2012;41:1275-9.
14. Hashemi HM, Beshkar M, Aghajani R. The effect of sutureless wound closure on postoperative pain and swelling after impacted mandibular third molar surgery. *Br J Oral Maxillofac Surg* 2012;50:256-8.
15. Ricard AS, Nau O, Veyret A, Majoufre-Lefèbvre C, Laurentjoye M. [Comparison between closure and absence of closure after removal of fully impacted mandibular third molar: A prospective randomized study]. *Rev Stomatol Chir Maxillofac Chir Orale* 2015;116:12-7.
16. Osunde OD, Saheeb BD, Adebola RA. Comparative study of effect of single and multiple suture techniques on inflammatory complications after third molar surgery. *J Oral Maxillofac Surg* 2011;69:971-6.
17. Treede RD. The international association for the study of pain definition of pain: As valid in 2018 as in 1979, but in need of regularly updated footnotes. *Pain Rep* 2018;3:e643.
18. Ong CK, Seymour RA. Pathogenesis of postoperative oral surgical pain. *Anesth Prog* 2003;50:5-17.
19. Osunde OD, Adebola RA, Omeje UK. Management of inflammatory complications in third molar surgery: A review of the literature. *Afr Health Sci* 2011;11:530-7.
20. Alkadi S, Stassen L. Effect of one-suture and sutureless techniques on postoperative healing after third molar surgery. *J Oral Maxillofac Surg* 2019;77:703.e1-16.
21. Mahat AK, Yadav R, Yadav AK, Acharya P, Dongol A, Sagtani A, *et al.* A comparative study of the effect of sutureless versus multiple sutures technique on complications following third molar surgery in Nepalese subpopulation. *Int J Dent* 2020;2020:9314762.
22. Quadri A, Quadri S, Khan T. Comparative study of post-operative complications in third molar surgery with and without sutures: A prospective study. *Int J Sci Stud* 2016;4:168-71.
23. Kazemian M, Eshghpour M, Ilkhani S, Ghadirimoghaddam N. The effect of sutureless surgery on postoperative pain and swelling following mandibular third molar surgery. *JDMT* 2016;5:63-7.
24. Akinwande JA. Mandibular third molar impaction: A comparison of two methods for predicting surgical difficulty. *Niger Dent J* 1991;10:3-7.
25. Anighoro E, Gbotolorun O, Adewole R, Arotiba G, Effiom O. Assessment of the effect of wound closure technique on postoperative sequelae and complications after impacted mandibular third molar extraction. *Open J Stomatol* 2013;3:527-32.
26. Berne RM. Cardiovascular physiology. *Annu Rev Physiol* 1981;43:357-8.
27. Prabhu P, Julius A, Elumalai M, Prabhu M. Wound healing in periodontics. *Biosci Biotechnol Res Asia* 2014;11:791-6.
28. Damodar ND, Nandakumar H, Srinath NM. Postoperative recovery after mandibular third molar surgery: A criteria for selection of type of surgical site closure. *Gen Dent* 2013;61:e9-e13.
29. Chukwunke F, Saheeb B. Evaluation of postoperative facial swelling following the surgical removal of impacted third molars using the tape measuring technique. *Ebonyi Medical Journal* 2010;9:90-5.