

CASE REPORT

Successful treatment of thymic carcinoma with dermatomyositis and interstitial pneumonia: A case report

Xingguo Yang¹ , Lei Yu¹, Fei Li¹, Tao Yu¹, Yunfeng Zhang¹ & Honggang Liu²

1 Department of Thoracic Surgery, Beijing Tongren Hospital, Capital Medical University, Beijing, China

2 Department of Pathology, Beijing Tongren Hospital, Capital Medical University, Beijing, China

Keywords

Dermatomyositis; interstitial pneumonia; thymic carcinoma.

Correspondence

Lei Yu, Department of Thoracic Surgery, Beijing Tongren Hospital, Capital Medical University, No. 1 Dongjiaomin Lane, Dongcheng District, Beijing 100010, China.
Tel: +86 185 1562 6402
Fax: +86 10 5826 8509
Email: yulei118@163.com

Received: 16 June 2019;

Accepted: 29 July 2019.

doi: 10.1111/1759-7714.13168

Thoracic Cancer **10** (2019) 2031–2034

Abstract

Here, we report a rare case of thymic carcinoma (TC) associated with dermatomyositis (DM) and interstitial pneumonia (IP) in a 68-year-old man. The patient presented with the characteristic features of a skin rash with Gottron's papules and increased serum levels of muscle-associated enzymes. Computed tomography (CT) showed the presence of an anterior mediastinal soft tissue mass with IP, which was diagnosed as TC by CT-guided tumor biopsy. The patients DM and IP disappeared completely after radical resection of the tumor. After a 20-month follow-up period, the patient was in good clinical condition without disease recidivism.

Introduction

Dermatomyositis (DM) is an uncommon inflammatory myopathy characterized by pain and weakness in the proximal muscles with characteristic cutaneous eruptions. DM is associated with an increased risk of developing cancer. The reported incidence of malignant tumors varies widely in the published literature from less than 7% to over 30%.^{1,2} A major complication of DM is interstitial pneumonia (IP), which affects the prognosis of patients with DM. However, there are relatively few cases of patients who have malignant tumors combined with DM and IP.^{3,4} Thymic carcinoma (TC) is very rare, accounting for <20% of thymic neoplasm.⁵ Here, we report an extremely rare case of DM with IP that improved dramatically after surgical resection of thymic carcinoma.

Case report

A 68-year-old man was admitted to the thoracic department in our hospital at the beginning of November 2017, complaining of weakness, shortness of breath and weight

loss. The patient had received a diagnosis of a large mediastinal mass at another hospital five days earlier; a chest radiograph had been obtained to evaluate chest discomfort. Subsequent computed tomography (CT) scans showed an anterior mediastinal soft-tissue mass that measured 7.4 cm craniocaudally, 9.0 cm transversely, and 3.7 cm anteroposteriorly, as well as IP (Fig 1). Histopathologic analysis of a CT-guided percutaneous core biopsy specimen was compatible with a diagnosis of TC.

As the patient had been diagnosed with IP, we consulted with a rheumatologist. On physical examination by the rheumatologist, Gottron's papules and erythema in the joints of his extremities were noted. Neurological evaluation confirmed grade 4/5 muscle weakness involving both shoulders and extremities. The blood chemistry results were as follows: creatinine kinase (CK), 3 808 iu/L; lactate dehydrogenase (LDH), 691 iu/L; aspartate aminotransferase (AST), 127 iu/L; alanine aminotransferase (ALT), 103 iu/L; and erythrocyte sedimentation rate (ESR), 39 mm/hour (0–15). Tumor markers were normal except for slightly elevated carbohydrate antigen 125 (CA125)

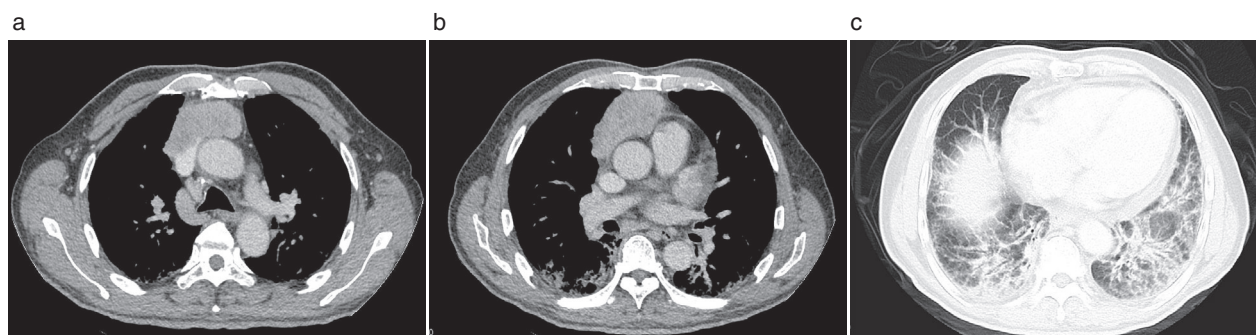


Figure 1 Computed tomography of the chest showing an anterior mediastinal tumor measuring 7.4 × 9 × 3.7 cm, as well as interstitial pneumonia (IP).

levels. The results of his serum anti-Jo-1 antibody test were positive.

Due to his active IP, cutaneous erythema and abnormal laboratory indexes, we organized a multidisciplinary discussion. We concluded that DM, IP, and TC co-occurred in this patient. The possibility of paraneoplastic myopathy was raised, which prompted us to remove the tumor. Following a careful clinical assessment, a radical resection was proposed.

A median sternotomy was performed and it was found that the tumor infiltrated the pericardium on the anterior and right lateral sides over the superior vena cava extending to the left brachiocephalic vein. Thus, we performed extended thymectomy. The superior vena cava was reconstructed with polytetrafluoroethylene grafts from the right auricle to both the left and the right brachiocephalic veins in an end-to-side fashion. The tumor was excised en bloc with all of the thymus gland, infiltrated great veins,

mediastinal fat, and anterior and right lateral portions of the pericardium with the right phrenic nerve, which were all involved in the mass. The surgical specimen was sent for pathological evaluation. (Fig 2) The histological results confirmed the diagnosis of TC staged as Masaoka stage IIIb.

During the postoperative period, prolonged mechanical ventilatory support was required because of right diaphragm elevation and IP. After surgery, without any administration of steroids, the skin rash and muscle weakness improved significantly, and serum CK levels decreased to 435 iu/L on the fourth day postoperatively and were within the normal range at 282 iu/L on the twelfth day. Spontaneous breathing was achieved 14 days postoperatively. To our surprise, the patient's IP improved dramatically after the operation (Fig 3). After surgery, the patient declined chemotherapy or radiotherapy for personal reasons. After a 20-month follow-up period, the patient was alive and free of disease.

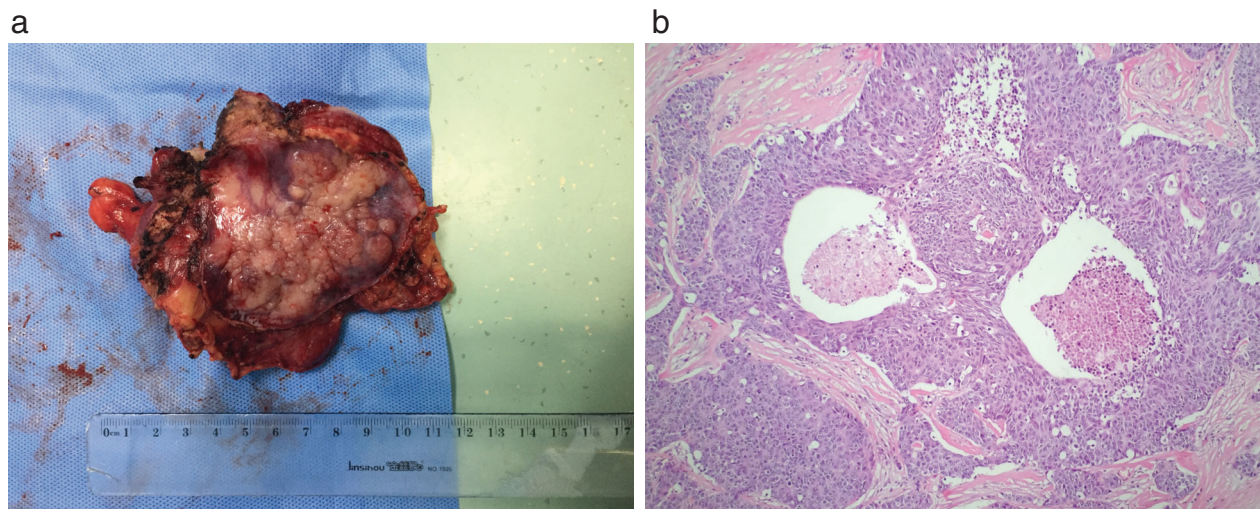


Figure 2 (a) Surgical specimen, showing the tumor was filled with soft grey-white fleshy tissue and encapsulated without an obvious membrane. (b) Histopathology of the tumor, showing tumor cells appeared as squamous cell carcinoma in nest-like arrangement with marked cytological atypia and cell necrosis (hematoxylin and eosin, ×100).

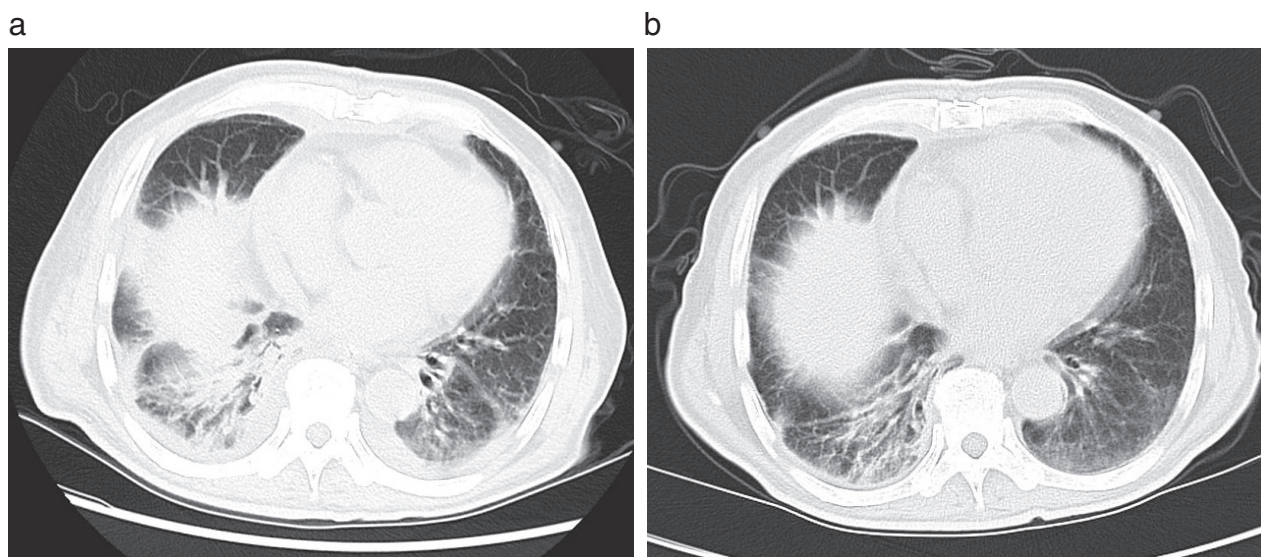


Figure 3 Computed tomography (CT) images of interstitial pneumonia showing (a) Improvement postoperatively after two weeks, and (b) dramatic improvement postoperatively after three weeks.

Discussion

DM is strongly associated with a wide range of cancers,⁶ the most common being ovarian, lung, pancreatic, stomach, and colorectal cancers, but DM is weakly associated with TC. Paraneoplastic syndrome is rarely associated with TC, but frequently with thymoma, such as myasthenia gravis.⁷ In our case, the clinical condition of the patient improved dramatically after complete resection of TC, which suggested that DM and IP were paraneoplastic syndromes. To our knowledge, this is the first case of combined DM, IP, and TC.

DM often coexists with IP or malignant tumors, but malignant tumors are unlikely to occur in cases of DM with IP. If DM coexists with IP, the Jo-1 antibody can be used as a specific antibody. Taggart *et al.* showed that Jo-1 antibody was highly expressed in association with interstitial lung disease (ILD), with a positive rate of 50–75%.⁸ The Jo-1 antibody, which is an anti-aminoacyl-tRNA synthetase (anti-ARS) antibody, is strongly related to ILD and is a clinical feature of DM that is unlikely to coexist with malignant tumors.³ Studies have reported that the response of ILD to corticosteroids was significantly better in anti-ARS antibody-positive patients than in anti-ARS antibody-negative patients.^{9,10} Some published observational studies have discussed predictive factors for the occurrence of malignancies in patients with DM and suggested that Raynaud's phenomenon, fever, ILD, and Jo-1 antibody positivity are inversely correlated with the presence of cancer.¹¹

A combination of three diseases is thought to be very rare.^{3,4} When present, IP is often the cause of death. Thus,

it might be better to prioritize the treatment of IP if its activity is assessed to be high. For past cases, the treatment of tumors did not favorably control IP, even though patients may have had paraneoplastic syndromes. In our case, if IP had been treated first, the timing of surgery would have been delayed, and the patient may have lost the opportunity to undergo radical surgery due to the continued delay. The patient's IP and DM improved after surgery, which suggested that IP and DM were paraneoplastic syndromes in the presented case.

Disclosure

No authors report any conflict of interest.

References

- 1 Madam V, Chinoy H, Griffiths CE, Cooper RG. Defining cancer risk in dermatomyositis. Part 1. *Clin Exp Dermatol* 2009; **34**: 451–5.
- 2 Buchbinder R, Hill CL. Malignancy in patients with inflammatory myopathy. *Curr Rheumatol Rep* 2002; **4**: 415–26.
- 3 Fujita Y, Hirano S, Yoneshim Y *et al.* A case of acute exacerbation of interstitial pneumonia complicated with dermatomyositis during treatment for lung cancer, and literature review. *Nihon Kokyuki Gakkai Zasshi* 2011; **49**: 108–15.
- 4 Daido W, Yamasaki M, Morio Y *et al.* A rare combination of dermatomyositis, interstitial pneumonia, and lung cancer in a patient treated with immunosuppressive therapy and chemotherapy. *Intern Med* 2018; **57**: 849–53.

- 5 Litvak AM, Woo K, Hayes S *et al.* Clinical characteristics and outcomes for patients with thymic carcinoma: Evaluation of Masaoka staging. *J Thorac Oncol* 2014; **9**: 1810–5.
- 6 Hill CL, Zhang Y, Sigurgeirsson B *et al.* Frequency of specific cancer types in dermatomyositis and polymyositis: A population-based study. *Lancet* 2001; **357**: 96–100.
- 7 Liu HC, Hsu WH, Chen YJ *et al.* Primary thymic carcinoma. *Ann Thorac Surg* 2002; **73**: 1076–81.
- 8 Taggart AJ, Finch MB, Courtney PA, Gormley GJ. Anti Jo-1 myositis. ‘Mechanic’s hands’ and interstitial lung disease. *Ulster Med J* 2002; **71**: 68–71.
- 9 Nakashima R, Imura Y, Hosono Y *et al.* The multicenter study of a new assay for simultaneous detection of multiple anti-aminoacyl-tRNA synthetases in myositis and interstitial pneumonia. *PLoS One* 2014; **9**: e85062.
- 10 Yoshifuji H, Fujii T, Kobayashi S *et al.* Anti-aminoacyl-tRNA synthetase antibodies in clinical course prediction of interstitial lung disease complicated with idiopathic inflammatory myopathies. *Autoimmunity* 2006; **39**: 233–41.
- 11 Di Rollo D, Abeni D, Tracanna M, Capo A, Amerio P. Cancer risk in dermatomyositis: A systematic review of the literature. *G Ital Dermatol Venereol* 2014; **149**: 525–37.