



# AL amyloidosis: advances in diagnosis and management

Youngil Koh

Department of Internal Medicine, Seoul National University Hospital, Seoul, Korea

p-ISSN 2287-979X / e-ISSN 2288-0011  
<https://doi.org/10.5045/br.2020.S009>  
**Blood Res 2020;55:S54-S57.**

Received on January 6, 2020  
Revised on January 19, 2020  
Accepted on January 31, 2020

## Correspondence to

Youngil Koh, M.D., Ph.D.  
Department of Internal Medicine, Seoul  
National University Hospital, 101  
Daehak-ro, Jongno-gu, Seoul 03080, Korea  
E-mail: go01@snu.ac.kr

© 2020 Korean Society of Hematology

## Abstract

Light chain (AL) amyloidosis is a disease in which malignant plasma cell clones affect multiple organs including the heart and kidney. The mechanism for organ function deterioration in AL amyloidosis differs from multiple myeloma. Thus, not all agents used to treat multiple myeloma shows similar efficacy in AL amyloidosis. In AL amyloidosis, both hematologic and organ responses after treatment are important to improve the clinical outcome. Especially, improving heart function is one of the key aspects in the treatment of AL amyloidosis. With recent advances in the understanding of the pathophysiologic mechanism of AL amyloidosis, novel treatment methods are under active trial. In this article, I have reviewed the advances in pathophysiology, diagnosis, risk stratification, and treatment of AL amyloidosis.

**Key Words** AL amyloidosis, SAP, Pathophysiology, Treatment

## INTRODUCTION

Despite improvements in the outcome of multiple myeloma with novel agents, the outcome of advanced Light chain (AL) amyloidosis has not improved significantly. Especially, the outcome of patients with advanced cardiac involvement is dismal. However, the understanding of the pathophysiology of AL amyloidosis has progressed. Moreover, there are active trials investigating new therapeutic options to improve the outcome of AL amyloidosis. Here, I reviewed the advances in both the pathophysiology and treatment of AL amyloidosis.

## EPIDEMIOLOGY AND CLINICAL CHARACTERISTICS

Epidemiology of AL amyloidosis varies across reports, but it is within 8–15% annual incidence per million [1, 2]. The prevalence of the disease increases with an increase in age. Mean age at diagnosis is mid 60's, and there is a predilection for men (55% vs. 45%). In addition, genetic factors contribute to the development of AL amyloidosis and polymorphism in the splice site of CCND1 (rs9344) and SMARCD3 (rs79419269) is strongly related to AL amyloidosis [3]. Malignant B cell clone produces an immunoglobulin light chain  $\lambda$  in 75–80% of cases and  $\kappa$  light chains in the remaining cases [4].

## PATHOPHYSIOLOGY

### Formation of amyloid fibrils

The key process in amyloidosis is the conversion of soluble proteins into insoluble amyloid fibrils that deposit in organs. Protein aggregation is countered by protein homeostasis (proteostasis) that maintains the proteome, and disruption of this balance by any reason contributes to amyloidosis [5]. Overall, ~1,600 different proteins play a role in proteostasis, the efficiency of which declines with age. If adequate proteostasis fails, protein aggregation might occur. Somatic mutations in IGLV are frequently found in AL amyloidosis, and they reduce the fold stability of the native protein and moreover, they increase protein dynamics and production of variable light chain domains that favors endoproteolysis and amyloidosis, respectively [6].

Once formed, oligomers of light chains form highly organized amyloid fibrils. The pentraxin serum amyloid P component (SAP) is a circulating plasma protein that is universally present in amyloid deposits owing to its calcium-dependent binding to amyloid fibrils [7]. SAP has been reported to protect amyloid fibrils from degradation. The accumulation of amyloid deposits in parenchymal tissue leads to tissue damage, which causes dysfunction in vital organs. In addition, amyloid fibrils cause cytotoxicity and promote the misfolding of light chains and further oligomer formation

(Fig. 1) [8].

**Mechanism of cardiac dysfunction**

Cardiac dysfunction can result from proteotoxicity of the light chains and amyloid deposits that cause widespread disruption of tissue architecture. Other mechanisms include perturbation of cell membrane by amyloid fibrils, cell toxicity from fibril growth, and the formation of soluble light chain oligomers by amyloid fibrils. Moreover, soluble amyloid light chains, unlike fibrils, induce apoptosis. In addition, it is known that amyloidogenic light chains can induce MAPK signaling, resulting in increased production of reactive oxygen species (ROS), impaired calcium homeostasis, cell dysfunction, and eventually cell death in isolated adult cardiomyocytes [9].

**DIAGNOSIS**

**Diagnostic principles**

The diagnostic criteria for AL amyloidosis include the presence of a systemic syndrome, histological documentation of amyloid, evidence of a monoclonal plasma cell disorder, and protein typing that supports the diagnosis. Among systemic syndromes, cardiac involvement is common (60–75%) and of utmost importance in determining the prognosis [10].

**Confirming cardiac involvement**

Traditionally, a biopsy of bone marrow or abdominal fat

is performed to confirm organ involvement. However, it is important to demonstrate clinically meaningful organ involvement such as heart or kidney to decide the treatment. Because the heart is the most commonly affected organ (>60%) and decides the fate of patients, determining heart involvement is the most critical part of the diagnosis. Recent advances in imaging techniques have contributed to the logical diagnostic procedure of determining heart involvement.

The most useful and commonly used method is cardiac magnetic resonance imaging (MRI). Cardiac MRI has high sensitivity (80–100%) and specificity (80–94%) [11, 12]. The finding of late gadolinium enhancement is highly suggestive of the diagnosis of amyloidosis. Along with MRI, scintigraphy with Tc-99m-pyrophosphate (99mTc-PYP) helps to differentiate ATTR (amyloid transthyretin) from AL amyloidosis. PYP scan is positive in almost all cases of ATTR amyloidosis, but it can be positive in some (40%) AL cases. Considering both the presence of monoclonal gammopathy and PYP scan results may help differentially diagnosing amyloidosis involving the heart [13].

However, the gold standard to confirm cardiac involvement is an endomyocardial biopsy, and this should be performed if the results from biochemical and radiological examinations are conflicting. Once a biopsy specimen is obtained, the typing of amyloid is an essential part of the diagnosis. Since MGUS is often present in the aged population, the existence of monoclonal proteins in the serum, urine, or clonal bone marrow plasma cells are not diagnostic for AL type and thus, might be misleading. Hence, the typing

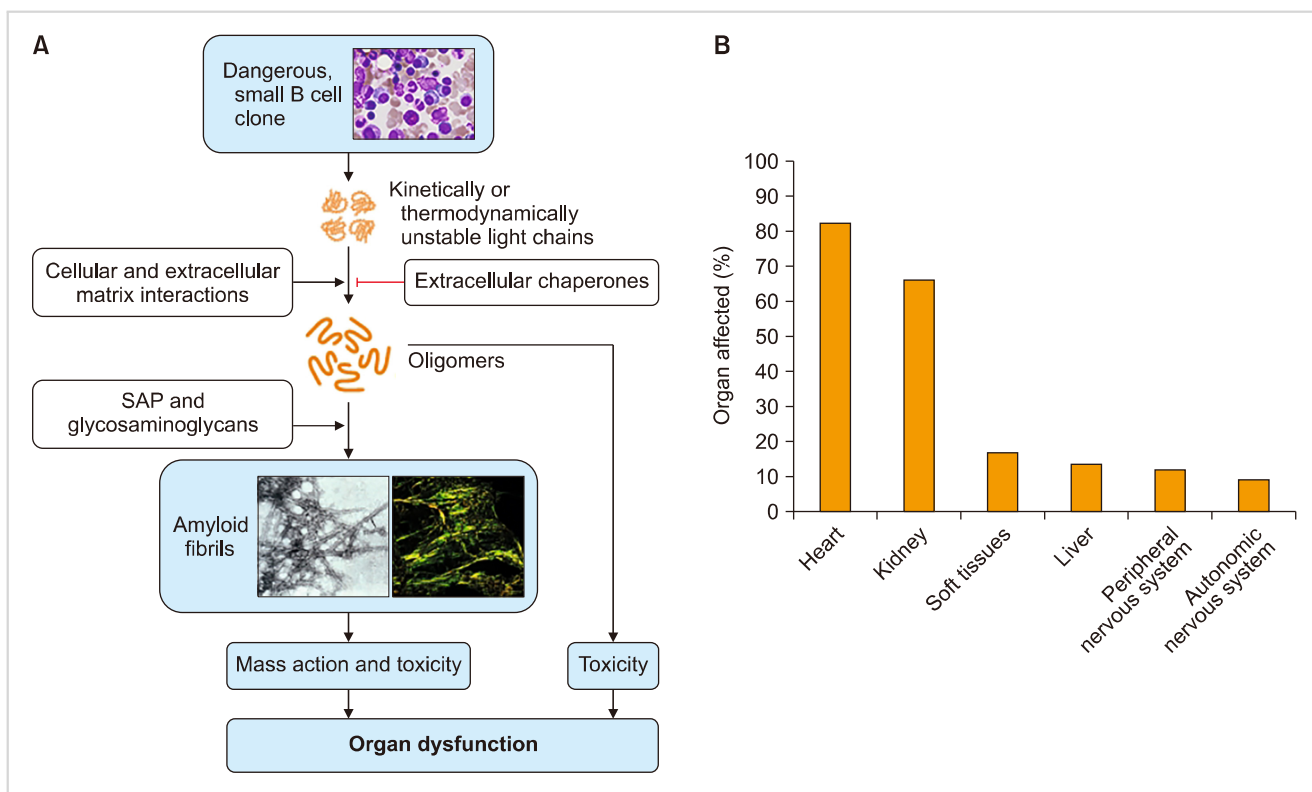


Fig. 1. Pathophysiologic mechanism of AL amyloidosis (Merlini et al. 2018).

of amyloidosis with biopsy specimens is highly recommended. There are three methods of amyloid typing: immunohistochemistry (IHC), immunoelectron microscopy (IEM), and mass spectrometry [14]. IHC is the most commonly used technique in the clinic for determining heart involvement, but IEM examination is highly recommended for an accurate diagnosis. Mass spectrometry is the most sensitive and specific method for diagnosis [15], but there is a gap between the bench and clinic in Korea.

### Staging system

The Mayo clinic proposed two prognostic models in 2004 and 2012, respectively. Additionally, there is a European model, which is a modification of the Mayo 2004 model (Table 1) [16-19]. The European model and the Mayo 2012 model showed the best predictive performance in recent validation studies [12].

## TREATMENT

The ultimate treatment goal of AL amyloidosis is the functional recovery of the involved organ. Considering the pathophysiology of AL amyloidosis, eradication of the malignant B cells is a precondition for organ function recovery. However, not all B cell eradicating strategies correlate with organ function recovery. Hence, the treatment strategies are divided into two functional categories as discussed below.

### Targeting malignant plasma cells

For patients who are eligible for autologous stem cell transplantation (ASCT), upfront ASCT is deemed to be the standard of care. Eligibility criteria for ASCT include good performance status; preserved cardiac function (cardiac biomarkers below the thresholds), pulmonary function, and

hepatic function; and hemodynamic stability (systolic pressure >90 mmHg).

In patients who are not eligible for upfront ASCT, regimens using bortezomib are now considered the standard of care in most cases. Studies have reported that response rates were higher with bortezomib-based regimens than with previous standards of care. The addition of daratumumab to bortezomib-based treatment has been evaluated and but the results have not been published (NCT03201965).

However, high-risk patients represent ~20% of AL amyloidosis. Due to advanced cardiac dysfunction or severe heart failure, no treatment regimen can substantially alter the course of the disease in these patients, and they have a very short median survival (around 6 mo). In these patients, removal of the amyloid deposit is necessary to improve the prognosis.

It is noteworthy that a high frequency (40–60%) of chromosome t(11;14) characterizes amyloid B cell clone. A recent trial using venetoclax showed good response in t(11;14) translocated multiple myeloma population [20] suggesting that venetoclax may play a role in the treatment of AL amyloidosis in the future.

### Targeting amyloid formation

Monoclonal antibodies that target existing amyloid deposits including SAP have been developed. SAP has been reported to protect amyloid fibrils from degradation. Therefore, SAP is an excellent candidate for amyloid scintigraphy and a target for amyloid-directed immunotherapy.

NEOD001 targets amyloid fibrils. In the early phase trial, NEOD001 showed a favorable safety profile and a fairly good response rate. However, the phase 3 trial failed to confirm the clinical benefit of NEOD001 in cases with cardiac involvement [4, 21].

Similarly, murine monoclonal antibody 11-1F4 targets the

**Table 1.** Three prognostic models of AL amyloidosis [12].

Prognostic model	Criteria	Survival
Mayo model 2004 [16]	TnT < 0.035 µg/L NT-pro-BNP < 332 ng/L BNP < 81 ng/L TnI < 0.1 µg/L	Stage 1- median 26.4 mo Stage 2- median 10.5 mo Stage 3- median 3.5 mo
Mayo model 2012 [17]	TnT < 0.025 ng/mL NT-pro-BNP < 1,800 pg/mL Serum dFLC < 180 mg/dL BNP < 400 ng/L TnI- No data	Stage 1- median 94.1 mo Stage 2- median 40.3 mo Stage 3- median 14 mo Stage 4- median 5.8 mo
European model 2015 [18]	TnT < 0.035 ng/mL NT-pro-BNP < 332 pg/mL BNP < 81 ng/L TnI < 0.1 µg/L *Mayo 2004 stage 3 has been subclassified based on NT-pro-BNP < 8,500 pg/mL	Stage 1- no death cases Stage 2- 3 yr 52% Stage 3a- 3 yr 55% Stage 3b- 3 yr 19%
Boston university score 2019 [19]	TnT < 0.1 ng/mL BNP < 81 pg/mL	Stage 1- median not reached Stage 2- median 9.4 yr Stage 3a- median 4.3 yr Stage 3b- median 1 yr

human light chain-related fibrils. It showed good efficacy with minimal toxicity in the phase 1 trial [22]. Further clinical trials on 11-1F4 are currently being planned.

Theoretically, the anti-SAP antibody is applicable to all types of amyloidosis. Dezamizumab binds to SAP and induces a macrophage response that triggers the rapid removal of SAP. The first phase 1 trial showed amyloid removal from the liver, spleen, and kidneys when SAP scintigraphy was performed [23]. Although its trial has been halted in ATTR amyloidosis with cardiac involvement due to risk-benefit calculation [24], evaluation of this antibody in AL cardiac amyloidosis is pending and warranted.

## CONCLUSION

Recently, there has been substantial progress in the understanding of the pathophysiology of AL amyloidosis. Efforts to improve the dismal outcome in advanced AL amyloidosis involving the heart is actively underway based on this knowledge.

## Authors' Disclosures of Potential Conflicts of Interest

No potential conflicts of interest relevant to this article were reported.

## REFERENCES

- Kyle RA, Linos A, Beard CM, et al. Incidence and natural history of primary systemic amyloidosis in Olmsted County, Minnesota, 1950 through 1989. *Blood* 1992;79:1817-22.
- Quock TP, Yan T, Chang E, Guthrie S, Broder MS. Epidemiology of AL amyloidosis: a real-world study using US claims data. *Blood Adv* 2018;2:1046-53.
- da Silva Filho MI, Försti A, Weinhold N, et al. Genome-wide association study of immunoglobulin light chain amyloidosis in three patient cohorts: comparison with myeloma. *Leukemia* 2017;31:1735-42.
- Merlini G, Dispenzieri A, Santhorawala V, et al. Systemic immunoglobulin light chain amyloidosis. *Nat Rev Dis Primers* 2018;4:38.
- Hipp MS, Park SH, Hartl FU. Proteostasis impairment in protein-misfolding and -aggregation diseases. *Trends Cell Biol* 2014;24:506-14.
- Morgan GJ, Kelly JW. The kinetic stability of a full-length antibody light chain dimer determines whether endoproteolysis can release amyloidogenic variable domains. *J Mol Biol* 2016; 428:4280-97.
- Pepys MB, Dyck RF, de Beer FC, Skinner M, Cohen AS. Binding of serum amyloid P-component (SAP) by amyloid fibrils. *Clin Exp Immunol* 1979;38:284-93.
- Marin-Argany M, Lin Y, Misra P, et al. Cell damage in light-chain amyloidosis: fibril internalization, toxicity and cell-mediated seeding. *J Biol Chem* 2016;291:19813-25.
- Imperlini E, Gnechi M, Rognoni P, et al. Proteotoxicity in cardiac amyloidosis: amyloidogenic light chains affect the levels of intracellular proteins in human heart cells. *Sci Rep* 2017;7:15661.
- Kumar S, Dispenzieri A, Lacy MQ, et al. Revised prognostic staging system for light chain amyloidosis incorporating cardiac biomarkers and serum free light chain measurements. *J Clin Oncol* 2012;30:989-95.
- Bhatti S, Watts E, Syed F, et al. Clinical and prognostic utility of cardiovascular magnetic resonance imaging in myeloma patients with suspected cardiac amyloidosis. *Eur Heart J Cardiovasc Imaging* 2016;17:970-7.
- Vaxman I, Dispenzieri A, Muchtar E, Gertz M. New developments in diagnosis, risk assessment and management in systemic amyloidosis. *Blood Rev* 2019. [Epub ahead of print].
- Gillmore JD, Maurer MS, Falk RH, et al. Nonbiopsy diagnosis of cardiac transthyretin amyloidosis. *Circulation* 2016;133:2404-12.
- Schönland SO, Hegenbart U, Bochtler T, et al. Immunohistochemistry in the classification of systemic forms of amyloidosis: a systematic investigation of 117 patients. *Blood* 2012;119:488-93.
- Vrana JA, Gamez JD, Madden BJ, Theis JD, Bergen HR 3rd, Dogan A. Classification of amyloidosis by laser microdissection and mass spectrometry-based proteomic analysis in clinical biopsy specimens. *Blood* 2009;114:4957-9.
- Dispenzieri A, Gertz MA, Kyle RA, et al. Serum cardiac troponins and N-terminal pro-brain natriuretic peptide: a staging system for primary systemic amyloidosis. *J Clin Oncol* 2004;22:3751-7.
- Kumar S, Dispenzieri A, Lacy MQ, et al. Revised prognostic staging system for light chain amyloidosis incorporating cardiac biomarkers and serum free light chain measurements. *J Clin Oncol* 2012; 30:989-95.
- Muchtar E, Therneau TM, Larson DR, et al. Comparative analysis of staging systems in AL amyloidosis. *Leukemia* 2019;33:811-4.
- Lilleness B, Ruberg FL, Mussinelli R, Doros G, Santhorawala V. Development and validation of a survival staging system incorporating BNP in patients with light chain amyloidosis. *Blood* 2019;133:215-23.
- Vaxman I, Sidiqi MH, Gertz M. Venetoclax for the treatment of multiple myeloma. *Expert Rev Hematol* 2018;11:915-20.
- Gertz MA, Landau H, Comenzo RL, et al. First-in-human phase I/II study of NEOD001 in patients with light chain amyloidosis and persistent organ dysfunction. *J Clin Oncol* 2016;34:1097-103.
- Edwards CV, Bhutani D, Mapara M, et al. One year follow up analysis of the phase 1a/b study of chimeric fibril-reactive monoclonal antibody 11-1F4 in patients with AL amyloidosis. *Amyloid* 2019;26:115-6.
- Richards DB, Cookson LM, Berges AC, et al. Therapeutic clearance of amyloid by antibodies to serum amyloid P component. *N Engl J Med* 2015;373:1106-14.
- Zhang KW, Stockerl-Goldstein KE, Lenihan DJ. Emerging therapeutics for the treatment of light chain and transthyretin amyloidosis. *JACC Basic Transl Sci* 2019;4:438-48.