



Case report

Case report of two patients having successful surgery for lung cancer after treatment for Grade 2 radiation pneumonitis



Yuki Nakajima ^{a,*}, Hirohiko Akiyama ^a, Hiroyasu Kinoshita ^a, Maiko Atari ^a, Mitsuro Fukuhara ^a, Yoshihiro Saito ^c, Hiroshi Sakai ^b, Hidetaka Uramoto ^a

^a Division of Thoracic Surgery, Saitama Cancer Center, Japan

^b Division of Thoracic Oncology, Saitama Cancer Center, Japan

^c Department of Radiation Oncology, Saitama Cancer Center, Japan

HIGHLIGHTS

- We report on two safely operation of the lung cancer with Grade 2 radiation pneumonitis.
- Surgery should defer during having symptoms with radiation pneumonitis.
- It should not cut into areas of radiation pneumonitis in operation.

ARTICLE INFO

Article history:

Received 18 August 2015

Received in revised form

15 November 2015

Accepted 17 November 2015

Keywords:

Radiation pneumonitis

Induction chemoradiotherapy

Locally advanced non-small cell lung cancer

Surgical indication

ABSTRACT

Introduction: Surgery for locally advanced lung cancer is carried out following chemoradiotherapy. However, there are no reports clarifying what the effects on the subsequent prognosis are when surgery is carried out in cases with radiation pneumonitis. In this paper, we report on 2 cases of non-small cell lung cancer with Grade 2 radiation pneumonitis after induction chemoradiotherapy, in which we were able to safely perform radical surgery subsequent to the treatment for pneumonia.

Presentation of cases: Case 1 was a 68-year-old male with a diagnosis of squamous cell lung cancer cT2aN2M0, Stage IIIA. Sixty days after completion of the radiotherapy, Grade 2 radiation pneumonitis was diagnosed. After administration of predonine, and upon checking that the radiation pneumonitis had improved, radical surgery was performed. Case 2 was a 63-year-old male. He was diagnosed with squamous cell lung cancer cT2bN1M0, Stage IIB. One hundred and twenty days after completion of the radiotherapy, he was diagnosed with Grade 2 radiation pneumonitis. After administration of predonine, the symptoms disappeared, and radical surgery was performed. In both cases, the postoperative course was favorable, without complications, and the patients were discharged.

Conclusion: Surgery for lung cancer on patients with Grade 2 radiation pneumonitis should be deferred until the patients complete steroid therapy, and the clinical pneumonitis is cured. Moreover, it is believed that it is important to remove the resolved radiation pneumonitis without leaving any residual areas and not to cut into any areas of active radiation pneumonitis as much as possible.

© 2015 The Authors. Published by Elsevier Ltd on behalf of IJS Publishing Group Limited. This is an open access article under the CC BY-NC-ND license (<http://creativecommons.org/licenses/by-nc-nd/4.0/>).

1. Introduction

Surgery for locally advanced lung cancer is usually performed following chemoradiotherapy [1,2]. There are no reports clarifying what the effects on the subsequent prognosis are when surgery is

carried out in cases with radiation pneumonitis. In fact, there is variability in the timing when the surgery is performed after chemoradiotherapy in both randomized controlled trials and case controlled studies. Furthermore, there are no available in depth descriptions on radiation pneumonitis. Therefore, when radiation pneumonitis occurs in patients scheduled to undergo surgery, whether or not to postpone or cancel the surgery and the length of time to wait before the surgery is performed depend on each institution. At our hospital, surgery is performed in cases of Grade 1 radiation pneumonitis without clinical findings based solely upon

* Corresponding author. 780 Komuro, Ina, Kita-adachi-gun, Saitama 362-0806, Japan.

E-mail address: yuki@nms.ac.jp (Y. Nakajima).

image findings [3]. Grade 3 radiation pneumonitis, in which oxygen support is required, is an exclusion criteria for surgery. The most difficult decision is whether or not to perform the surgery on Grade 2 radiation pneumonitis patients complaining of fever, coughing, and a sensation of dyspnea. We report here on our experience with two lung cancer cases in which surgery was performed after steroid therapy due to chemoradiotherapy-induced Grade 2 radiation pneumonitis. We investigated the issues to consider prior to and during surgery with some bibliographical considerations.

2. Presentation of cases

2.1. Case 1

The patient was a 68-year-old man in whom an abnormal opacity was detected on chest radiography in a health check-up. He had a history of smoking (Brinkman index: 1000). He also had a history of cerebellar infarction, diabetes, and lumbar disc herniation. No obvious family histories were found. A 33-mm mass was present in the left lung S3 on chest CT, and the subaortic lymph node was swollen to a size of 24 mm. A bronchoscopic lung biopsy was performed, and the patient was diagnosed with stage IIIA squamous cell carcinoma, cT2aN2M0. Chemoradiotherapy with 4 cycles of cisplatin + S-1 and radiotherapy at 50 Gy concomitantly for the primary lesion and for the mediastinum were performed. Routine re-evaluation was carried out according to the New Guidelines for Evaluation of the Treatment Response of Solid Tumors. In principle, the period between the end of the radiation treatment and the surgery was recommended as at least 8 weeks. Before surgery, a second risk analysis was performed, and the decision regarding surgical intervention was made jointly by a committee, including the attending radiation oncologist, thoracic surgeon, medical oncologist, and pulmonologist. Following re-evaluation, surgery is generally performed for patients in whom a R0 resection is deemed possible. Therefore, surgery was planned for our patient based on the treatment response (PR, ycT1bN0M0). Pneumonitis was detected in the radiated field on a CT at 60 days after completion of the radiotherapy, and a fever had developed. The patient was diagnosed with Grade 2 radiation pneumonitis. Surgery was postponed and treatment with 30 mg of oral prednisolone was initiated. The dose was reduced weekly from 30 to 20

to 10 to 5 mg. After confirming remission of the symptoms and improvement in the radiation pneumonitis, surgery was scheduled at 106 days after completion of the radiotherapy and at 63 days after completion of the anticancer drug therapy (Fig. 1) (Table 1). A left upper lobectomy plus mediastinal lymph node dissection, pulmonary angioplasty, and segmental resection of S6 were performed (Table 1). No postoperative complications developed, and the patient was discharged on postoperative day (POD) 9. He currently remains alive without disease progression one year after therapy.

2.2. Case 2

The patient was a 63-year-old man with a chief complaint of bloody phlegm. He had a history of diabetes and hepatitis C. A chest CT revealed a 64-mm mass continuous from the left pulmonary hilar region over the bronchial lumen of the left upper lobe. The lesion was diagnosed by sputum cytology as stage IIB squamous cell carcinoma, cT2bN1M0. Preoperative chemoradiotherapy was selected to avoid the need for total excision. Four cycles of cisplatin + S-1 and radiotherapy at 60 Gy concomitantly for the primary lesion and for the mediastinum were performed. The treatment response was PR, ycT1bN0M0, and the surgery was planned. Pneumonitis was noted at a site consistent with the radiated field 120 days after completion of the radiotherapy. Fever and cough developed, and the patient was diagnosed with Grade 2 radiation pneumonitis. Surgery was postponed, and treatment with 30 mg of oral prednisolone was initiated. The dose was reduced weekly from 30 to 20 to 10 mg. After confirming remission of the symptoms and improvement in the radiation pneumonitis, surgery was scheduled at 188 days after completion of radiotherapy and at 117 days after completion of anticancer drug therapy (Fig. 2) (Table 1). A total resection of the left lung plus mediastinal lymph node dissection was performed (Table 1). A paroxysmal atrial fibrillation occurred at day 3 after surgery. However, anti-arrhythmic treatment corrected the problem, and the patient was discharged on day 19 after surgery. He currently remains alive without disease progression thirteen months after therapy. Follow-up information was obtained from both patients through office visits or by telephone interviews. The two patients were basically evaluated every month by a physical examination, chest

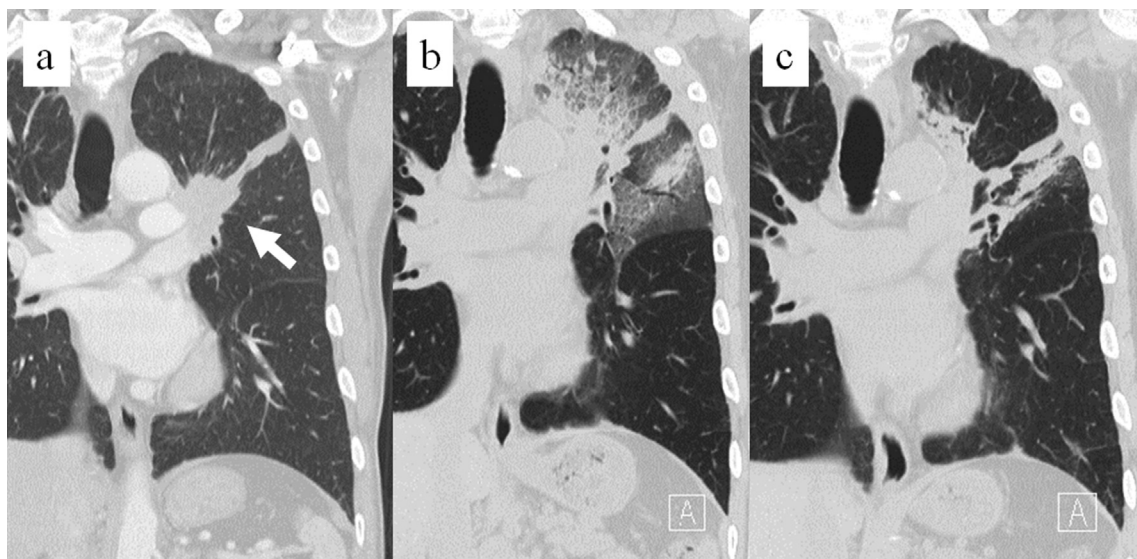


Fig. 1. Chest CT in case 1. a) A tumor in the left upper lobe (arrow). b) Preoperative radiation pneumonitis. c) Inflammation of the lungs was improved with only residual fibrosis.

Table 1
Clinical data and surgical data in the two cases.

	Case 1	Case 2
Age	68	63
Gender	Male	Male
Stage (Before treatment)	cT2aN2M0 Stage IIIA	cT2bN1M0 Stage IIB
Stage (After treatment)	ycT1bN0M0 Stage IA	ycT1bN0M0 Stage IA
Regimen	CDDP + S-1	CDDP + S-1
Dose (Gy)	50	60
Treatment response	PR	PR
Grade of radiation pneumonitis	Grade 2	Grade 2
Time to surgery after final chemotherapy (days)	63	117
Time to surgery after final radiotherapy (days)	106	188
Blood test findings before treatment of radiation pneumonitis	WBC: 7610/ μ l LDH: 162 IU/l CRP: 1.3 mg/dl	WBC: 6170/ μ l LDH: 179 IU/l CRP: 2.2 mg/dl
Blood test findings before surgery	WBC: 7130/ μ l LDH: 196 IU/l CRP: 0.3 mg/dl	WBC: 7100/ μ l LDH: 195 IU/l CRP: 2.1 mg/dl
Operation	Left upper lobectomy + S6 segmentectomy + ND2a-2	Left pneumonectomy + ND2a-2
Operation time (minutes)	358	277
Bleeding (g)	468	520
Transfusion	Map: 4u	none
Coverage of bronchial stump	Pericardial adipose tissue	Pericardial adipose tissue
Postoperative complication	None	None

roentgenography, analysis of the blood chemistry variables, and measurements of the tumor marker levels. As a general rule, chest and abdominal CT scans, brain MRI, and a bone scintiscan were obtained every 6 months for the first 2 years after surgery. Additional examinations were performed if any symptoms or signs of recurrence were detected.

3. Discussion

Acute radiation pneumonitis becomes problematic during surgical procedures. Moreover, acute radiation pneumonitis is classified into classical radiation pneumonitis, in which pneumonia occurs within the radiation field, and sporadic radiation pneumonitis, in which pneumonia occurs outside and on the symmetrical side of the radiation field [4,5]. Sporadic radiation pneumonitis occurs in approximately 5% of all radiation therapy cases, with the degree often serious and with a poor prognosis [4–7]. From these findings, it is believed that the clinical conditions are an index for active medical intervention, and surgery should be postponed

when fever, coughing, etc. are observed [1]. It is important to confirm via images that the range of radiation pneumonitis has not expanded outside the radiation field, and that the clinical condition has not become serious [2]. Generally, steroid therapy is carried out as a treatment for symptomatic radiation pneumonitis. Usually, symptoms remit within one week following steroid drug administration, with improvement observed upon imaging within 2–4 weeks [7,8].

Moreover, there are some reports on postoperative empyema determined to be caused by radiation pneumonitis [9,10]. Changes in pneumonitis due to radiation include the formation of a hyaline membrane and a fibrotic change of the alveolar wall, hyperplasia of the alveolar epithelium, edema and hyperemia of the alveolus, inflammatory cell infiltration, hyalinization of the capillary vessel, changes in the bronchi, including fibrosis of the bronchial wall, and contraction of the bronchial gland [11]. From these findings, it is believed that normal wound healing mechanisms do not function in lungs with radiation pneumonitis, and moreover, the lungs are susceptible to infection. Accordingly, it is believed that during

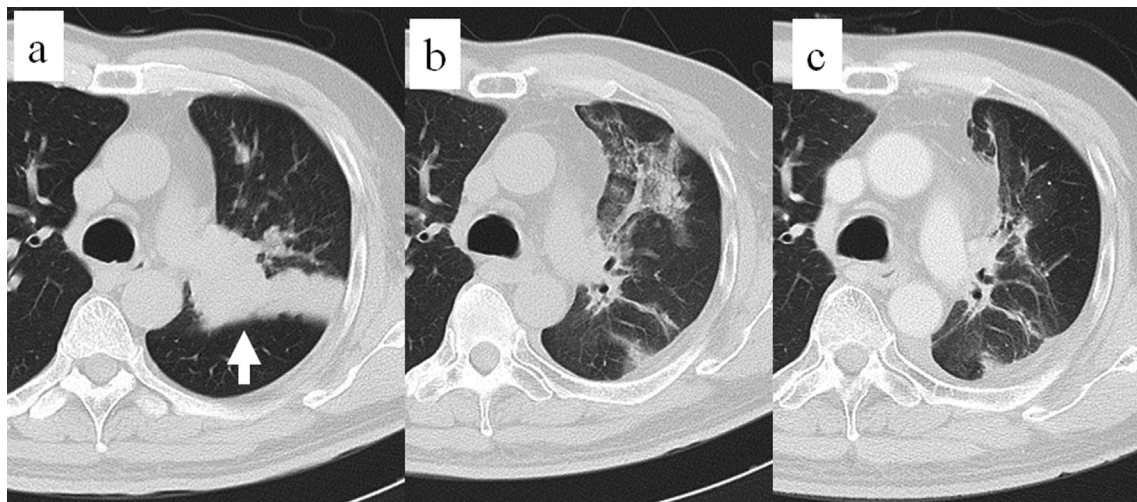


Fig. 2. Chest CT in case 2. a) A tumor in the left upper lobe (arrow). b) Preoperative radiation pneumonitis. c) Inflammation of the lungs was improved with only residual fibrosis.

pneumonectomy, cutting into areas of radiation pneumonitis should be avoided, with resection recommended, if possible [10]. In our study as well, in case 1, segmentectomy was carried out on the radiation pneumonitis area, including S6. Moreover, there are reports mentioning that radiation pneumonitis occurs in the residual lungs following surgery, thereby leading to empyema. Furthermore, it is believed that even if radiation pneumonitis is not observed during surgery, when cutting into the radiation field for the purpose of creating gaps between lobes, etc., careful checking for a pulmonary fistula and repair of the pulmonary fistula part is subsequently required. At our institute, surgery is performed at least 2 months following radiation therapy in order to reduce such post-operative complications [1,12].

4. Conclusion

Surgery for lung cancer with respect to cases with onset of Grade 2 radiation pneumonitis was deferred until after the patients were treated with steroid therapy and after the clinical conditions along with improvement in image findings were confirmed. Moreover, it was believed that it is essential to remove the resolved radiation pneumonitis without any residual areas and not to cut into any areas of active radiation pneumonitis as much as possible. Therefore, we propose Grade 2 radiation pneumonitis caused by chemoradiotherapy followed by steroid treatment and then by lung cancer surgery for clinical practice and for clinical trials.

Ethical approval

Two patients provided their written informed consent for treatment, and privacy policy fully explained.

Funding

None.

Author contribution

Yuki Nakajima carried out the operations and wrote the manuscript. Hiroyasu Kinoshita, Maiko Atari, Mitsuro Fukuhara carried out the operations. Hiroshi Sakai and Hirohiko Akiyama have contributed to the clinical management of the patient. Yoshihiro Saito carried out the radiotherapy. Hidetaka Uramoto carried out the operations and revision of the manuscript.

Conflict of interest

The authors report no conflict of interest.

Guarantor

Yuki Nakajima and Hidetaka Uramoto.

Consent

Informed and written consent has been given by patient.

References

- [1] H. Uramoto, H. Akiyama, Y. Nakajima, H. Kinoshita, T. Inoue, et al., The long term outcome of induction chemoradiotherapy followed by surgery for locally advanced non-small cell lung cancer, *Case Rep. Oncol.* 7 (2014) 700–710.
- [2] S. Yoneda, M. Yamamoto, M. Sakura, T. Izumo, Y. Noguchi, H. Nishimura, et al., Induction chemoradiotherapy followed by surgery for stage III nonsmall cell lung cancer, *Jpn. J. Clin. Oncol.* 23 (1993) 173–177.
- [3] National Cancer Institute: Common Terminology Criteria for Adverse Events (CTCAE) v.4.0, May 28, 2008, p. 173. Available at: http://ctep.cancer.gov/protocolDevelopment/electronic_applications/ctc.htm.
- [4] G.W. Morgan, S.N. Breit, Radiation and the lung: a reevaluation of the mechanisms mediated pulmonary injury, *Int. Radiat. Oncol. Biol. Phys.* 31 (1995) 361–369.
- [5] U.B. Prakash, Radiation-induced injury in the “non- irradiated” lung, *Eur. Respir. J.* 13 (1999) 715–717.
- [6] J.D. Cox, N. Azarnia, R.W. Byhardt, K.H. Shin, B. Emami, T.F. Pajak, A randomized phase I/II trial of hyperfractionated radiation therapy with total doses of 60.0 Gy to 79.2 Gy: possible survival benefit with greater than or equal to 69.6 Gy in favorable patients with radiation therapy oncology group stage III non-small-cell lung carcinoma: report of radiation therapy oncology group 83-11, *J. Clin. Oncol.* 8 (1990) 1543–1555.
- [7] J.D. Cox, N. Azarnia, R.W. Byhardt, K.H. Shin, B. Emami, C.A. Perez, N2 (clinical) non-small cell carcinoma of the lung: prospective trials of radiation therapy with total doses 60 Gy by the Radiation Therapy Oncology Group, *Int. J. Radiat. Oncol. Biol. Phys.* 20 (1991 Jan) 7–12.
- [8] S. Kudo, A. Yoshimura, Current status and measures for lung injuries in cancer treatment, *Jpn. J. Cancer Chemother.* 31 (2004) 679–684.
- [9] M. Iwasaki, J. Ogawa, K. Inoue, A. Shoftsu, T. Mori, Empyema manifesting more than two months after pulmonary resection, *Jpn. J. Lung Cancer* 30 (1990) 255–259.
- [10] D. Masuya, M. Gotoh, T. Nakashima, T. Okamoto, D. Liu, S. Ishikawa, et al., An intractable empyema proceeded from radiation pneumonitis after operation of lung cancer, *Jpn. J. Chest Surg.* 19 (2005) 689–692.
- [11] S. Warren, J. Spencer, Radiation reaction on the lung and bronchial tree, *Am. J. Roentigenol.* 43 (1940) 682–701.
- [12] J.R. Sonett, M.J. Krasna, M. Suntharalingam, J. Schuetz, L.A. Doyle, R. Lilenbaum, et al., Safe pulmonary resection after chemotherapy and high-dose thoracic radiation, *Ann. Thorac. Surg.* 68 (1999) 316–320.