


Effect of gum Arabic as natural prebiotic on intestinal ecosystem of post-hatched broiler chicks

Hani Hasan Al-Baadani*, Rashed Abdullah Alhotan, Mahmoud Mustafa Azzam, Ibrahim Abdullah Alhidary, Abdulrahman Salem Alharthi, Abdulaziz Abdullah Al-Abdullatif

Department of Animal Production, College of Food and Agriculture Science, King Saud University, Riyadh 11451, Saudi Arabia



Received: Apr 30, 2023

Revised: Jun 1, 2023

Accepted: Jun 20, 2023

*Corresponding author

Hani Hasan Al-Baadani
Department of Animal Production,
College of Food and Agriculture
Science, King Saud University, Riyadh
11451, Saudi Arabia.
Tel: +966-558829648
E-mail: hsaeed@ksu.edu.sa

Copyright © 2024 Korean Society of Animal Sciences and Technology. This is an Open Access article distributed under the terms of the Creative Commons Attribution Non-Commercial License (<http://creativecommons.org/licenses/by-nc/4.0/>) which permits unrestricted non-commercial use, distribution, and reproduction in any medium, provided the original work is properly cited.

ORCID

Hani Hasan Al-Baadani
<https://orcid.org/0000-0003-3994-9216>
Rashed Abdullah Alhotan
<https://orcid.org/0000-0002-7789-4722>
Mahmoud Mustafa Azzam
<https://orcid.org/0000-0001-9736-5468>
Ibrahim Abdullah Alhidary
<https://orcid.org/0000-0003-2547-4395>
Abdulrahman Salem Alharthi
<https://orcid.org/0000-0002-9719-9444>
Abdulaziz Abdullah Al-Abdullatif
<https://orcid.org/0000-0003-2975-3519>

Competing interests

No potential conflict of interest relevant to this article was reported.

Funding sources

The authors thank King Saud

Abstract

The purpose of the current study was to investigate the effects of gum Arabic supplementation on short-chain fatty acids, cecal microbiota, immune-related gene expression, and small intestinal morphology in post-hatched broiler chicks. On the day of hatching, four hundred thirty-two commercial male broiler chicks were randomly allocated into six treatments with twelve cages as replicates of six chicks each for 24 days. Dietary treatments (T1 to T6) were supplemented with 0.0, 0.12, 0.25, 0.50, 0.75, and 1.0% gum Arabic to the basal diet, respectively. Performance parameters, short-chain fatty acid concentration, quantification of microbiota and immune response gene expression (pre-inflammatory cytokines, mucin-2, and secretory immunoglobulin A), and histomorphometry of the small intestine were measured. According to our results, daily weight gains in T2 and the production efficiency index increased in T2 to T4, whereas daily feed intake decreased in T2, T3, T5, and T6, but feed conversion ratio improved. Concentration of lactate, acetate, butyrate, and total short-chain fatty acid increased in T2, T3, T5, and T6. Propionate in T2, T3, T4, and T6 and formate in T2, T5, and T6 also increased. *Lactobacillus* spp. quantitatively increased from T3 to T6, whereas *Bacteroides* spp. decreased in T3 and T5. Other microbiota quantitatively showed no effect of dietary supplements. *IL-1 β* , *TNF- α* , and *MUC-2* decreased in T2 to T6 and *IL-12* in T3, whereas *INF- γ* increased in T4 to T6 and *SlgA* in T4. All histometric parameters of the duodenum, jejunum, and ileum improved with dietary supplementation. We conclude that the administration of gum Arabic resulted in an improvement in overall performance, fermentation metabolites, and modification of microbiota and immune response with improved histomorphometry in the intestines of young chicks.

Keywords: *Gallus domesticus*, Performance, Short-chain fatty acids (SCFAs), Microbiota, Immune response, Morphology

INTRODUCTION

Currently, the colonization of the microbiota in the gut of young chicks is the focus of many studies. Commercial hatcheries are a source of gut colonization for chicks after hatching, which can colonize

University, Riyadh, Saudi Arabia, for funding this work through the Research Project Group (RSPD2024R581).

Acknowledgements

Not applicable.

Availability of data and material

Upon reasonable request, the datasets of this study can be available from the corresponding author.

Authors' contributions

Conceptualization: Alhotan RA, Azzam MM.

Formal analysis: Al-Baadani HH.

Methodology: Al-Baadani HH.

Validation: Alhotan RA, Azzam MM, Alhidary IA, Alharthi AS, Al-Abdullatif AA.

Investigation: Alhotan RA, Azzam MM, Alhidary IA, Alharthi AS, Al-Abdullatif AA.

Writing - review & editing: Al-Baadani HH, Alhotan RA, Azzam MM, Alhidary IA, Alharthi AS, Al-Abdullatif AA.

Ethics approval and consent to participate

The King Saud University in Saudi Arabia's Scientific Research Ethics Committee gave its approval for the current study and the use of all chickens (KSU-SE-20-39).

during the growth stage [1]. Pathogens can grow and continuously colonize the gut of chicks because it is an empty ecological niche [2,3]. For decades, antimicrobial growth promoters (AGPs) have been used in poultry diets to improve feed efficiency and maintain intestinal ecosystem balance [4]. However, due to the emergence of bacterial resistance, imbalance in the gut microbiota, and increasing consumer concern about the negative effects of antibiotics, the use of AGP in chicken feed has been banned [5,6]. Schokker et al. [7] reported that post-hatch administration of AGP negatively affected the microbial colonization of broiler chicks at 14 days of age. These revealed problems indicated the need to search for a dietary supplement without AGP [8]. Early administration of dietary supplements after chick hatching is critical for promoting early growth and improving gut function and therefore could be an effective strategy [9,10]. Rapid colonization of the gut with commensal bacteria acts as an environmental factor that influences host physiology, metabolism, and gut health [11,12].

Gum Arabic is a soluble, indigestible dietary fiber naturally secreted from the tears of *Acacia Senegal*, a plant in the Fabaceae family [13,14]. Gum Arabic is used in many scopes of the food and pharmaceutical industries, especially in conventional medicine to treat a wide range of human diseases [15]. The action mechanism of gum Arabic has been studied in humans, rats, laying hens, and broilers [16,17]. They indicated that since gum Arabic is not broken down in the digestive system, commensal bacteria ferment it instead. This promotes the growth of probiotic bacteria that produce short-chain fatty acids (SCFAs) or other antibacterial compounds, which can improve gut health and consequently affect broiler performance [18,19]. Gum Arabic may inhibit pathogenic bacteria colonization and activate the production of cytokines to regulate immune responses [20]. On the other hand, gum Arabic fibers can be recognized by immune cell receptors, which enhances the host's immunity [21]. This study hypothesized that the use of gum Arabic (*Acacia Senegal*) from the first day after hatching could potentially affect intestinal ecosystem parameters (microbiota, immune response, and histomorphological characteristics) and overall growth performance. The aim of the present study was to investigate the effects of gum Arabic supplementation on quantitative microbiota, SCFA concentration, immune-related gene expression, and small intestine morphology in broiler chicks during the early growth phase.

MATERIALS AND METHODS

The King Saud University in Saudi Arabia's Scientific Research Ethics Committee gave its approval for the current study and the use of all chickens (KSU-SE-20-39).

Analysis of gum Arabic fiber and sugar content

Insoluble fiber, soluble fiber, hemicelluloses, cellulose, and lignin were analyzed according to the methods of AOAC International [22]. Following the method described by Vázquez-Ortiz et al. [23], the sugar composition of gum Arabic powder, including arabinose and galactose, was determined by High performance liquid chromatography (HPLC; Table 1).

Study design: housing

A total of four hundred thirty-two commercial male broiler chicks (Ross 308) were used from 1 to 24 days of age in this study. Chicks were weighed and then randomly assigned to six dietary treatments with twelve replicate cages of six chicks each. The base diet used was formulated to meet all the nutritional needs of the chicks in mash form during the two phases (starter and grower), according to the recommendations in the Ross 308 Management Guide (Table 2). Dietary treatments (T1 to T6) were supplemented with 0.0, 0.12, 0.25, 0.5, 0.75, and 1.0% gum Arabic

Table 1. Analysis of gum Arabic (*Acacia Senegal*) fiber and sugar content

Chemical composition	%
Insoluble fiber	2.93
Soluble fiber	80.22
Hemicelluloses	1.73
Cellulose	0.23
Lignin	0.97
Sugar composition	
Rhamnose	8.4
Arabinose	26.0
Galactose	40.18
Glucuronic acid	18.23

Table 2. Feed ingredients and nutrient composition of the basal diet¹⁾

	Starter	Grower
	1–10 days	11–24 days
Ingredients (%)	100	100
Yellow corn	52.66	57.38
Soybean meal 48%	39.10	33.98
Corn oil	3.72	4.41
Limestone	1.00	0.92
Dicalcium phosphate	1.82	1.63
Vit. and Min. mixture ²⁾	0.50	0.50
Salt	0.42	0.32
DL-Methionine	0.35	0.32
L-Lysin HCl	0.20	0.19
L-Threonine	0.13	0.11
Choline Cl 60%	0.09	0.09
Sodium bicarbonate	0.01	0.15
Calculated nutrient		
ME (kcal/kg)	3,000	3,100
Crude protein (%)	23.29	21.15
Crude fat (%)	6.51	7.26
Crude fiber (%)	2.83	2.72
Calcium (%)	0.96	0.87
Non-phytate P (%)	0.48	0.44
d Lysine (%)	1.28	1.15
d TSAA (%)	0.95	0.87
d Threonine (%)	0.86	0.77
d Arginine (%)	1.43	1.28

¹⁾Nutritional requirements in the diet was suggested according Management Guide recommendation Ross 308 strain.

²⁾Containing mixture supplied per kg of diets: Vit. A: 2,400,000 IU; Vit. D: 1,000,000 IU; Vit. E: 16,000 IU; Vit. K: 800 mg; Vit. B1: 600 mg; Vit. B2: 1,600 mg; Vit. B6: 1,000 mg; Vit. B12: 6 mg; Biotin: 40 mg; Folic Acid: 400 mg; Niacin: 8,000 mg; Pantothenic Acid: 3,000 mg; Cobalt: 80 mg; Copper: 2,000 mg; Iodine: 400 mg; Iron: 1200 mg; Manganese: 18,000 mg; Selenium: 60 mg; Zinc: 14,000 mg.

ME, metabolizable energy; TSAA, total sulfur amino acid.

powder to the basal diet, respectively. Chicks were raised in environmentally controlled battery cages under similar management and sanitation conditions. For the duration of the study, the chicks had ad libitum access to food and water for 24 hours each day.

Performance evaluations

Growth performance parameters were measured at starter and grower stages from 1 to 24 days. Daily weight gain, feed intake, and feed conversion ratio were calculated [24]. Production efficiency index (PEI) was evaluated using the following formula: $PEI = (\text{livability} \times \text{live weight/age in days} \times \text{feed conversion ratio}) \times 100$ [25].

Caecal short-chain fatty acids (SCFAs)

At 10 days of age, collection of caecal digesta samples (12 birds per gum Arabic) for analysis of SCFAs according to the method of Aljumaah et al. [26]. Internal standard (mixture of SCFAs) was used (Augsburg, Germany) for procedures of lactate, format, acetate, propionate, butyrate and total SCFA analysis by HPLC Agilent 1260 series. Inertsustain AQ-C18 HP column (4.6 mm \times 150 mm i.d., 3 μ m) was used for separation. The mobile phase consisted of 0.005 N sulfuric acid. The mobile phase was sequentially programmed in a linear gradient for flow rate from 0–4.5 to 23–25 minutes (0.8 mL/min). The diode array detector was tracked at 210 nm. An injection volume of 5 μ L was used for each of the sample solutions. The temperature in the column was maintained at 55°C. Results of SCFA concentrations are expressed as mg SCFA per 1 g of caecal digesta.

Quantification of the cecal microbiota

Approximately 200 mg of caecal digesta (10 chicks) were collected for counting caecal bacteria according to Gharib-Naseri et al. [27] and Tajudeen et al. [28]. Total DNA extraction was performed using the QIAamp DNA Stool Mini Kit (Qiagen, Germantown, MD, USA) according to the manufacturer's instructions. Using a Nanodrop spectrophotometer (Nanodrop 2000, Thermo Fisher Scientific, Waltham, MA, USA) and an agarose gel electrophoresis technique, DNA quantity and quality were determined. Extracted DNA from all samples was diluted in nuclease-free water to a concentration of 50 ng/ μ L. On the Applied Biosystems 7300 Real-Time polymerase chain reaction system (Applied Biosystems, Waltham, MA, USA), 5 bacteria (Table 3) were quantified using the Power SYBR® Green polymerase chain reaction master mix (Applied Biosystems, Thermo Fisher Scientific, Warrington, UK) according to the manufacturer's instructions. For each target gene, every reaction was performed in triplicate. Thermal cycling was carried out in three stages as follows: one cycle at 50°C for 2 min, followed by 40 cycles at 95°C for 15 s, and finally, 60°C for 1 min. Using a standard curve generated for serially diluted pool DNA at a known concentration (from 10^2 to 10^{12} copies/g caecal digesta), quantification of the microbiota in each sample was determined [29]. The result of the quantification of the microbiota was expressed as Log_{10} per 1 g of caecal digesta.

Gene expression of immune response in the jejunum

Approximately one-centimeter-long tissue sections (10 chicks) were taken from the proximal upper part of the jejunum in RNAlater (Qiagen, Hilden, Germany) solution for quantification of gene expression according to Han et al. [30] and Elnagar et al. [31]. The ZymoQuick mRNA extraction kit from Zymo Research, California, USA, was used to isolate mRNA for each sample according to the manufacturer's instructions. A Nanodrop spectrophotometer (NANODROP 2000, Thermo Scientific) was used to evaluate the absorbance at 260 nm and the 260/280 nm ratio to determine the amount and purity of extracted mRNA. The final concentration of extracted mRNA was

Table 3. Primer sequences of immune response and caecal microbiota genes for real-time quantitative polymerase chain reaction analysis

Target gene	Forward primer (5' → 3')	Reverse primer (5' → 3')	GenBank number
Immune response			
<i>TNF-α</i>	GGGAGTGTGAGGGGTATCCT	CTGCACCTTCTGTCTCGGTT	MH180383.1
<i>IL-1β</i>	ACAAGCCGAACAAAGCACAC	CTCCACATCTGGCTCACGTT	KY038171.1
<i>IL-12</i>	ATCCACTGGACCTCAGACCA	CTCAGAGTCTCGCCTCCTCT	S82489.1
<i>INF-γ</i>	TCCCAGAAGCTATCTGAGCAT	CCACCGTCAGCTACATCTGAAT	NM_205149.2
<i>slgA</i>	TTCCTGAGTTGCCGAGTGAC	AGGGATTTCTTGCTGGGAGC	DL232588.1
<i>MUC-2</i>	CGGTGATGACAACGACTCCA	AAGTTTGACAGTCGTTTCGC	AF167707.1
<i>β-actin</i>	CCTTCCTGGGTAGGTGTGCG	TGGCGTAGAGGTCCTTCTCTG	AJ312193.1
Caecal microbiota			
<i>Lactobacillus</i> spp.	CGACTGCTCTGGTTATACCGT	TGAAGAAGGGTTTCGGCTCG	DI197694.1
<i>Bifidobacteria</i> spp.	CAGCTCGTGTCGTGAGATGT	GATCTGACGTCATCCCCACC	MW750419.1
<i>Bacteroides</i> spp.	TAGAGATAAGGCCCTTTGGGGT	CGAATCGGAGATTATTTAGGTGC	MZ172908.1
<i>Clostridium</i> spp.	GTTTACGGCGTGGACTACCA	TGGAAGTCTAGAGTGCGGGA	DI335788.1
<i>Escherichia coli</i>	CATGCCGCGTGTATGAAGA	GGGTAACGTC AATGAGCAAAG	5NDI_C

TNF-α, tumor necrosis factor-alpha; IL, interleukin; INF-γ, interferon-gamma; slgA, secretory IgA; MUC-2, mucin 2.

diluted to 100 ng/μL for all samples. Subsequently, according to the instructions of the Applied Biosystems reverse transcription kit manufacturer, Thermo Fisher Scientific, UK, it was used to convert total mRNA into complementary DNA (cDNA). The cDNA sample was diluted (1:3) to reduce the template concentration. The quantitative polymerase chain reaction of the cDNA samples was performed by Power SYBR® Green polymerase chain reaction master mix (Applied Biosystems, Thermo Fisher Scientific) with the primers of the target genes (Table 3) using 7300 Real-Time polymerase chain reaction system (Applied Biosystems, Warrington, UK). The reaction for each target gene was performed in duplicate. The cycle threshold (Ct) was determined according to the amplification procedure. Relative quantification was calculated by the $2^{-\Delta\Delta C_t}$ method ($2^{-[\Delta C_t \text{ for target gene} - (\Delta C_t \text{ value of } \beta\text{-actin as housekeeper} - \text{average } \Delta C_t \text{ value for control sample})]}$). Compared with the control treatment, a fold change in gene expression was calculated.

Morphological measurements of small intestinal

On day 10 of age, the small intestine of 12 chicks was sampled for each dietary treatment. The relative length and weight of the duodenum, jejunum, and ileum were measured as a percentage of the total small intestine. Small intestinal weight (SI) was expressed as a percentage of live weight. In addition, the weight to length ratio of the intestine was calculated based on its weight and length [32].

Histometric measurements of small intestinal

Tissues (almost 2 cm) from the middle part of the duodenum, jejunum, and ileum of 12 chicks were collected for each dietary treatment at 10 days of age. According to the procedure indicated by Daneshmand et al. [33], histological sections were prepared. After sectioning, tissue was fixed (10% buffered formalin) for 72 hours, dehydrated (70%–95% ethyl alcohol) for 60 minutes, and embedded using paraffin wax (Tissue-Tek VIP 5 Jr, Sakura, Tokyo, Japan). 5 μm-long sections were cut with a rotary microtome (RM 2255, Leica Biosystems, Nußloch, Germany) and then stained with eosin, hematoxylin, and Alcian blue on slides (CV5030, Leica Biosystems). Histometric parameters of the small intestine such as villus length (VL), width (W), crypt depth (CD), goblet cells (GC), epithelial thickness (ET), and lamina propria thickness (LPT) were measured (five villi

per section) using a light microscope (Nikon, Tokyo, Japan) and image analysis software (AmScope digital camera with attached Ceti England microscope) [34]. In addition, the villus surface area ($SA=2\pi \times (W/2) \times VL$), height of villus length to crypt ratio (VL/CD), and density of goblet cell /100 μm of villus area (GC100) were recorded [35,36].

Data analysis

SAS software [37] was used to analyze all data using one-way variance. A comparison of dietary treatments (T2 to T6) with a based diet (T1) was determined when $p < 0.05$ is the threshold for statistical significance according to Dunnett's test. In addition, regression analysis was used to determine whether the dietary treatments produced linear or quadratic responses. The SEM was included in the data presented.

RESULTS

Performance measurements

The effects of treatments on the overall performance of male broiler chicks are presented in Table 4. According to Dunnett's test, the results show that daily weight gain was higher on days 1–5 and 6–10, when chicks received gum Arabic supplementation of 0.12% (T2) compared to T1 ($p < 0.05$). In contrast, chicks received gum Arabic supplementation (T2 to T5) had higher daily weight gain on days 11–17 compared with T1 ($p < 0.05$). T2, T3, and T5 dietary treatments on days 1–5, T6 on

Table 4. Effect of dietary treatments on general growth performance of male broiler chicks

Parameters	Dietary treatments (TRT) ¹⁾						SEM	p-value		
	T1	T2	T3	T4	T5	T6		TRT	L	Q
Daily weight gain (g)										
1–5 d	13.13 ^b	14.24 ^a	13.51 ^b	13.84 ^b	13.63 ^b	13.58 ^b	0.28	0.150	0.098	0.242
6–10 d	29.80 ^b	32.03 ^a	30.86 ^b	31.67 ^b	30.29 ^b	28.80 ^b	0.61	0.004	0.246	0.004
11–17 d	50.69 ^b	57.01 ^a	55.93 ^a	56.58 ^a	59.23 ^a	54.88 ^a	1.13	0.001	< .0001	0.001
18–24 d	76.24	78.82	79.17	78.35	73.01	75.23	2.04	0.263	0.764	0.206
Daily feed intake (g)										
1–5 d	13.30 ^a	11.84 ^b	12.08 ^b	12.63 ^a	12.58 ^b	12.75 ^a	0.19	< .0001	0.002	0.001
6–10 d	38.76 ^a	37.12 ^a	37.02 ^a	38.63 ^a	37.20 ^a	36.61 ^b	0.52	0.016	0.048	0.991
11–17 d	75.04 ^a	69.16 ^b	68.12 ^b	71.81 ^a	70.84 ^a	67.94 ^b	1.19	0.006	0.002	0.230
18–24 d	105.45 ^a	98.84 ^b	102.80 ^a	102.72 ^a	105.14 ^a	106.59 ^a	1.39	0.003	0.199	0.022
Feed conversion ratio (g/g)										
1–5 d	1.02 ^a	0.83 ^b	0.89 ^b	0.92 ^b	0.93 ^b	0.94 ^b	0.02	< .0001	< .0001	0.002
6–10 d	1.31 ^a	1.16 ^b	1.20 ^b	1.22 ^b	1.23 ^a	1.27 ^a	0.02	< .0001	0.004	0.002
11–17 d	1.48 ^a	1.21 ^b	1.22 ^b	1.27 ^b	1.20 ^b	1.24 ^b	0.02	< .0001	< .0001	< .0001
18–24 d	1.39 ^a	1.26 ^b	1.30 ^b	1.33 ^a	1.46 ^a	1.42 ^a	0.03	0.001	0.349	0.020
Production efficiency index										
1–5 d	217.5 ^b	277.4 ^a	250.2 ^a	248.4 ^a	243.0 ^a	238.5 ^b	6.43	< .0001	0.001	0.003
6–10 d	199.5 ^b	237.9 ^a	221.7 ^a	222.8 ^a	214.9 ^b	201.3 ^b	5.49	< .0001	0.003	0.003
11–17 d	250.5 ^b	331.1 ^a	322.2 ^a	312.3 ^a	339.9 ^a	310.6 ^a	8.54	< .0001	< .0001	< .0001
18–24 d	350.8 ^b	410.3 ^a	392.4 ^b	392.7 ^b	347.9 ^b	347.2 ^b	14.1	0.004	0.096	0.004

¹⁾Dietary treatments from T1 to T6 supplemented by 0.0%, 0.12%, 0.25%, 0.50%, 0.75%, and 1.0% of gum Arabic, respectively.

^{a,b}Means that do not share a common superscripted with control treatment (T1) within a row for each parameter has a significant effect, as determined by the Dunnett test ($p < 0.05$). SEM, standard error of means for diet effect; TRT, dietary treatments effect; L, linear response; Q, quadratic response.

days 6–10, T2, T3, and T6 on days 11–17, and T2 on days 18–24 had lower daily feed intake ($p < 0.05$). Feed conversion improved in all dietary treatments during the study phases ($p < 0.05$), except for T5 and T6 on days 6–10 and 18–24, which had no effect compared to T1. Chicks receiving gum Arabic at T2, T3, and T4 had a higher production efficiency index than T1 during starter and grower stages ($p < 0.05$). Additionally, a quadratic response of dietary treatments on daily weight gain, feed conversion, and production efficiency index and a linear response on daily feed intake with increasing dietary supplementation was observed ($p < 0.05$), except for 1–5 and 18–24 with quadratic response.

Short-chain fatty acids of cecal

The effects of treatments on short-chain fatty acids (SCFA) in the caecum of male broiler chicks are presented in Table 5. T2, T3, T5, and T6 had higher concentrations of lactic acid, acetic acid, butyric acid, and total SCFA compared to T1 ($p < 0.05$ by Dunnett's test). Dunnett's test also revealed that chicks fed T2, T5, and T6 had higher formic acid concentrations, and that T2 to T6 had higher propionic acid concentrations compared to T1, with the exception of T5 ($p < 0.05$). In addition, a linear response of dietary treatments on concentrations of lactic acid, acetic acid, butyric acid, propionic acid, and total SCFA was observed, as well as a quadratic response on formic acid concentration with increasing dietary supplementation ($p < 0.05$).

Quantification of caecal bacteria

The effects of treatments on quantification of the caecal microbiota of male broiler chicks are presented in Fig. 1. When chicks received T3 to T6, quantification of *Lactobacillus* spp. was increased compared to T1 ($p = 0.017$ by Dunnett's test). While *Bacteroides* spp. was reduced in chicks receiving T3 and T5 compared to T1 ($p = 0.036$). In addition, *Bifidobacteria* spp., *Clostridium* spp. and *Escherichia coli* (*E. coli*) showed no effect in chicks receiving dietary supplements compared to T1 ($p > 0.05$). In addition, there was a linear response to treatments in *Lactobacillus* spp. and *Bacteroides* spp. ($p < 0.05$), but other quantifiable bacteria did not respond linearly or quadratically to treatments ($p > 0.05$).

Gene expression of the immune response

The effects of treatments on pre-inflammatory cytokines expression in male broiler chicks are presented in Fig. 2. When chicks received T2 to T6 compared to T1, fold change in interleukin (*IL*)- 1β and tumor necrosis factor (*TNF*)- α expression was reduced ($p < 0.05$ by Dunnett's test). In contrast, *IL*-12 and interferon (*INF*)- γ expression was increased in chicks receiving T6 compared

Table 5. Effect of dietary treatments on cecal short-chain fatty acid (SCFA; mg/g) of male broiler chicks

Item	Dietary treatments (TRT) ¹						SEM	p-value		
	T1	T2	T3	T4	T5	T6		TRT	L	Q
Lactate	60.1 ^b	106.8 ^a	92.1 ^a	40.3 ^b	135.8 ^a	138.3 ^a	6.70	< .0001	< .0001	0.154
Format	0.29 ^b	0.81 ^a	0.55 ^b	0.28 ^b	0.84 ^a	2.22 ^a	0.09	< .0001	< .0001	0.004
Acetate	41.9 ^b	67.6 ^a	62.0 ^a	40.3 ^b	71.4 ^a	74.6 ^a	4.04	< .0001	< .0001	0.609
Propionate	0.92 ^b	7.4 ^a	6.3 ^a	2.2 ^a	1.3 ^b	3.6 ^a	0.25	< .0001	< .0001	0.088
Butyrate	2.95 ^b	3.9 ^a	4.7 ^a	2.4 ^b	4.7 ^a	4.7 ^a	0.21	< .0001	0.002	0.764
Total SCFA	106.2 ^b	186.5 ^a	165.7 ^a	85.5 ^b	214.2 ^a	223.4 ^a	8.37	< .0001	< .0001	0.274

¹Dietary treatments from T1 to T6 supplemented by 0.0%, 0.12%, 0.25%, 0.50%, 0.75%, and 1.0% of gum Arabic, respectively.

^{a,b}Means that do not share a common superscript with control treatment (T1) within a row for each parameter has a significant effect, as determined by the Dunnett test ($p < 0.05$). SEM, standard error of means for diet effect; TRT, dietary treatments effect; L, linear response; Q, quadratic response.

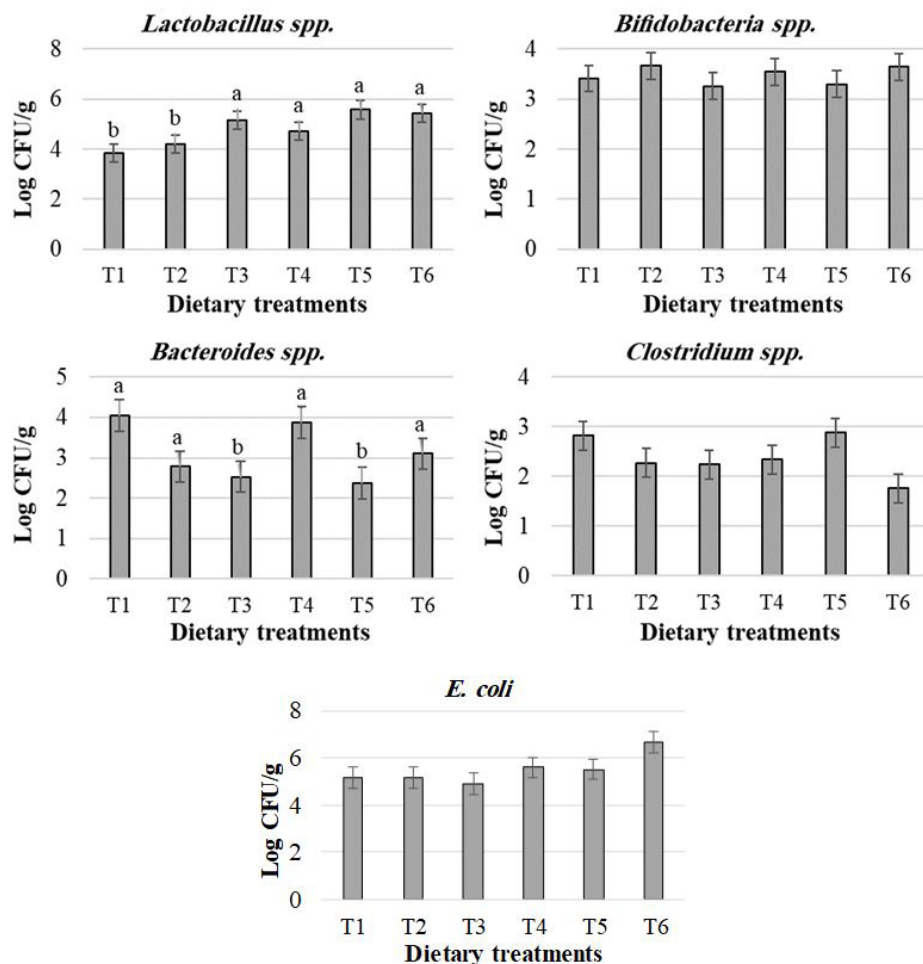


Fig. 1. Effect of dietary treatments on caecal microbiota quantification in the intestine of male broiler chicks. Dietary treatments from T1 to T6 supplemented by 0.0%, 0.12%, 0.25%, 0.50%, 0.75%, and 1.0% of gum Arabic, respectively. ^{a,b}Means that do not share a common superscripted with control treatment (T1) within a row for each parameter has a significant effect, as determined by the Dunnett test ($p < 0.05$). *Lactobacillus* spp. (p -value: TRT = 0.017; L = 0.008; Q = 0.375); *Bifidobacteria* spp. (p -value: TRT = 0.814; L = 0.799; Q = 0.654); *Bacteroides* spp. (p -value: TRT = 0.036; L = 0.024; Q = 0.265); *Clostridium* spp. (p -value: TRT = 0.126; L = 0.123; Q = 0.842); *Escherichia coli* (p -value: TRT = 0.124; L = 0.444; Q = 0.099). TRT, dietary treatments effect; L, linear response; Q, quadratic response.

to T1 ($p < 0.05$) as determined by Dunnett's test. In addition, there was a quadratic response to *IL-1 β* , *IL-12*, and *TNF- α* ($p < 0.05$), but expression of *INF- γ* showed no linear or quadratic response to dietary treatments ($p > 0.05$).

The effects of treatments on mucin-2 protein (*MUC-2*) expression in male broiler chicks are presented in Fig. 3. The fold change in *MUC-2* expression was increased in chicks receiving T2 and decreased in chicks receiving T6 compared to T1 ($p < 0.05$ by Dunnett's test), and a quadratic response with dietary treatments was observed ($p < 0.05$).

The effects of treatments on the expression of secretory *SIgA* in male broiler chicks are presented in Fig. 4. According to Dunnett's test, chicks receiving T4 and T5 had higher *SIgA* expression than T1 ($p < 0.05$), and a linear response with dietary treatments was observed ($p < 0.05$).

Morphological and histometric

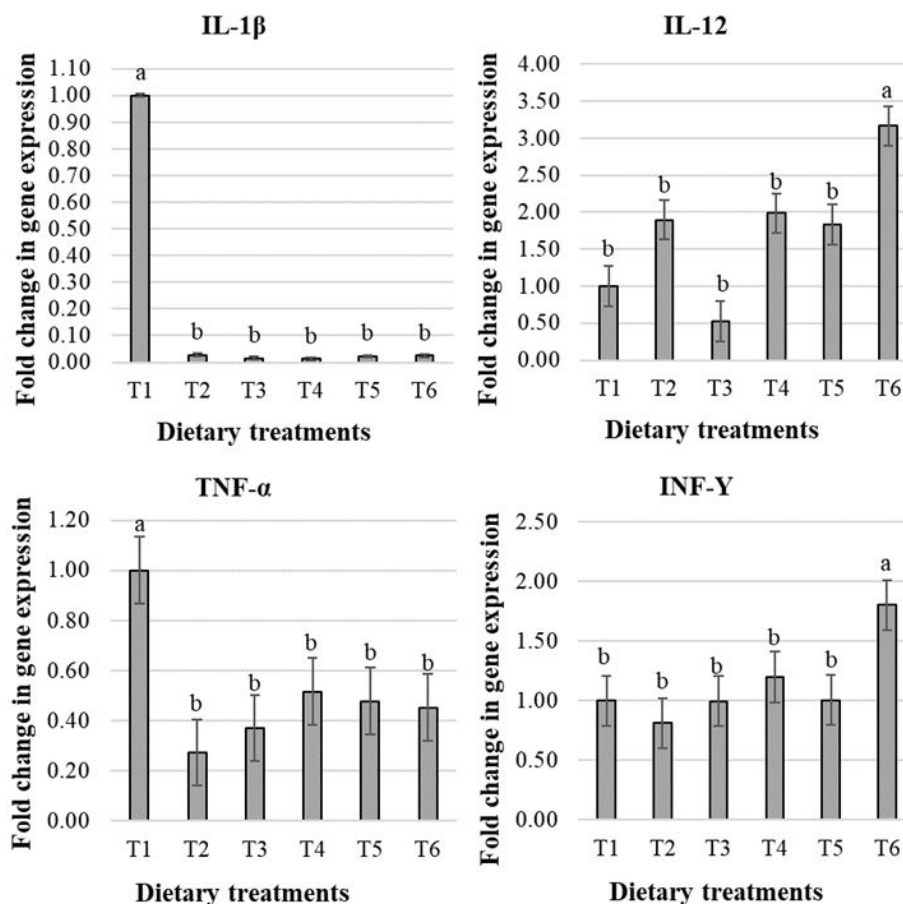


Fig. 2. Effect of dietary treatments on gene expression of pre-inflammatory cytokines in the intestine of male broiler chicks. Dietary treatments from T1 to T6 supplemented by 0.0%, 0.12%, 0.25%, 0.50%, 0.75%, and 1.0% of gum Arabic, respectively. ^{a,b}Means that do not share a common superscripted with control treatment (T1) within a row for each parameter has a significant effect, as determined by the Dunnett test ($p < 0.05$). IL-1 β , interleukin 1 beta (p -value: GA = $<.0001$; L = $<.0001$; Q = $<.0001$); IL-12, interleukin 12 (p -value: GA = $<.0001$; L = 0.006; Q = 0.028); TNF- α , tumor necrosis factor alpha (p -value: GA = 0.011; L = 0.0004; Q = 0.033); INF- γ , interferon gamma; at 10 days (p -value: GA = 0.046; L = 0.497; Q = 0.095). GA, gum Arabic; L, linear response; Q, quadratic response.

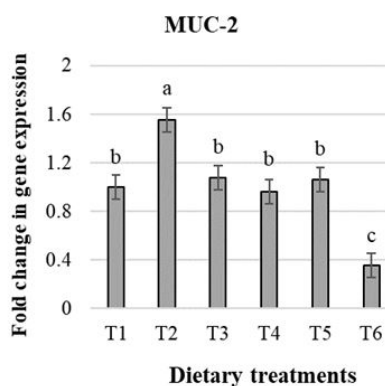


Fig. 3. Effect of dietary treatments on gene expression of mucin-2 protein (MUC-2) in the intestine of male broiler chickens (p -value: TRT = $<.0001$; L = 0.997; Q = 0.001). Dietary treatments from T1 to T6 supplemented by 0.0%, 0.12%, 0.25%, 0.50%, 0.75%, and 1.0% of gum Arabic, respectively. ^{a,b}Means that do not share a common superscripted with control treatment (T1) within a row has a significant effect, as determined by the Dunnett test ($p < 0.05$). TRT, dietary treatments effect; L, linear response; Q, quadratic response.

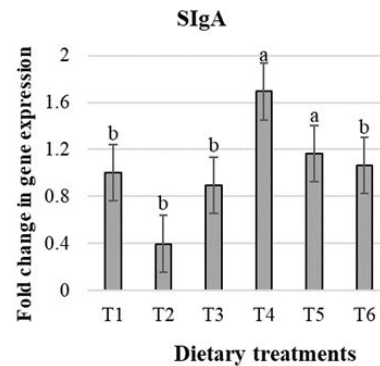


Fig. 4. Effect of dietary treatments on gene expression of secretory immunoglobulin A (SIgA) in the intestine of male broiler chickens (p -value: TRT = 0.031; L = 0.878; Q = 0.541). Dietary treatments from T1 to T6 supplemented by 0.0%, 0.12%, 0.25%, 0.50%, 0.75%, and 1.0% of gum Arabic, respectively. ^{a,b}Means that do not share a common superscript with control treatment (T1) within a row has a significant effect, as determined by the Dunnett test ($p < 0.05$). TRT, dietary treatments effect; L, linear response; Q, quadratic response.

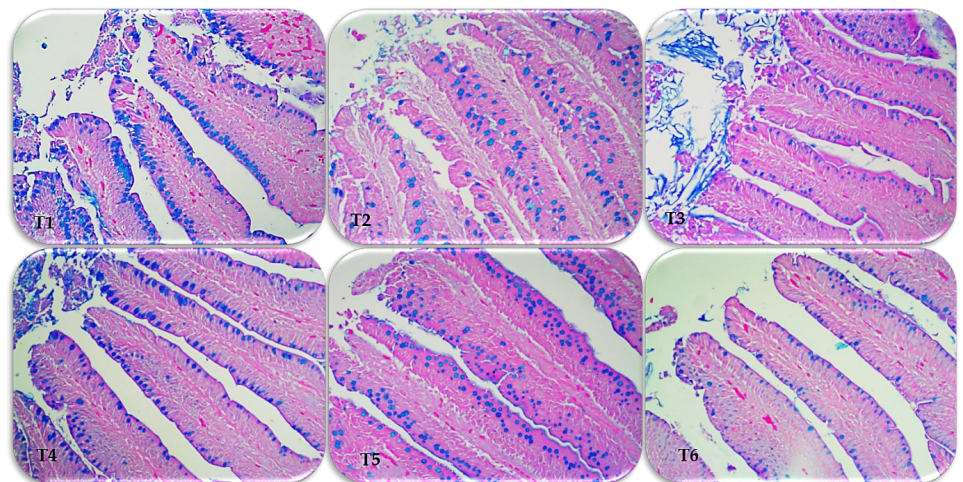


Fig. 5. Photomicrographs to histomorphometric for ileum sections of male broiler chicks stained with hematoxylin, eosin and Alcian blue (200X). Dietary treatments from T1 to T6 supplemented by 0.0%, 0.12%, 0.25%, 0.50%, 0.75%, and 1.0% of gum Arabic, respectively.

The effects of treatments on small intestine morphology in broiler chicks are presented in Table 6. The ratio between weight and length of small intestine was higher in T2 than in chicks receiving the basal diet (T1; $p < 0.05$), and a quadratic response was observed ($p < 0.05$). Furthermore, the histomorphology of other small intestinal fragments was not affected by treatments ($p > 0.05$ by Dunnett's test) and showed no linear or quadratic response ($p > 0.05$).

The effects of treatments on small intestinal histometry of broiler chicks are presented in Table 7 and Fig. 5. In duodenal tissue, VL, SA, and VL/CD were higher in T2 to T6, while LPT was lower compared to T1 ($p < 0.05$ by Dunnett test). Villus width (W) in T3, GC in T2 and ET in T5 were increased compared to T1 ($p < 0.05$). Furthermore, there was no linear or quadratic response ($p > 0.05$) for ET, but there was a quadratic response to VL, W, SA, VL /CD, and LPT, as well as a linear response to GC and GC100 ($p < 0.05$).

In jejunum tissue, chicks fed T2 to T6 showed higher VL, SA, VL /CD, and GC compared with

Table 6. Effect of dietary treatments on small intestine morphology of male broiler chicks at 10 days of age

Item	Dietary treatments ¹⁾						SEM	p-value		
	T1	T2	T3	T4	T5	T6		GA	L	Q
Doud. length (%)	16.8	17.1	16.7	17.0	16.2	16.6	0.44	0.81	0.89	0.99
Doud. weight (%)	19.0	18.5	20.5	19.9	18.0	18.3	0.66	0.20	0.95	0.12
Jej. length (%)	42.6	42.7	43.3	42.8	42.9	42.8	0.60	0.98	0.65	0.96
Jej. weight (%)	47.4	44.2	43.3	43.5	47.2	48.0	1.19	0.04	0.12	0.03
Ile. length (%)	40.6	40.1	40.0	40.2	40.9	40.6	0.77	0.98	0.78	0.97
Ile weight (%)	33.6	37.2	36.2	36.6	34.7	33.6	1.42	0.41	0.20	0.01
Total length (cm)	125.8	122.1	126.8	129.2	123.3	114.2	2.93	0.06	0.41	0.38
Total weight (g)	25.2	28.2	24.0	28.3	24.7	23.1	1.28	0.06	0.74	0.09
SI (%)	9.6	9.2	8.2	9.2	8.7	8.9	0.33	0.13	0.04	0.04
weight/length ratio	0.20 ^b	0.23 ^a	0.18 ^b	0.22 ^b	0.20 ^b	0.20 ^b	0.008	0.01	0.34	0.04

¹⁾Dietary treatments from T1 to T6 supplemented by 0.0%, 0.12%, 0.25%, 0.50%, 0.75%, and 1.0% of gum Arabic, respectively.

^{a,b}Means that do not share a common superscripted with control treatment (T1) within a row for each parameter has a significant effect, as determined by the Dunnett test ($p < 0.05$). SEM, standard error of means for diet effect; GA, gum Arabic levels effect; L, linear response; Q, quadratic response; Doud, duodenum; Jej, jejunum; Ile, ileum; SI, small intestine.

tissue from chicks fed T1 ($p < 0.05$ by Dunnett's test). In addition, W and ET of jejunum tissue were increased when broiler chicks were fed T2 and T4, as well as LPT, which was higher at T2 and lower at T6 than at T1 ($p < 0.05$). Furthermore, there was a quadratic response with treatments in all histometric measurements ($p < 0.05$).

In ileum tissue, chicks fed T2 to T5 had higher VL, SA, and LPT, as well as T2, T3, and T5 had higher W and GC compared with tissue from chicks receiving T1 ($p < 0.05$ by Dunnett test). In addition, VL/CD and ET of ileum tissue were increased in chicks fed T2 and T5 compared to T1 ($p < 0.05$). Furthermore, there was a quadratic response to VL, W, SA, GC, and LPT while linear response to VL/CD and ET with treatments ($p < 0.05$).

DISCUSSION

Modification of the gut microbiota content has an important impact on gut development, physiological functions, and SCFA production in chicks, especially in the post-hatching period [11]. Gum Arabic is a soluble and indigestible dietary fiber in the small intestine of chicks. Therefore, soluble dietary fiber can stimulate the metabolic activities of commensal bacteria to produce SCFAs through a fermentation process, which potentially has a positive effect on host health and thus improves broiler growth performance [18,19]. The current results show that dietary supplementation with gum Arabic improves daily weight gain, feed conversion ratio, and production efficiency index compared to control group (T1). These results are in agreement with those of Tabidi & Ekram [38], who showed that the addition of gum Arabic (0.6%) to the basal diet improved the overall performance of broilers. However, daily feed intake was lower at T2, T3, and T5 (1 to 5 days old) and at T6 (6 to 10 days old). According to Dreher [39], gum Arabic can reduce feed intake by increasing satiety. Administration of 10% gum Arabic for 15 weeks decreased feed intake in mice [40]. Production efficiency index is often used as an expression of the economic status of broiler production [41]. Thus, a higher production efficiency index indicates better performance when chicks receive gum Arabic.

The metabolites of the gut microbiota (SCFAs), which include lactate, format, acetate, propionate, and butyrate, play critical role in maintaining the structural and functional integrity of the gut [42]. According to the current study, broiler chicks fed the diet treatments (T2, T3, T5,

Table 7. Effect of dietary treatments on small intestine histometric of male broiler chicks at 10 days of age

Item	Dietary treatments ¹⁾						SEM	p-value		
	T1	T2	T3	T4	T5	T6		GA	L	Q
Duodenum										
VL (µm)	833 ^b	1,077 ^a	904 ^a	975 ^a	1054 ^a	1025 ^a	16.9	< .0001	< .0001	0.047
W (µm)	148 ^b	159 ^b	162 ^a	154 ^b	157 ^b	137 ^b	3.80	< .0001	0.161	< .0001
SA (mm ²)	0.39 ^b	0.54 ^a	0.46 ^a	0.47 ^a	0.52 ^a	0.44 ^a	0.01	< .0001	< .0001	< .0001
VL/CD	8.8 ^b	13.2 ^a	14.0 ^a	10.2 ^a	12.7 ^a	12.2 ^a	0.30	< .0001	< .0001	< .0001
GC (no)	109 ^b	128 ^a	106 ^b	107 ^b	103 ^b	88 ^c	2.64	< .0001	0.045	0.186
GC100 [†]	6.6 ^a	5.9 ^b	6.0 ^a	5.6 ^b	4.9 ^b	4.3 ^b	0.15	< .0001	< .0001	0.398
ET (µm)	36.8 ^b	35.2 ^b	31.9 ^c	36.9 ^b	41.9 ^a	37.9 ^b	0.86	< .0001	0.511	0.054
LPT (µm)	53.3 ^a	48.2 ^b	42.1 ^b	46.1 ^b	42.5 ^b	47.7 ^b	1.31	< .0001	< .0001	< .0001
Jejunum										
VL (µm)	744 ^b	1108 ^a	997 ^a	918 ^a	996 ^a	1026 ^a	19.2	< .0001	< .0001	< .0001
W (µm)	146 ^b	166 ^a	158 ^b	176 ^a	155 ^b	136 ^b	4.07	< .0001	0.009	< .0001
SA (µm ²)	0.34 ^b	0.58 ^a	0.49 ^a	0.50 ^a	0.48 ^a	0.44 ^a	0.01	< .0001	< .0001	< .0001
VL/CD	8.6 ^b	14.0 ^a	12.6 ^a	13.4 ^a	15.4 ^a	13.9 ^a	0.36	< .0001	< .0001	< .0001
GC (no)	91 ^b	142 ^a	117 ^a	128 ^a	131 ^a	109 ^a	3.82	< .0001	< .0001	< .0001
GC100 [†]	6.2 ^a	6.5 ^a	6.0 ^a	7.2 ^a	7.1 ^a	5.3 ^b	0.27	< .0001	0.517	0.001
ET (µm)	37.3 ^b	44.4 ^a	38.4 ^b	42.8 ^a	38.0 ^b	33.8 ^b	1.07	< .0001	0.058	< .0001
LPT (µm)	53.6 ^b	63.0 ^a	55.2 ^b	51.0 ^b	49.6 ^b	36.1 ^c	1.39	< .0001	0.091	< .0001
Ileum										
VL (µm)	518 ^b	896 ^a	626 ^a	600 ^a	800 ^a	544 ^b	21.4	< .0001	< .0001	< .0001
W (µm)	104 ^b	134 ^a	168 ^a	116 ^b	161 ^a	115 ^b	4.50	< .0001	< .0001	< .0001
SA (µm ²)	0.17 ^b	0.37 ^a	0.33 ^a	0.22 ^a	0.39 ^a	0.20 ^b	0.01	< .0001	< .0001	< .0001
VL/CD	9.2 ^b	11.8 ^a	9.2 ^b	9.2 ^b	12.1 ^a	8.9 ^b	0.35	< .0001	0.010	0.053
GC (no)	77 ^b	101 ^a	82 ^b	111 ^a	119 ^a	89 ^a	2.84	< .0001	< .0001	< .0001
GC100 [†]	7.6 ^b	5.9 ^c	6.7 ^b	9.3 ^a	8.2 ^b	8.2 ^b	0.29	< .0001	0.963	0.695
ET (µm)	28.3 ^b	35.8 ^a	29.2 ^b	30.4 ^b	34.2 ^a	30.8 ^b	0.79	< .0001	< .0001	0.100
LPT (µm)	32.9 ^b	39.5 ^a	38.9 ^a	37.6 ^a	49.6 ^a	39.4 ^b	1.10	< .0001	< .0001	0.002

¹⁾Dietary treatments from T1 to T6 supplemented by 0.0%, 0.12%, 0.25%, 0.50%, 0.75%, and 1.0% of gum Arabic, respectively.

^{a,b}Means that do not share a common superscript with control treatment (T1) within a row for each parameter has a significant effect, as determined by the Dunnett test ($p < 0.05$). SEM, standard error of means for diet effect; GA, gum Arabic levels effect; L, linear response; Q, quadratic response; VL, length; W, width; SA, villus surface area (mm²); VL/CD, villus length/crypt depth; GC, goblet cells; GC/100, goblet cells / 100 µm villi area; ET, epithelial thickness; LPT, lamina propria thickness.

and T6) had higher concentrations of lactate, acetate, propionate, butyrate, and total SCFA in their cecum. These results may be indicative of the ability of gum Arabic to ferment and produce SCFA during the starter phase (10 days). The type of dietary fiber and the degree of fermentation in chicks may have an effect on SCFA concentrations [43]. In a study by Teng and Kim [21], gum Arabic was reported to improve gut health by stimulating lactobacilli in young chicks. *Lactobacillus* spp. have antipathogenic bacterial properties [44]. This property might be the reason why the administration of gum Arabic (T2, T3, T4 and T6) decreased the number of *Clostridium* spp. but had no significant effect compared to the control group (T1). Menconi et al. [45] reported that SCFAs have antimicrobial properties by penetrating the cell membrane of gram-negative bacteria and lowering pH. Al Alawi et al. [46] reported that the antibacterial activity of gum Arabic may be due to a high concentration of nonpolar components. The aqueous extract of gum Arabic inhibited *Clostridium* spp. [47]. *Bacteroides* spp. have strong metabolic activity by efficiently fermenting indigestible polysaccharides to SCFA, thus protecting the host from pathogen infection

[48]. Gum Arabic promotes the growth of *bifidobacteria* in the human intestine [49]. However, some *Bacteroides* species have been reported to encode sugar-degrading enzymes in gum Arabic *in vitro* [50]. Moreover, administration of gum Arabic increased the quantity of *Bifidobacteria* and *Bacteroides* in human intestine and simulation models, respectively [16]. However, our results showed that gum Arabic had no effect on the quantity of *Bifidobacteria* spp. and *E. coli*.

Furthermore, we discovered that the expression of IL-1 and TNF- (T2 to T6), whereas IL-12 and INF- γ was increased in T6. MUC-2 expression was reduced in chicks receiving T6 and increased in T2, while chicks receiving T4 and T5 had higher sIgA expression. Kogut [20] reported that prebiotic fibers may include gum Arabic can act as non-pathogenic antigens by being recognized by immune cell receptors that positively influence host immunity. Prebiotics increased MUC gene expression, which is related to mucin secretion [51]. In our results, the greater number of GCs by gum Arabic could increase mucin expression and synthesis, which plays a critical role as the first line of defense. Mucin can prevent the invasion of pathogens into epithelial cells [52]. In a previous study, feed supplementation with prebiotics (0.2% mannan oligosaccharide [MOS]) increased gene expression of IL-12 and IFN- γ in broilers [53]. Prebiotics can strengthen intestinal barrier function by increasing the number of GCs and immunoglobulin A (IgA)-secreting cells, as shown by Shao et al. [54]. Important immunoglobulin known as secretory sIgA acts as the first line of defense against any pathogenic bacteria on the intestinal mucosa [55]. Kamal et al. [56] found that gum Arabic decreased inflammatory biomarkers in humans. In addition, gum Arabic decreased TNF- α expression in rats [57].

A healthy small intestine with a balanced microbiota is necessary for enhanced growth performance and feed utilization [58,59]. On the other hand, the intestine has a large surface area and shallow crypts for maximum absorption [60]. The most used histometric indicators for assessing the growth and the intestine health in broiler chickens are VL and VL/CD [10,61]. However, the VL is associated with active cell mitosis, and the VL/CD height ratio to increase absorptive capacity and epithelial cell turnover may indicate proliferative activity the villi in addition to the CD height [62,63]. Our results showed that from T2 to T5, ileum histometric parameters (VL, W, SA, VL /CD, GC, ET, and LPT) increased. In principle, a greater VL, SA, and VL/CD ratio could improve intestinal structure, digestion, and nutritional absorption, making this technique a useful method to improve performance and intestine development. In a study by Lan et al. [64] reported that gum Arabic could quantitative change microbiota and improve intestinal structure, thereby enhancing growth performance. Moreover, gum Arabic can improve the integrity of intestinal epithelial in broilers as suggested by Liu et al. [65].

CONCLUSION

Chemical composition results confirmed that gum Arabic contains soluble fiber (galactose, arabinose, glucuronic acid, and rhamnose), which could be used as a feed additive for broilers. Therefore, we conclude that administration of gum Arabic resulted in improvements in overall performance, fermentation metabolites, and a change in microbiota and immune response with improved histomorphometry in the intestine of young chicks. Further studies are needed to determine the possible mechanism of gum Arabic and confirm the optimal level of gum Arabic at different growth stages of broilers.

REFERENCES

1. Kubasova T, Kollarcikova M, Crhanova M, Karasova D, Cejkova D, Sebkova A, et al. Contact

- with adult hen affects development of caecal microbiota in newly hatched chicks. *PLOS ONE*. 2019;14:e0212446. <https://doi.org/10.1371/journal.pone.0212446>
2. Donaldson EE, Stanley D, Hughes RJ, Moore RJ. The time-course of broiler intestinal microbiota development after administration of cecal contents to incubating eggs. *PeerJ*. 2017;5:e3587. <https://doi.org/10.7717/peerj.3587>
 3. Rodrigues DR, Briggs W, Duff A, Chasser K, Murugesan R, Pender C, et al. Cecal microbiome composition and metabolic function in probiotic treated broilers. *PLOS ONE*. 2020;15:e0225921. <https://doi.org/10.1371/journal.pone.0225921>
 4. Smith JA. Broiler production without antibiotics: United States field perspectives. *Anim Feed Sci Technol*. 2019;250:93-8. <https://doi.org/10.1016/j.anifeedsci.2018.04.027>
 5. Xiong W, Wang Y, Sun Y, Ma L, Zeng Q, Jiang X, et al. Antibiotic-mediated changes in the fecal microbiome of broiler chickens define the incidence of antibiotic resistance genes. *Microbiome*. 2018;6:34. <https://doi.org/10.1186/s40168-018-0419-2>
 6. Mohammadigheisar M, Shirley RB, Barton J, Welsher A, Thiery P, Kiarie E. Growth performance and gastrointestinal responses in heavy Tom turkeys fed antibiotic free corn-soybean meal diets supplemented with multiple doses of a single strain *Bacillus subtilis* probiotic (DSM29784). *Poult Sci*. 2019;98:5541-50. <https://doi.org/10.3382/ps/pez305>
 7. Schokker D, Jansman AJM, Veninga G, de Bruin N, Vastenhouw SA, de Bree FM, et al. Perturbation of microbiota in one-day old broiler chickens with antibiotic for 24 hours negatively affects intestinal immune development. *BMC Genom*. 2017;18:241. <https://doi.org/10.1186/s12864-017-3625-6>
 8. Reuben RC, Sarkar SL, Roy PC, Anwar A, Hossain MA, Jahid IK. Prebiotics, probiotics and postbiotics for sustainable poultry production. *Worlds Poult Sci J*. 2021;77:825-82. <https://doi.org/10.1080/00439339.2021.1960234>
 9. Berrococo JD, Kida R, Singh AK, Kim YS, Jha R. Effect of in ovo injection of raffinose on growth performance and gut health parameters of broiler chicken. *Poult Sci*. 2017;96:1573-80. <https://doi.org/10.3382/ps/pew430>
 10. Zhao H, Bai H, Deng F, Zhong R, Liu L, Chen L, et al. Chemically protected sodium butyrate improves growth performance and early development and function of small intestine in broilers as one effective substitute for antibiotics. *Antibiotics*. 2022;11:132. <https://doi.org/10.3390/antibiotics11020132>
 11. Martinez-Guryn K, Hubert N, Frazier K, Urlass S, Musch MW, Ojeda P, et al. Small intestine microbiota regulate host digestive and absorptive adaptive responses to dietary lipids. *Cell Host Microbe*. 2018;23:458-69. <https://doi.org/10.1016/j.chom.2018.03.011>
 12. Ravindran V, Abdollahi MR. Nutrition and digestive physiology of the broiler chick: state of the art and outlook. *Animals*. 2021;11:2795. <https://doi.org/10.3390/ani11102795>
 13. Ahmed AA, Fedail JS, Musa HH, Musa TH, Sifaldin AZ. Gum Arabic supplementation improved antioxidant status and alters expression of oxidative stress gene in ovary of mice fed high fat diet. *Middle East Fertil Soc J*. 2016;21:101-8. <https://doi.org/10.1016/j.mefs.2015.10.001>
 14. Ahmed AA. Health benefits of gum Arabic and medical use. In: Mariod AA, editor. *Gum Arabic: structure, properties, application and economics*. Academic Press; 2018. p. 183-210.
 15. Fedail JS, Ahmed AA, Musa HH, Ismail E, Sifaldin AZ, Musa TH. Gum Arabic improves semen quality and oxidative stress capacity in alloxan induced diabetes rats. *Asian Pac J Reprod*. 2016;5:434-41. <https://doi.org/10.1016/j.apjr.2016.07.014>
 16. Calame W, Weseler AR, Viebke C, Flynn C, Siemensma AD. Gum arabic establishes prebiotic functionality in healthy human volunteers in a dose-dependent manner. *Br J Nutr*.

- 2008;100:1269-75. <https://doi.org/10.1017/S0007114508981447>
17. Gultemirian ML, Corti HR, Perez Chaia A, Apella MC. Fermentation in vitro of a mixture of dietary fibers and cane molasses by the cecal microbiota: application on mineral absorption through the laying hen's colonic epithelium. *Anim Feed Sci Technol.* 2014;191:76-82. <https://doi.org/10.1016/j.anifeedsci.2014.01.019>
 18. Korcz E, Kerényi Z, Varga L. Dietary fibers, prebiotics, and exopolysaccharides produced by lactic acid bacteria: potential health benefits with special regard to cholesterol-lowering effects. *Food Funct.* 2018;9:3057-68. <https://doi.org/10.1039/C8FO00118A>
 19. Qiu Y, Li C, Dong H, Yuan H, Ye S, Huang X, et al. Analysis of key fungi and their effect on the edible quality of HongJun tofu, a Chinese fermented okara food. *LWT.* 2022;172:114151. <https://doi.org/10.1016/j.lwt.2022.114151>
 20. Kogut MH. The gut microbiota and host innate immunity: regulators of host metabolism and metabolic diseases in poultry. *J Appl Poult Res.* 2013;22:637-46. <https://doi.org/10.3382/japr.2013-00741>
 21. Teng PY, Kim WK. Review: Roles of prebiotics in intestinal ecosystem of broilers. *Front Vet Sci.* 2018;5:245. <https://doi.org/10.3389/fvets.2018.00245>
 22. AOAC [Association of Official Analytical Chemists] International. Official methods of analysis of AOAC International. 19th ed. Gaithersburg, MD: AOA C. International; 2012.
 23. Vázquez-Ortiz FA, López-Franco Y, Goycoolea FM. Fractionation and characterization of the monosaccharides from mesquite *Prosopis* spp. and arabic gum by normal, bonded phase, HPLC. *J Liq Chromatogr Relat Technol.* 2006;29:1991-9. <https://doi.org/10.1080/10826070600758183>
 24. Diler Ö, Özil Ö, Bayrak H, Yiğit NÖ, Özmen Ö, Saygın M, et al. Effect of dietary supplementation of sumac fruit powder (*Rhus coriaria* L.) on growth performance, serum biochemistry, intestinal morphology and antioxidant capacity of rainbow trout (*Oncorhynchus mykiss*, Walbaum). *Anim Feed Sci Technol.* 2021;278:114993. <https://doi.org/10.1016/j.anifeedsci.2021.114993>
 25. Goiri I, Ruiz R, Atxaerandio R, Lavin JL, Díaz de Otálora X, García-Rodríguez A. Assessing the potential use of a feed additive based on biochar on broilers feeding upon productive performance, pH of digestive organs, cecum fermentation and bacterial community. *Anim Feed Sci Technol.* 2021;279:115039. <https://doi.org/10.1016/j.anifeedsci.2021.115039>
 26. Aljumaah MR, Alkhalaihi MM, Abudabos AM, Aljumaah RS, Alsaleh AN, Stanley D. *Bacillus subtilis* PB6 based probiotic supplementation plays a role in the recovery after the necrotic enteritis challenge. *PLOS ONE.* 2020;15:e0232781. <https://doi.org/10.1371/journal.pone.0232781>
 27. Gharib-Naseri K, Kheravii SK, Keerqin C, Morgan N, Swick RA, Choct M, et al. Two different *Clostridium perfringens* strains produce different levels of necrotic enteritis in broiler chickens. *Poult Sci.* 2019;98:6422-32. <https://doi.org/10.3382/ps/pez480>
 28. Tajudeen H, Mun J, Ha S, Hosseindoust A, Lee S, Kim J. Effect of wild ginseng on the laying performance, egg quality, cytokine expression, ginsenoside concentration, and microflora quantity of laying hens. *J Anim Sci Technol.* 2023;65:351-64. <https://doi.org/10.5187/jast.2022.e108>
 29. Mushtaq N, Hussain S, Zhang S, Yuan L, Li H, Ullah S, et al. Molecular characterization of alterations in the intestinal microbiota of patients with grade 3 hypertension. *Int J Mol Med.* 2019;44:513-22. <https://doi.org/10.3892/ijmm.2019.4235>
 30. Han J, Wu L, Lv X, Liu M, Zhang Y, He L, et al. Intestinal segment and vitamin D3 concentration affect gene expression levels of calcium and phosphorus transporters in broiler

- chickens. *J Anim Sci Technol.* 2023;65:336-50. <https://doi.org/10.5187/jast.2022.e78>
31. Elnagar R, Elkenany R, Younis G. Interleukin gene expression in broiler chickens infected by different *Escherichia coli* serotypes. *Vet World.* 2021;14:2727-34. <https://doi.org/10.14202/vetworld.2021.2727-2734>
 32. Al-Mufarrej SI, Al-Baadani HH, Fazea EH. Effect of level of inclusion of clove (*Syzygium aromaticum*) powder in the diet on growth and histological changes in the intestines and livers of broiler chickens. *S Afr J Anim Sci.* 2019;49:166-75. <https://doi.org/10.4314/sajas.v49i1.19>
 33. Daneshmand A, Kermanshahi H, Mesgaran MD, King AJ, Ibrahim SA, Klasing KC. Combination of purine and pyrimidine nucleosides influences growth performance, gut morphology, digestive enzymes, serum biochemical indices and immune functions in broiler chickens. *Anim Feed Sci Technol.* 2017;228:186-93. <https://doi.org/10.1016/j.anifeedsci.2017.04.011>
 34. Abbasi Pour AR, Kermanshahi H, Golian A. Effects of conditioning time and activated sodium bentonite on pellet quality, performance, intestinal morphology, and nutrients retention in growing broilers fed wheat-soybean meal diets. *Anim Feed Sci Technol.* 2021;277:114955. <https://doi.org/10.1016/j.anifeedsci.2021.114955>
 35. Al-Baadani HH, Abudabos AM, Al-Mufarrej SI, Alzawqari M. Effects of dietary inclusion of probiotics, prebiotics and synbiotics on intestinal histological changes in challenged broiler chickens. *S Afr J Anim Sci.* 2016;46:157-65. <https://doi.org/10.4314/sajas.v46i2.6>
 36. Azzam MM, Qaid MM, Al-Mufarrej SI, Al-Garadi MA, Albaadani HH, Alhidary IA. *Rumex nervosus* leaves meal improves body weight gain, duodenal morphology, serum thyroid hormones, and cecal microflora of broiler chickens during the starter period. *Poult Sci.* 2020;99:5572-81. <https://doi.org/10.1016/j.psj.2020.08.023>
 37. SAS Institute. SAS users guide: statistics. Cary, NC: SAS Institute; 2008.
 38. Tabidi MH, Ekram KA. Effect of feeding gum Arabic with or without commercial xylem enzyme 500 on the performance of broiler chicks. *World J Pharm Pharm Sci.* 2015;4:1863-72.
 39. Dreher ML. Whole fruits and fruit fiber emerging health effects. *Nutrients.* 2018;10:1833. <https://doi.org/10.3390/nu10121833>
 40. Ahmed AA, Adam Essa ME, Mollica A, Stefanucci A, Zengin G, Ahmed H. Gum Arabic modifies anti-inflammatory cytokine in mice fed with high fat diet induced obesity. *Bioact Carbohydr Diet Fibre.* 2021;25:100258. <https://doi.org/10.1016/j.bcdf.2020.100258>
 41. Huff GR, Huff WE, Jalukar S, Oppy J, Rath NC, Packialakshmi B. The effects of yeast feed supplementation on turkey performance and pathogen colonization in a transport stress/*Escherichia coli* challenge. *Poult Sci.* 2013;92:655-62. <https://doi.org/10.3382/ps.2012-02787>
 42. Louis P, Flint HJ. Formation of propionate and butyrate by the human colonic microbiota. *Environ Microbiol.* 2017;19:29-41. <https://doi.org/10.1111/1462-2920.13589>
 43. Jiménez-Moreno E, González-Alvarado JM, de Coca-Sinova A, Lázaro R, Mateos GG. Effects of source of fibre on the development and pH of the gastrointestinal tract of broilers. *Anim Feed Sci Technol.* 2009;154:93-101. <https://doi.org/10.1016/j.anifeedsci.2009.06.020>
 44. Zhang G, Ma L, Doyle MP. Salmonellae reduction in poultry by competitive exclusion bacteria *Lactobacillus salivarius* and *Streptococcus cristatus*. *J Food Prot.* 2007;70:874-81. <https://doi.org/10.4315/0362-028X-70.4.874>
 45. Menconi A, Kuttappan VA, Hernandez-Velasco X, Urbano T, Matté F, Layton S, et al. Evaluation of a commercially available organic acid product on body weight loss, carcass yield, and meat quality during preslaughter feed withdrawal in broiler chickens: a poultry welfare and economic perspective. *Poult Sci.* 2014;93:448-55. <https://doi.org/10.3382/ps.2013-03444>
 46. Al Alawi SM, Hossain MA, Abusham AA. Antimicrobial and cytotoxic comparative study

- of different extracts of Omani and Sudanese Gum acacia. *Beni-Seuf Univ J Basic Appl Sci.* 2018;7:22-6. <https://doi.org/10.1016/j.bjbas.2017.10.007>
47. Bnuyan IA, Hindi NKK, Jebur MH, Mahdi MA. In vitro antimicrobial activity of gum Arabic (Al Manna and Tayebat) prebiotics against infectious pathogens. *Int J Pharm Pharm Res.* 2015;3:77-85.
 48. Lee SI, Park SH, Ricke SC. Assessment of cecal microbiota, integron occurrence, fermentation responses, and Salmonella frequency in conventionally raised broilers fed a commercial yeast-based prebiotic compound. *Poult Sci.* 2016;95:144-53. <https://doi.org/10.3382/ps/pev322>
 49. Sasaki Y, Komeno M, Ishiwata A, Horigome A, Odamaki T, Xiao JZ, et al. Mechanism of cooperative degradation of gum arabic arabinogalactan protein by *Bifidobacterium longum* surface enzymes. *Appl Environ Microbiol.* 2022;88:e02187-21. <https://doi.org/10.1128/aem.02187-21>
 50. Cartmell A, Muñoz-Muñoz J, Briggs JA, Ndeh DA, Lowe EC, Baslé A, et al. A surface endogalactanase in *Bacteroides thetaiotaomicron* confers keystone status for arabinogalactan degradation. *Nat Microbiol.* 2018;3:1314-26. <https://doi.org/10.1038/s41564-018-0258-8>
 51. Rajani J, Dastar B, Samadi F, Karimi Torshizi MA, Abdulkhani A, Esfandyarpour S. Effect of extracted galactoglucomannan oligosaccharides from pine wood (*Pinus brutia*) on *Salmonella typhimurium* colonisation, growth performance and intestinal morphology in broiler chicks. *Br Poult Sci.* 2016;57:682-92. <https://doi.org/10.1080/00071668.2016.1200013>
 52. Cheled-Shoval SL, Withana Gamage NS, Amit-Romach E, Forder R, Marshal J, Van Kessel A, et al. Differences in intestinal mucin dynamics between germ-free and conventionally reared chickens after mannan-oligosaccharide supplementation. *Poult Sci.* 2014;93:636-44. <https://doi.org/10.3382/ps.2013-03362>
 53. Yitbarek A, Echeverry H, Brady J, Hernandez-Doria J, Camelo-Jaimes G, Sharif S, et al. Innate immune response to yeast-derived carbohydrates in broiler chickens fed organic diets and challenged with *Clostridium perfringens*. *Poult Sci.* 2012;91:1105-12. <https://doi.org/10.3382/ps.2011-02109>
 54. Shao Y, Guo Y, Wang Z. β -1,3/1,6-Glucan alleviated intestinal mucosal barrier impairment of broiler chickens challenged with *Salmonella enterica* serovar Typhimurium. *Poult Sci.* 2013;92:1764-73. <https://doi.org/10.3382/ps.2013-03029>
 55. Mantis NJ, Rol N, Corthésy B. Secretory IgA's complex roles in immunity and mucosal homeostasis in the gut. *Mucosal Immunol.* 2011;4:603-11. <https://doi.org/10.1038/mi.2011.41>
 56. Kamal E, Kaddam LA, Dahawi M, Osman M, Salih MA, Alagib A, et al. Gum arabic fibers decreased inflammatory markers and disease severity score among rheumatoid arthritis patients, phase II trial. *Int J Rheumatol.* 2018;2018:4197537. <https://doi.org/10.1155/2018/4197537>
 57. Ali BH, Al-Husseni I, Beegam S, Al-Shukaili A, Nemmar A, Schierling S, et al. Effect of gum Arabic on oxidative stress and inflammation in adenine-induced chronic renal failure in rats. *PLOS ONE.* 2013;8:e55242. <https://doi.org/10.1371/journal.pone.0055242>
 58. Mountzouris KC, Palamidi I, Paraskeuas V, Griela E, Fegeros K. Dietary probiotic form modulates broiler gut microbiota indices and expression of gut barrier genes including essential components for gut homeostasis. *J Anim Physiol Anim Nutr.* 2019;103:1143-59. <https://doi.org/10.1111/jpn.13112>
 59. Elnesr SS, Alagawany M, Elwan HAM, Fathi MA, Farag MR. Effect of sodium butyrate on intestinal health of poultry – a review. *Ann Anim Sci.* 2020;20:29-41. <https://doi.org/10.2478/aoas-2019-0077>
 60. Ahsan U, Cengiz Ö, Raza I, Kuter E, Chacher MFA, Iqbal Z, et al. Sodium butyrate in chicken nutrition: the dynamics of performance, gut microbiota, gut morphology, and immunity.

- Worlds Poult Sci J. 2016;72:265-75. <https://doi.org/10.1017/S0043933916000210>
61. Ducatelle R, Goossens E, De Meyer F, Eeckhaut V, Antonissen G, Haesebrouck F, et al. Biomarkers for monitoring intestinal health in poultry: present status and future perspectives. *Vet Res.* 2018;49:43. <https://doi.org/10.1186/s13567-018-0538-6>
 62. Awad WA, Ghareeb K, Abdel-Raheem S, Böhm J. Effects of dietary inclusion of probiotic and synbiotic on growth performance, organ weights, and intestinal histomorphology of broiler chickens. *Poult Sci.* 2009;88:49-56. <https://doi.org/10.3382/ps.2008-00244>
 63. Chiang G, Lu WQ, Piao XS, Hu JK, Gong LM, Thacker PA. Effects of feeding solid-state fermented rapeseed meal on performance, nutrient digestibility, intestinal ecology and intestinal morphology of broiler chickens. *Asian-Australas J Anim Sci.* 2010;23:263-71. <https://doi.org/10.5713/ajas.2010.90145>
 64. Lan Y, Verstegen MWA, Tamminga S, Williams BA. The role of the commensal gut microbial community in broiler chickens. *Worlds Poult Sci J.* 2005;61:95-104. <https://doi.org/10.1079/WPS200445>
 65. Liu SD, Song MH, Yun W, Lee JH, Kim HB, Cho JH. Effect of carvacrol essential oils on immune response and inflammation-related genes expression in broilers challenged by lipopolysaccharide. *Poult Sci.* 2019;98:2026-33. <https://doi.org/10.3382/ps/pey575>