

Early Macular Thickness Changes after Trabeculectomy and Combined Phaco-Trabeculectomy

Naveed Nilforushan¹, Shima Loni¹, Parya Abdolalizadeh¹, Arezoo Mirafatabi¹, Mohammad Banifatemi¹, Reza Rakhshan¹, Samira Jafari¹, Navid Abolfathzadeh¹

¹Eye Research Center, The Five Senses Institute, Rassoul Akram Hospital, Iran University of Medical Sciences, Tehran, Iran

Abstract

Purpose: To assess postoperative changes in central retinal thickness (RT) following trabeculectomy and combined phaco-trabeculectomy using spectral domain-optical coherence tomography.

Methods: In a prospective interventional comparative study, 64 consecutive glaucoma patients who underwent trabeculectomy (32 eyes) or phaco-trabeculectomy (32 eyes) were included. A macular thickness map using the Early Treatment Diabetic Retinopathy Study circles of 1 mm, 3 mm, and 6 mm was the standard to evaluate the 9-subfield thickness preoperatively and again at 1 and 3 months after surgery. Four subfields in each of the 3 mm and 6 mm rings were considered parafoveal and perifoveal regions, respectively.

Results: Preoperative measurements were similar in the two groups, except patients in the combined group which were older ($P = 0.002$). The mean RT in the combined phaco-trabeculectomy group at month 1 was significantly higher than baseline measurements at central subfield retinal thickness (CSRT) ($P = 0.01$), temporal ($P = 0.001$), and inferior ($P = 0.04$) parafoveal and temporal ($P = 0.01$), superior ($P = 0.02$), and nasal ($P < 0.001$) perifoveal quadrants; however, RT changes in the trabeculectomy-only group were not statistically significant at months 1 and 3 ($P > 0.05$). The increase in the temporal perifoveal RT of the combined phaco-trabeculectomy group persisted at month 3 ($P = 0.01$), while the RT in other sectors returned to preoperative values. The two treatment groups did not differ in terms of changes in the CSRT over time ($P = 0.37$). In addition, no difference was observed between the treatment groups regarding the parafoveal RTs at each time points ($0.06 \leq P \leq 0.29$).

Conclusions: There was no significant difference in the pattern of changes of CSRT and parafoveal RT between trabeculectomy and combined phaco-trabeculectomy treatment groups up to 3 months after surgery. Some detectable increase in RT in the combined phaco-trabeculectomy will reverse to baseline values 3 months after surgery, except in the temporal perifoveal region.

Keywords: Optical coherence tomography, Phacoemulsification, Retinal thickness, Trabeculectomy

Address for correspondence: Navid Abolfathzadeh, Eye Research Center, The Five Senses Institute, Rassoul Akram Hospital, Iran University of Medical Sciences, Tehran 1445613131, Iran.

E-mail: navid.ab@gmail.com

Submitted: 23-Nov-2021; **Revised:** 15-Jan-2022; **Accepted:** 16-Jan-2022; **Published:** 26-Jul-2022

INTRODUCTION

Central macular thickness changes following intraocular surgeries have been shown to impair visual outcomes even in uncomplicated cases.¹⁻⁵ Acute reduction of intraocular pressure (IOP) after glaucoma filtering surgery could result in reversible central macular thickening and retinal changes.⁵⁻⁹ Such macular thickening after glaucoma filtering surgery could

be a physiological reaction to the stress of the retina after a sudden reduction of IOP.^{7,8} Although many other etiological factors are associated with the development of macular changes, the most accepted explanation is the diffusion of inflammatory mediators from the anterior chamber into the vitreous cavity, causing secondary leakage from retinal blood vessels.^{6,8} In addition, IOP reduction increases postoperative

This is an open access journal, and articles are distributed under the terms of the Creative Commons Attribution-NonCommercial-ShareAlike 4.0 License, which allows others to remix, tweak, and build upon the work non-commercially, as long as appropriate credit is given and the new creations are licensed under the identical terms.

For reprints contact: WKHLRPMedknow_reprints@wolterskluwer.com

How to cite this article: Nilforushan N, Loni S, Abdolalizadeh P, Mirafatabi A, Banifatemi M, Rakhshan R, *et al.* Early macular thickness changes after trabeculectomy and combined phaco-trabeculectomy. *J Curr Ophthalmol* 2022;34:160-6.

Access this article online

Quick Response Code:



Website:
www.jcurrophthalmol.org

DOI:
10.4103/joco.joco_333_21

ocular blood flow, especially in the central retinal area and possibly even the choroid.¹⁰⁻¹² Studies have shown no difference in macular changes between patients treated with or without adjunctive antifibrotic medications, including mitomycin C (MMC) or 5-fluorouracil (5-FU), after trabeculectomy.^{8,9} In addition, diabetes mellitus (DM) or prostaglandin drops usage before surgery has not been shown to have any impact on these postoperative macular changes.^{8,13} However, some studies have shown that early postoperative changes in macular thickness can be different, defined by spectral domain-optical coherence tomography (SD-OCT), in different quadrants of the macula.¹⁴

Combined phacoemulsification and trabeculectomy is a commonly performed procedure for certain glaucoma patients with significant cataracts.¹⁵ However, studies evaluating the short-term effects on central macular thickness after combined phacoemulsification and trabeculectomy are lacking. Furthermore, it is not known if adding a procedure, such as phacoemulsification, to trabeculectomy would affect the macular thickness more than glaucoma surgery alone. The aim of our study was to assess early postoperative changes in the central retinal thickness (RT) following trabeculectomy and phaco-trabeculectomy surgery.

METHODS

This prospective interventional comparative case series was performed from 2014 to 2019 at the Glaucoma clinic, Rassoul Akram Hospital, Iran University of Medical Sciences, Tehran, Iran. The study protocol adhered to the tenets of the Declaration of Helsinki. Written informed consents were obtained, and the Ethics Committee of the Iran University of Medical Sciences approved the study design (IR.IUMS.REC.1394.8911215327). Patients with inadequately controlled glaucoma with maximally tolerated medical therapy or intolerance to glaucoma medications who were scheduled for combined phaco-trabeculectomy or trabeculectomy alone were included. Patients younger than 18 years old, pregnant or nursing mothers with a previous history of intraocular surgery (except phacoemulsification more than 6 months prior to the study), diabetic retinopathy or macular edema of any stage, retinal vascular disease, chronic or recurrent uveitis, neovascular glaucoma, ocular surface infection within 2 weeks of surgery, any kind of intravitreal injections or other intraocular surgeries during the study period were excluded from the study. Moreover, patients with intraoperative or postoperative complications including hypotony maculopathy, vitreoretinal interface disorders, choroidal detachment, papillopathy, and complicated cataract surgery which needed significant iris manipulation or any more surgical intervention were excluded.

In the preoperative assessment, all subjects underwent a comprehensive ophthalmic examination, including slit-lamp biomicroscopy, IOP measurement by a calibrated Goldmann applanation tonometer, dilated funduscopy, gonioscopy, and same day macular SD-OCT (Spectralis, Heidelberg Engineering, Carlsbad, CA, USA). A macular thickness map using Early

Treatment Diabetic Retinopathy Study circles of 1 mm, 3 mm, and 6 mm was the standard to evaluate the 9-subfield thickness. Four subfields in each of the 3 mm and 6 mm rings were considered parafoveal and perifoveal regions, respectively.

In combined phaco-trabeculectomy, standard phacoemulsification from the temporal site with intraocular lens insertion was performed, and surgical wounds were closed using 10/0 nylon sutures. Then a standard trabeculectomy was carried out. The surgical procedure of trabeculectomy for each patient included a fornix-based trabeculectomy with a half-thickness trapezoidal scleral flap (3 mm × 2 mm) in the superonasal quadrant. After creating the scleral flap, MMC (0.2 mg/mL) was applied using multiple thin sponges under the scleral flap and between the sclera and Tenon capsule for 2 min. Then the sponges were removed, and the surgical field was irrigated with at least 50 ml of balanced salt solution. Keratectomy was performed with a Kelly-Descemet punch, and the peripheral iridectomy was performed with Vannas scissors. The scleral flap was closed with two 10-0 nylon sutures using the releasable technique. The conjunctival closure was carried out using 10-0 nylon sutures. In both groups, from postoperative day 1, patients were treated with ciprofloxacin eye drop (four times a day for 1–2 weeks) and betamethasone eye drop every 2 h for 2 weeks. Betamethasone was tapered off slowly over the next 8–10 weeks. Releasable sutures were removed if needed based on the postoperative IOP, individual target IOP, and bleb morphology in each patient.

Patients were followed up on day 1, 1-week, 1-month, and 3-month intervals after the surgery. A window of 10 days was allowed for the 1 and 3-month visits. IOP, types of medications, slit-lamp biomicroscopy, bleb characteristics, funduscopy as well as complications were assessed and recorded at each visit. Macular SD-OCT was done for all subjects at the 1 and 3-month visits.

Statistical analysis

Statistical analyses were performed using SPSS software version 22 (SPSS, Inc., Chicago, IL, USA). A $P < 0.05$ was considered statistically significant. Baseline characteristics of the two groups were compared using a Chi-square (categorical variables) and Mann-Whitney U tests (continuous variables). A two-way repeated measure mixed model analysis of variance (ANOVA) was used to simultaneously test three null hypotheses of the study: (1) all mean values of RT at different time points are the same (referred to as the main effect of time); (2) all mean values of RT in different groups are the same (referred to as the main effect of surgical intervention); and (3) there is no interaction between time and surgical intervention (the two groups do not differ in their degree of change in the RT over time). Therefore, we evaluated whether the two surgeries affect the RT differently over time by considering intervention × time interactions as our primary outcome measure. The changes of RT at the baseline and follow-up examinations in each group of the study (intragroup) were analyzed by one-way repeated measure ANOVA and *post hoc* tests. Furthermore, we evaluated the test-retest variability of the OCT machine by considering

the proportion of the patients showing at least a 5% increase in macular thickness at postoperative months 1 and 3 in both groups, compared with Fisher’s exact test. The sample size was calculated based on the one-way ANOVA formula using G*Power software (developer by heinrich-heine university, Düsseldorf, Germany). By assuming $\alpha = 0.05$, power = 80%, the standardized Cohen effect size ($f = 0.40$), and a 10% dropout rate, the final sample size of each group was estimated at 30 patients.

RESULTS

Sixty-four eyes of 64 patients were enrolled. All of the subjects were phakic in the trabeculectomy group. The baseline demographics were similar between the two groups, except the patients in the combined phaco-trabeculectomy group were slightly older ($P = 0.002$) [Table 1]. Furthermore, there was no statistically significant difference between the two groups, with regard to the main outcome measures at baseline, including central subfield retinal thickness (CSRT) ($P = 0.88$) as well as parafoveal ($0.58 \leq P \leq 0.89$) and perifoveal ($0.25 \leq P \leq 0.60$) RT.

The mean baseline IOP was 22.96 (standard deviation [SD] = 9.75) mmHg (ranging from 10 to 50 mmHg) in the combined phaco-trabeculectomy group and significantly decreased to 11.96 mmHg (SD = 3.97, $P < 0.001$, ranging from 6 to 20 mmHg) at 1 month and further to 12.73 mmHg (SD = 7.52, $P < 0.001$, ranging from 6 to 47 mmHg) at 3 months. In the trabeculectomy-only group, the IOP decreased from 22.87 (SD = 9.03) mmHg (ranging from 10 to 50 mmHg) to 13.00 mmHg (SD = 4.53, $P < 0.001$, ranging from 4 to 20 mmHg) at 1 month and 10.63 mmHg (SD = 3.92, $P < 0.001$, ranging from 4 to 27 mmHg) at 3 months. There were two patients with hypotony (IOP ≤ 5 mmHg) at 1 month, including one with an IOP of 4 mmHg. At month 3, only one patient had hypotony with an IOP of 4 mmHg.

Effects of surgical intervention on central subfield retinal thickness: Based on the mixed model analysis, no significant interaction was detected between time and intervention groups for CSRT ($P = 0.25$); therefore, the two treatment groups did not differ in terms of changes in CSRT over time. The CSRT was not different between treatment groups ($P = 0.37$) at each time point. Tables 2 and 3 show the changes of the CSRT in the follow-up intervals. Although the changes of CSRT in the two groups were similar at 1 month ($P = 0.49$) and 3 months ($P = 0.41$) [Table 3], the increase of CSRT was significant in the combined phaco-trabeculectomy group at 1 month ($P = 0.01$), but mostly reversed to the preoperative value at 3 months ($P = 0.15$). Figure 1 illustrates the trend of the changes of CSRT at preoperative, 1 and 3 months in trabeculectomy and phaco-trabeculectomy groups. In comparison to baseline values, there was at least a 5% increase in CSRTs in nearly 10% of the patients in both groups [Table 4]. Moreover, the proportion of patients with significant

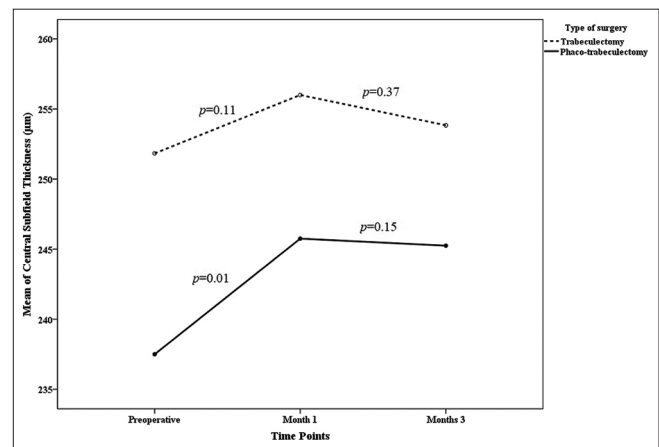


Figure 1: Trend of the changes of central subfield retinal thickness at preoperative, 1 and 3 months in trabeculectomy and phaco-trabeculectomy groups

Table 1: Baseline characteristics of 64 patients with glaucoma

Variables	Trabeculectomy (n=32), n (%)	Trabeculectomy + phacoemulsification (n=32), n (%)	P
Age (years)	57.45 (14.10)	67.72 (9.10)	0.002 ^a
Sex (female %)	9/32 (28.1)	8/32 (25.0)	0.78 ^b
Laterality (OD%)	17/32 (53.1)	18/32 (56.3)	0.80 ^b
Diabetes (%)	5/32 (16.1)	3/32 (9.4)	0.47 ^b
Systemic hypertension (%)	7/32 (22.6)	11/32 (34.4)	0.30 ^b
Previous PI (%)	4/32 (12.5)	6/32 (18.8)	0.46 ^b
Axial length (mm)	23.51 (0.44)	23.19 (0.61)	0.91 ^c
Visual field indices			
Median deviation	-14.67 (10.55)	-17.21 (9.08)	0.94 ^c
Pattern SD	6.29 (1.32)	5.03 (3.78)	0.22 ^c
Preoperative IOP (mmHg)	22.87 (9.23)	22.96 (9.75)	0.94 ^a
Type of glaucoma			
POAG	14/32 (43.8)	18/32 (56.3)	0.32 ^b
PACG	18/32 (56.3)	14/32 (43.8)	

^aMann-Whitney U-test, ^bChi-square test, ^cIndependent sample t-test. IOP: Intraocular pressure, SD: Standard deviation, POAG: Primary open-angle glaucoma, PACG: Primary angle-closure glaucoma, PI: Peripheral iridectomy

Table 2: Macular thickness profiles of 64 patients with glaucoma at preoperative, 1 and 3 months following trabeculectomy with (n=32) or without phacoemulsification (n=32)

Variables	Follow-up times	Trabeculectomy (n=32)			Trabeculectomy with phacoemulsification (n=32)			Difference between two groups at each time point	Difference between total pattern of two groups
		Mean (SD)	P ^a	P ^b	Mean (SD)	P ^a	P ^b		
Central subfield thickness (µm)	Preoperative	251.83 (20.03)	-	0.16	237.50 (21.63)	-	0.10	0.88	0.25
	1 month	256.00 (17.39)	0.11		245.75 (20.16)	0.01		0.31	
	3 months	253.83 (16.42)	0.37		245.25 (15.20)	0.15		0.42	
Temporal parafoveal thickness (µm)	Preoperative	300.00 (19.06)	-	0.54	293.25 (12.74)	-	0.26	0.81	0.31
	1 month	301.67 (20.26)	0.39		299.75 (11.76)	0.001		0.33	
	3 months	301.00 (19.70)	0.58		295.00 (14.17)	0.70		0.13	
Superior parafoveal thickness (µm)	Preoperative	308.67 (22.41)	-	0.73	310.25 (12.76)	-	0.33	0.89	0.73
	1 month	310.17 (23.90)	0.41		314.50 (16.66)	0.23		0.86	
	3 months	310.17 (19.93)	0.60		313.00 (17.80)	0.47		0.37	
Nasal parafoveal thickness (µm)	Preoperative	313.50 (16.91)	-	0.30	308.50 (14.62)	-	0.12	0.87	0.56
	1 month	316.33 (19.11)	0.29		313.75 (15.09)	0.08		0.46	
	3 months	316.50 (18.52)	0.26		311.25 (16.07)	0.33		0.42	
Inferior parafoveal thickness (µm)	Preoperative	310.50 (18.57)	-	0.94	297.75 (15.71)	-	0.19	0.58	0.11
	1 month	311.00 (19.56)	0.75		308.00 (15.00)	0.046		0.56	
	3 months	310.50 (22.06)	>0.99		303.00 (16.55)	0.46		0.77	
Temporal perifoveal thickness (µm)	Preoperative	261.17 (22.94)	-	0.31	260.00 (9.62)	-	0.02	0.50	0.02
	1 month	263.00 (24.02)	0.24		267.25 (9.91)	0.01		0.69	
	3 months	262.83 (23.68)	0.28		267.25 (9.67)	0.01		0.19	
Superior perifoveal thickness (µm)	Preoperative	269.00 (26.41)	-	0.44	276.75 (15.78)	-	0.02	0.60	0.007
	1 month	270.17 (28.36)	0.35		284.25 (17.97)	0.02		0.30	
	3 months	270.00 (27.33)	0.27		281.50 (17.29)	0.05		0.46	
Nasal perifoveal thickness (µm)	Preoperative	286.17 (24.49)	-	0.77	281.75 (19.38)	-	0.04	0.58	0.06
	1 month	287.17 (27.04)	0.64		290.25 (19.96)	<0.001		0.69	
	3 months	287.17 (27.08)	0.68		286.75 (23.11)	0.11		0.25	
Inferior perifoveal thickness (µm)	Preoperative	260.83 (21.96)	-	0.65	270.00 (11.20)	-	0.63	0.25	0.71
	1 month	262.17 (23.00)	0.38		274.25 (15.67)	0.44		0.39	
	3 months	261.17 (22.44)	0.83		272.00 (20.22)	0.82		0.11	

^aOne-way ANOVA repeated measure *post hoc* tests for comparing with preoperation, ^bOne-way ANOVA repeated measure Greenhouse-Geisser correction to evaluate the changes of thickness over time in each group, ^cIndependent student *t*-test, ^dOne-way ANOVA repeated measure Greenhouse-Geisser correction to evaluate the interaction between time and surgery. SD: Standard deviation, ANOVA: Analysis of variance

thickening was similar between diabetes and nondiabetes subjects ($0.58 \leq P \leq 0.99$).

Effects of surgical intervention on parafoveal retinal thickness: There was no significant difference between the two treatment groups in terms of the changes of parafoveal RTs over time. In addition, no difference was observed between the treatment groups regarding the parafoveal RTs at each time point. The main effect of time was also not statistically significant in all quadrants ($0.06 \leq P \leq 0.29$). Tables 2 and 3 show the trend of changes in the parafoveal RTs over time. The inferior and temporal parafoveal RTs increased transiently at 1 month and then decreased at 3 months in the combined phaco-trabeculectomy group, while changes in the parafoveal RTs were not significant in the trabeculectomy-only group ($0.26 \leq P \leq 0.99$). Furthermore, the changes of the inferior and temporal parafoveal RT in the combined phaco-trabeculectomy group were significantly more than the changes in the trabeculectomy-only group at 1 month (both quadrants) and 3 months (temporal quadrant only) [Table 3].

Effects of surgical intervention on perifoveal retinal thickness: There was a significant difference between the two groups in terms of temporal ($P = 0.020$) and superior ($P = 0.007$) perifoveal RT changes over time [Figure 1]. The main effect of time was also significant in the temporal ($P < 0.001$), superior ($P = 0.001$), and nasal ($P = 0.02$) quadrants, but the main effect of intervention groups was not significant ($0.43 \leq P \leq 0.97$). Overall, RT in the superior, temporal, and nasal perifoveal quadrants changed significantly over time in the combined phaco-trabeculectomy group. The combined phaco-trabeculectomy group showed significant thickening in all regions of perifoveal RTs, except the inferior quadrant [Table 2]. The perifoveal RT returned to the preoperative measures in the superior ($P = 0.05$) and nasal quadrants ($P = 0.11$) while it remained at higher levels in the temporal quadrant ($P = 0.01$) till month 3. The combined phaco-trabeculectomy group also had more increase of the perifoveal RT in the temporal, superior, and nasal RTs at 1 month compared to the trabeculectomy-only group [Table 3].

Table 3: Comparing the changes of macular thickness in 64 patients with glaucoma at preoperative, 1 and 3 months following trabeculectomy with (n=32) or without phacoemulsification (n=32)

Variables	Follow-up times	Trabeculectomy		Trabeculectomy with phacoemulsification		P ^a
		Mean (SD)	Percentage	Mean (SD)	Percentage	
Changes of central subfield thickness (µm)	1 month	1.80 (5.51)	0.71	4.13 (8.46)	1.74	0.49
	3 months	2.00 (5.63)	0.79	5.40 (19.63)	2.27	0.41
Changes of temporal parafoveal thickness (µm)	1 month	1.20 (3.49)	0.40	5.50 (8.35)	1.88	0.03
	3 months	0.68 (5.14)	0.22	7.50 (15.26)	2.56	0.03
Changes of superior parafoveal thickness (µm)	1 month	0.80 (3.55)	0.26	5.88 (8.36)	1.89	0.10
	3 months	0.18 (11.30)	0.06	5.93 (13.46)	1.91	0.09
Changes of nasal parafoveal thickness (µm)	1 month	1.90 (4.77)	0.61	8.50 (9.93)	2.76	0.08
	3 months	0.93 (5.63)	0.30	5.46 (15.93)	1.77	0.16
Changes of inferior parafoveal thickness (µm)	1 month	0.40 (4.14)	0.12	8.75 (8.94)	2.94	0.01
	3 months	1.79 (6.35)	0.58	6.50 (15.84)	2.18	0.15
Changes of temporal perifoveal thickness (µm)	1 month	1.10 (3.00)	0.42	9.75 (8.76)	3.75	0.01
	3 months	0.38 (7.22)	0.14	4.11 (12.33)	1.58	0.19
Changes of superior perifoveal thickness (µm)	1 month	0.60 (3.17)	0.22	7.63 (7.09)	2.76	0.005
	3 months	0.07 (7.48)	0.02	2.30 (11.69)	0.83	0.38
Changes of nasal perifoveal thickness (µm)	1 month	0.10 (4.86)	0.03	8.75 (7.00)	3.11	0.006
	3 months	1.26 (9.94)	0.44	3.82 (8.56)	1.35	0.05
Changes of inferior perifoveal thickness (µm)	1 month	1.80 (3.49)	0.69	6.25 (9.87)	2.31	0.20
	3 months	2.08 (12.58)	0.80	1.31 (14.37)	0.49	0.37

^aIndependent student *t*-test. All comparisons were made in comparison to the baseline measurements. SD: Standard deviation

Table 4: Proportion of patients showing at least five percent increase in the macular thickness at postoperative months 1 and 3

Variable	Trabeculectomy, n (%)	Trabeculectomy with phacoemulsification, n (%)	P ^a
Central subfield thickness	2/32 (6.3)	5/32 (15.6)	0.43
Temporal parafoveal thickness	0/32 (0)	6/32 (18.8)	0.02
Superior parafoveal thickness	1/32 (3.1)	4/32 (12.5)	0.35
Nasal parafoveal thickness	0/32 (0)	4/32 (12.5)	0.11
Inferior parafoveal thickness	1/32 (3.1)	5/32 (15.6)	0.20
Temporal perifoveal thickness	1/32 (3.1)	5/32 (15.6)	0.20
Superior perifoveal thickness	0/32 (0)	5/32 (15.6)	0.05
Nasal perifoveal thickness	1/32 (3.1)	4/32 (12.5)	0.36
Inferior perifoveal thickness	0/32 (0)	4/32 (12.5)	0.11

^aFisher’s exact test

In subjects with primary open-angle glaucoma (OAG), there were no differences between the baseline RTs and their changes at 1 and 3 months for the trabeculectomy and phaco-trabeculectomy groups, except in the temporal perifoveal area at 1 month. The phaco-trabeculectomy group had more increase in RT than the trabeculectomy group ($P = 0.02$). However, in subjects with primary angle-closure glaucoma, the increase of RTs in the temporal and inferior perifoveal areas were higher in the phaco-trabeculectomy groups than the trabeculectomy groups at 1 and 3 months (see supplement digital content 1 showing the subgroup analysis between primary open-angle and angle-closure glaucoma following trabeculectomy with and without phacoemulsification).

Correlation between changes of intraocular pressure and changes of retinal thickness: Changes of CSRT ($r_s = -0.83$, $P = 0.04$) and temporal parafoveal RT ($r_s = -0.81$, $P = 0.049$)

were significantly correlated with changes of IOP at 1 month. Further reduction of IOP caused more increase in postoperative RT. Other parafoveal and perifoveal sectors did not have a significant correlation with changes of IOP ($0.08 \leq P \leq 0.91$). No significant correlation between changes of RT and IOP was found at 3 months ($0.07 \leq P \leq 0.72$).

DISCUSSION

Our study investigated the central RT changes by SD-OCT after trabeculectomy and combined phaco-trabeculectomy. We did not find a significant difference in the pattern of changes of CSRT between the treatment groups up to 3 months after surgery. In addition, the two treatment groups did not show any difference in terms of the changes of parafoveal RTs over the study period. However, the pattern of changes was statistically significantly different in the temporal and superior perifoveal

RTs. The changes in the inferior and temporal parafoveal RT in the combined phaco-trabeculectomy group were significant compared to changes in the trabeculectomy-only group at 1 month (both quadrants) and 3 months (temporal quadrant only). The combined phaco-trabeculectomy group also had an increase in the perifoveal RTs in the temporal, superior, and nasal quadrants at 1 month compared to the trabeculectomy-only group.

There is controversy in the literature regarding changes in macular thickness after trabeculectomy. These contradictory results could be attributed to the different study populations in terms of age, type of glaucoma, the severity of glaucoma as well as surgical procedures, postoperative IOP changes, and follow-up intervals. In a small sample study (10 subjects including 1 tube shunt, 2 combined phaco-trabeculectomy, 7 trabeculectomy), Pitale *et al.*⁶ showed an increase in the total macular thickness in 70% of their cases. Their study included patients who had macular SD-OCT scans within 1 year prior to and up to 2 years following surgery. They did not find a correlation between the amount of IOP reduction and the change in macular thickness. Kadziauskien *et al.*⁵ looked at 106 eyes and found that trabeculectomy, with or without 5-FU, may induce a slight postoperative macular thickening, which is more pronounced in the early postoperative period. However, in that study, the macula remained thicker only at the central and inner nasal subfields 6 months after surgery. They concluded that IOP reduction plays an important role in the thicker postoperative macula; however, inflammatory mechanisms should also be considered. Huq Ridoy *et al.*⁷ studied 25 OAG patients before and 1 and 3 months after trabeculectomy. Macular thickness increased from 229.82 μm preoperatively to 243.88 μm at 1 month and 233.52 μm at 3 months postoperatively, and neither was statistically significant. These findings are comparable to our study, which found an increase in CSRT from 252 μm preoperatively to 256 μm at month 1 and 253 μm at 3 months postoperatively in the trabeculectomy-only group [Table 2].

In a prospective study on 44 patients (45 eyes), Karasheva *et al.*⁹ investigated the thickness of the fovea and the extrafoveal retina using OCT, before and after glaucoma filtration surgery. They excluded patients undergoing combined cataract surgery and trabeculectomy. Central macular thickness changed from 164 μm before surgery to 173 μm after 1 month and 165 μm 3 months after surgery. However, they did not find a statistically significant change in the mean thickness of the extrafoveal retina. In addition, there was no significant correlation between the reduction of IOP and RT.⁹ Similar to our study, they included patients with different etiology of glaucoma. Sesar *et al.*⁸ found a slight subclinical increase in the macular thickness after uncomplicated trabeculectomy with or without MMC in 32 patients (34 eyes) with OAG. They followed their patients up to 1 month after surgery and considered their findings to be related to the reduction of IOP. They had 7 diabetic patients who did not show significant variation in outcomes in comparison to nondiabetic cases.

There have been reports that the usage of prostaglandin analogs may lead to disruption of the blood-aqueous barrier and subsequent development of cystoid macular edema in patients with pseudophakia or aphakia.¹⁶ Sesar *et al.*⁸ showed that there was no significant difference in the change of macular thickness in patients who had used topical prostaglandins compared with those who had used other topical medications. Such findings in terms of the neutral effect of DM status and prostaglandin drops usage on postoperative macular changes were confirmed in another study by Drukteinienė *et al.*¹³ They studied 93 eyes from 90 patients who underwent trabeculectomy and followed them up to 12 months. They found mild macular thickening, which was more pronounced in the early postoperative period (6 months).

In nearly 10% of the patients in our study, we found at least a 5% increase in CSRT in comparison to the baseline in both groups [Table 4]. In another study, Pardianteo *et al.*¹⁷ studied 27 eyes of 27 subjects who underwent uncomplicated phacoemulsification. They evaluated all nine areas of the macula by SD-OCT preoperatively and 2 months postoperatively. They showed that the thickness of three quadrants significantly increased in the paracentral macular area (superior, temporal, and nasal). Furthermore, they found a significant increase in the peripheral macular thickness in the superior and temporal areas.¹⁷ In comparison, in our study, the changes of the inferior and temporal parafoveal RT in the combined phaco-trabeculectomy group were significantly more than the changes in the trabeculectomy-only group at 1 month (both quadrants) and 3 months (temporal quadrant only). The combined phaco-trabeculectomy group also had more increase in the perifoveal RTs in the temporal, superior, and nasal quadrants at postoperative month 1 in comparison to the trabeculectomy-only group, which is again compatible with the findings from Pardianteo *et al.* [Table 3]. Kojima *et al.*¹¹ evaluated the changes in the choroidal area after IOP reduction following trabeculectomy on 74 eyes using enhanced depth imaging OCT. The authors concluded a reduction in the IOP after trabeculectomy surgery will lead to an increase in the macular and also peripapillary choroidal thickness. They excluded patients with significant cataracts from the study.¹¹

During the first few months after the filtering surgeries, patients may not have good visual acuity due to different causes such as fluctuations in the IOP, usage of mydriatic eyedrops, postoperative induced astigmatism and corneal tear-film irregularity; therefore, many detectable changes in the visual acuity may be transient and unreliable. In addition, there are many patients with advanced glaucoma and very low visual acuity before the surgery which makes this variable hard to evaluate. In contrast to visual acuity, OCT is an objective, reliable, and accurate test and can be easily performed in nearly all patients. Intraocular surgeries may induce macular changes such as thickening and edema which is more frequent during 6–8 weeks after the surgery with or without detectable visual symptoms. Hence, OCT findings would give more informative and can be a good surrogate to subjective tests as far as the visual acuity is not captured during the first 3 months of trabeculectomy or combined phaco-trabeculectomy. Based on

our findings, which showed no significant anatomical changes in the macular area, we now know that if any changes in the visual acuity happen during the first 3 months of the surgery, it would less likely to be related to the structural changes in the macula, and other causes should be considered.

Our study has its strengths and limitations. We evaluated the changes in postoperative RT in patients who underwent trabeculectomy and combined phaco-trabeculectomy separately. In addition, the prospective nature of the study and the inclusion of a uniform group of glaucoma patients for each procedure are among the strengths of this study. However, the short duration of follow-up could be a limitation because it has been shown that changes in RT may last up to 6 months postoperatively.¹⁸ The absence of a control phacoemulsification group is another limitation as RT may increase in the early postoperative period after cataract surgery and affect the findings in the combined phaco-trabeculectomy group. Furthermore, the clinical relevance of the findings could be more valuable if the proper visual acuity data could be available. On the other hand, since the quality of obtained OCT images would improve after concomitant cataract surgery in the combined phaco-trabeculectomy group, this could affect the final results and create an unavoidable bias in the interpretation of results. The two groups did not match in terms of age, which could have affected the results. We recommend future studies with a longer duration of follow-up and consideration of phacoemulsification group as a control, also evaluation of macular changes using the OCT angiography method.

In conclusion, macular thickness significantly increased in some subfield sectors (inferior and temporal parafoveal; superior, temporal, and nasal perifoveal) 1 month after the combined phaco-trabeculectomy but not the trabeculectomy surgery. No significant changes were detected at month 3 postoperatively, except in the temporal perifoveal sector in patients with the combined procedure. Therefore, it seems that the increase of RT in combined phaco-trabeculectomy will reverse to baseline values 3 months after surgery, except in the temporal perifoveal region.

Acknowledgement

The authors would like to thank Mona Arbab MD, Indiana University, for her great assistance in the language editing of the manuscript. Also, we send our special thanks to all the patients and the Ophthalmology Department staff at the Rassoul Akram Hospital and Eye Research Center.

Financial support and sponsorship

Nil.

Conflicts of interest

There are no conflicts of interest.

REFERENCES

1. Yonekawa Y, Kim IK. Pseudophakic cystoid macular edema. *Curr Opin Ophthalmol* 2012;23:26-32.
2. Vukicevic M, Gin T, Al-Qureshi S. Prevalence of optical coherence tomography-diagnosed postoperative cystoid macular oedema in patients following uncomplicated phaco-emulsification cataract surgery. *Clin Exp Ophthalmol* 2012;40:282-7.
3. Jampel HD, Musch DC, Gillespie BW, Lichter PR, Wright MM, Guire KE, *et al.* Perioperative complications of trabeculectomy in the collaborative initial glaucoma treatment study (CIGTS). *Am J Ophthalmol* 2005;140:16-22.
4. Gedde SJ, Schiffman JC, Feuer WJ, Herndon LW, Brandt JD, Budenz DL, *et al.* Three-year follow-up of the tube versus trabeculectomy study. *Am J Ophthalmol* 2009;148:670-84.
5. Kadziauskienė A, Strelkauskaitė E, Mockevičiūtė E, Ašoklis R, Lesinskas E, Schmetterer L. Changes in macular thickness after trabeculectomy with or without adjunctive 5-fluorouracil. *Acta Med Litu* 2017;24:93-100.
6. Pitale PM, Chatha U, Patel V, Gupta L, Waisbourd M, Pro MJ. Changes in macular thickness following glaucoma surgery. *Int J Ophthalmol* 2016;9:1236-7.
7. Huq Ridoy A, Nazrul Islam M, Chowdhury MR. Effect of trabeculectomy on retinal nerve fiber layer and macular thickness by optical coherence tomography. *J Clin Exp Ophthalmol* 2016;7:7.
8. Sesar A, Cavar I, Sesar AP, Geber MZ, Sesar I, Laus KN, *et al.* Macular thickness after glaucoma filtration surgery. *Coll Antropol* 2013;37:841-5.
9. Karasheva G, Goebel W, Klink T, Haigis W, Grehn F. Changes in macular thickness and depth of anterior chamber in patients after filtration surgery. *Graefes Arch Clin Exp Ophthalmol* 2003;241:170-5.
10. Ch'ng TW, Gillmann K, Hoskens K, Rao HL, Mermoud A, Mansouri K. Effect of surgical intraocular pressure lowering on retinal structures - nerve fibre layer, foveal avascular zone, peripapillary and macular vessel density: 1 year results. *Eye (Lond)* 2020;34:562-71.
11. Kojima H, Hirooka K, Nitta E, Ukegawa K, Sonoda S, Sakamoto T. Changes in choroidal area after intraocular pressure reduction following trabeculectomy. *PLoS One* 2018;13:e0201973.
12. Zhao Z, Wen W, Jiang C, Lu Y. Changes in macular vasculature after uncomplicated phacoemulsification surgery: Optical coherence tomography angiography study. *J Cataract Refract Surg* 2018;44:453-8.
13. Drukteinienė E, Strelkauskaitė E, Kadziauskienė A, Ašoklis R, Schmetterer L. Macular thickness after intraocular pressure reduction following trabeculectomy. *Acta Ophthalmol* 2017;95:S259.
14. Gharbiya M, Cruciani F, Cuozzo G, Parisi F, Russo P, Abdolrahimzadeh S. Macular thickness changes evaluated with spectral domain optical coherence tomography after uncomplicated phacoemulsification. *Eye (Lond)* 2013;27:605-11.
15. Stark WJ, Goyal RK, Awad O, Vito E, Kouzis AC. The safety and efficacy of combined phacoemulsification and trabeculectomy with releasable sutures. *Br J Ophthalmol* 2006;90:146-9.
16. Arcieri ES, Santana A, Rocha FN, Guapo GL, Costa VP. Blood-aqueous barrier changes after the use of prostaglandin analogues in patients with pseudophakia and aphakia: A 6-month randomized trial. *Arch Ophthalmol* 2005;123:186-92.
17. Pardiato G, Moeloek N, Reveny J, Wage S, Satari I, Sembiring R, *et al.* Retinal thickness changes after phacoemulsification. *Clin Ophthalmol* 2013;7:2207-14.
18. Kadziauskienė A, Strelkauskaitė E, Mockevičiūtė E, Ašoklis R, Lesinskas E, Schmetterer L. Changes in macular thickness after trabeculectomy with or without adjunctive 5-fluorouracil. *Acta Med Litu* 2017;24:93-100.

Supplemental digital content 1: Comparing the changes of macular thickness in 64 patients with primary open-angle glaucoma and primary angle-closure glaucoma at preoperative, 1 and 3 months following trabeculectomy with or without phacoemulsification

Variables	Follow-up times	Subgroups						P ^a
		POAG, mean (SD)			PACG, mean (SD)			
		Trabeculectomy (n=14)	Trabeculectomy with phacoemulsification (n=18)	P ^a	Trabeculectomy (n=18)	Trabeculectomy with phacoemulsification (n=14)	P ^a	
Central subfield thickness (µm)	Preoperative	256.25 (28.30)	261.88 (35.41)	0.77	256.89 (26.81)	252.71 (22.963)	0.58	
Changes of foveal thickness (µm)	1 month	1.40 (3.65)	8.00 (6.00)	0.06	5.00 (5.43)	0.25 (9.54)	0.32	
	3 months	1.38 (7.73)	8.64 (17.00)	0.32	2.29 (4.61)	1.27 (22.71)	0.13	
Temporal parafoveal thickness (µm)	Preoperative	297.36 (18.64)	297.00 (31.98)	0.85	301.28 (22.68)	306.43 (27.29)	0.57	
Changes of temporal parafoveal thickness (µm)	1 month	0.40 (1.67)	9.75 (8.38)	0.02	2.00 (4.80)	1.25 (6.65)	0.80	
	3 months	0.50 (4.77)	7.25 (17.47)	0.14	0.78 (5.46)	7.83 (12.45)	0.04	
Superior parafoveal thickness (µm)	Preoperative	310.14 (27.74)	309.11 (30.34)	0.88	312.89 (29.43)	312.86 (21.51)	0.63	
Changes of superior parafoveal thickness (µm)	1 month	0.00 (2.55)	7.25 (11.87)	0.27	1.60 (4.51)	4.50 (4.12)	0.17	
	3 months	2.70 (11.54)	6.50 (16.66)	0.59	1.22 (11.25)	5.17 (8.08)	0.06	
Nasal parafoveal thickness (µm)	Preoperative	309.29 (30.98)	312.78 (30.52)	0.92	315.00 (25.65)	309.71 (22.95)	0.69	
Changes of nasal parafoveal thickness (µm)	1 month	0.40 (2.07)	6.50 (10.41)	0.13	3.40 (6.43)	10.50 (10.54)	0.17	
	3 months	0.50 (4.65)	5.63 (20.47)	0.81	1.17 (6.22)	5.25 (7.18)	0.12	
Inferior parafoveal thickness (µm)	Preoperative	306.36 (29.88)	298.78 (29.52)	0.47	304.11 (20.69)	305.71 (21.87)	0.96	
Changes of inferior parafoveal thickness (µm)	1 month	1.80 (4.32)	11.00 (12.03)	0.06	1.00 (3.87)	6.50 (5.32)	0.14	
	3 months	2.70 (5.54)	7.37 (20.11)	0.92	1.28 (6.86)	5.33 (7.83)	0.05	
Temporal perifoveal thickness (µm)	Preoperative	267.50 (20.28)	269.50 (40.24)	0.38	264.11 (20.25)	271.86 (29.71)	0.70	
Changes of temporal perifoveal thickness (µm)	1 month	0.60 (2.41)	8.75 (10.56)	0.08	1.60 (3.72)	10.75 (8.06)	0.04	
	3 months	2.10 (9.02)	1.75 (15.36)	0.21	0.69 (5.91)	7.25 (5.71)	0.003	
Superior perifoveal thickness (µm)	Preoperative	280.71 (24.55)	279.94 (30.25)	0.95	275.67 (27.30)	282.93 (20.86)	0.29	
Changes of superior perifoveal thickness (µm)	1 month	1.80 (3.42)	8.50 (10.21)	0.05	0.60 (2.70)	6.75 (3.30)	0.04	
	3 months	1.40 (4.30)	0.07 (13.74)	0.93	0.94 (8.86)	5.25 (8.09)	0.07	
Nasal perifoveal thickness (µm)	Preoperative	284.07 (25.81)	291.11 (34.59)	0.59	288.11 (29.49)	289.07 (18.37)	0.49	
Changes of nasal perifoveal thickness (µm)	1 month	1.00 (4.64)	10.25 (10.01)	0.09	0.80 (5.45)	7.25 (2.87)	0.06	
	3 months	1.70 (6.90)	2.88 (8.89)	0.87	3.00 (11.18)	5.08 (8.31)	0.02	
Inferior perifoveal thickness (µm)	Preoperative	267.07 (20.90)	270.72 (40.72)	0.58	265.50 (27.90)	283.25 (33.17)	0.13	
Changes of inferior perifoveal thickness (µm)	1 month	2.60 (3.51)	6.00 (14.77)	0.90	1.00 (3.67)	6.50 (3.00)	0.04	
	3 months	2.40 (5.95)	0.94 (12.15)	0.85	5.07 (14.99)	1.90 (18.08)	0.01	

^aMann-Whitney *U*-test. SD: Standard deviation, POAG: Primary open-angle glaucoma, PACG: Primary angle-closure glaucoma