

“Double Protection Closed Compartment” Aspiration Technique for Left Internal Carotid Artery (ICA) Free Floating Thrombus

Sir,

A 39-year-old gentleman, nonsmoker, nonalcoholic, without any other premorbid illness, complained of giddiness and mild difficulty in walking on 24th November 2020 at around 11 am. He was able to carry out his daily routine work and did not give much importance to his symptoms. At around 5 pm, he started to have mild weakness involving the right side of his body. His wife also noticed him having trouble finding words, although with intact comprehension. Concerned with his symptoms, he was taken to a nearby clinic, where he was advised magnetic resonance imaging (MRI) of the brain which was suggestive of acute left middle cerebral artery (MCA) territory infarcts (high-resolution images not available). After the MRI, the patient deteriorated and developed worsening of his right-side motor power, such that he was barely able to lift his right upper and lower limbs along with speech impairment, in the form of word-finding difficulties. After this, he was referred to our center for further management. On examination in the emergency department at 09.30 pm, he had right side hemiplegia along with Broca's aphasia (NIHSS 18). Stroke Code was activated as per our institutional protocol, and the patient was immediately rushed for imaging (CT Brain, CT angiography head-neck, and CT perfusion). CT Brain showed focal areas of hypodensities suggestive of acute infarcts seen in the left frontal cortex and left MCA-anterior cerebral artery (ACA) and MCA-posterior cerebral artery (PCA) watershed territories. CT Perfusion showed focal areas of matched perfusion deficit in the left frontal cortex and left MCA-ACA and MCA-PCA watershed territories. Hypodensity suggestive of free-floating thrombus was noted in the left cervical internal carotid artery (ICA) with decreased anterograde signal intensity [Figure 1]. There was no occlusion of MCA and its branches.

In spite of a free-floating thrombus, the patient had patchy infarcts which had caused hemiplegia and aphasia. Further treatment decision was to be governed by multiple factors such as young age, presence of free-floating thrombus proximally with a risk of further distal clot migration, leading to large vessel occlusion causing major stroke and thus a need for decompression surgery. Another important consideration was the already present deficits [hemiplegia and Broca's aphasia with high *National Institutes of Health Stroke Scale* (NIHSS)] which might affect our clinical judgment in case of any fresh infarcts because of distal clot migration. In view of the patient's best clinical interests, after discussing with the family and written informed consent, a decision for mechanical clot aspiration was taken.

With the patient under monitored anesthesia care (MAC) following regular prepping and draping of the right groin,

8-F short sheath was placed, and Neuron max 6 F 088 was inserted through the right femoral artery and parked in left distal common carotid artery (CCA). The contrast run showed Left ICA floating thrombus [Figure 2]. MCA branches (M1, M2, and M3) showed normal opacification with minor perfusion deficits noted in the distal cortical branches.

With the free-floating thrombus, there was always a risk of clot migration.^[1,2] We did not have a balloon-guided catheter in our lab at that time. So, to prevent the risk of clot migration during aspiration, we first placed the Emboshield NAV filter device distal to the thrombus followed by a noncompliant balloon (NC TREK 4.5 mm × 12 mm) over the filter wire placed proximal to the filter device but distal to the thrombus. The idea behind this step was to create a “Double Protection Closed Compartment,” with the purpose of minimizing distal clot migration during aspiration [Figure 3].

After that, an 8F short sheath was placed in the left femoral artery, and Neuron Max 6 F 088 was inserted and parked in the left proximal CCA. Thereafter, the balloon was inflated to

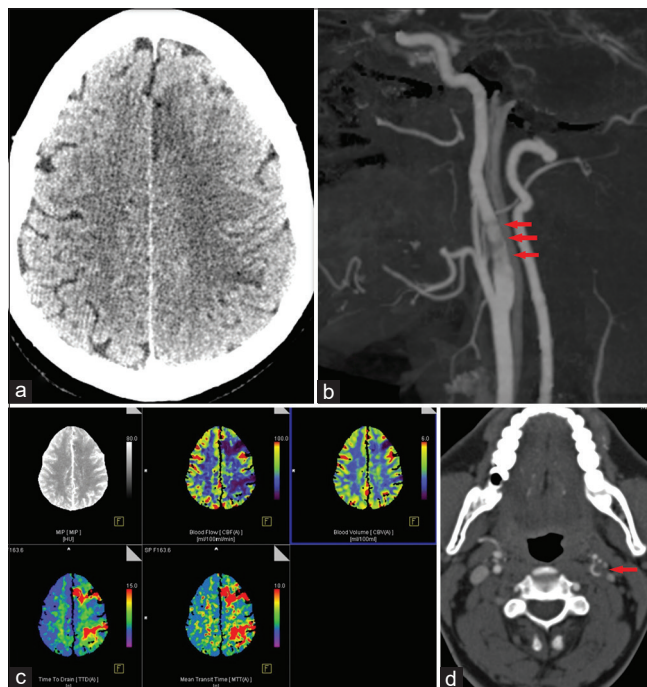


Figure 1: (a) CT Brain showed focal areas of hypodensities suggestive of acute infarcts seen in the left frontal cortex and left MCA-ACA and MCA-PCA watershed territories. Sagittal (b) and Axial (d) CT Angiography showing hypodensity suggestive of free-floating thrombus in the cervical internal carotid artery (ICA) with decreased anterograde signal intensity. (c) CT perfusion showed focal areas of matched perfusion deficit in the left frontal cortex and left MCA-ACA and MCA-PCA watershed territories

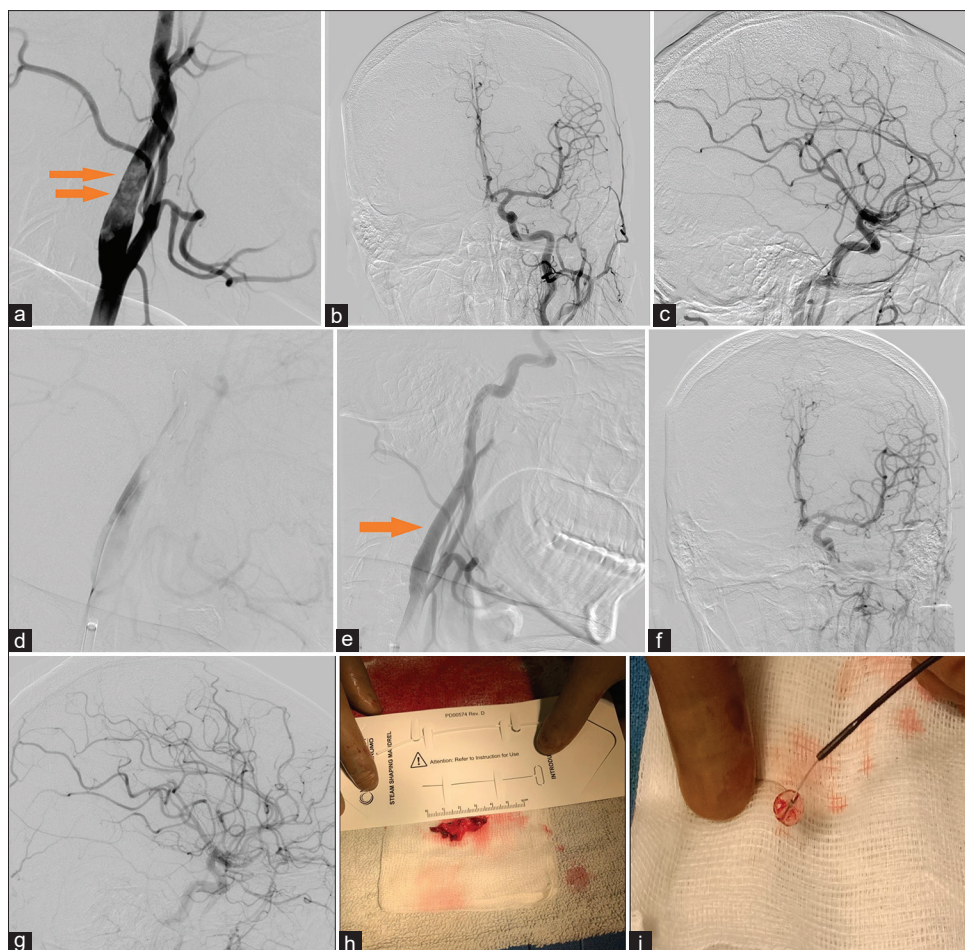


Figure 2: (a) Left Common carotid contrast run showing Left ICA floating thrombus. Baseline left ICA injection showing intracranial circulation – antero-posterior (b) and lateral view (c) showing normal opacification of the MCA branches (M1, M2, and M3) with minor perfusion deficits in the distal cortical branches. (d) “Double Protection Closed Compartment” technique. (e) The subsequent run showed complete opacification of the left ICA with no residual intraluminal clot. Repeat left ICA injection showing intracranial circulation – antero-posterior (f) and lateral view (g) showing no new perfusion deficits in the MCA territory compared to the baseline angiographic run. (h) Clot captured. (i) Distal protection device post-procedure

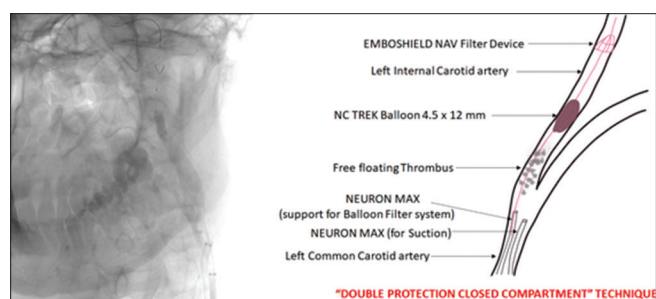


Figure 3: “Double Protection Closed Compartment” technique

create “Double Protection Closed Compartment,” following which aspiration was connected to 2nd Neuron max and advanced distally into the mid-cervical ICA engaging the clot.

The subsequent run showed complete opacification of the left ICA with no residual intraluminal clot.

Check angiography also didnot show any new perfusion deficits in the MCA territory compared to the baseline angiographic run.

The patient remained neurologically stable after procedure. Repeat CT Brain done the next morning did not show any new evidence of new territorial infarcts [Figure 4].

The patient was evaluated for the etiology of the stroke. 2D echocardiogram and Holter monitoring were within normal limits. Reverse transcription polymerase chain reaction (RT PCR) for COVID-19 was nonreactive. Other investigations (serum homocysteine, protein C and S, antithrombin III, anticardiolipin antibodies) did not reveal any abnormality. The patient improved during the course of the hospital stay with improvement in the right side motor power (3/5) and speech (modified Rankin scale score 3).

This case demonstrates the importance of aggressive management in cases where future clinical decision judgement might be impaired by patient’s present clinical deficits. Also, the technique we used in this case, Double Protection Closed Compartment,” might be useful and effective in such cases with limited/unavailable resources.

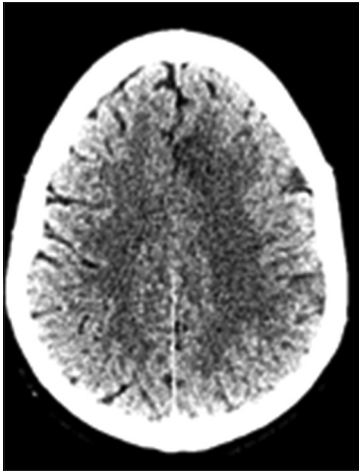


Figure 4: Follow-up CT Brain – no evidence of any fresh infarcts post-procedure

Financial support and sponsorship

Nil.

Conflicts of interest

There are no conflicts of interest.

Piyush Ojha, Gaurav Goel, Apratim Chatterjee, Vasudha Singhal¹, Anshu Mahajan

Departments of Neurointervention Surgery, and ¹Neuroanaesthesiology and Critical Care, Medanta Institute of Neurosciences, Medanta – The Medicity, Sector 38, Gurgaon, Haryana, India

Address for correspondence: Dr. Anshu Mahajan,
Department of Neurointervention Surgery,
Medanta Institute of Neurosciences, Medanta – The Medicity, Sector 38,
Gurgaon, Haryana - 122 001, India.
E-mail: anshunph@gmail.com

REFERENCES

1. Bhatti AF, Leon LR Jr, Labropoulos N, Rubinas TL, Rodriguez H, Kalman PG, *et al.* Free-floating thrombus of the carotid artery: Literature review and case reports. *J Vasc Surg* 2007;45:199-205.
2. Ferrero E, Ferri M, Viazzo A, Labate C, Pecchio A, Berardi G, *et al.* Free-floating thrombus in the internal carotid artery: Diagnosis and treatment of 16 cases in a single center. *Ann Vasc Surg* 2011;25:805-12.

Submitted: 31-Mar-2021 **Accepted:** 15-Oct-2021 **Published:** 13-Jan-2022

This is an open access journal, and articles are distributed under the terms of the Creative Commons Attribution-NonCommercial-ShareAlike 4.0 License, which allows others to remix, tweak, and build upon the work non-commercially, as long as appropriate credit is given and the new creations are licensed under the identical terms.

DOI: 10.4103/aian.aian_271_21