



Since January 2020 Elsevier has created a COVID-19 resource centre with free information in English and Mandarin on the novel coronavirus COVID-19. The COVID-19 resource centre is hosted on Elsevier Connect, the company's public news and information website.

Elsevier hereby grants permission to make all its COVID-19-related research that is available on the COVID-19 resource centre - including this research content - immediately available in PubMed Central and other publicly funded repositories, such as the WHO COVID database with rights for unrestricted research re-use and analyses in any form or by any means with acknowledgement of the original source. These permissions are granted for free by Elsevier for as long as the COVID-19 resource centre remains active.

Bibliografía

- Hsu JC, Varosy PD, Bao H, Dewland TA, Curtis JP, Marcus GM. Cardiac perforation from implantable cardioverter-defibrillator lead placement: insights from the national cardiovascular data registry. *Circ Cardiovasc Qual Outcomes*. 2013;6:582-90. <http://dx.doi.org/10.1161/circoutcomes.113.000299>.
- Vamos M; Erath J; Benz AP; Bari Z; Duray GZ; Hohnloser SH; Incidence of cardiac perforation with conventional and with leadless pacemaker systems: a systematic review and meta-analysis. *J Cardiovasc Electrophysiol*. 28. 336-346. doi: 10.1111/jce.13140.
- Banaszewski M, Stepnińska J. Right heart perforation by pacemaker leads. *Arch Med Sci*. 2012;8:11-3. <http://dx.doi.org/10.5114/aoms.2012.27273>.
- Van Gelder BM, Verberkmoes N, Nathoe R, Bracke FA. Late asymptomatic atrial lead perforation, a fortuitous finding during lead extraction using thoroscopic surveillance: a case report and review of the literature. *Europace*. 2016;18:1773-8. <http://dx.doi.org/10.1093/europace/euw054>.
- Haque MA, Roy S, Biswas B. Perforation by permanent pacemaker lead: how late can they occur? *Cardiol J*. 2012;19:326-7. <http://dx.doi.org/10.5603/cj.2012.0059>.
- Kumar S, Madanieh A, Patel H, Murthy RS, Goyos JM, Milunski MR. Large unilateral pleural effusion with pacemaker-associated post-cardiac injury syndrome. *Cureus*. 2018;10:e2946. <http://dx.doi.org/10.7759/cureus.2946>.
- Saradna A, Sinha A, Abduraimova M, Rodríguez D, Yang F. Tale of a wandering lead: late atrial lead perforation into right lung following pacemaker implantation. *Cureus*. 2017;9:e1865. <http://dx.doi.org/10.7759/cureus.1865>.
- Cano O, Andrés A, Jiménez R, Osca J, Alonso P, Rodríguez Y, et al. Incidence and predictors of clinically relevant cardiac perforation associated with systematic implantation of active-fixation pacing and defibrillation leads: a single-centre experience with over 3800 implanted leads. *Europace*. 2017;19:96-102. <http://dx.doi.org/10.1093/europace/euv410>.
- Hirschi DA, Jain VR, Spindola-Franco H, Gross JN, Haramati LB. Prevalence and characterization of asymptomatic pacemaker and ICD lead perforation on CT. *Pacing Clin Electrophysiol*. 2007;30:28-32. <http://dx.doi.org/10.1111/j.1540-8159.2007.00575.x>.
- Schryver N, Marchandise S, Colin GC, Ghaye B, Polain de Waroux JB. Asymptomatic late migration of an atrial pacemaker lead into the right lung. *Case Rep Cardiol*. 2014;2014:145917. <http://dx.doi.org/10.1155/2014/145917>.
- Tran NT, Zivin A, Mozafferian D, Karmy-Jones R. Right atrial perforation secondary to implantable cardioverter defibrillator insertion. *Can Respir J*. 2001;8:283-5. <http://dx.doi.org/10.1155/2001/257641>.
- Rajkumar CA, Claridge S, Jackson T, Behar J, Johnson J, Sohal M, et al. Diagnosis and management of iatrogenic cardiac perforation caused by pacemaker and defibrillator leads. *Europace*. 2017;19:1031-7. <http://dx.doi.org/10.1093/europace/euw074>.
- Migliore F, Zorzi A, Bertaglia E, Leoni L, Siciliano M, De Lazzari M, et al. Incidence, management, and prevention of right ventricular perforation by pacemaker and implantable cardioverter defibrillator leads. *Pacing Clin Electrophysiol*. 2014;37:1602-9. <http://dx.doi.org/10.1111/pace.12472>.
- Ellenbogen KE, Wood MA, Shepard RK. Delayed complications following pacemaker implantation. *Pacing Clin Electrophysiol*. 2002;25:1155-8. <http://dx.doi.org/10.1046/j.1460-9592.2002.01155.x>.

Eduardo Laviña Soriano^{a,*}, Yunelsy Anta Mejías^a, Lucía Gil Abadía^b y Olga Mediano^{a,c,d}

^a Servicio de Neumología, Hospital Universitario de Guadalajara, Guadalajara, España

^b Servicio de Radiodiagnóstico, Hospital Universitario de Guadalajara, Guadalajara, España

^c Departamento de Medicina, Universidad de Alcalá de Henares, Madrid, España

^d Ciber de Enfermedades Respiratorias (CIBERES), Madrid, España

* Autor para correspondencia.

Correo electrónico: elaviña@sescam.jccm.es (E. Laviña Soriano).

<https://doi.org/10.1016/j.arbres.2020.09.015>

0300-2896/ © 2020 SEPAR. Publicado por Elsevier España, S.L.U. Todos los derechos reservados.

Bird Fancier's Lung Diagnosis in Times of COVID-19



Diagnóstico de la neumonitis de los avicultores en tiempos de la COVID-19

Dear Editor,

The identification of bilateral ground-glass opacifications on thoracic computed tomography (CT) in the COVID-19 ongoing pandemic, supports the diagnosis of SARS-CoV-2 infection. Although COVID-19 pneumonia may present with this typical imaging pattern, it is important to highlight that even in an acute clinical setting this pattern it is a non-specific imaging finding and other conditions such as pulmonary oedema, non-infectious pneumonitis and infectious interstitial pneumonia by other pathogens need to be considered.^{1,2}

We report the case of a 69-year-old woman who presented to our department in April 2020, during COVID-19 pandemic. On admission, the patient described a 10 day history of progressive dyspnoea and chest pain. There was a 11% of weight loss and occasional wrist and ankle arthralgia, without myalgia, fever or cough. Relevant clinical history included hypertension, allergic rhinosinusitis and psoriasis (on cyclosporine treatment, discontinued in 2018). On physical exam she had tachypnoea, inspiratory crackles in the lung bases and a peripheral oxygen saturation (SpO₂) of 89%. Laboratory findings revealed normal white blood cell count, an increased high-sensitivity C-reactive protein (3.70 mg/dL N.R.<0.5 mg/dL), lactate dehydrogenase (308 U/L >250 U/L) and

erythrocyte sedimentation rate (60 mm/h <20 mm/h) with procalcitonin value within the reference range (0.09 ng/mL <0.5 ng/mL). Immunological and microbiological studies (including a swab test for RT-PCR SARS-CoV-2) were negative. Chest radiography showed diffuse bilateral symmetric ill-defined air-space opacities. Chest CT displayed diffuse bilateral ground-glass opacities with lobular spared areas (mosaic attenuation pattern), ill-defined centrilobular ground-glass nodules and mild interlobular thickening, however without the characteristic distribution of COVID-19 (Fig. 1).

The patient was admitted with the presumptive diagnosis of SARS-CoV-2 pneumonia, based on a high probability diagnosis' score,³ pending a second negative nasopharyngeal swab test for RT-PCR SARS-CoV-2.

On a more detailed clinical history, the patient acknowledged to have a budgerigar at home for about one year. Flexible bronchoscopy showed diffusely friable mucosa. Bronchoalveolar lavage fluid cell count was consistent with alveolitis (28% alveolar macrophages, 42% lymphocytes, 24% neutrophils and 6% eosinophils, with a CD4/CD8 ratio of 2). A diagnosis of Bird Fancier's Lung was confirmed by strongly positive precipitins to budgerigar. The patient initiated inhaled steroids with rapid symptomatic improvement and was discharged home with rest SpO₂ of 98%. The budgerigar was removed from the patient's environment and she became totally asymptomatic after a short steroid treatment.^{4,5}

Hypersensitivity pneumonitis (HP) is an immunologically non-IgE-mediated lung disease due to the repetitive inhalation of antigens. Most cases are secondary to residential environmental exposure, particularly birds. Given the time length to onset of symptoms, the causal epidemiological link is often initially

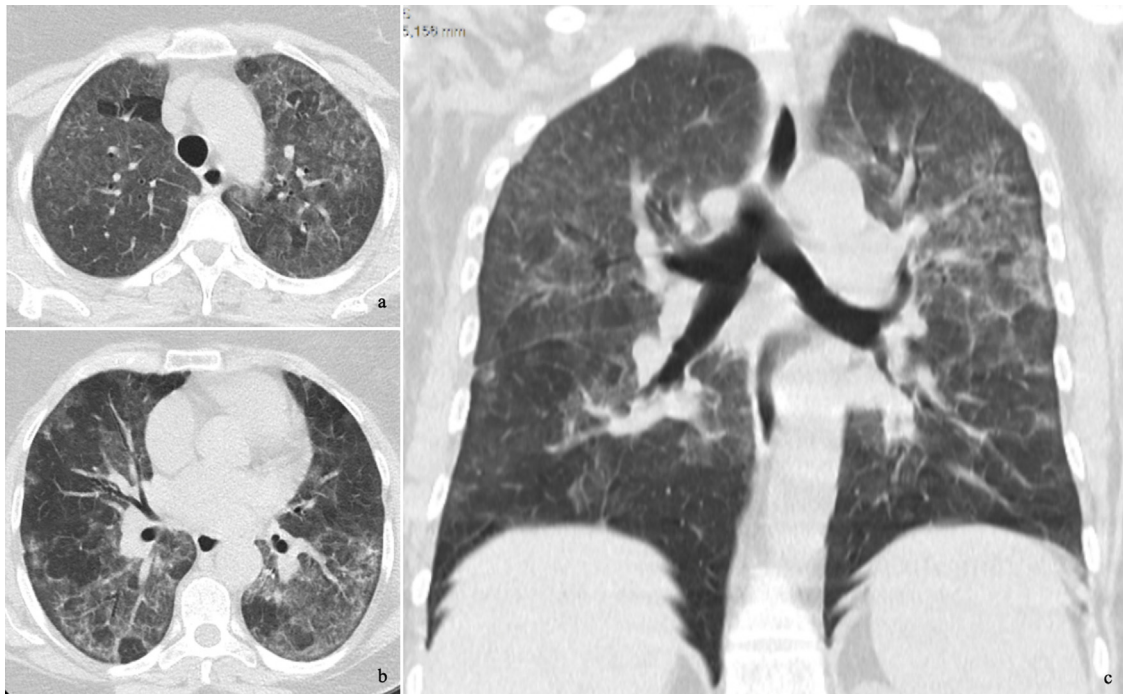


Fig. 1. Chest CT axial (a, b) and coronal (c) images demonstrating diffuse bilateral ground-glass opacities with lobular spared areas (mosaic attenuation pattern), ill-defined centrilobular ground-glass nodules in the upper lobes and mild interlobula.

unrecognized. The clinical symptoms and imaging findings are nonspecific and may mimic COVID-19 in the ongoing pandemic. Nevertheless, other medical conditions may present with a similar clinical and radiographic findings. In the pandemic time of COVID-19, the presence of alveolar infiltrates urges to consider the hypothesis of this infection. Atypical clinical findings and negative swabs compel us to exclude other etiologies, being of the utmost importance a thorough clinical history.

Funding

None.

Conflict of interest

None.

Bibliografía

1. Miller WT Jr, Shah RM. Isolated diffuse ground-glass opacity in thoracic CT: causes and clinical presentations. *Am J Roentgenol.* 2005;184:613–22, <http://dx.doi.org/10.2214/ajr.184.2.01840613>.
2. Salehi S, Abedi A, Balakrishnan S, Gholamrezanezhad A. Coronavirus Disease 2019 (COVID-19): a systematic review of imaging findings in 919 patients. *Am J Roentgenol.* 2020;14:1–7, <http://dx.doi.org/10.2214/AJR.20.23034>.
3. Mendes JJ, Mergulhão P, Froes F, Paiva JA, Gouveia J. (Sociedade Portuguesa de Cuidados Intensivos, 2020). Diagnóstico de infeção (COVID-19). Available from: <https://www.spci.pt/media/covid-19/COVID-19-R-20200322.pdf>.

4. Raghu G, Remy-Jardin M, Ryerson CJ, et al. Diagnosis of hypersensitivity pneumonitis in adults. An official ATS/JRS/ALAT clinical practice guideline. *Am J Respir Crit Care Med.* 2020;202:e36–69, <http://dx.doi.org/10.1164/rccm.202005-2032ST>.
5. Funke M, Fellrath J-M. Hypersensitivity pneumonitis secondary to love-birds: a new cause of bird fancier's disease. *Eur Respir J.* 2008;32:517–21, <http://dx.doi.org/10.1183/09031936.00108507>.

Ana Cardoso^{a,*}, Lisa Gonçalves^{a,1}, João R. Inácio^b, Francisco Cunha^a, João Victor Freitas^a, Raquel Soares^a, Carolina Branco^a, Tiago Branco^a, Nuno Jacinto^a, Liliana R. Santos^a, Lourdes Alvoeiro^a, António Pais de Lacerda^{a,c}

^a Department of Medicine 2, Hospital de Santa Maria, Centro Hospitalar Universitário Lisboa Norte, Lisbon, Portugal

^b Department of Radiology, Hospital de Santa Maria, Centro Hospitalar Universitário Lisboa Norte, Lisbon, Portugal

^c Faculty of Medicine of the University of Lisbon, Lisbon

* Corresponding author.

E-mail address: njacinto84@gmail.com (A. Cardoso).

¹ Co-authorship.

<https://doi.org/10.1016/j.arbres.2020.09.016>

0300-2896/ © 2020 SEPAR. Published by Elsevier España, S.L.U. All rights reserved.