

Case report

Dual intestinal parasitosis unmasked by treatment for gastrointestinal sarcoidosis

Olutobi Ojuawo^{a,*}, Thidar Htwe^a, Sakaria Farah^a, Dominic King^b, Imtiaz Ahmed^a^a Respiratory Department, Sandwell and West Birmingham Hospitals, NHS Trust, Birmingham, United Kingdom^b Gastroenterology Department, Sandwell and West Birmingham Hospitals, NHS Trust, Birmingham, United Kingdom

ARTICLE INFO

Article history:

Received 1 November 2021

Received in revised form 6 November 2021

Accepted 7 November 2021

Available online xxxx

Keywords:

Sarcoidosis

Giardiasis

Strongyloidiasis

Corticosteroid therapy

ABSTRACT

The symptoms and complications of intestinal parasitosis can occur with long-term corticosteroid therapy. We highlight the case of a young man who developed chronic gastrointestinal (GI) symptoms of diarrhea, crampy abdominal pain, and vomiting while on treatment for multisystemic sarcoidosis with corticosteroids. His symptoms were initially thought to be related to the gastrointestinal manifestations of sarcoidosis, but further evaluation revealed a combined case of intestinal strongyloidiasis and giardiasis as well as previously undiagnosed human T-cell lymphotropic virus (HTLV-1) infection. This distinctive case of dual intestinal parasitosis highlights the need for clinicians to maintain a high level of awareness to screen for intestinal parasites, particularly *Strongyloides* when prescribing corticosteroids in the long term given the potential risk of hyperinfection in the setting of immunosuppression.

© 2021 Published by Elsevier Ltd.
CC_BY_NC_ND_4.0

Introduction

Sarcoidosis is a multisystemic granulomatous disease of unknown etiology, characterized by the presence of giant-cell non-necrotizing granulomas [1]. The involvement of the GI tract is uncommon, occurring in only 0.1 – 1.6% of cases [2]. The putative mechanisms of GI tract damage include mucosal infiltration, endoluminal lesions, dysfunction of the myenteric plexus, and extrinsic compression of structures [2]. This culminates in the clinical manifestations of abdominal pain, diarrhea, vomiting, and weight loss [2].

Symptomatic sarcoidosis is treated with glucocorticoids, cytotoxic medications, or biologic agents; all of which carry a risk of systemic infections including parasitic GI tract infections [3]. There have been a few case reports of intestinal parasitosis in the context of corticosteroid therapy for sarcoidosis [4–6], however, our finding of dual parasitosis is unique particularly given the concomitant finding of asymptomatic human T-cell lymphotropic virus 1 (HTLV-1) co-infection.

Case presentation

A 32 year old Afro-Caribbean man with no prior medical condition presented with progressive exercise intolerance and worsening

painful skin nodules in both legs for four weeks. He had no cough, chest pain, wheeze, or fever. He had resided in the United Kingdom for about 20 years without travel to his country of birth. He was a current smoker with a twenty pack-year history.

Clinical examination revealed tender nodules on the shins consistent with erythema nodosum and unremarkable systemic examinations. Blood investigations showed a normal complete blood count, erythrocyte sedimentation rate of 118 mm/h; C-reactive protein of 44 mg/L, with normal renal and liver function tests. Human immunodeficiency virus (HIV) screen was negative. High-resolution CT scan of the thorax revealed bilateral lung infiltrates and hilar adenopathy (Fig. 1). Serum adjusted calcium level was normal but angiotensin converting enzyme levels were raised at 154 U/L (12–82 U/L). Lung function tests revealed a restrictive pattern with reduced diffusion capacity: FEV1/FVC – 92% (111% predicted); FVC 3.49 L (73% predicted); FEV1 3.21 L (82% predicted); TLC 5.5 L (72% predicted); TLCO 6.62 L (56% predicted). He was treated for pulmonary sarcoidosis with oral prednisolone 30 mg daily for 4 weeks followed by a gradually tapering dose whilst monitoring his exercise tolerance and lung function parameters.

Four months later, he presented in the emergency department with profuse foul-smelling non-bloody, non-mucoid diarrhea associated with crampy lower abdominal pain and nausea. Stool and blood cultures did not yield any pathogen. He was managed in the high dependency unit where he had inotropic support due to persistent hypotension and treatment for prerenal acute kidney injury.

* Corresponding author.

E-mail address: ojuawo@nhs.net (O. Ojuawo).

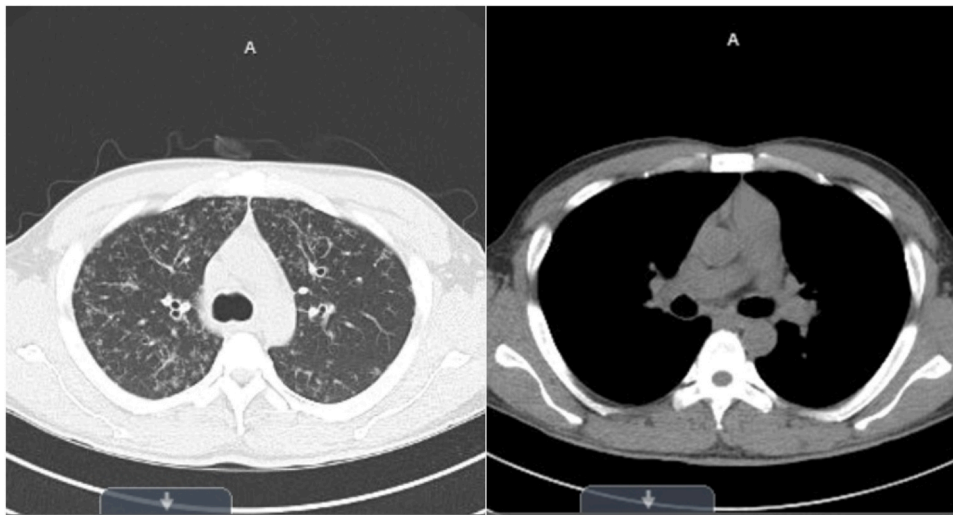


Fig. 1. High resolution CT scan of the thorax showing lung infiltrates and hilar lymphadenopathy. Left – lung window; Right – mediastinal window.

He presented again two weeks after discharge with similar abdominal symptoms. Blood investigations were significant for eosinophilia (1280 cells/uL; 13.2% of total white blood cell count) and hypokalemia of 3.3 mmol/L. Stool analysis did not isolate any pathogen, and fecal elastase was normal. However, fecal calprotectin was mildly elevated at 159 ug/mL (< 60). CT scan of the abdomen and pelvis showed mild distension of the small and large bowels. Upper and lower GI tract endoscopies were performed due to a clinical suspicion of GI sarcoidosis and were macroscopically normal. However, histologic assessment of gastric and duodenal biopsies revealed non-necrotizing epithelioid granulomas confirming a diagnosis of GI sarcoidosis. His corticosteroid dose was subsequently increased to 40 mg daily.

A repeat stool sample was sent for microbiological analysis due to persistent symptoms. *Giardia lamblia* (GL) was detected by polymerase chain reaction (PCR) although cysts remained absent on microscopy. Also, rhabditiform larvae and an adult female form of *Strongyloides stercoralis* (SS) were identified. Stool PCR for *Clostridium difficile*, *Salmonella* and *Shigella* species were negative. Enzyme linked immunosorbent assay was strongly positive for *Strongyloides* at an optical density of 0.977 (cut-off: 0.702).

Following consultations with the regional tropical disease departments, he was given intravenous metronidazole for symptomatic giardiasis at 500 mg three times a day for 5 days and oral ivermectin for strongyloidiasis at 200 ug/kg for 2 days. He had improvement in abdominal pain and the frequency of diarrhea episodes within 48 h of commencement; however, his loose stools persisted. Further stool examinations revealed clearance of GL; with persistent presence of rhabditiform larvae of SS. This prompted an extended course of ivermectin for a further 14 days with daily assessment of stool samples given the likelihood of a SS hyperinfection syndrome. Considering his persistent strongyloidiasis, a blood sample was also sent for HTLV-1 serology which returned positive.

His symptoms resolved afterwards with consistent evidence of negative stool examinations. He remains clinically stable on outpatient clinic visits on a stable prednisolone dose of 5 mg daily whilst being monitored for asymptomatic HTLV-1 infection.

Discussion

Our case report is unique in highlighting dual intestinal parasitosis (giardiasis and strongyloidiasis) in an individual on corticosteroid treatment for sarcoidosis and previously unidentified HTLV-1 infection. Immunosuppressed patients are thought to be at a higher

risk of symptomatic parasitic infections and although the exact mechanism for this susceptibility is not entirely clear, diminished adaptive and innate immune responses in GL impair the host's ability to control infection [7]. Furthermore, the dysregulated immune response with sarcoidosis itself could potentially increase the risk of opportunistic parasitic infections as the inhibition of IL-2 production reduce the myeloid cell's ability to stimulate T-cells which are fundamental for defense against the parasite [8].

GL is a flagellated microscopic protozoon that is ubiquitous in many regions of the world especially in developing countries [9]. The transmission mode is through consumption of contaminated water and food with an incubation period of 5–25 days [9]. Symptomatic patients with GL commonly have abdominal cramps, bloating, and explosive non-bloody diarrhea [10]. In our subject's case, GL was detected by PCR with negative stool microscopy. This is likely due to microscopy having about 60% sensitivity for detecting oocyte and trophozoites in stool samples [11]. Concomitant PCR testing is beneficial as it improves detection rates in patients who have low parasitic cyst count [11] which may have been the case in our patient. Once giardiasis is suspected, it is advocated that a minimum of six stool samples be sent for microbiological analysis to objectively exclude GL, with the first three samples taken two to three days apart [10]. If results are negative, a further three samples are taken weekly to account for the varying shedding rates of the parasite [10].

The other intestinal parasite detected was *Strongyloides stercoralis* which is a soil-transmitted helminth that commonly enters the human host transcutaneously [12]. In our subject, the potential for autoinfection was increased as the rhabditiform larvae can transform into invasive filariform larvae [12]. This process can culminate in chronic infection with SS which manifests with diarrhea, abdominal cramps and itching [12]. Unchecked autoinfection in the context of altered immune status can lead to hyper-infection due to accelerated larval migration or disseminated infection which is mostly associated with co-infection with HTLV-1, or immunosuppression secondary to corticosteroid use or HIV, [12], the former two of which were present in our subject.

Another interesting observation from our report is the presence of HTLV-1 infection in our subject who had been residing in a non-endemic area (United Kingdom) for two decades. It is important to note that HTLV-1 infection is increasing in non-endemic areas due to population movement and hence co-infections with helminths such as SS are also being observed [13].

The patient's background of sarcoidosis, concurrent use of corticosteroid as well as the HTLV-1 co-infection increased the risk of

hyper-infection in our patient. HTLV-1 infection and prolonged corticosteroid use interrupt granulocyte function which can promote severe strongyloidiasis [14]. HTLV-1 infection can also lead to reduced serum IL-4, IL-5, IgE levels, causing hampered immune response to SS [14].

Conclusion

Intestinal parasitosis like strongyloidiasis should always be considered in cases of subacute to chronic diarrhea and eosinophilia. In addition, HTLV-1 co-infection should be investigated in patients with difficult to treat or disseminated strongyloidiasis infection.

Clinicians need to maintain a high level of awareness for intestinal parasites when prescribing long-term corticosteroid therapy; particularly for strongyloidiasis which can become fatal in the setting of hyper infection due to immunosuppression and HTLV-1 co-infection.

Funding source

There was no funding received from any individual or organization.

CRediT authorship contribution statement

OO: Conceptualization, Writing - original draft, reviewing and editing; **TH:** Conceptualization, Writing - original draft, reviewing and editing; **SF:** Writing original draft, reviewing, and editing; **DK:** Writing - reviewing and editing, consent from patient; **IA:** Writing - reviewing and editing, supervision.

Ethical approval

Written informed consent was obtained from the patient for publication of this case report as well as the accompanying images.

Consent

Written informed consent was obtained from the patient for publication of this case report and accompanying images. A copy of the written consent is available for review by the Editor-in-Chief of this journal on request.

Conflict of interest

The authors do not have any conflict of interests.

References

- [1] Valeyre D, Prasse A, Nunes H, Uzunhan Y, Brillet PY, Müller-Quernheim J. Sarcoidosis. *Lancet* 2014;383(9923):1155–67. [https://doi.org/10.1016/S0140-6736\(13\)60680-7](https://doi.org/10.1016/S0140-6736(13)60680-7)
- [2] Brito-Zerón P, Bari K, Baughman RP, Ramos-Casals M. Sarcoidosis involving the gastrointestinal tract: Diagnostic and therapeutic management. *Am J Gastroenterol* 2019;114(8):1238–47. <https://doi.org/10.14309/ajg.0000000000000171>
- [3] Duréault A, Chapelon C, Biard L, Domont F, Savey L, Bodaghi B, et al. Severe infections in sarcoidosis: incidence, predictors, and long-term outcome in a cohort of 585 patients. *Medicine* 2017;96(49):e8846 <https://doi.org/10.1097/MD.00000000000008846>
- [4] Almasidou D, Maniatis M, Vassiou K, Damani E, Vakalis N, Fesoulidis I, et al. Strongyloides hyperinfection in a patient with sarcoidosis. *Respirology* 2003;8(1):105–6. <https://doi.org/10.1046/j.1440-1843.2003.00429.x>
- [5] Gao X, Joshi V, Thomas S, Grabscheid E. Strongyloidiasis with coexisting sarcoidosis: Steroids can be tricky. Abstract published at Hospital Medicine March 6–9, 2016, San Diego, California. Abstract 511. *J Hosp Med* 2016; 11: Suppl 1.
- [6] Kumar A, Paulose R, Sadasivan S, Bajad C, Ramachandran A, Nair P. Sarcoidosis, steroids and strongyloides - what's the catch? *Clin Microbiol Infect* 2020;17:708–9. <https://doi.org/10.1016/j.cmi.2020.09.012>. S1198-743X (20) 30561-9.
- [7] Espelage W, der Heiden M, Stark K, Alpers K. Characteristics, and risk factors for symptomatic *Giardia lamblia* infections in Germany. *BMC Public Health* 2003;8(1):105–6. <https://doi.org/10.1186/1471-2458-10-41>. 10:41.
- [8] Lee NS, Barber L, Kanchwala A, Childs CJ, Kataria YP, Judson MA, et al. Low levels of NF-κB/p65 mark anergic CD4+ T cells and correlate with disease severity in sarcoidosis. *Clin Vaccin Immunol* 2011;18(2):223–34. <https://doi.org/10.1128/CVI.00469-10>
- [9] Horton B, Bridle H, Alexander CL, Katzer F. *Giardia duodenalis* in the UK: current knowledge of risk factors and public health implications. *Parasitology* 2019;146(4):413–24. <https://doi.org/10.1017/S0031182018001683>
- [10] Minetti C, Chalmers RM, Beeching NJ, Probert C, Lamden K. Giardiasis. *Br Med J* 2016;27(355):i5369. <https://doi.org/10.1136/bmj.i5369>
- [11] Sari Y, Suryawati B, Yudhani RD, Artama WT. Comparison of microscopic and PCR for detection of *Giardia spp.* in the human faecal sample at Bedog Watershed, Sleman, DIY. *Kne Life Sci* 2019;4:103. <https://doi.org/10.18502/klsv4i12.4162> (Accessed 19/10/2021).
- [12] Nutman TB. Human infection with *Strongyloides stercoralis* and other related Strongyloides species. *Parasitology* 2017;144(3):263–73. <https://doi.org/10.1017/S0031182016000834>
- [13] Dykie A, Wijesinghe T, Rabson AB, Madugula K, Farinas C, Wilson S, et al. Human T-cell Leukemia virus type 1 and *Strongyloides stercoralis*: partners in pathogenesis. *Pathogens* 2020;9(11):904. <https://doi.org/10.3390/pathogens9110904>. 29.
- [14] Montes M, Sawhney C, Barros N. *Strongyloides stercoralis*: there but not seen. *Curr Opin Infect Dis* 2010;23(5):500–4. <https://doi.org/10.1097/QCO.0b013e32833df718>