

Comparative accuracy of magnetic resonance morphometry and sonography in assessment of post-cesarean uterine scar

Gayatri Satpathy, Ishan Kumar¹, Manjari Matah, Ashish Verma¹

Departments of Obstetrics and Gynaecology and ¹Radiodiagnosis, Institute of Medical Sciences, Banaras Hindu University, Varanasi, Uttar Pradesh, India

Correspondence: Dr. Ashish Verma, Department of Radiodiagnosis, Institute of Medical Sciences, Banaras Hindu University, Varanasi - 221005, Uttar Pradesh, India. E-mail: drdnv5@gmail.com

Abstract

Objective: To compare the diagnostic accuracy of magnetic resonance imaging (MRI) with that of ultrasonography (USG) for the measurement of lower segment cesarean scar during trial of labor after cesarean (TOLAC). **Materials and Methods:** This was a prospective case-control observational study conducted with a cohort of 30 participants being considered for TOLAC but eventually proceeding to lower segment cesarean section (LSCS) at a university-based teaching institute over a period of 2 years. Measurement of scar thicknesses were done by MRI and USG preoperatively and validated by surgical findings. Comparison of diagnostic accuracy as well as the cut-off values (to differentiate a normal scar from an abnormal scar) was done between the two modalities. **Results:** Insignificant systematic error between the measurements obtained by the two modalities was noted by a Bland–Altman analysis. The diagnostic accuracy of USG for differentiating a normal from an abnormal uterine scar was 96.7% while that of MRI was at a slightly lower level of 90%. A strong level of agreement between the two modalities was observed. **Conclusion:** MRI offers no advantage in diagnostic accuracy for the measurement of LSCS scar thickness during consideration of TOLAC. **Advances in Knowledge:** Measurement of uterine scar by MRI has a good correlation with that done on USG in the setting of post-cesarean pregnancy. The results hold good both for normal (grades 1 and 2) and abnormal (grades 3) scars. MRI, however, does not offer any added advantage over sonographic scar thickness measurement for the differentiation of a normal (grades 1 and 2) from an abnormal (grade 3) scar.

Key words: Lower segment caesarian section; magnetic resonance imaging; scar thickness; uterine scar; vaginal birth after cesarean

Introduction

A worldwide increase in the rate of deliveries conducted by lower segment cesarean section (LSCS) has been documented over the last two decades with resultant increase in the proportion of women with previous

cesarean births requiring obstetric care during repeat pregnancies.^[1] The challenge faced by an obstetrician is to decide between a repeat cesarean versus vaginal birth after caesarian (VBAC), the latter leading to an increased chance

Access this article online	
Quick Response Code: 	Website: www.ijri.org
	DOI: 10.4103/ijri.IJRI_325_17

This is an open access journal, and articles are distributed under the terms of the Creative Commons Attribution-NonCommercial-ShareAlike 4.0 License, which allows others to remix, tweak, and build upon the work non-commercially, as long as appropriate credit is given and the new creations are licensed under the identical terms.

For reprints contact: reprints@medknow.com

Cite this article as: Satpathy G, Kumar I, Matah M, Verma A. Comparative accuracy of magnetic resonance morphometry and sonography in assessment of post-cesarean uterine scar. Indian J Radiol Imaging 2018;28:169-74.

of uterine scar dehiscence/rupture during the trial of labor,^[2] and consequent high maternal and neonatal mortality and morbidity. Despite a high success rate of VBAC (50–85%), obstetricians remain apprehensive for scar rupture, hence, patients mostly end up having repeat cesarean deliveries.^[3] The reliability of methods to predict the risks of uterine rupture in post LSCS pregnancies has been variable with sonographic measurement of scar thickness being the most sought after technique.^[4,5] This may be one of the causes for a natural preference of repeat cesarean (both by the doctor and the patient) till certain reproducible and reliable techniques are available for a reasonable prediction of a safe VBAC. Magnetic resonance imaging (MRI) has recently shown promise for evaluation of uterine scar thickness.^[6-8] As opposed to ultrasonography (USG), which is the current gold standard for this purpose, MRI reduces observer dependence and has a superior multiplanar capability. These features may offer advantage while measuring uterine scar as well. The aim of the present study was to compare scar thickness measured by MRI to that done by USG while evaluation for VBAC with surgical scar assessment being considered as the gold standard.

Patients and Methods

This institutional review board approved study was a prospective observational study carried out among 30 pregnant women where a decision of repeat cesarean section was taken due to one of the established indications of LSCS, viz. previous 2 LSCS ($n = 9$), scar tenderness ($n = 7$), breech presentation ($n = 2$), features of chorio-amnionitis ($n = 2$), severe pre-eclampsia ($n = 2$), fetal distress ($n = 2$), uncontrolled maternal diabetes ($n = 1$), intrauterine growth retardation ($n = 1$), placental abruption ($n = 1$) and meconium-stained liquor ($n = 1$). These included both pre-registered patients presenting to the antenatal clinic and unregistered emergency patients. The mean maternal age was 31 years (range, 26–35 years) while the mean gestational age was 37 weeks 6 days (range, 37–39 weeks). Grand multigravida (gravidity >4) constituted 53.7% of the study (range 2 to 7) with most ladies having >1 previous LSCS ($n = 29$) and only 7 (23.3%) having a previous VBAC. Majority (60%) of the scars had a complication after the index surgery, with wound infection being the most common complication ($n = 6$). Written informed consent was obtained from all the participants prior to enrolment, and the regulations laid down in the PCPNDT act 1994 were followed during all scans.^[9]

Patients with multiple pregnancies, preterm deliveries, polyhydramnios or oligohydramnios, low lying placenta, patients with history of uterine surgery other than cesarean section or unavailable previous caesarian details, and having a contraindication to MRI were excluded from the study. A standard protocol for patient management, as practiced in the antenatal clinic, was followed during which

an ultrasound was performed for assessment of the fetus as well as the scar.

Protocol for ultrasonography

All sonographic examinations were done after 36 weeks to assess the lower uterine segment (LUS), on a high-end equipment (iU22; Philips Medical System, Andover, MA, USA) using a 3.5-MHz multifrequency convex transabdominal transducer. Transabdominal ultrasonography was done with the patient having a moderately full urinary bladder in the supine position. LUS was scanned in sagittal section under magnification to localize the thinnest zone. Measurements were taken with the '+' shape cursors at urinary bladder wall – myometrium interface and myometrium/chorioamniotic membrane – amniotic fluid interface [Figure 1]. Average of 2-3 readings taken was recorded with the vertical bar of the caliper being as parallel to the interface as possible. The examination was aborted in case a uterine contraction was noted and was repeated after 30 minutes.

Protocol for magnetic resonance imaging

MRI was done on a 1.5-Tesla (Siemens Avanto, Erlangen, Germany) system with an actively shielded whole body superconducting magnet. Imaging was done using an 8-channel Torso phased-array body coil with the patient in the supine position and a moderately full urinary bladder. Signal improvement was done by addition of integrated spine elements. Saturation bands were applied over the abdomen to eliminate bowel peristalsis and fetal movement artifacts. The focus of imaging was tapered down to pelvis with the field of view just enough to cover the area (40 cm). Predesignated standard protocols were followed consisting of T1W and T2W imaging sequences in axial and sagittal planes remaining perpendicular to the long axis of the scar. Initial single shot localizers were taken to define the uterine scar (similar to the method followed by sonography), followed by oblique images which were

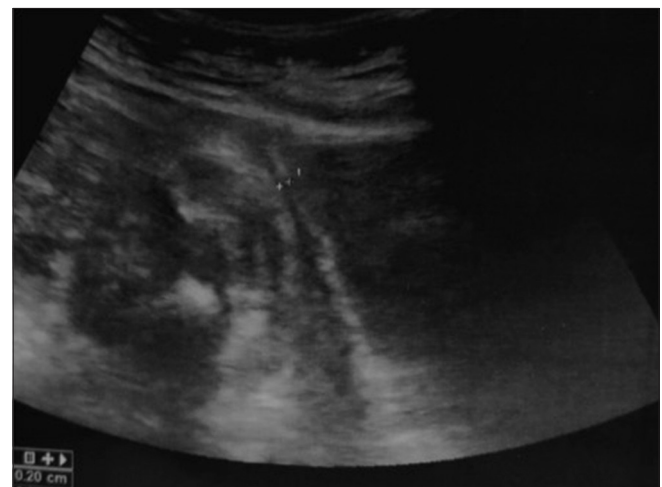


Figure 1: Longitudinal sonographic image showing measurement of scar thickness taken at the thinnest portion of the lower uterine segment

exactly perpendicular to the scar. This exercise was done to eliminate errors of over and underestimation due to foreshortening or widening of the region in either plane. The measurements were taken in T2 mid-sagittal image at the thinnest portion of the scar [Figure 2].

Protocol for surgical scar grading

The LUS was assessed and graded according to the system developed by Qureshi *et al.*:^[5]

Grade I: Well-developed LUS.

Grade II: Thin LUS, content not visible.

Grade III: Translucent LUS, content visible.

Grade IV: Well-circumscribed defect either dehiscence or rupture.

Grades IV and III were considered abnormal LUS intraoperatively, and grades I and II were considered normal.

Statistical approach

Statistical analysis was performed using SPSS software (IBM Corp 2013; Version 22.0; Armonk, NY). The mean scar thickness derived by each modality was stratified according to the surgical grades assigned during surgery [Tables 1 and 2]. The significance of difference in mean between normal and abnormal scars was evaluated using *t*-test. This exercise was done for each modality separately. Further, the difference between the measurements obtained by both modalities (*viz.* difference between the MRI derived scar thickness and USG-derived thickness) was plotted against the mean values of scar thickness derived from the two methods

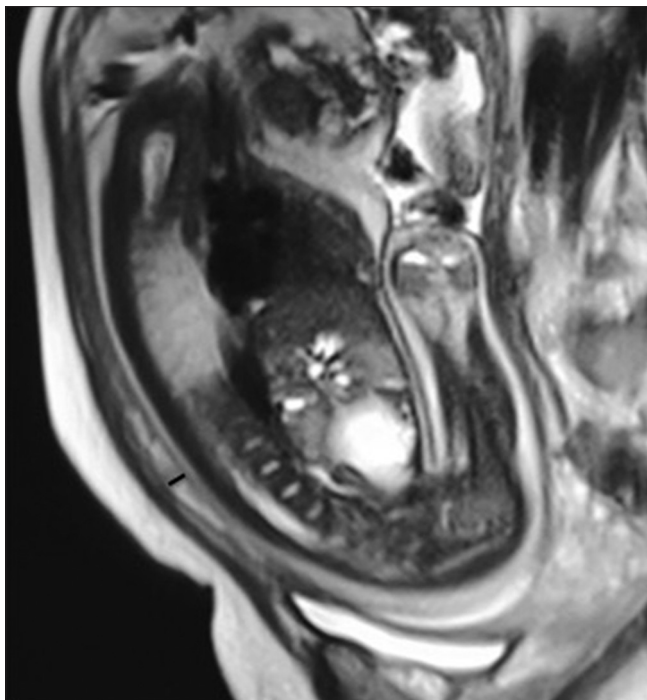


Figure 2: T2-weighted mid-sagittal image showing hyperintense scar and thickness measured at its thinnest portion

to examine systematic error, as described by Bland and Altman [Figure 1]. Intraclass correlation coefficient analysis was also used to quantify the agreement between the scar thicknesses measured by both the modalities. Receiver-operating characteristics (ROC) curves were constructed to evaluate the individual utility of the two modalities in predicting surgical grade 3 scar (*i.e.*, the abnormal scar) with the help of the area under the curve (AUC) [Figure 2]. Cut-off values were determined based on ROC curve that optimized sensitivity, specificity, positive predictive value (PPV), and negative predictive value (NPV) of each modality for the purpose [Figure 3].

Results

The cohort under evaluation followed a normal distribution; the groups were matched for age and parity with no significant difference among the characteristics of patients included in the three groups (*i.e.*, the three grades of scar) ($P < 0.05$). The difference in means of scar thickness measured by the two modalities in each of the three groups and between the normal (group 1+2) and abnormal (group 3) scars was insignificant ($t < 0.05$). Hence, the results for both the modalities were stratified according to the surgically-assessed grade of scar thickness to demonstrate the role of each modality in differentiating a normal (grade I and II put together) and abnormal (grade III) scars [Table 2].

Evaluation of systematic error between measurements by the two modalities

The Bland–Altman analysis [Figure 3] revealed an insignificant systematic error between differences of the measurements obtained by both modalities (*i.e.*, MRI thickness minus USG thickness).

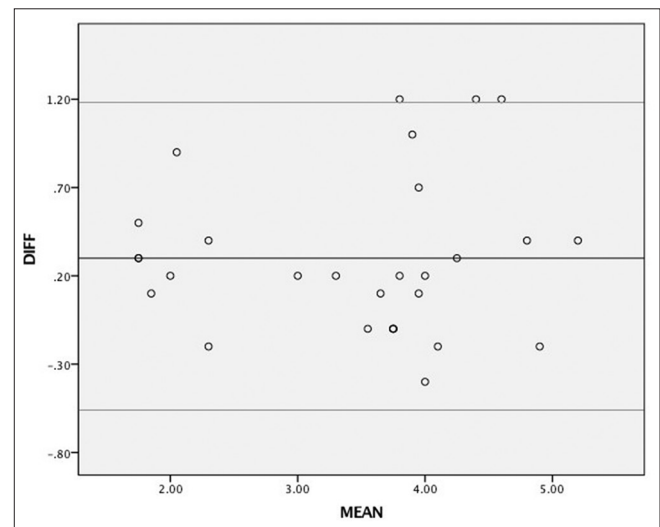


Figure 3: Bland–Altman plot of the difference between the scar thickness measurements obtained by USG and MRI against the mean values of scar thickness derived from these two methods

Table 1: Uterine scar thickness measured by MRI and USG in patients being assessed for VBAC in grade I, grade II and grade III

Patient no	Grade I	
	Scar thickness (mm)	
	MRI	USG
Patient 1	4.1	4
Patient 3	4	4.2
Patient 6	5.4	5
Patient 7	3.7	3.6
Patient 8	2.2	2.4
Patient 10	4.4	4.1
Patient 13	4	3.9
Patient 14	5	4.6
Patient 16	3.5	3.6
Patient 20	3.7	3.8
Patient 22	5.2	4
Patient 25	4.8	5
Patient 27	3.9	3.7
Mean	4.15	3.99

Patient no	Grade II	
	Scar thickness (mm)	
	MRI	USG
Patient 5	1.9	1.8
Patient 9	2.5	2.1
Patient 12	3.4	3.2
Patient 18	2.5	1.6
Patient 19	2.1	1.9
Patient 21	4.4	3.4
Patient 26	2	1.5
Patient 28	1.9	1.6
Patient 30	3.1	2.9
Mean	2.64	2.22

Patient no	Grade III	
	Scar thickness (mm)	
	MRI	USG
Patient 2	5	3.8
Patient 4	1.9	1.6
Patient 11	3.7	3.8
Patient 15	4.4	3.2
Patient 17	4.1	3.9
Patient 23	3.8	4.2
Patient 24	3.7	3.8
Patient 29	4.3	3.6
Mean	3.86	3.49

Diagnostic accuracy indicators

The ROC analysis of USG-derived scar thickness [Figure 4A and C] assigned a cut-off value of 3.5 mm while that for MRI-derived scar thickness gave a cut-off value of 3.45 mm [Figure 4B and C] for the differentiation of a normal scar from an abnormal one. These thresholds carried a sensitivity of 100% (USG) versus 88.9% (MRI), specificity of 85% (USG) versus 90.4% (MRI), PPV of

Table 2: Correlation of mean uterine scar thickness in each group measured by MRI and USG in patients being assessed for VBAC. Grade I and II scars have been considered together in final analysis as 'normal scars' while grade III scars have been labelled as 'abnormal'

	USG scar thickness (mm)	MRI scar thickness (mm)
Grade 1	3.99	4.15
Grade 2	3.49	3.86
Grade 1 + 2	3.8	4.005
Grade 3	2.2	2.64
<i>t</i>	5.286	<0.001
<i>P</i>	4.091	<0.001

94.2% (USG) versus 95.6% (MRI), and NPV of 100% (USG) versus 77.7% (MRI). Accordingly, both USG and MRI had a high AUC (USG = 0.936 versus MRI = 0.861) with the former scoring better over the latter in this respect. Accordingly, the diagnostic accuracy of USG for differentiating a normal from an abnormal uterine scar was 96.7% while that of MRI was at a slightly lower level of 90% [Figure 5].

Surgical validation of ultrasonography and magnetic resonance imaging-derived scar thickness

Peroperative assessment of uterine scar revealed that 43.3% ($n = 13$) of the women had a grade I scar, 26.7% ($n = 8$) had Grade II, and 30% ($n = 9$) had Grade III scar. Hence, 30% of the patients had an abnormal scar while in 70% the scar was normal. The difference between the mean (and standard deviation) of USG-derived scar thickness in women with normal scar from abnormal scar was statistically significant ($3.80 \text{ mm} \pm 0.75 \text{ mm}$ for normal versus $2.22 \text{ mm} \pm 0.74 \text{ mm}$ for abnormal). Corresponding values for MRI remained $4.03 \text{ mm} \pm 0.85 \text{ mm}$ and $2.64 \text{ mm} \pm 0.84 \text{ mm}$, respectively, which was significant ($P < 0.05$). It may be noted that the final validation of our data was done on the basis of surgical findings, which correlated well with the statistics derived hitherto.

Intermodality agreement across groups

Intraclass correlation coefficient of 0.936 was obtained signifying a strong level of agreement between the two modalities when a correlation between scar thickness in a single group (i.e., normal or abnormal) was measured by two different modalities (i.e., USG and MRI).

Discussion

The most suitable method to predict the likelihood of scar dehiscence during a trial of labor after cesarean (TOLAC) is to assess the size of post-cesarean scar thickness in a nonpregnant uterus.^[10] The practicability of this option, however, seems questionable, as even in the developed world with a high resource-to-resource seeker ratio, the motivation to undergo an interval scan for measurement of previous cesarean scar may be difficult to achieve. In a developing nation, women undergo scans only during their next gravidity and that too for the assessment of fetal

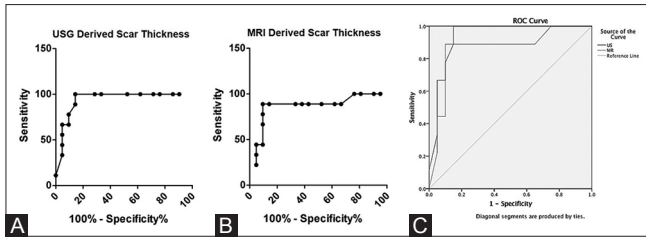


Figure 4 (A-C): Receiver–operating characteristics (ROC) curves evaluate individual utility of USG (A), MRI (B) and comparison of both (C) in predicting surgical grade 3 scar

well-being. Scar thickness measurement has to be mostly done as a clinical exercise during such an investigation to improve outcome and prevent complications. In most clinical settings, especially in the developing world, booking of pregnancy with a fully-equipped medical facility right at the initiation is not a routine practice, as most patients seek support from local midwifery services. Such patients report to proper medical centers only during the third trimester, if at all. In such circumstances, the residual myometrium is quite thin and is difficult to measure, but still remains the most useful method to assess the likelihood of scar dehiscence.^[11] USG has been labelled as the most optimal method to assess post-cesarean scar thickness with a threshold of 3.5 mm.^[12] The measurements done by USG, however, show poor interobserver reproducibility in few studies, and the sonographic technique for the purpose has been shown to have a shallow upstroke on the learning curve; hence, the same are not predictive for the risk of scar dehiscence in an individual woman.^[13] MRI, on the other hand, may have a better reproducibility and can be evaluated by many observers once the images have been acquired. Though the results of our study have substantiated the role of USG over MRI for the purpose, we would suggest further studies with larger sample sizes as in our setting the measurements were made by experienced observers only (experience >12 years).

- (a) The systematic error between measurements of post-cesarean uterine scar thickness done by USG has an insignificant difference from that done by MRI. This may be extrapolated to the fact that, in a single case, though a measurement notified by USG may be different from that done by MRI, the error of judgment liable to emanate due to the same may be clinically insignificant
- (b) The diagnostic accuracy of MRI for differentiating a normal from an abnormal uterine scar is slightly lower (90%) than that of USG (96.7%). A strongly significant negative predictive value has been assigned to USG-derived scar thickness for defining an LUS as abnormal ($P < 0.001$). The PPV of LUS thickness is lesser than the NPV, suggesting that all thin LUS are not abnormal and the prediction of uterine scar dehiscence/rupture in these cases is not highly reliable. This may be due to several factors other than LUS thickness, such as obstetric and social, which might be involved in the causation of an abnormal LUS. Moreover, there

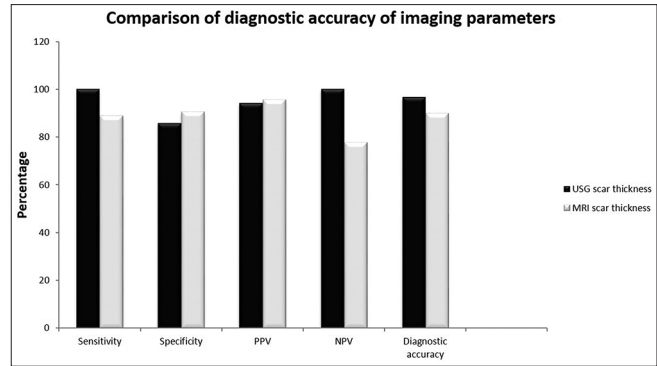


Figure 5: Comparison between sensitivity, specificity, positive predictive value (PPV), negative predictive value (NPV), and diagnostic accuracies between USG and MRI based on cut-off values determined from ROC curve

is always a component of intraobserver error, which is relatively large for measurements by USG in patients with thin LUS. The PPV of MRI is similar to that of USG but remains higher than its own NPV, indicating that in a single case MRI may be better than USG for predicting scar dehiscence. The sensitivity and specificity for a cut-off value of 3.5 mm for USG and 3.45 mm for MRI to differentiate a normal from an abnormal scar are comparable, while the difference in these cut-off values is also insignificant. As with USG, the correlation between MRI-derived scar thickness and intraoperative grade of uterine scar was statistically significant in the present study ($P < 0.001$). These results may show promise for utilization of MRI as a problem-solving tool in certain high-risk cases or cases with multiple cesareans, where multiple factors causing an abnormal scar are present. Further, the multiparametric capability of MRI to predict the adequacy of scar healing, as suggested in our recent publication, gives this modality an added advantage over USG.^[14] However, we could not find a comparable study to evaluate our results from a relatively small dataset and propose that a larger prospective study maybe performed

- (c) The scar thickness data as measured by the two modalities was validated surgically in each of the 30 participants whereby it was noted that the difference between the mean (and standard deviation) of USG-derived scar thickness as well as MRI-derived thickness in women with normal scar ($3.80 \text{ mm} \pm 0.75 \text{ mm}$ for USG and $4.03 \text{ mm} \pm 0.85 \text{ mm}$ from MRI) had a statistically significant difference ($P < 0.05$) from that of an abnormal scar ($2.22 \text{ mm} \pm 0.74 \text{ mm}$ for USG and $2.64 \text{ mm} \pm 0.84 \text{ mm}$ for MRI). This data is in agreement to most previous studies and again favors USG as the preferred modality for initial assessment of a post-cesarean scar
- (d) The intermodality agreement across groups was established by an intraclass correlation coefficient of 0.936, which signifies a strong level of agreement between the two modalities. USG is currently the modality of choice for the assessment of a post-cesarean scar and would remain

as such due to its cost effectiveness, ease of availability, and operability. This result, however, validates the role of MRI for this important clinical indication and in accordance with the justifications given above may establish the role of this modality as a problem-solving tool, if not the initial modality of choice. Further, for a beginner, defining a uterine scar by USG may be difficult as the same is usually judged on the basis of a wedge-shaped hypoechoic area at the expected site cesarean section wound.^[15] A tailored application of MRI with utilization of specific imaging protocol has been shown to have better contrast resolution than other modalities and can offer optimal contrast resolution for the above described purpose also. Further, with multiparametric capabilities defining a scar may be best done by MRI.^[14,16]

Conclusion

According to the present study, the diagnostic accuracy of USG-derived scar thickness is superior to MRI-derived scar thickness. MRI being an expensive investigation may not replace ultrasound for the measurement of LSCS scar during TOLAC. However, in isolated cases, MRI may hold promise to suggest the health of a scar due to a higher NPV than USG.

Financial support and sponsorship

Nil.

Conflicts of interest

There are no conflicts of interest.

References

- Hamilton BE, Hoyert DL, Martin JA, Strobino DM, Guyer B. Annual summary of vital statistics: 2010-2011. *Pediatrics* 2013;131:548-58.
- Biswas A. Management of previous cesareans section. *Curr Opin Obstet Gynecol* 2003;15:123-9.
- Quilligan EJ. Vaginal birth after cesarean section: 270 degrees. *J Obstet Gynecol Res* 2001;27:169-73.
- Martins WP, Bara DA, Gallarreta FMP, Irion O, Boulvain M. Inter and intraobserver variability in sonographic measurement of the lower uterine segment after a previous cesarean section. *Ultrasound obstet gynecol* 2006;27:420-4.
- Qureshi B, Inafuku K, Oshima K, Masamoto H, Kanazawa K. Ultrasonographic evaluation of lower uterine segment to predict the integrity and quality of cesarean scar during pregnancy: A prospective study. *Tohoku J Exp Med* 1997;183:55-65.
- Sen S, Malik S, Salhan S. Ultrasonographic evaluation of lower uterine segment thickness in patients of previous caesarean section. *Int J Gynecol Obstet* 2004;87:215-9.
- Dicle O, Kucukler C, Pinar T, Erata Y, Posaci C. Magnetic resonance imaging evaluation of incision healing after cesarean sections. *Eur Radiol* 1997;7:31-4.
- Ofili-Yebovi D, Ben-Nagi J, Sawyer E, Yazbek J, Lee C, Gonzalez J, *et al.* Deficient lower-segment Cesarean section scars: Prevalence and risk factors. *Ultrasound Obstet Gynecol* 2008;31:72-7.
- Arnold F, Kishor S, Roy TK. Sex-Selective Abortions in India. *Popul Dev Rev* 2002;28:759-85.
- Pomorski M, Fuchs T, Zimmer M. Prediction of uterine dehiscence using ultrasonographic parameters of cesarean section scar in the nonpregnant uterus: A prospective observational study. *BMC Pregnancy Childbirth* 2014;14:365.
- Naji O, Abdallah Y, Bij De Vaate AJ, Smith A, Pexsters A, Stalder C, *et al.* Standardized approach for imaging and measuring Cesarean section scars using ultrasonography. *Ultrasound Obstet Gynecol* 2012;39:252-9.
- Jastrow N, Chaillet N, Roberge S, Morency AM, Lacasse Y, Bujold E. Sonographic lower uterine segment thickness and risk of uterine scar defect: A systematic review. *J Obstet Gynecol Can* 2010;32:321-7.
- Drouin, O, Bergeron T, Beaudry A, Demers S, Roberge S, Bujold E. Ultrasonographic Evaluation of Uterine Scar Niche before and after Laparoscopic Surgical Repair: A Case Report. *AJP Rep* 2014;4:e65-8.
- Kumar I, Verma A, Matah M, Satpaty G. Utility of Multiparametric MRI in Caesarean Section Scar Characterization and pre-operative prediction of scar Dehiscence: A Prospective Study. *Acta Radiol.* 2017;58:890-6.
- Chen HY, Chen SJ, Hseih FJ. Observation of cesarean section scar by transvaginal ultrasonography. *Ultrasound Med Biol* 1990;16:443-7.
- Ogura A, Miyai A, Maeda F, Hongoh T, Kikumoto R. Comparison of contrast resolution between dynamic MRI and dynamic CT in liver scanning. *Nihon Hoshasen Gijutsu Gakkai Zasshi* 2002;58:286-91.